

1  
2  
3  
4 **Functional and anatomical significance of the ectopic inner foveal layers in eyes**  
5 **with idiopathic epiretinal membranes: surgical results at 12 months.**  
6  
7  
8  
9

10 Short title: Surgical significance of the ectopic inner foveal layers.  
11

12  
13 Andrea Govetto, MD;<sup>1,2</sup> Gianni Virgili, MD;<sup>3</sup> Francisco J. Rodriguez, MD; <sup>2</sup> Marta S.  
14 Figuerola, MD, PhD; <sup>4</sup> David Sarraf, MD; <sup>5</sup> Jean Pierre Hubschman, MD.<sup>1</sup>  
15  
16  
17  
18

- 19 1. Retina Division, Stein Eye Institute, University of California Los Angeles, USA.
- 20 2. Retina Division, Fundación Oftalmológica Nacional Hospital, del Rosario
- 21 University, Bogotá, Colombia.
- 22 3. Ophthalmology department, Careggi University Hospital, Florence, Italy.
- 23 4. Retina Division, Ramon y Cajal University Hospital, Madrid, Spain.
- 24 5. Retinal Disorders and Ophthalmic Genetics Division, Stein Eye Institute,
- 25 University of California Los Angeles, USA.
- 26
- 27
- 28
- 29
- 30
- 31
- 32
- 33
- 34

35 The authors have no conflicts of interest relevant to this submission to disclose.  
36  
37  
38  
39  
40  
41  
42  
43  
44

45 **Corresponding Author:**  
46

47 Andrea Govetto, MD.  
48

49 Retina Division, Fundación Oftalmológica Nacional Hospital, del Rosario University  
50

51 50 street, 50 #13, Bogotá, Colombia  
52

53 Telephone: +57 1 7455999  
54

55 Email: [a.govetto@gmail.com](mailto:a.govetto@gmail.com)  
56  
57  
58  
59  
60  
61  
62  
63  
64  
65

1  
2  
3  
4 **Key Words:** Epiretinal Membrane; Macular Pucker; Ectopic inner foveal layers; Pars  
5  
6 Plana Vitrectomy; Optical coherence tomography.  
7  
8  
9

10 **Summary statement:** This study analyzed the outcomes of pars plana vitrectomy with  
11  
12 epiretinal membrane peel in eyes with and without ectopic inner foveal layers. The  
13  
14 presence of ectopic inner foveal layers was associated with lower preoperative and  
15  
16 postoperative visual acuity, and should be considered a negative prognostic factor for  
17  
18 postoperative anatomical and functional recovery.  
19  
20  
21  
22  
23  
24  
25  
26  
27  
28  
29  
30  
31  
32  
33  
34  
35  
36  
37  
38  
39  
40  
41  
42  
43  
44  
45  
46  
47  
48  
49  
50  
51  
52  
53  
54  
55  
56  
57  
58  
59  
60  
61  
62  
63  
64  
65

## Abstract

**Purpose:** To describe the functional and anatomical outcomes of pars plana vitrectomy (PPV) with epiretinal membrane (ERM) and internal limiting membrane (ILM) peel in eyes with and without ectopic inner foveal layers (EIFL).

**Methods:** In this retrospective multicenter study were enrolled patients diagnosed with idiopathic ERMs who underwent PPV with ERM and ILM peel, with a minimum follow-up of 12 months. Preoperative and postoperative spectral domain optical coherence tomography (SD-OCT) scans were qualitatively and quantitatively evaluated. The association of the EIFL and other SD-OCT parameters with preoperative and postoperative best corrected visual acuity (BCVA) was analyzed.

**Results:** One-hundred and eleven eyes of 107 patients were included. Preoperatively, the EIFL were present in 56 out of 111 eyes (50.4%). The presence of EIFL was significantly associated with lower preoperative and postoperative BCVA ( $p < 0.001$ ). EIFL thickness was negatively correlated with preoperative BCVA ( $r = 0.58$ ,  $p < 0.001$ ). Postoperatively, the EIFL persisted in 51 out of 56 eyes (91%) with stage 3 and 4 ERMs. EIFL thickness decreased significantly after surgery ( $p < 0.001$ ), but postoperative EIFL thinning had no direct effect on postoperative change in BCVA. At 12 months from surgery, EIFL thickness maintained a significant negative correlation with BCVA ( $r = 0.55$ ,  $p < 0.001$ ).

**Conclusions:** The presence of EIFL should be considered a negative prognostic factor for postoperative anatomical and functional recovery.

## Introduction

Pars Plana vitrectomy (PPV) with membrane peeling is the standard treatment for symptomatic idiopathic epiretinal membranes (ERMs). However, despite high anatomical success rates, the postoperative visual prognosis is often elusive.<sup>1-4</sup> Consequently, considerable efforts have been made to identify reliable prognostic biomarkers that may predict postoperative visual outcome.<sup>5,6</sup>

Recent advancements with spectral-domain optical coherence tomography (SD-OCT) technology, including remarkably greater A scan speeds, have led to faster data acquisition and higher resolution. As a result, SD-OCT imaging provides a powerful tool for both preoperative and postoperative ERM evaluation.

Several biomarkers have been proposed as predictors of postoperative best corrected visual acuity (BCVA) in idiopathic ERMs, including the integrity of both the ellipsoid and interdigitation zone bands, and the length of photoreceptor outer segment.<sup>3,7-9</sup> However, the prognostic value of such factors remains controversial, as the evaluation of outer retinal integrity may be limited due to SD-OCT imaging artifacts that are common with the analysis of idiopathic ERMs.<sup>10</sup>

As the analysis of outer retinal alterations may be insufficient to predict postoperative visual outcome, attention has shifted to the study of the inner retina, the primary affected site of ERM-associated mechanical stress.<sup>11-18</sup> The presence of continuous ectopic inner foveal layers (EIFL) in the central foveal region was recently described with SD-OCT in eyes with idiopathic ERMs. EIFL formation may represent an important sign of ERM progression, and it is the centerpiece of a newly proposed SD-OCT staging scheme for idiopathic ERMs.<sup>19</sup> Although the presence of EIFL was

1  
2  
3  
4 significantly associated with lower preoperative BCVA, the prognostic value of the EIFL  
5  
6 on postoperative BCVA has not yet been properly studied.<sup>19</sup>  
7  
8

9 To investigate the postoperative clinical significance of the EIFL, this study  
10 performed an in-depth analysis of both functional and anatomical surgical results in a  
11 consecutive cohort of patients diagnosed with idiopathic ERMs who underwent PPV with  
12  
13 ERM and internal limiting membrane (ILM) peel.  
14  
15  
16  
17  
18  
19  
20  
21

## 22 **Methods:**

### 23 *Study design.*

24  
25  
26 This study was approved by the Institutional Review Boards of the University of  
27  
28 California Los Angeles, the Fundación Oftalmológica Nacional Hospital and the Ramon y  
29  
30 Cajal University Hospital. This research project adhered to the tenets of the Declaration  
31  
32 of Helsinki and was designed in compliance with the Health Insurance Portability and  
33  
34 Accountability Act regulations.  
35  
36  
37  
38  
39

40 A retrospective, observational, and consecutive review of the clinical records of  
41  
42 patients diagnosed with idiopathic ERMs and evaluated by three retina specialists (J.P.H,  
43  
44 F.J.R, and M.S.F) between January 1, 2010 and January 31, 2016 at the Stein Eye  
45  
46 Institute, the Fundación Oftalmológica Nacional Hospital and the Ramon y Cajal  
47  
48 University Hospital, was performed. Cases were identified by a medical billing record  
49  
50 search, using the International Statistical Classification of Diseases and Related Health  
51  
52 Problems, Ninth Revision diagnosis code 362.56 for macular pucker. Inclusion criteria  
53  
54 included the presence of idiopathic unilateral or bilateral ERM treated with PPV and  
55  
56  
57  
58  
59  
60  
61  
62  
63  
64  
65

1  
2  
3  
4 membrane peeling, with a minimum follow up of 12 months. Exclusion criteria are listed  
5  
6 in Table 1.  
7  
8  
9

10  
11 *Ophthalmological evaluation and SD-OCT imaging.*  
12

13  
14 Comprehensive ophthalmologic exams including BCVA and intraocular pressure  
15  
16 assessment, slit-lamp biomicroscopy, fundus examination, and SD-OCT imaging were  
17  
18 performed in all patients before surgery and at 1, 6 and 12 months after surgery.  
19  
20

21 BCVA was recorded at each visit, reported in Snellen fraction and then converted  
22  
23 into logarithm of the minimal angle of resolution (logMAR) values for statistical analysis.  
24  
25

26 In all cases, SD-OCT images were obtained with the Spectralis OCT with eye-  
27  
28 tracking dual-beam technology (Heidelberg Engineering GmbH, Heidelberg, Germany)  
29  
30 and analyzed with the Heidelberg Eye Explorer (version 1.8.6.0) using the HRA/Spectralis  
31  
32 Viewing Module (version 5.8.3.0).  
33  
34

35  
36 Spectralis SD-OCT scans were used for all quantitative measurements and  
37  
38 qualitative evaluation of ERMs. At each visit, all eyes were imaged with at least 2 type of  
39  
40 SD-OCT scan patterns: 19 B-scans administered over an area of 20 X 15 degrees with  
41  
42 each B-scan spaced 242  $\mu\text{m}$  apart and a single high-definition horizontal B-scan at 30  
43  
44 degrees. In addition, some of the included eyes underwent high-density scanning over a  
45  
46 macular area of either 15 X 10 degrees with 97 B-scan each spaced 31  $\mu\text{m}$  apart, or 15  
47  
48 X 5 degrees with 131 B-Scan spaced 11  $\mu\text{m}$  apart.  
49  
50  
51

52  
53 On SD-OCT, all retinal layers were identified according to the IN•OCT  
54  
55 Consensus.<sup>20</sup>  
56  
57  
58  
59  
60  
61  
62  
63  
64  
65

1  
2  
3  
4 EIFL were identified with SD-OCT and were defined according to Govetto et al:  
5  
6 presence of continuous hyporeflective and hyperreflective bands, extending from the  
7  
8 inner nuclear layer (INL) and inner plexiform layer (IPL) across the foveal region and  
9  
10 visible in all SD-OCT scans centered in the fovea, as illustrated in figure 1.<sup>19</sup>  
11  
12  
13

14 The thickness of the EIFL in the central foveal region were measured manually  
15  
16 with the “caliper” function of the Heidelberg Spectralis, adjusted to an aspect ratio of 1:1  
17  
18 mm, by tracing a vertical line from the outer margin of the INL to the inner margin of the  
19  
20 ILM.<sup>19</sup> Mean central foveal thickness (CFT) values were obtained automatically by the  
21  
22 Heidelberg software.  
23  
24

25  
26 With SD-OCT, ERMs were defined as single, irregular, and hyperreflective lines  
27  
28 above the ILM, often associated with underlying retinal wrinkling and with the presence  
29  
30 of hyporeflective spaces between the ERM and ILM. All ERMs were classified according  
31  
32 to the 4-grade staging system by Govetto et al., as illustrated in figure 1.<sup>19</sup>  
33  
34  
35

36 Cystoid macular edema (CME) was defined with SD-OCT as the presence of  
37  
38 multiple hyporeflective intraretinal cystoid spaces.  
39  
40

41 The presence of a discontinuous ellipsoid band in the foveal region was considered  
42  
43 a sign of ellipsoid zone disruption, while the appearance of a roundish or diffuse  
44  
45 hyperreflective area between the ellipsoid zone and the interdigitation zone in the central  
46  
47 fovea was defined as the *Tsunoda* or “cotton ball” sign, representing tractional elevation  
48  
49 of the photoreceptors.<sup>20</sup>  
50  
51

52  
53 All SD-OCT images were quantitatively and qualitatively evaluated by three  
54  
55 independent and masked observers (A.G., F.J.R and M.S.F), and disagreements were  
56  
57 resolved with the intervention of a fourth observer (D.S. or J.P.H.).  
58  
59  
60  
61  
62  
63  
64  
65

### *Surgical procedures.*

All patients underwent a standard, three port 23-Gauge PPV with ERM and ILM peeling performed by three vitreo-retinal surgeons (J.P.H., F.J.R, and M.S.F) with the Constellation vision system (Alcon, Fort wort, TX, USA).

Combined phacoemulsification and intraocular lens implantation procedures were performed at the discretion of the surgeon.

Core vitrectomy was performed in all cases and, after the creation of posterior vitreous detachment, Grieshaber ILM forceps (Alcon, Fort Wort, TX, USA) were used to peel both ERM and ILM up to the vascular arcades. Depending on surgeons' preferences, in some cases intraocular Kenalog (Bristol-Myers Squibb, Irvine, CA, USA) or Brilliant blue G (DORC, Zuidland, The Netherlands) was applied over the retinal surface to enhance retinal surface visualization during ILM peeling. At the end of the surgery, partial air-fluid exchange was performed in all cases, and subconjunctival vancomycin and dexamethasone were injected over the sclerotomy sites.

All patients were evaluated at 1, 6 and 12 months after surgery, and potential post-operative complications were recorded at any time point during the follow up period.

### *Statistical analysis.*

Descriptive statistics were first calculated for all variables of interest. Mean and standard deviation values were calculated for continuous variables, while frequency and percentage were calculated for categorical variables. Kruskal-Wallis test was used to compare the statistically significant difference in continuous measurements among all subgroups, Chi-square test was used to compare proportions among the study



1  
2  
3  
4 population. Pearson correlation was used to explore the association among continuous  
5  
6 functional and morphometric variables. The association of SD-OCT parameters with  
7  
8 BCVA was assessed by means of univariate and multivariate linear or logistic regression,  
9  
10 as appropriate. Structural Equation Modeling was used to fit mediation analyses and to  
11  
12 assess whether EIFL affects BCVA directly or only indirectly, i.e. through CFT increase.  
13  
14 Linear mixed models with subjects as random intercept and time as a random slope were  
15  
16 used to investigate predictors of change in BCVA during follow-up. Covariates included  
17  
18 in univariate and multivariate models were baseline BCVA and CFT, and change in CFT  
19  
20 and EIFL thickness from baseline. All analyses were conducted using Stata 14.2 software  
21  
22 (StataCorp, College Station, TX, USA).  
23  
24  
25  
26  
27  
28  
29  
30  
31  
32

## 33 **Results**

34  
35 We reviewed the clinical records of 1135 patients diagnosed with ERMs, of which  
36  
37 1024 were excluded owing to the presence of one or more exclusion criteria. At the end  
38  
39 of the selection process, we enrolled 107 patients (111 eyes), of which 52 were males  
40  
41 (44.4%) and 55 were females (55.6%) with a mean age of  $70 \pm 8.9$  years (range 45-93).  
42  
43 Four out of 107 patients (3.7%) underwent bilateral PPV (figure 2), while combined  
44  
45 phacoemulsification was performed in 13 out of 111 eyes (11.7%).  
46  
47  
48  
49

50 Preoperatively, stage 2 ERMs were diagnosed in 55 out of 111 eyes (49.5%),  
51  
52 stage 3 ERMs were diagnosed in 42 out of 111 eyes (37.9%), and stage 4 ERMs were  
53  
54 diagnosed in 14 out of 111 eyes (12.6%). Stage 1 ERMs were not identified in the study  
55  
56  
57  
58  
59  
60  
61  
62  
63  
64  
65

1  
2  
3  
4 population. Characteristics of the included eyes at presentation are summarized in table  
5  
6  
7 2.

8  
9 Preoperatively, the presence of EIFL was confirmed in 56 out of 111 eyes (50.4%),  
10  
11 in which the mean EIFL thickness was  $191.7 \pm 75.5 \mu\text{m}$  (range 76-420  $\mu\text{m}$ ). However, in  
12  
13 6 out of 14 stage 4 ERMs (42.8%) EIFL thickness measurements were unreliable due to  
14  
15 the remarkable preoperative disruption of the retinal layers, and these eyes were  
16  
17 therefore excluded from preoperative thickness analysis.  
18  
19

20  
21 Preoperatively, differences in BCVA and CFT were significant among the three  
22  
23 ERM stages, as stage 3 and 4 ERMs were characterized by lower BCVA and thicker CFT,  
24  
25 if compared to stage 2 ERMs ( $p < 0.001$ , table 2).  
26  
27

### 28 29 30 31 *Preoperative correlation of BCVA with SD-OCT parameters.*

32  
33 Preoperatively, BCVA was correlated with both CFT ( $r=0.61$ ) and EIFL thickness  
34  
35 ( $r=0.58$ , figure 3, A). However, CFT was strongly correlated with EIFL thickness ( $r=0.69$ ,  
36  
37 figure 3, B), meaning that these variables shared an effect on BCVA. This may be  
38  
39 explained by the fact that the EIFL are an important determinant of increased CFT.  
40  
41

42  
43 Mediation analysis was used to disentangle direct effects of EIFL thickness on  
44  
45 BCVA from any indirect effects mediated by CFT. In this model, the effect of CFT on  
46  
47 BCVA was a decrease of 0.047 logMAR per 100  $\mu\text{m}$  ( $p=0.030$ ), and EIFL thickness  
48  
49 accounted for one half of this reduction (coefficient: 0.502,  $p < 0.001$ ). Moreover, the direct  
50  
51 effect of EIFL on BCVA was a decrease of 0.062 logMAR per 100  $\mu\text{m}$  ( $p < 0.001$ ).  
52  
53 Therefore, the total effect of EIFL thickness on BCVA was a decrease of 0.086 logMAR  
54  
55 per 100  $\mu\text{m}$  ( $p < 0.001$ ).  
56  
57  
58  
59  
60  
61  
62  
63  
64  
65

1  
2  
3  
4 In multiple forward regression analysis of factors including CFT, EIFL thickness,  
5  
6 ellipsoid layer status and presence of CME, only EIFL thickness ( $p<0.001$ ) and the  
7  
8 disruption of the ellipsoid zone ( $p=0.012$ ) were significantly associated with worse  
9  
10 preoperative BCVA.  
11  
12  
13  
14

15  
16 *Postoperative visual outcomes and association with EIFL and other SD-OCT parameters.*  
17

18  
19 In the postoperative period BCVA improved significantly in all ERM subgroups, but  
20  
21 differences between stages 2, 3 and 4 ERMs remained significant ( $p<0.001$ ), as  
22  
23 summarized in table 3 and illustrated in figure 4, A. The preoperative presence of EIFL  
24  
25 was strongly associated with lower postoperative BCVA ( $p<0.001$ ).  
26  
27

28  
29 Postoperative BCVA changes were greatest in the first month after surgery  
30  
31 especially for stage 3 and 4 ERMs, reflecting a ceiling effect. However, in stage 4 ERMs  
32  
33 postoperative improvements in BCVA reached a plateau at six months after surgery, while  
34  
35 in both stages 2 and 3 ERMs BCVA continued to improve until the end of the follow up  
36  
37 period, as illustrated in figure 4, A.  
38  
39

40  
41 Better preoperative BCVA and thicker preoperative CFT were robustly associated  
42  
43 with greater postoperative BCVA improvement in multivariate analyses ( $p<0.001$ ).  
44

45  
46 At 12 months from surgery, EIFL thickness maintained a significant negative  
47  
48 correlation with BCVA ( $r=0.55$ ,  $p<0.001$ ). In a mediation model, the effect of CFT on BCVA  
49  
50 at 12 months was a decrease of 0.055 logMAR per 100  $\mu\text{m}$  ( $p=0.049$ ), and EIFL thickness  
51  
52 accounted for one third of this reduction (coefficient: 0.353,  $p<0.001$ ). At 12 months, the  
53  
54 direct effect of EIFL on BCVA was much stronger and accounted for a decrease of 0.124  
55  
56 logMAR per 100  $\mu\text{m}$  ( $p<0.001$ ).  
57  
58  
59  
60  
61  
62  
63  
64  
65

1  
2  
3  
4 However, neither the preoperative presence of EIFL nor preoperative EIFL  
5 thickness were associated with the postoperative change in BCVA in both univariate and  
6 multivariate regression analysis ( $p>0.100$ ). Moreover, while postoperative CFT reduction  
7 was associated with BCVA improvement ( $p<0.001$ ), the postoperative decrease in EIFL  
8 thickness was not ( $p=0.284$ ).  
9  
10  
11  
12  
13  
14

15  
16  
17  
18  
19 *Postoperative anatomic outcomes and secondary findings.*  
20

21 CFT improved significantly after surgery in all ERM stages ( $p<0.001$ , figure 4, B).  
22 Similarly, EIFL thickness decreased significantly in stage 3 and 4 ERM in the  
23 postoperative period ( $p<0.001$ , figure 4, C).  
24  
25  
26  
27

28 EIFL persisted in the large majority of the cases, being present in 51 out of 56 eyes  
29 with stage 3 and 4 ERMs (91%) at 12 months from surgery, as illustrated in figure 5, A.  
30 Only in 5 out of 56 eyes (9%) the EIFL regressed by the end of the follow up period, as  
31 illustrated in figure 5, B. Preoperative differences in CFT, EIFL thickness and BCVA  
32 between eyes with and without postoperative EIFL regression were not significant.  
33  
34  
35  
36  
37  
38  
39

40 In the postoperative period a shallow, hyperreflective layer of inner retinal tissue  
41 over the foveal region developed in 24 out of 55 stage 2 ERMs (46.1%). The morphology  
42 of this tissue as seen with SD-OCT was similar to the EIFL, but without continuity with the  
43 INL, as illustrated in figure 6. This finding had no effect on post-operative BCVA in  
44 univariate or multivariate models ( $p>0.100$ )  
45  
46  
47  
48  
49  
50  
51

52 At the end of the follow up period, a shallow foveal depression was present in 23  
53 out of 55 eyes with stage 2 ERMs (41.8%), 10 out of 42 eyes with stage 3 ERMs (23.8%)  
54 and only 1 out of 14 eyes with stage 4 ERM (7.1%). These rates were significantly  
55  
56  
57  
58  
59  
60  
61  
62  
63  
64  
65

1  
2  
3  
4 different between the 3 groups ( $p=0.020$ ). The restoration of the foveal depression was  
5  
6 not associated with better postoperative BCVA in univariate or multivariate models  
7  
8  
9 ( $p>0.100$ ).

10  
11 CME resolved in 24 out of 27 eyes (88.9%) after surgery, and persisted until the  
12  
13 end of the follow up in only 3 out of 27 eyes (11.1%).

14  
15 At the end of the follow-up period, the cotton ball sign persisted only in 1 out of 32  
16  
17  
18 eyes (3.1%).

19  
20 No serious intra- or postoperative complications were registered over the follow-  
21  
22 up period. However, the new onset of postoperative CME was recorded in 6 out of 84  
23  
24 eyes (7.1%). The postoperative CME had microcystoid morphology, it was mainly located  
25  
26 in the INL and persisted until the end of the follow up period in 2 out of 84 eyes (2.9%),  
27  
28 despite treatment with topical ketorolac tromethamine (Acular, Parsippany-Troy Hills, NJ,  
29  
30 USA).

31  
32 Finally, 11 out of 53 phakic eyes (20.7%) developed visually significant cataract in  
33  
34 the postoperative period, of which 9 (81.8%) underwent cataract extraction before the  
35  
36 end of the follow up period. The development of visually significant cataract was taken  
37  
38 into account in all the statistical analysis performed.  
39  
40  
41  
42  
43  
44  
45  
46  
47

## 48 **Discussion**

49  
50 The timing of surgery in eyes with idiopathic ERMs can be challenging with poor  
51  
52 consensus even among experienced vitreoretinal surgeons. The evaluation of the  
53  
54 severity of the ERM and the prognosis with surgical removal can be elusive.<sup>19</sup> Therefore,  
55  
56  
57  
58  
59  
60  
61  
62  
63  
64  
65

1  
2  
3  
4 the identification of reliable prognostic biomarkers is critical to improve the ability of  
5  
6  
7 clinicians to predict postoperative outcomes in patients with idiopathic ERMs.  
8

9 This study explored the clinical significance of the EIFL in a cohort of 111 eyes  
10  
11 diagnosed with idiopathic ERMs treated with PPV, ERM and ILM peel, and found a  
12  
13 significant association between the preoperative presence of EIFL and lower preoperative  
14  
15 and postoperative BCVA over a 1-year follow up period.  
16  
17

18 Recently, there has been a greater number of published SD-OCT studies  
19  
20 investigating inner retinal alterations in idiopathic ERMs, and the role of the inner retina  
21  
22 in visual acuity loss has been studied more closely. In fact, increasing evidence suggests  
23  
24 that outer retinal disruption may be insufficient to fully explain vision loss in the setting of  
25  
26 ERM formation.<sup>11-18</sup>  
27  
28

29 In this regard, we described the development of continuous EIFL in a subset of  
30  
31 idiopathic ERMs, and correlated the incidence of this anatomical finding with lower  
32  
33 preoperative BCVA.<sup>19</sup> The present study further supports our previous observations  
34  
35 demonstrating a significant correlation between EIFL thickness and lower BCVA at  
36  
37 presentation. Such results are coherent with the work of Joe et al., who first suggested  
38  
39 that an “abnormal inner retinal thickening” in the foveal region may be a major determinant  
40  
41 of visual acuity in patients with idiopathic ERMs.<sup>11</sup>  
42  
43  
44  
45  
46  
47

48 However, to estimate the direct effect of inner retinal alterations on visual function  
49  
50 may be challenging due to the strong correlation between inner retinal thickness and CFT,  
51  
52 which makes such analysis prone to bias.  
53  
54

55 Previous reports have already described independent associations between inner  
56  
57 retinal thickness and visual acuity in idiopathic ERMs, but inner retinal parameters were  
58  
59  
60  
61  
62  
63  
64  
65

1  
2  
3  
4 often measured using automated software, which may have provided inaccurate layer  
5  
6 segmentation.<sup>15,16,22</sup>  
7  
8

9 In the present study the effect of EIFL thickness on BCVA was separated from that  
10  
11 of CFT with mediation analysis, and remained significant after further multivariate logistic  
12  
13 regression. Such results suggest a negative direct effect of EIFL thickness on BCVA,  
14  
15 independently from CFT and other confounders.  
16  
17

18  
19 EIFL thickness was significantly reduced in the postoperative period. This  
20  
21 reduction was prominent up to 6 months but minimal between 6 and 12 months after  
22  
23 surgery. However, mediation analysis showed no direct effect of postoperative EIFL  
24  
25 thinning on postoperative BCVA changes.  
26  
27

28  
29 This fact raises questions on the mechanisms of EIFL-related vision loss and  
30  
31 limited functional recovery after surgery. In fact, the negative correlation between EIFL  
32  
33 thickness and BCVA at presentation may suggest that the ectopic retinal tissue may act  
34  
35 as a physical barrier which interposes between the afferent light and photoreceptors,  
36  
37 obstructing or degrading the projected visual image on the foveal cones. The extent of  
38  
39 this optical obstruction may be greater with increasing EIFL thickness.  
40  
41

42  
43 However, the presence of inner retinal tissue covering the foveal region does not  
44  
45 fully explain vision loss, as suggested by the good visual function frequently observed in  
46  
47 patients with foveal plana, a congenital condition characterized by the persistence of inner  
48  
49 retinal layers over the central fovea.<sup>23</sup>  
50  
51

52  
53 Therefore, further alterations in retinal microstructures may occur in the presence  
54  
55 of EIFL. The chronic displacement of the inner retina may cause damage and  
56  
57 deformations of photoreceptors and other retinal neural cells, compromising normal  
58  
59  
60  
61  
62  
63  
64  
65

1  
2  
3  
4 neural transmission and contributing to the visual alterations and metamorphopsia in eyes  
5  
6 with ERM.<sup>11,19,24</sup> This fact may be especially relevant in stage 4 ERMs, characterized by  
7  
8 complete foveal disorganization and lower postoperative functional outcomes.  
9

10  
11 The chronic disruption of foveal microanatomy may not be fully reversible after  
12  
13 ERM peel, as illustrated in figure 7. In the present study, the likelihood to restore the  
14  
15 foveal depression at 12 months from surgery decreased progressively at increasing ERM  
16  
17 stage and was rarely encountered in advanced stage 4 ERMs. This result is consistent  
18  
19 with other reports describing poor anatomical restoration after ERM peel, and may be the  
20  
21 reflection of deeper retinal alterations associated with the presence of EIFL.<sup>25</sup>  
22  
23

24  
25 After surgery, the EIFL persisted in the vast majority of eyes diagnosed with stage  
26  
27 3 and 4 ERM, a fact which may explain the lower postoperative anatomical restoration  
28  
29 observed in this subset of patients and the lower visual outcomes.  
30  
31

32  
33 The persistence of EIFL in the absence of traction supports the hypothesis that  
34  
35 other molecular reactions, possibly mediated by Müller cells, may contribute to their  
36  
37 formation, together with the mechanical displacement of inner retinal tissue driven by the  
38  
39 ERM.<sup>19</sup> Müller cell activation may also be responsible for the postoperative formation of  
40  
41 inner retinal bridging tissue over the fovea in a subset of eyes with stage 2 ERMs, which  
42  
43 may represent a reparative reaction after surgery.  
44  
45  
46

47  
48 Finally, the present study explored the prognostic value of our SD-OCT  
49  
50 classification of ERMs, which was a useful and practical tool in the prediction of  
51  
52 postoperative outcomes. In fact, differences in functional and morphometric outcomes  
53  
54 remained significant between the three ERM stages, with stage 2 and 4 ERMs at opposite  
55  
56 ends.  
57  
58  
59  
60  
61  
62  
63  
64  
65



1  
2  
3  
4           Limitations of this study include its retrospective nature, and the lack of high-  
5  
6 density macula raster scanning for all cases. Although high-density SD-OCT imaging was  
7  
8 performed in most of the included eyes, the central fovea may have been missed by the  
9  
10 standard 20 X 15-degree macular raster or the single high-definition horizontal B-scan,  
11  
12 causing the misclassification of some ERMs.  
13

14  
15           Strengths of our study include adequate follow up and good size of the study  
16  
17 population, consistent surgical technique among the three surgeons and the use of SD-  
18  
19 OCT eye tracking systems in all cases, which allowed precise analysis of postoperative  
20  
21 anatomical changes. Although longer follow-up would have increased the strength of this  
22  
23 study, it has been shown that both visual acuity and SD-OCT parameters stabilize at 12  
24  
25 months from surgery, suggesting that a 1-year follow up is adequate to assess  
26  
27 postoperative results.<sup>26</sup>  
28  
29  
30  
31

32  
33           In conclusion, to the best of our knowledge this is the first report investigating the  
34  
35 surgical significance of the EIFL in eyes with idiopathic ERMs. This study reported  
36  
37 significantly lower postoperative visual and anatomical restoration in idiopathic ERMs with  
38  
39 EIFL over a 1-year follow-up period. The thickness of the EIFL had a strong negative  
40  
41 correlation with both preoperative and postoperative BCVA. However, postoperative EIFL  
42  
43 thinning had no direct effect on postoperative BCVA change, suggesting that once EIFL  
44  
45 is established, its change has no independent effect on surgical visual outcome.  
46  
47 Accordingly, EIFL formation may produce irreversible retinal damage, and the presence  
48  
49 of EIFL should be considered a negative prognostic factor for postoperative anatomical  
50  
51 and functional recovery.  
52  
53  
54  
55  
56  
57  
58  
59  
60  
61  
62  
63  
64  
65

1  
2  
3  
4           However, our hypothesis should be the subject of further prospective  
5  
6 investigations, which are necessary to confirm our results, further validate the proposed  
7  
8 ERM staging scheme and reduce the risk of bias. Additional clinicopathological studies  
9  
10 are also needed to better understand the pathophysiology of EIFL development prior to  
11  
12 developing rational preventive and interventional strategies.  
13  
14

15           We hope that our results and proposed ERM classification scheme will stimulate  
16  
17 and encourage the design of future research, which will ultimately improve the  
18  
19 management of these lesions.  
20  
21  
22  
23  
24  
25  
26  
27  
28  
29  
30  
31  
32  
33  
34  
35  
36  
37  
38  
39  
40  
41  
42  
43  
44  
45  
46  
47  
48  
49  
50  
51  
52  
53  
54  
55  
56  
57  
58  
59  
60  
61  
62  
63  
64  
65

## REFERENCES

1. Michalewski J, Michalewska Z, Cisiecki S, Nawrocki J. Morphologically functional correlations of macular pathology connected with epiretinal membrane formation in spectral optical coherence tomography (SOCT). *Graefes Arch Clin Exp Ophthalmol* 2007;245:1623–1631.
2. Asaria R, Garnham L, Gregor ZJ, Sloper JJ. A prospective study of binocular visual function before and after successful surgery to remove a unilateral epiretinal membrane. *Ophthalmology* 2008;115:1930 –1937.
3. Falkner-Radler CI, Glittenberg C, Hagen S, Benesch T, Binder S. Spectral-Domain Optical Coherence Tomography for Monitoring Epiretinal Membrane Surgery. *Ophthalmology* 2010;117:798–805.
4. Dawson SR, Shunmugam M, Williamson TH. Visual acuity outcomes following surgery for idiopathic epiretinal membrane: an analysis of data from 2001 to 2011. *Eye (Lond)* 2014;28: 219–224.
5. Scheerlinck LM1 van der Valk R, van Leeuwen R. Predictive factors for postoperative visual acuity in idiopathic epiretinal membrane: a systematic review. *Acta Ophthalmol.* 2015;93:203-212.

- 1  
2  
3  
4 6. Kim JH, Kim YM, Chung EJ, Lee SY, Koh HJ. Structural and Functional Predictors  
5  
6 of Visual Outcome of Epiretinal Membrane Surgery. *Am J Ophthalmol* 2012;153:103–  
7  
8 110.  
9
- 10  
11  
12  
13  
14 7. Hosoda Y, Ooto S, Hangai M, Oishi A, Yoshimura N. Foveal Photoreceptor  
15  
16 Deformation as a Significant Predictor of Postoperative Visual Outcome in Idiopathic  
17  
18 Epiretinal Membrane Surgery. *Invest Ophthalmol Vis Sci* 2015;56:6387-6393.  
19
- 20  
21  
22  
23 8. Shiono A, Kogo J, Klose G, et al. Photoreceptor Outer Segment Length: A  
24  
25 Prognostic Factor for Idiopathic Epiretinal Membrane Surgery. *Ophthalmology*  
26  
27 2013;120:788–794.  
28  
29
- 30  
31  
32  
33 9. Hashimoto Y, Saito W, Saito M, et al. Retinal outer layer thickness increases after  
34  
35 vitrectomy for epiretinal membrane, and visual improvement positively correlates with  
36  
37 photoreceptor outer segment length. *Graefes Arch Clin Exp Ophthalmol* 2014;252:219–  
38  
39 226.  
40  
41
- 42  
43  
44  
45 10. Rii T, Itoh Y, Inoue M, Hirakata A. Foveal cone outer segment tips line and  
46  
47 disruption artifacts in spectral-domain optical coherence tomographic images of normal  
48  
49 eyes. *Am J Ophthalmol*. 2012; 153(3): 524–529.  
50  
51  
52  
53  
54  
55  
56  
57  
58  
59  
60  
61  
62  
63  
64  
65

- 1  
2  
3  
4 11. Joe SG, Lee KS, Lee JY, et al. Inner retinal layer thickness is the major determinant  
5  
6 of visual acuity in patients with idiopathic epiretinal membrane. *Acta Ophthalmol.*  
7  
8 2013;91:242-243.  
9
- 10  
11  
12  
13  
14 12. Kim JH, Kang SW, Kong MG, Ha HS. Assessment of retinal layers and visual  
15  
16 rehabilitation after epiretinal membrane removal. *Graefes Arch Clin Exp Ophthalmol*  
17  
18 2013; 251:1055–1064.  
19
- 20  
21  
22  
23  
24 13. Okamoto F, Sugiura Y, Okamoto Y, Hiraoka T, Oshika T. Inner nuclear layer  
25  
26 thickness as a prognostic factor for Metamorphopsia after epiretinal Membrane surgery.  
27  
28 *Retina* 2015;35:2107-2114.  
29
- 30  
31  
32  
33  
34 14. Cho KH, Park SJ, Cho JH, Woo SJ, Park KH. Inner-Retinal Irregularity Index  
35  
36 Predicts Postoperative Visual Prognosis in Idiopathic Epiretinal Membrane. *Am J*  
37  
38 *Ophthalmol* 2016;168:139–149.  
39
- 40  
41  
42  
43 15. Lee EK, Yu HG. Ganglion Cell-Inner Plexiform Layer Thickness after Epiretinal  
44  
45 Membrane Surgery A Spectral-Domain Optical Coherence Tomography Study.  
46  
47 *Ophthalmology* 2014;121:1579-1587.  
48
- 49  
50  
51  
52  
53 16. Park SW, Byon IS, Lee JE, Oum BS. Analysis of the ganglion cell layer and  
54  
55 photoreceptor layer using optical coherence tomography after idiopathic epiretinal  
56  
57 membrane surgery. *Graefes Arch Clin Exp Ophthalmol* 2015;253:1829–1830.  
58  
59  
60  
61  
62  
63  
64  
65

- 1  
2  
3  
4  
5  
6  
7 17. Yang SH, Kim JT, Joe SG, Lee JY, Yoon YH. Postoperative restoration of foveal  
8  
9 inner retinal configuration in patients with epiretinal membrane and abnormally thick inner  
10  
11 retina. *Retina* 2015; 35:111–119.  
12  
13
- 14  
15  
16 18. Song SJ, Lee MY, Smiddy WE. Ganglion cell layer thickness and Visual  
17  
18 improvement after epiretinal membrane surgery. *Retina* 2016; 36: 305-310.  
19  
20  
21  
22
- 23 19. Govetto A, Lalane RA 3rd, Sarraf D, Figueroa MS, Hubschman JP. Insights Into  
24  
25 Epiretinal Membranes: Presence of Ectopic Inner Foveal Layers and a New Optical  
26  
27 Coherence Tomography Staging Scheme. *Am J Ophthalmol.* 2017;175:99-113.  
28  
29  
30  
31  
32
- 33 20. Staurenghi G, Sadda S, Chakravarthy U, Spaide RF; International Nomenclature  
34  
35 for Optical Coherence Tomography (IN•OCT) Panel. *Ophthalmology.* 2014;121:1572-  
36  
37 1578.  
38  
39  
40  
41  
42
- 43 21. Tsunoda K, Watanabe K, Akiyama K, Usui T, Noda T. Highly reflective foveal  
44  
45 region in optical coherence tomography in eyes with vitreomacular traction or epiretinal  
46  
47 membrane. *Ophthalmology.* 2012;119:581-587.  
48  
49  
50  
51  
52
- 53 22. Pierro L, Iuliano L, Gagliardi M, et al. Role of ganglion cell complex in visual  
54  
55 recovery following surgical internal limiting membrane peeling. *Graefes Arch Clin Exp*  
56  
57 *Ophthalmol* 2015;253:37–45.  
58  
59  
60  
61  
62  
63  
64  
65

- 1  
2  
3  
4  
5  
6  
7 23. Marmor MF, Choi SS, Zawadzki RJ, Werner JS. Visual Insignificance of the Foveal  
8  
9 Pit Reassessment of Foveal Hypoplasia as Fovea Plana. Arch Ophthalmol.  
10  
11 2008;126:907-13.  
12  
13  
14  
15  
16 24. Romano MR, Cennamo G, Cesarano I, et al. Changes of Tangential Traction after  
17  
18 Macular Peeling: Correlation between en-face Analysis and Macular Sensitivity. Curr Eye  
19  
20 Res. 2017;42:780-788.  
21  
22  
23  
24  
25  
26 25. Mathews NR, Tarima S, Kim DG, Kim JE. Foveal Contour Changes Following  
27  
28 Surgery for Idiopathic Epiretinal Membrane. Invest Ophthalmol Vis Sci. 2014;55:7754–  
29  
30 7760.  
31  
32  
33  
34  
35  
36 26. Kinoshita T, Imaizumi H, Miyamoto H, et al. Two-year results of metamorphopsia,  
37  
38 visual acuity, and optical coherence tomographic parameters after epiretinal membrane  
39  
40 Surgery. Graefes Arch Clin Exp Ophthalmol 2016;254:1041–1049.  
41  
42  
43  
44  
45  
46  
47  
48  
49  
50  
51  
52  
53  
54  
55  
56  
57  
58  
59  
60  
61  
62  
63  
64  
65

## FIGURE CAPTIONS

**Figure 1: Spectral-Domain optical coherence tomography staging scheme of epiretinal membranes.**

**Stage 1.** Mild epiretinal membrane with few anatomical modifications. The foveal depression is preserved, and all retinal layers are well identified. **Stage 2.** Epiretinal membrane with more advanced anatomical changes. The foveal depression is loss, but all retinal layers are still well defined. **Stage 3.** Continuous ectopic inner foveal layers cover the whole foveal floor (white arrows). Like in stage 2 epiretinal membranes, the foveal depression is lost and all retinal layers are well defined. **Stage 4.** Advanced epiretinal membrane with complete foveal disorganization. Thick ectopic inner foveal layers cover the foveal area (white arrows), there is no foveal depression and all retinal layers are disrupted.

**Figure 2: Multimodal imaging of a patient diagnosed with stage 2 epiretinal membrane in one eye and stage 3 epiretinal membrane in the fellow eye.**

**A. Right eye.** Preoperatively, blue reflectance and multicolor imaging show mild wrinkling on the retinal surface from membrane contracture. A Stage 2 epiretinal membrane is diagnosed with spectral-domain optical coherence tomography. The cotton ball sign is visible in the outer retina (white arrow). At 1 month from surgery, the cotton ball sign is reduced, but there is no restoration of foveal microanatomy. At 12 months from surgery, the cotton ball sign is resolved and a shallow foveal depression appears. There is no



1  
2  
3  
4 continuity between parafoveal inner retinal layers. **B. Left eye.** Preoperatively, blue  
5 reflectance and multicolor imaging evidence severe wrinkling of the retinal surface due to  
6 a thick epiretinal membrane. A stage 3 epiretinal membrane is diagnosed with spectral  
7 domain optical coherence tomography due to the presence of continuous ectopic inner  
8 foveal layers in the central fovea (black arrow). At 1 month from surgery, thick ectopic  
9 inner foveal layers persist over the outer nuclear layer. At 12 months from surgery the  
10 ectopic inner foveal layers persist, although significant thinning is observed. There is still  
11 continuity of inner retinal layers over the fovea, and a shallow foveal depression is  
12 present.  
13  
14  
15  
16  
17  
18  
19  
20  
21  
22  
23  
24  
25  
26  
27  
28  
29  
30  
31  
32

**Figure 3: Preoperative correlations between best corrected visual acuity and central foveal thickness with ectopic inner foveal layers thickness.**

33 **A. Best corrected visual acuity.** Preoperatively, there was a strong inverse correlation of  
34 best corrected visual acuity and ectopic inner foveal layers thickness ( $r=0.58$ ). **B. Central**  
35 **foveal thickness.** Preoperatively, there was a robust direct correlation between the  
36 thickness of the ectopic inner foveal layers and central foveal thickness ( $r=0.69$ ).  
37  
38  
39  
40  
41  
42  
43  
44  
45

**Figure 4: Functional and anatomical modifications after surgery.**

46 **A. Best corrected visual acuity.** In all epiretinal membrane stages, best corrected visual  
47 acuity improved in the postoperative period. Higher visual acuity changes from baseline  
48 are observed in epiretinal membranes stages 3 and 4. In stage 4 epiretinal membranes,  
49 best corrected visual acuity tended to stabilize after 6 months from surgery. Best  
50 corrected visual acuity differences between the three epiretinal membrane stages  
51  
52  
53  
54  
55  
56  
57  
58  
59  
60  
61  
62  
63  
64  
65

1  
2  
3  
4 remained significant during the follow-up period ( $p < 0.001$ ). **B. Central foveal thicknes.**  
5  
6 Central foveal thickness decreased significantly in all epiretinal membrane stages, with a  
7  
8 prominent effect in the first month after surgery. Central foveal thickness differences  
9  
10 between epiretinal membranes stages 3 and 4 were minimal after 6 months from surgery.  
11  
12 Central foveal thickness differences between stage 2 versus stages 3 and 4 epiretinal  
13  
14 membranes remained significant over the follow-up period ( $p < 0.001$ ). **C. Ectopic inner**  
15  
16 **foveal layers thickness.** Similarly to central foveal thickness, ectopic inner foveal layers  
17  
18 thickness decreased significantly in all epiretinal membrane stages, with a prominent  
19  
20 effect in the first month after surgery.  
21  
22  
23  
24  
25  
26  
27

28  
29 **Figure 5: Anatomical variations of the ectopic inner foveal layers in the**  
30  
31 **postoperative period.**  
32

33  
34 **A. Persistence of the ectopic inner foveal layers.** In this stage 4 epiretinal membrane,  
35  
36 thick ectopic inner foveal layers are visible at presentation. The cotton ball sign is present.  
37  
38 Over the follow up period, retinal and ectopic inner foveal layers thickness decrease  
39  
40 significantly, but the ectopic inner foveal layers persist up to 12 months after surgery. At  
41  
42 the end of the follow-up period, residual chronic cystoid macular edema and the cotton  
43  
44 ball sign are visible. **B. Regression of the ectopic inner foveal layers.** In this stage 3  
45  
46 epiretinal membrane, thick ectopic inner foveal layers are identified at presentation, as  
47  
48 well as a prominent cotton ball sign in the outer retina, accompanied by a shallow foveolar  
49  
50 detachment. Over the follow up period, the ectopic inner foveal layers progressively  
51  
52 regressed. At 12 months from surgery, the foveal depression is restored and the fovea is  
53  
54 free from ectopic inner foveal layers. The cotton ball sign is no longer visible.  
55  
56  
57  
58  
59  
60  
61  
62  
63  
64  
65

1  
2  
3  
4 **Figure 6: Postoperative anatomical changes in a stage 2 epiretinal membrane.**  
5

6  
7 At presentation, no ectopic inner retinal tissue is observed in this stage 2 epiretinal  
8  
9 membrane. At 1 month from surgery, a thin and hyperreflective bridge of inner retinal  
10  
11 tissue develops over the outer nuclear layer in the absence of traction (white arrows). The  
12  
13 thickness of this tissue increases over the follow up period, while the parafoveal inner  
14  
15 nuclear layer approximates to the foveal center (black arrows). However, differently from  
16  
17 the ectopic inner foveal layers, there is no apparent continuity with the parafoveal inner  
18  
19 nuclear layer.  
20  
21  
22  
23  
24  
25

26 **Figure 7: Preoperative and postoperative changes of foveal morphology.**  
27

28  
29 **A.** At presentation, no epiretinal membrane is present. The foveal depression is wide and  
30  
31 no inner retinal tissue is visible over the foveal center. Signs of mild vitreomacular traction  
32  
33 can be appreciated over the foveal floor. After 21 months, a thick stage 4 epiretinal  
34  
35 membrane has developed. At 1 month from surgery both retinal and ectopic inner foveal  
36  
37 layers thickness significantly decreased. At 12 months, a shallow foveal depression can  
38  
39 be appreciated, although thin ectopic inner foveal layers are still present over the foveal  
40  
41 floor. Note the significant alteration of the foveal anatomy, if compared to baseline. **B.** At  
42  
43 presentation, no epiretinal membrane is present. The foveal depression is appreciable,  
44  
45 although shallow. No inner retina is visible over the foveal floor. After 18 months, a stage  
46  
47 3 epiretinal membrane developed, with thick ectopic inner foveal layers over the fovea,  
48  
49 and the appearance of the cotton ball sign in the outer retina. At 1 month from surgery,  
50  
51 thick ectopic inner foveal layers can still be seen in the central fovea, although retinal  
52  
53 thickness significantly decreased. The cotton ball sign disappeared. At 12 months from  
54  
55  
56  
57  
58  
59  
60  
61  
62  
63  
64  
65

1  
2  
3  
4 surgery, there is no restoration of the foveal microanatomy and the ectopic inner foveal  
5  
6 layers thickness remained grossly unchanged. Note the remarkable differences in the  
7  
8 foveal structure compared to baseline.  
9  
10  
11  
12  
13  
14  
15  
16  
17  
18  
19  
20  
21  
22  
23  
24  
25  
26  
27  
28  
29  
30  
31  
32  
33  
34  
35  
36  
37  
38  
39  
40  
41  
42  
43  
44  
45  
46  
47  
48  
49  
50  
51  
52  
53  
54  
55  
56  
57  
58  
59  
60  
61  
62  
63  
64  
65

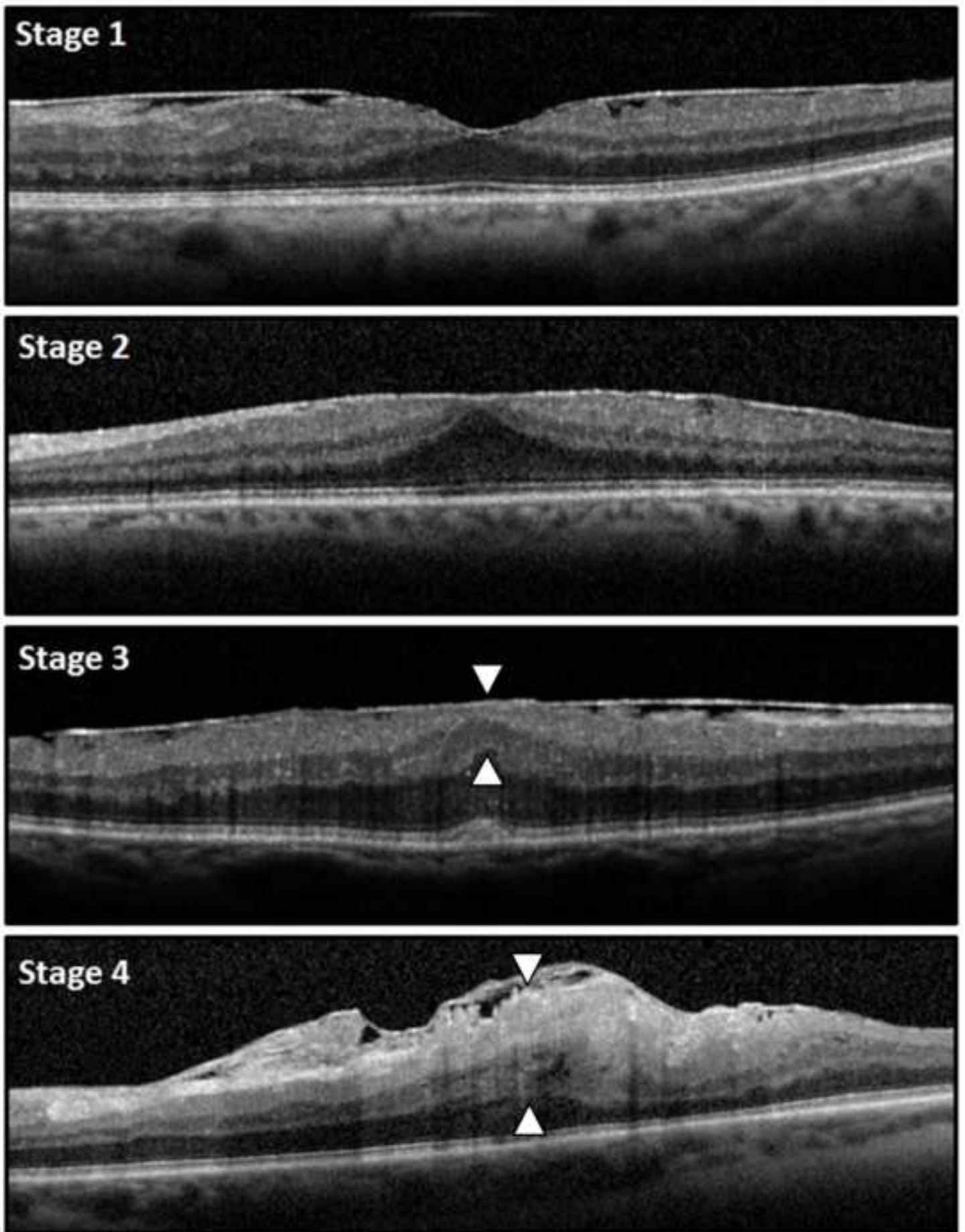
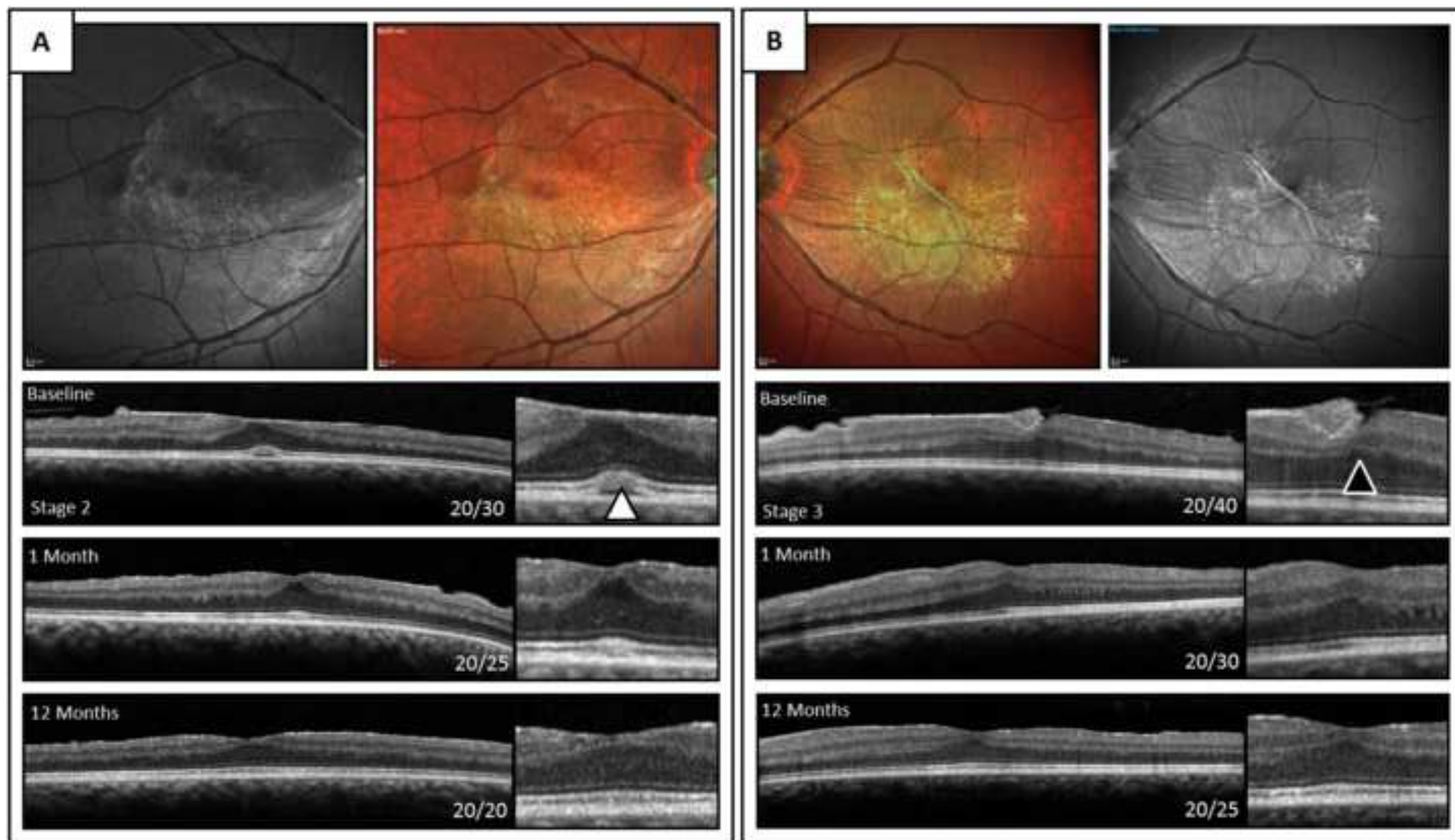
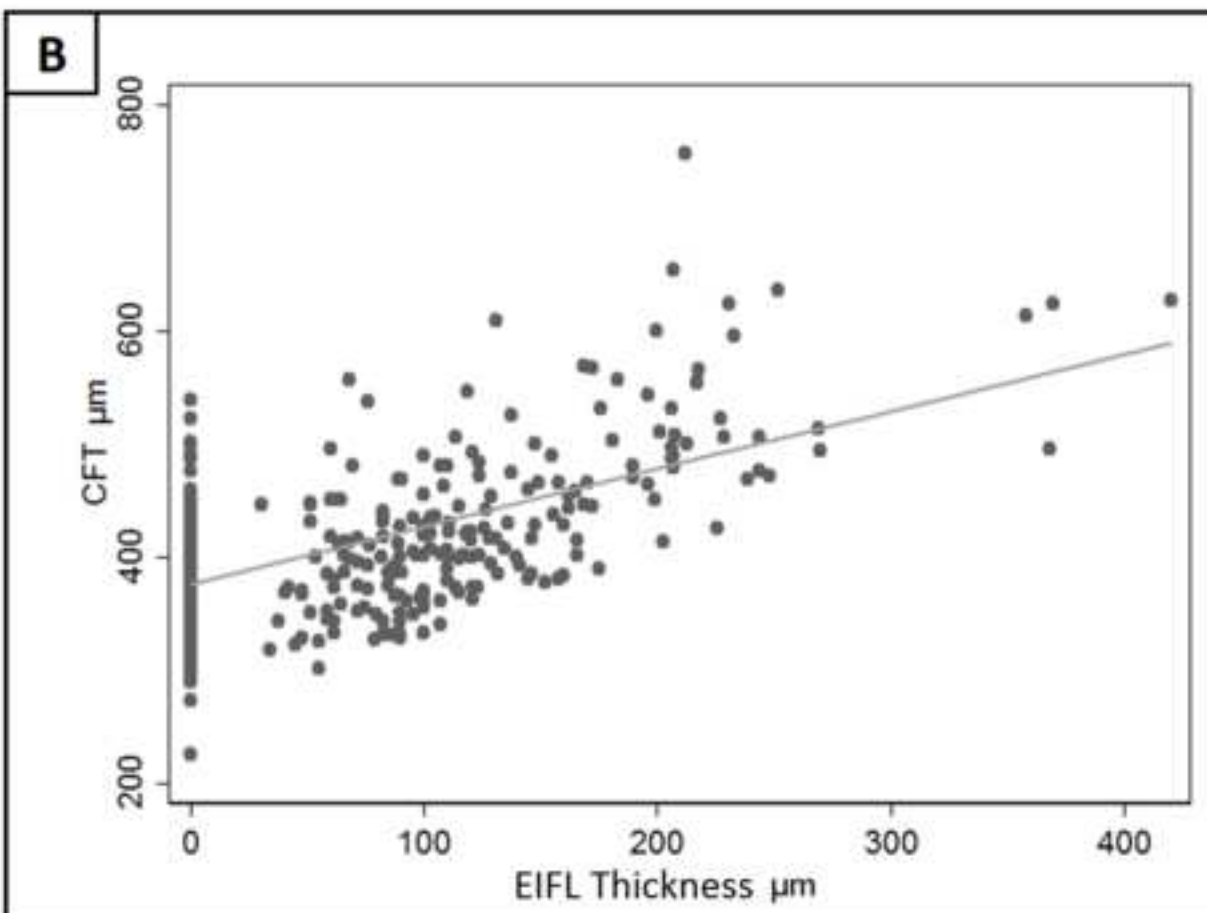
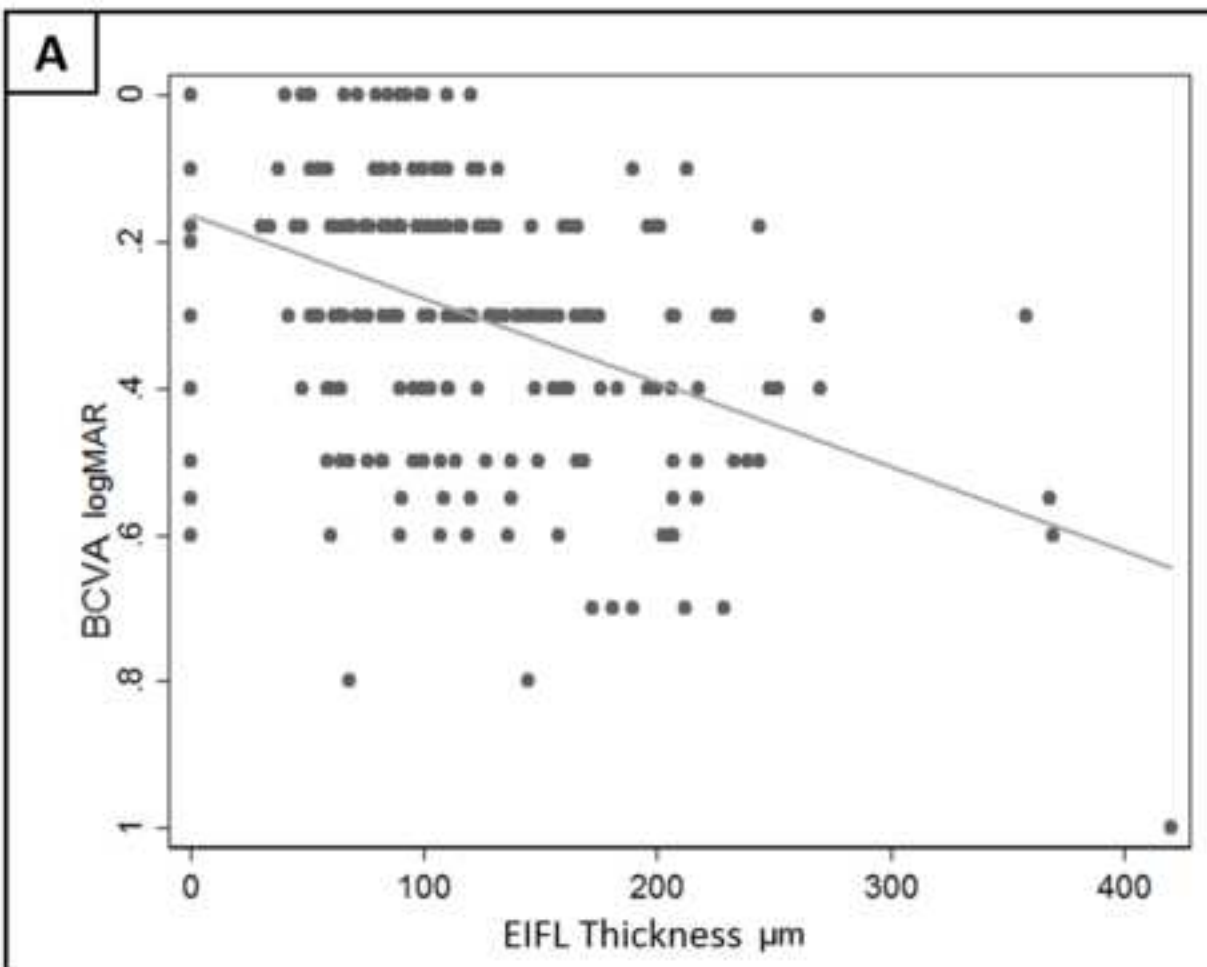


Figure 2





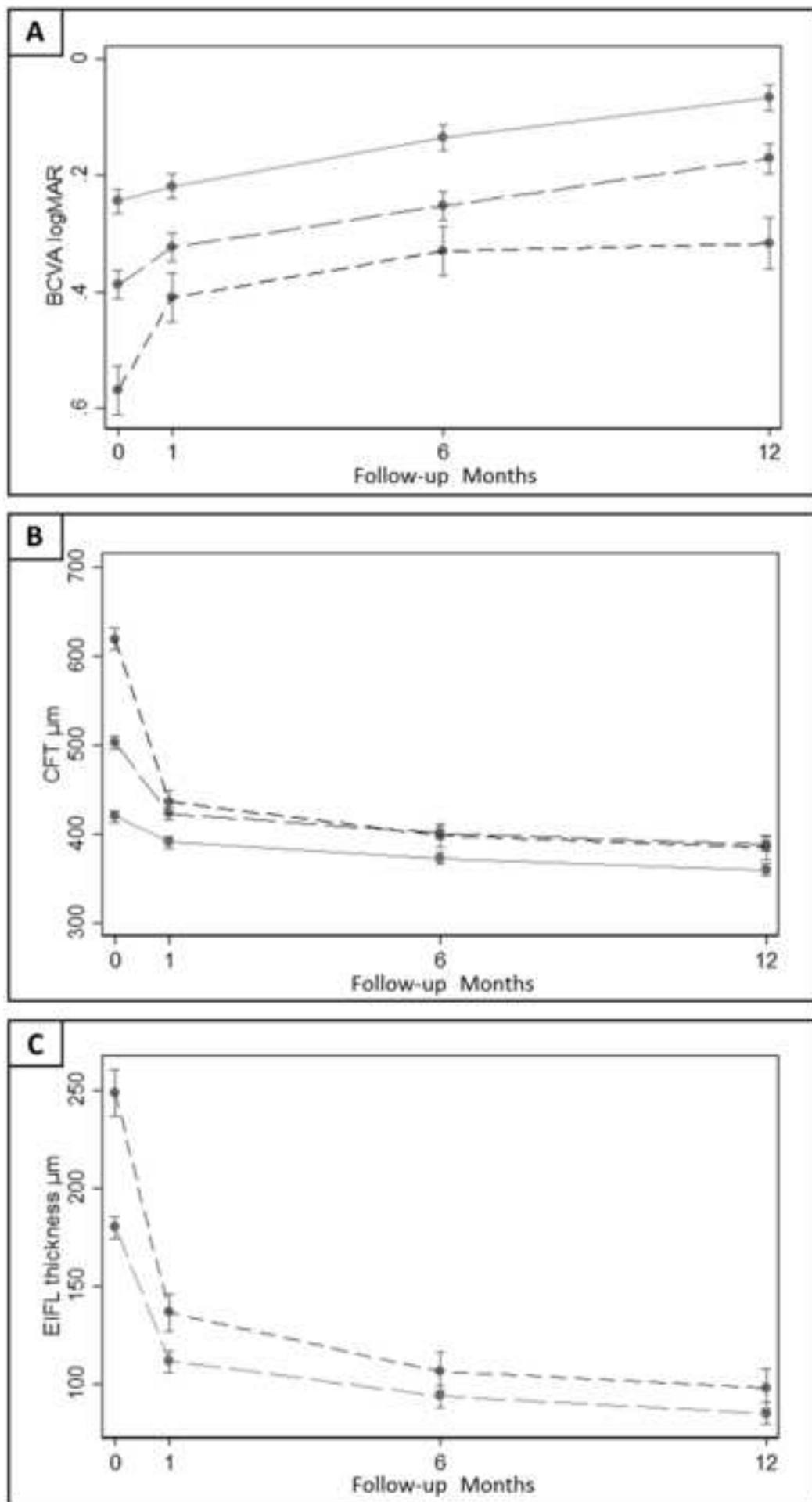




Figure 5

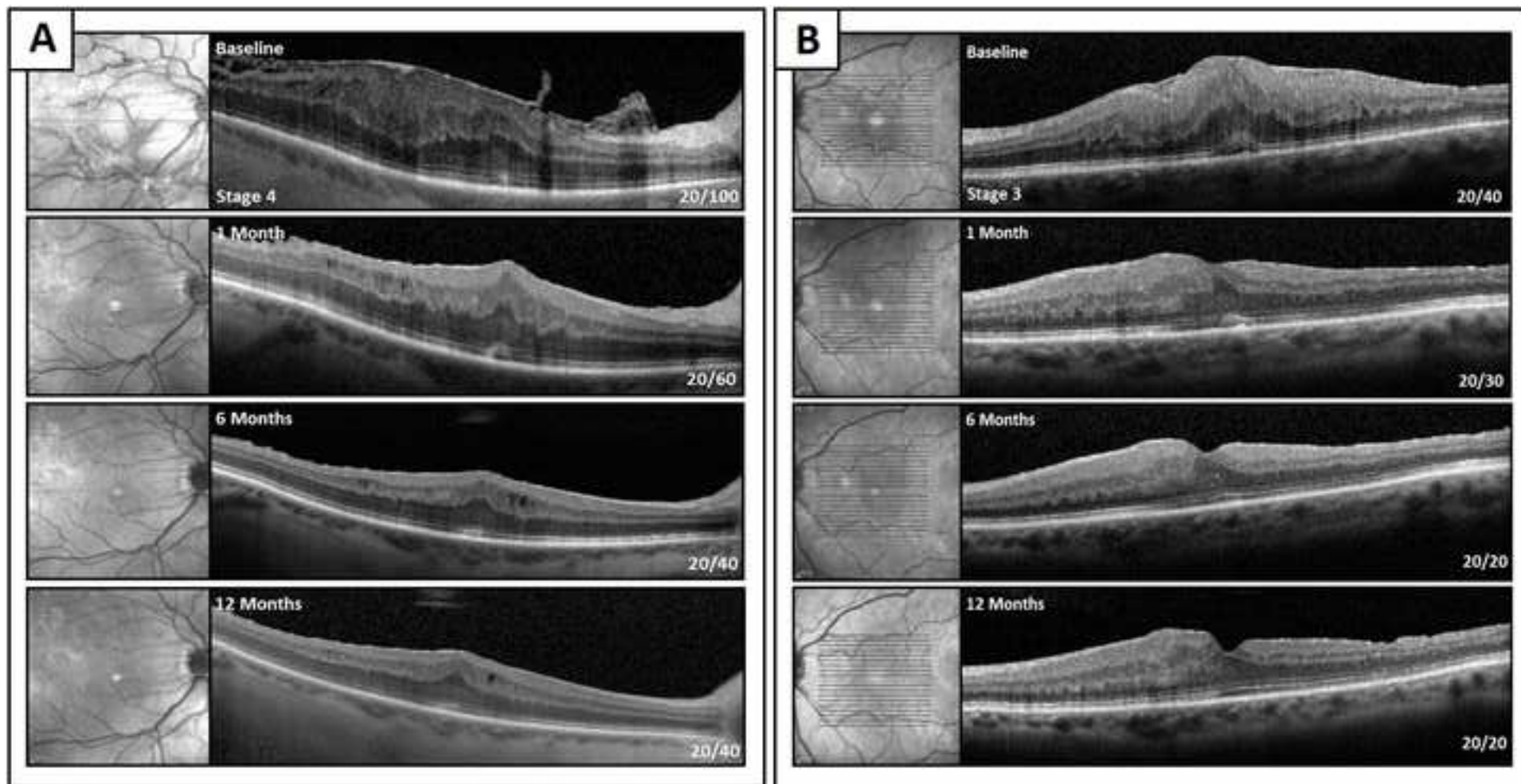
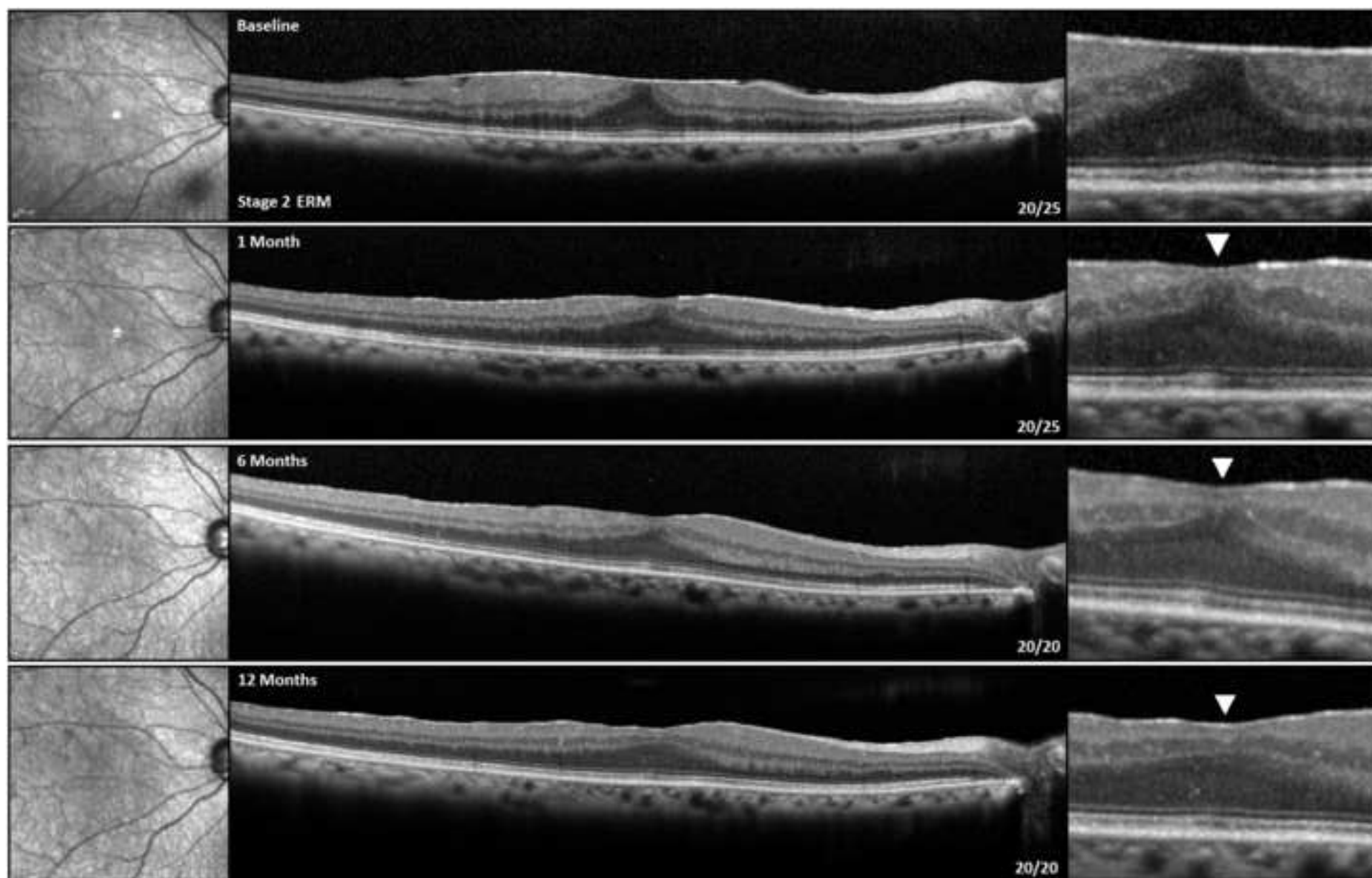
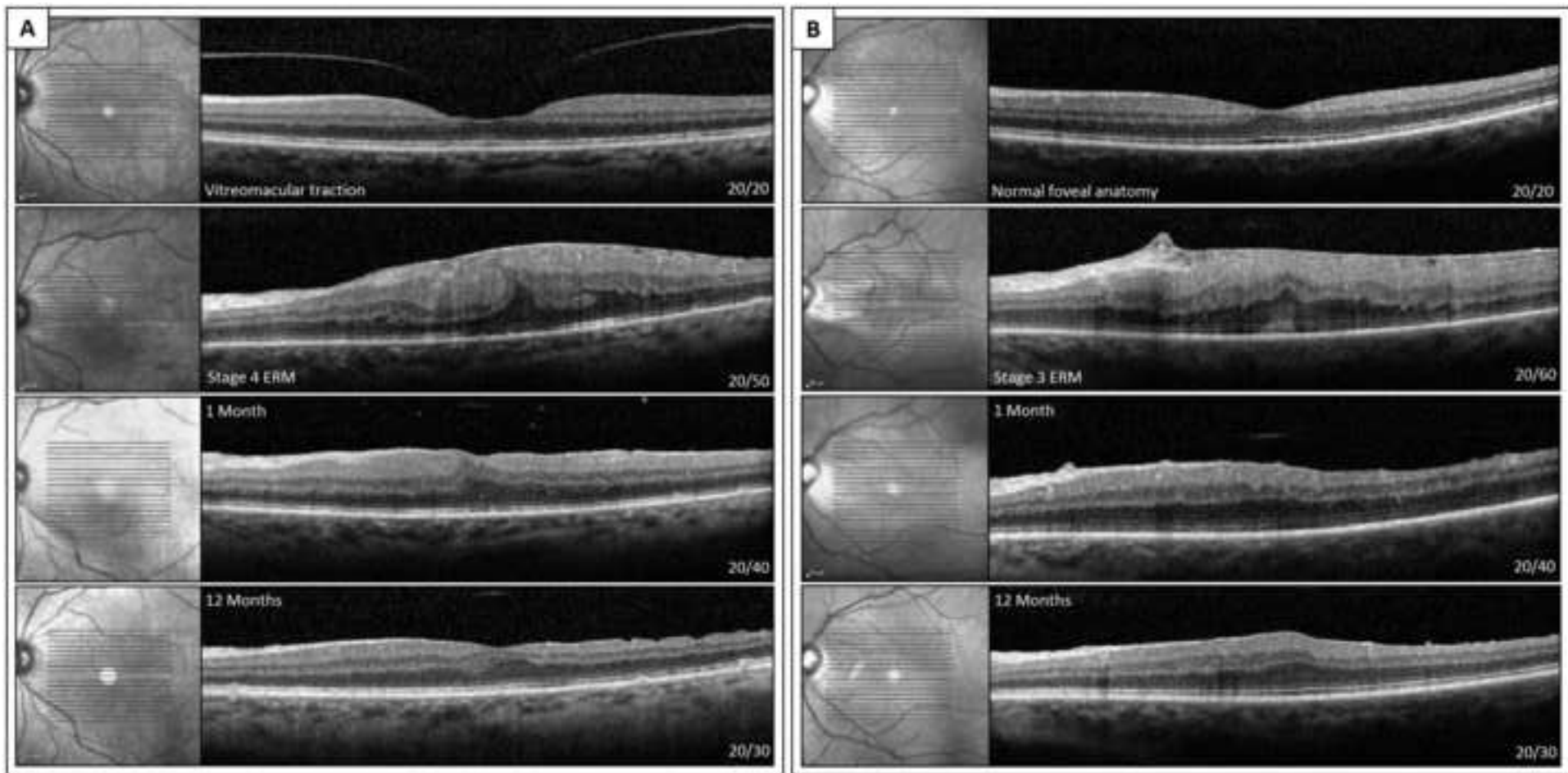


Figure 6





**Table 1. Exclusion Criteria**

<b>Exclusion Criteria</b>	<ul style="list-style-type: none"><li>• Any previous intraocular surgery with the exclusion of uncomplicated phacoemulsification.</li><li>• History of retinal detachment.</li><li>• Intermediate or Advanced Age Related Macular Degeneration.</li><li>• History of Choroidal neovascularization of any etiology.</li><li>• Central Serous Chorioretinopathy.</li><li>• Proliferative Diabetic Retinopathy.</li><li>• Non Proliferative Diabetic Retinopathy with history of clinically significant diabetic macular edema.</li><li>• Macular teleangectasias.</li><li>• Tractional and Degenerative lamellar macular holes.</li><li>• History of central or branch retinal vein occlusion and central or branch retinal artery occlusion.</li><li>• Advanced Glaucoma, or optic neuropathy of any kind.</li><li>• History of inflammatory eye disorders.</li><li>• History of Irvine-Gass syndrome.</li><li>• Visually significant cataract.</li><li>• History of endophthalmitis or any other intraocular infection.</li><li>• Retinal dystrophies.</li><li>• Foveal hypoplasia/Fovea plana</li><li>• History of ocular trauma.</li><li>• Any other potential cause of vision loss other than epiretinal membranes.</li></ul>
-------------------------------	--

**Table 2: Preoperative characteristics of the included eyes.**

ERM	BCVA	CFT	CME	Ellipsoid disruption	Pseudophakia	Cotton ball sign
Stage 2 (n=55)	0.24 ± 0.11 logMAR 20/35 Snellen	419.7 ± 45 µm	14/55 (25.4%)	10/55 (18.1%)	31/55 (56.4%)	21/55 (38.1%)
Stage 3 (n=42)	0.39 ± 0.13 logMAR 20/49 Snellen	501.9 ± 66 µm	6/42 (14.2%)	4/42 (9.5%)	20/42 (47.6%)	10/42 (23.8%)
Stage 4 (n=14)	0.57 ± 0.30 logMAR 20/74 Snellen	619.2 ± 90 µm	7/14 (50%)	6/14 (42.8%)	7/14 (50%)	1/14 (7.4%)
<i>-p value</i>	<0.001*	<0.001*	0.025†	0.019†	0.683†	0.039†

ERM: epiretinal membrane; BCVA; best-corrected visual acuity; CFT; central foveal thickness; CME: cystoid macular edema;

p-value: \*Kruskal-Wallis test; †Chi-square test.

**Table 3: Best corrected visual acuity changes in the postoperative period.**

ERM	Baseline	1 Month	6 Months	12 Months
Stage 2 (n=55)	0.24 ± 0.11 logMAR 20/35 Snellen	0.22 ± 0.14 logMAR 20/33 Snellen	0.13 ± 0.15 logMAR 20/27 Snellen	0.06 ± 0.08 logMAR 20/23 Snellen
Stage 3 (n=42)	0.39 ± 0.13 logMAR 20/49 Snellen	0.32 ± 0.17 logMAR 20/42 Snellen	0.25 ± 0.16 logMAR 20/35 Snellen	0.17 ± 0.14 logMAR 20/30 Snellen
Stage 4 (n=14)	0.57 ± 0.30 logMAR 20/74 Snellen	0.41 ± 0.23 logMAR 20/51 Snellen	0.33 ± 0.26 logMAR 20/43 Snellen	0.31 ± 0.26 logMAR 20/41 Snellen
-p value	<0.001	<0.001	<0.001	<0.001

ERM: epiretinal membrane; p-value: Kruskal-Wallis test.