

UCSF

UC San Francisco Previously Published Works

Title

Diagnostic Momentum in Acute Liver Injury: an Exercise in Clinical Reasoning

Permalink

<https://escholarship.org/uc/item/4g39z9bd>

Journal

Journal of General Internal Medicine, 37(11)

ISSN

0884-8734

Authors

Thomas, Isaiah

Roberts, Andrea

Sharma, Shreyak

et al.

Publication Date

2022-08-01

DOI

10.1007/s11606-022-07673-4

Copyright Information

This work is made available under the terms of a Creative Commons Attribution License, available at <https://creativecommons.org/licenses/by/4.0/>


Peer reviewed



## CLINICAL PRACTICE

*Exercises in Clinical Reasoning*

# Diagnostic Momentum in Acute Liver Injury: an Exercise in Clinical Reasoning

Isaiah Thomas, BA<sup>1</sup>, Andrea Roberts, MD<sup>1</sup>, Shreyak Sharma, MD<sup>1</sup>, John Penner, MD<sup>2</sup>, and Tamar Taddei, MD<sup>1</sup> 

<sup>1</sup>Yale School of Medicine, New Haven, USA; <sup>2</sup>UCSF School of Medicine, San Francisco, USA.

J Gen Intern Med 37(11):2861–5

DOI: 10.1007/s11606-022-07673-4

© This is a U.S. government work and not under copyright protection in the U.S.; foreign copyright protection may apply 2022

**A** 50-year-old male with a history of low back pain presented to his primary care physician with 1 week of worsening back pain. He began taking 4000 to 6000 mg of acetaminophen daily for pain control. His outpatient labs were notable for a creatinine of 2.11 mg/dL (baseline 1.01 mg/dL), aspartate aminotransferase (AST) 100 U/L, alanine aminotransferase (ALT) 170 U/L, alkaline phosphatase 357 U/L, GGT 520 U/L, and total bilirubin 7.2 mg/dL. He was sent to the emergency department where he was found to have normal vital signs, abdominal distension, and bilateral lower extremity edema. No spider angiomas, palmar erythema, or distended paraumbilical veins were noted. His mental status was normal with no asterixis. Repeat labs showed a white blood cell count of 12,800 cells/uL, ALT 196 U/L, AST 140 U/L, alkaline phosphatase 461 U/L, total bilirubin 8.0 mg/dL, direct bilirubin 6.4 mg/dL, albumin 3.3 g/dL, INR 2.34, and creatinine 1.61 mg/dL. His serum acetaminophen level was less than 5 ug/mL. He was started on N-acetylcysteine infusion and admitted overnight by a covering physician and transferred to the hepatology service the next morning with a presumptive diagnosis of acetaminophen overdose.

Based on the history, clinical findings, and diagnostic data, the clinical syndrome is consistent with acute liver injury with ascites and coagulopathy. Because his mental status is at baseline, the patient does not meet the diagnostic criteria for acute liver failure (coagulopathy, transaminase elevation, and encephalopathy in the absence of known liver disease). Although the initial diagnosis for this patient is acetaminophen

toxicity, other etiologies should be considered as his presentation does not completely fit with acetaminophen overdose. Classically, one would expect transaminase elevations greater than 1,000 (even as high as 10,000) and a higher serum acetaminophen level (although these values may be low if the patient is chronically ingesting acetaminophen or is more than 1 day removed from the acute ingestion).<sup>1</sup> The differential for acute liver injury includes infection, alcohol- or drug-induced injury, fatty liver disease, autoimmune hepatitis, genetic conditions, infiltrative disease, malignancy, and vascular injury (e.g., thrombosis, shock). A schema for acute liver injury could include<sup>1</sup> the pattern of transaminase elevation and<sup>2</sup> the degree of elevation (Figure 1). Classically, AST is greater than ALT, usually in a ratio of 2:1, when liver injury is associated with alcohol.<sup>2</sup> For this patient, ALT is greater than AST, making alcohol-related injury less likely.

*The discussant here has identified the patient's clinical syndrome as acute liver injury and compared their illness script for acetaminophen toxicity to the patient's presentation to determine the accuracy of the current working diagnosis. An illness script is a clinician's summary of the key features of a disease.<sup>3</sup> It typically includes the predisposing factors, the pathophysiology of the disease, and the clinical and diagnostic manifestations. In this case, the discussant recognizes that, although the patient demonstrated elevated liver enzymes and an elevated INR in conjunction with increased acetaminophen ingestion, his presentation lacks core features of the illness script for acetaminophen toxicity, such as markedly elevated liver enzymes. When faced with a discordance between the patient's illness script and that of the working diagnosis, one can explore the possibility of an alternative diagnosis, as the discussant does here.*

**His chronic back pain began to progressively worsen about 4 weeks ago, peaking 1 week ago, and he began taking high doses of acetaminophen. The abdominal distension preceded his increased acetaminophen use by about a week. He also reported about 1 week of dyspnea on exertion, lower extremity edema, and early satiety. He reported no fevers, night sweats, or weight loss.**

**Other than chronic low back pain, the patient had no known medical problems. Home medications included as needed acetaminophen, ibuprofen, and cyclobenzaprine. He reported rare alcohol use and no history of heavy alcohol consumption. He did not ingest any supplements,**

---

*John Penner and Tamar Taddei contributed equally to this work.*

---

**Prior presentation:** None

---

*In this series, a clinician extemporaneously discusses the diagnostic approach (regular text) to sequentially presented clinical information (bold). Additional commentary on the diagnostic reasoning process (italics) is integrated throughout the discussion.*

---

Received June 28, 2021

Accepted May 10, 2022

Published online June 8, 2022

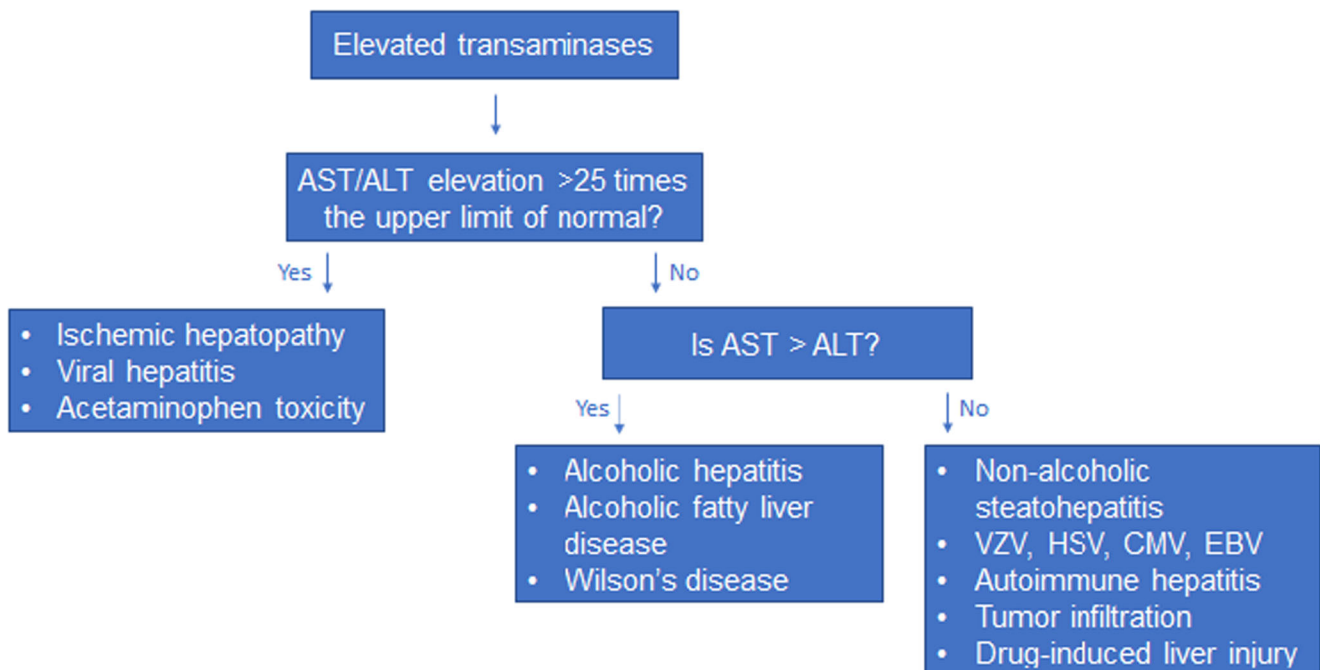


Figure 1 A diagnostic schema for acute liver injury

herbal teas, or unusual foods. The patient's brother and sister were both diagnosed with cancer under the age of 50 (leukemia and lung cancer, respectively).

Acetaminophen toxicity is a common cause of acute liver injury and the most common cause of acute liver failure in the USA.<sup>4</sup> This patient is demonstrating signs and symptoms of acute liver injury and recently took a large amount of acetaminophen, yet the history reveals that some of these symptoms actually appeared before the increased intake. While the patient's history and lab values do not rule out acetaminophen toxicity, they do increase the likelihood that there is a different process at work. A wide range of other medications, both common and less common, have been associated with drug-induced liver injury (DILI), such as amiodarone, ketoconazole, and valproic acid. However, other than acetaminophen, this patient is not on any medications with a known association with the condition. Alcoholic hepatitis should be considered given the lack of distinguishing elements in the history and its high prevalence in the population. However, neither the social history nor the pattern of transaminase elevation suggests alcohol-induced injury.

This history has revealed further discordance between the patient's presentation and the expected presentation of acetaminophen toxicity. This increasing discordance between the patient's illness script and the illness script of the initial working diagnosis triggers the discussant to move even further away from acetaminophen toxicity. In doing so, the discussant breaks away from the diagnostic momentum that can lead a clinician to accept a diagnostic label already applied to a patient without appraising its accuracy.<sup>5</sup> The discussant has also begun to elaborate their diagnostic schema for the new label they have applied to the patient's syndrome, acute liver injury, starting with common etiologies,

such as drug- or alcohol-induced liver injury. This schema will allow them to continue to use historical information, physical exam findings, and diagnostic data to frame the probabilities of other possible etiologies as the case unfolds.

On physical examination, the patient had a heart rate of 112 beats per minute with otherwise normal vital signs. He was well-appearing with scleral icterus. He had an enlarged (approximately 4 cm), hard, non-mobile left supraclavicular lymph node. His cardiac exam demonstrated tachycardia with no abnormal heart sounds. His lungs were clear bilaterally to auscultation. His abdomen was distended and non-tender with shifting dullness. Ecchymoses were apparent on both flanks. He had no distended paraumbilical veins, hepatosplenomegaly, guarding, or rebound tenderness. His lower extremities demonstrated pretibial 2+ pitting edema. No spider angiomas or palmar erythema were noted. He was alert and oriented to person, place, time, and situation with a non-focal neurological exam. No asterix was present.

Additional laboratory values obtained prior to admission are listed in Table 1. Ascitic fluid analysis obtained prior to admission is listed in Table 2. Negative serum tests included viral hepatitis antibody titers (HAV, HBV, and HCV), EBV and CMV antibody titers and PCR, adenovirus PCR, Babesia blood smear, F-Actin IgG, ANA, liver-kidney microsome IgG, mitochondrial antibody, and SLA autoantibody. Alpha-1-antitrypsin level was within normal limits at 183 mg/dL, and ceruloplasmin level was slightly low at 18 mg/dL.

A chest X-ray obtained demonstrated large bilateral pleural effusions with possible loculations on the right (Figure 2). A right upper quadrant ultrasound showed multiple indeterminate lesions in the liver.

**Table 1** Select serum laboratory values

	Lab value	Reference range
Sodium	130 mmol/L	136–144 mmol/L
Hemoglobin	14.4 g/dL	12.0–18.0 g/dL
Platelets	422 ×1000/ μL	140–440 × 1000/μL
Albumin	3.3 g/dL	3.6–4.9 g/dL
PTT	33.0 s	23.9–29.9 s
Pro B-type natriuretic peptide (proBNP)	219.0 pg/mL	<125.0 pg/mL
Ethanol	<10 mg/dL	<10 mg/dL

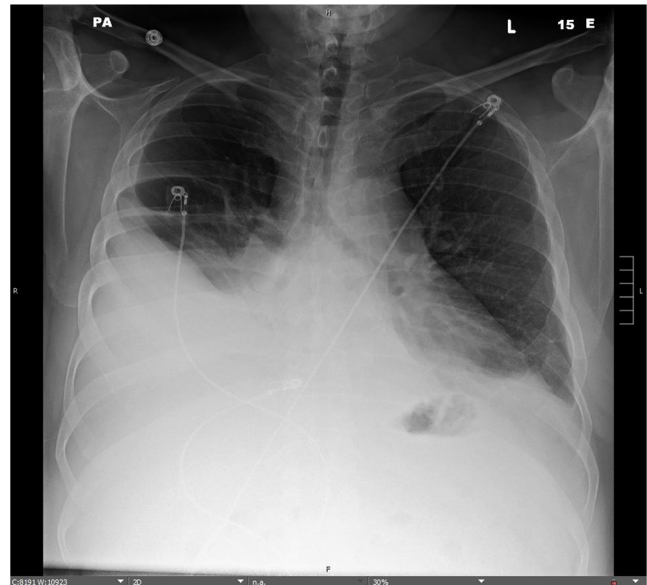
The patient’s diagnostic testing is consistent with mixed hepatocellular and cholestatic liver injury and acute kidney injury. The serum-ascites albumin gradient, or SAAG, is used to help determine whether ascitic fluid is caused by portal hypertension or another cause (Table 3). The SAAG for this patient was 1.0, which suggests that the ascites is unlikely secondary to portal hypertension.<sup>6</sup> Additionally, the ascitic white blood cell count is over 500 cells/mm<sup>3</sup> in about 75% of cases of peritoneal carcinomatosis.<sup>7</sup> The patient’s enlarged left supraclavicular lymph node is highly concerning for gastrointestinal malignancy. Technically, the term “Virchow’s node” refers to any left supraclavicular lymph node, and the “Troisier sign” refers to the enlargement of such a lymph node, but the terms are often used interchangeably to describe the enlarged lymph node. Numerous studies have shown the node to be a potential seeding site for gastrointestinal, pulmonary, prostate, and ovarian cancers, as well as lymphoma.<sup>8</sup>

With this new diagnostic data, a problem representation for this patient’s presentation could be as follows: a 50-year-old male with no history of or risk factors for liver disease presenting with mixed hepatocellular and cholestatic liver injury, low SAAG ascites, an enlarged Virchow’s node, and multiple liver lesions on ultrasound. This presentation is highly suggestive of malignancy. The liver lesions seen on ultrasound could represent multifocal hepatocellular carcinoma (HCC), although HCC is unlikely in a patient with no risk factors. Most likely, they represent metastases from primary cancer of another site, and less likely, they could represent benign simple cysts given the number of them. To further assess for malignancy, imaging of the chest, abdomen, and pelvis should be ordered to search for concerning lesions. Additionally, a thoracentesis could be performed to characterize the pleural effusion, along with a biopsy of the palpable lymph node.

*In this aliquot, the discussant takes a diagnostic timeout (i.e., reviewing the available data and rebuilding a new diagnostic hypothesis) and summarizes the case via a new problem representation. A problem representation can be a useful*

**Table 2** Select diagnostic paracentesis laboratory values

	Lab value
Albumin	2.3 g/dL
Protein	3.7 g/dL
Red cells	5,000 cells/uL
Nucleated cells	1,086 cells/uL



**Figure 2** PA chest X-ray demonstrating bilateral pleural effusions  
*framework for providing a concise and specific illness description. This one-line summary describes who the patient is (demographics and risk factors), the time course of the illness (length of time and progression), and the clinical syndrome (defining signs, symptoms, and diagnostic tests). The clinician can then compare the problem representation against illness scripts for diseases that may fall within their schema for the represented problem.<sup>9</sup> In this case, when the discussant crystallizes this patient’s problem into its most distinctive features, the case activates an illness script for malignancy. The discussant then deploys their diagnostic playbook for potential malignancy, drawing on imaging studies (e.g., cross-sectional imaging of the chest, abdomen, and pelvis), fluid sampling (e.g., thoracentesis), and tissue sampling (e.g., lymph node biopsy) to help confirm the diagnosis.*

**A CT scan of the chest showed diffuse lymphadenopathy, bilateral pleural effusions with pleural nodularity, and a linear area of low attenuation in the superior vena cava, suggesting a thrombus (Figure 3). Ascites, peritoneal nodularity, and an enlarged gastrohepatic node were noted. A thoracentesis was performed: the fluid had an lactate dehydrogenase (LDH) level of 124 U/L, glucose 106 mg/dL, and protein 3.8 g/dL. Serum total protein was 6.0 g/dL and serum LDH was 209 U/L. CT of the abdomen and pelvis demonstrated cecal thickening and several enlarged lymph nodes, including gastrohepatic, periportal, mesenteric, aortocaval, and right external iliac nodes (Fig. 4). The liver demonstrated several hypodensities, some of which were cysts while others were too small to characterize.**

With these findings, malignancy appears to be the definitive etiology for the patient’s symptoms. The pleural fluid meets criteria for an exudative effusion based on the protein level but not the LDH level. However, meeting one of the Light’s criteria is 98% sensitive for exudative pleural effusion.<sup>10</sup> With these findings, the overall picture



**Table 3 Etiologies of high and low serum-ascites albumin gradient (SAAG) values**

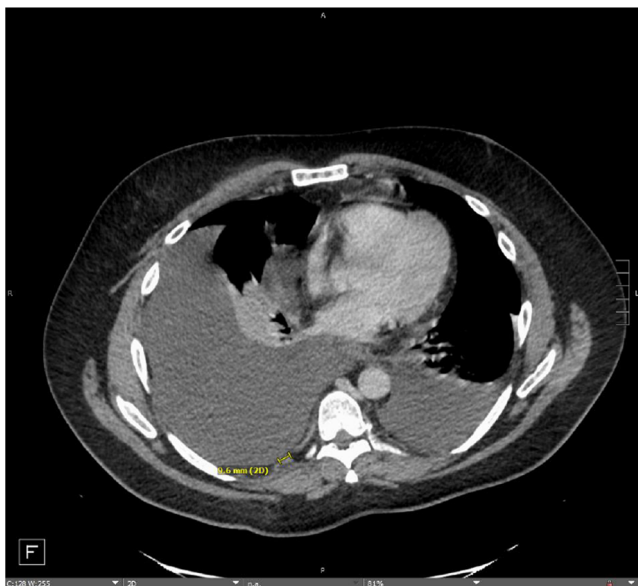	Low SAAG (<1.1 g/dL)	High SAAG (≥1.1 g/dL)
Etiologies	<ul style="list-style-type: none"> <li>- Peritoneal carcinomatosis</li> <li>- Peritoneal tuberculosis</li> <li>- Pancreatitis</li> <li>- Serositis</li> <li>- Nephrotic syndrome</li> </ul>	<ul style="list-style-type: none"> <li>Portal hypertension:               <ul style="list-style-type: none"> <li>- Cirrhosis</li> <li>- Alcoholic hepatitis</li> <li>- Heart failure</li> <li>- Budd-Chiari syndrome</li> <li>- Portal vein thrombosis</li> </ul> </li> </ul>

is most consistent with a malignant process that has impacted the liver via liver metastases or congestive hepatopathy, rather than a disease of hepatic origin.

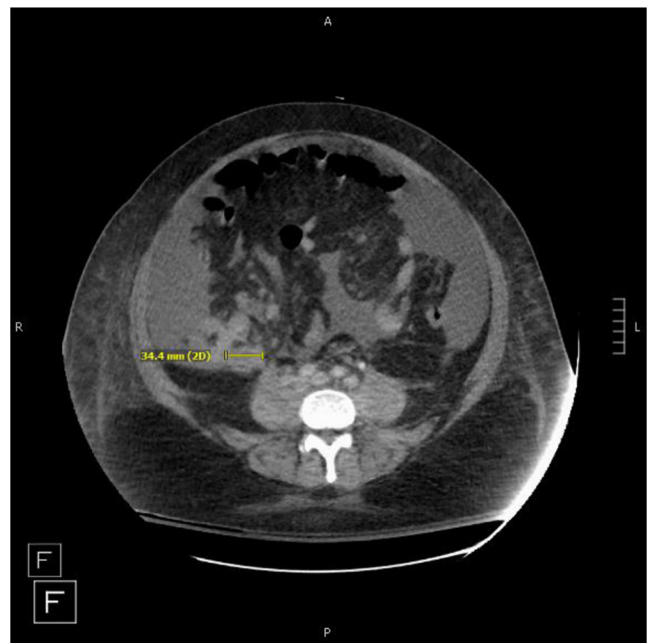
An ultrasound-guided biopsy of the left axillary lymph node demonstrated high-grade tumor cells growing in sheets, with numerous signet ring cells, consistent with an adenocarcinoma. The cytologic profile somewhat favored a primary upper-GI or pancreatobiliary neoplasia. On the ninth day of his hospitalization, the patient went into cardiac arrest and was pronounced dead. On autopsy, the patient's cause of death was reported as mucinous adenocarcinoma of the appendix with signet ring cells with extensive systemic and pulmonary metastases leading to right heart failure. There were metastases to the hilar, periaortic, peripancreatic, iliac, and mesenteric lymph nodes, as well as the omentum, diaphragm, and right upper lobe. The liver demonstrated chronic passive congestion consistent with right heart failure, centrilobular necrosis, multiple simple cysts, and a cavernous hemangioma, with no evidence of hepatocellular carcinoma or metastases to the liver.

## DISCUSSION

Malignancy is an uncommon but important cause of ascites that may be overlooked when evaluating a patient with liver



**Figure 3 Chest CT scan demonstrating right posterior pleural nodule and bilateral effusions**



**Figure 4 Abdominal CT scan demonstrating thickened appendix**

injury and new-onset ascites. In this case, the patient's initial presentation did not activate an illness script for malignancy-related ascites for the evaluating clinicians given the historical data available (e.g., recent increase in acetaminophen use) and higher baseline probability of more common causes (e.g., acetaminophen toxicity). When the patient was admitted to the liver service, there was a risk of carrying forward the incorrect diagnosis and falling prey to diagnostic momentum. Holdover admissions, in which teams admit patients overnight and transfer their care to day teams the following morning, have come to make up a significant portion of inpatient care and put clinicians at particular risk of perpetuating diagnostic momentum. In this clinical climate, providers face the challenge of finding the balance between the desire for efficient and prudent resource allocation and the need for thorough and accurate evaluations. In one qualitative study focusing on holdover admissions, participants identified "diagnostic uncertainty" and anchoring as central issues in the handoff process. Regarding anchoring, one attending physician remarked that "every patient comes prepackaged" due to the previous team communicating their impressions of the patient to the new primary team.<sup>11</sup> While the handoff process, particularly for holdover patients, is often viewed as creating discontinuity in care, this process seems like a natural opportunity for a diagnostic re-evaluation.

Current research is equivocal on the effectiveness of personal strategies to mitigate the risk of cognition-based diagnostic errors, such as awareness of cognitive biases and thinking about how we think (i.e., meta-cognition). One systems-based strategy for increasing diagnostic accuracy may be the use of "diagnostic time-outs," which the discussant deployed in this case, as a standardized step in the holdover admission process to help counter diagnostic momentum. A diagnostic

time-out is a pause in the reasoning process that allows the care team “to reflect on the current working diagnosis and the evidence supporting that diagnosis”; this pause “entails reviewing the data available without framing it with the current diagnosis and re-building a differential diagnosis from the ground up”.<sup>12</sup> The time-out can be an opportunity to ask, “What else could this be?” and then consider the data in favor of and against alternative diagnoses. A more drastic version of this cognitive-forcing strategy is “prospective hindsight,” a technique that looks into the future and assumes that the current working diagnosis is incorrect, forcing the clinician to think of alternatives, particularly worst-case scenarios.<sup>13</sup>

Beyond individual cognitive processes, social settings and dynamics play a significant role in clinical reasoning. In this case, the admission of the patient to the liver service implies that the pathology is primarily hepatic in its origin, which was not the case here. Further, the concept of distributed cognition, which is part of a larger family of social cognitive theories, addresses how clinical reasoning and error are impacted by communication among individuals on larger teams or among multiple teams. As described by Torre et al., “members of the team need to rely on and trust the information reported by each member, yet they must develop opportunities to confirm the accuracy of the information to avoid errors.”<sup>14</sup> Diagnostic time-outs can provide such an opportunity to re-assess and reflect.

During the handoff process, the receiving team’s evaluation of the patient could be viewed as a second opinion, another strategy for decreasing diagnostic momentum, granted that the teams re-assesses the clinical data from the ground up. The presence of attending physicians, advanced practice providers, residents, and students on interprofessional clinical teams can allow for multiple parallel chains of clinical reasoning, with different areas of focus and knowledge. Framing the process as providing a second opinion may help trainees in particular; by normalizing the process of reconsidering an assigned diagnosis, we can help model humility and a growth mindset in clinical decision making.<sup>15</sup>

In this case, the initial working diagnosis easily could have been carried forward and acted upon due to diagnostic momentum, leaving the correct diagnosis undiscovered. A diagnostic time-out provided an opportunity to consider alternative etiologies and allowed the discussant to use a problem representation to recognize that the patient’s presentation fit their illness script for malignancy. By reconsidering the initial diagnosis, re-assessing the clinical data from the ground up, and effectively synthesizing the data, the discussant uncovered the correct diagnosis.

### TEACHING POINTS

1. Signet ring cell adenocarcinoma variants are a rare and histologically aggressive form of colorectal cancer that generally lead to poorer patient outcomes.

2. Supraclavicular lymphadenopathy is associated with a high risk of malignancy and should prompt urgent evaluation. The right supraclavicular lymph system drains primarily from the lungs and mediastinum whereas the left is associated with the hepatobiliary, gastrointestinal, and genitourinary systems.
3. Malignancy, hepatic or otherwise, can cause ascites and acute liver injury and should be considered when other common etiologies (e.g., alcohol, acetaminophen, viral) are absent.
4. Findings associated with malignancy-related ascites include a low serum-ascites albumin gradient value (in contrast to the high SAAG values associated with causes involving portal hypertension), an elevated ascitic white blood cell count, and, in some cases, ascitic fluid cytology findings.

---

**Corresponding Author:** Tamar Taddei, MD; Yale School of Medicine, New Haven, USA (e-mail: tamar.taddei@yale.edu).

### REFERENCES

1. Wong A, Graudins A. Risk prediction of hepatotoxicity in paracetamol poisoning. *Clin Toxicol (Phila)*. 2017;55(8):879-892.
2. Thapa BR, Walia A. Liver function tests and their interpretation. *Indian J Pediatr* 2007;74: 663-71
3. Feltovich PJ, Barrows HS. Issues of generality in medical problem solving. *Tutorials in Problem-Based Learning*. 1984:128-42.
4. Fontana RJ. Acute liver failure including acetaminophen overdose. *Med Clin North Am*. 2008;92(4):761-94, viii.
5. Croskerry P. Achieving quality in clinical decision making: cognitive strategies and detection of bias. *Acad Emerg Med*. 2002;9(11):1184-204.
6. Uddin MS, Hoque MI, Islam MB, Uddin MK, Haq I, Mondol G, Tariquzzaman M. Serum-ascites albumin gradient in differential diagnosis of ascites. *Mymensingh Med J*. 2013;22(4):748-54.
7. Runyon BA, Hoefs JC, Morgan TR. Ascitic fluid analysis in malignancy-related ascites. *Hepatology*. 1988 Sep;8(5):1104-9.
8. Aghedo BO, Kasi A. Virchow Node. *StatPearls [Internet]*. Treasure Island (FL): StatPearls Publishing; 2020
9. Olenik J, Kohlwe J, Manesh RS, Connor DM. Problem representation overview. *Journal of General Internal Medicine*. Available at: <https://www.sgim.org/web-only/clinical-reasoning-exercises/problem-representation-overview>. Accessed 2 Dec 2020.
10. Hassan T, Al-Alawi M, Chotirmall SH, McElvaney NG. Pleural fluid analysis: standstill or a work in progress? *Pulm Med*. 2012;2012:716235.
11. Duong JA, Jensen TP, Morduchowicz S, Mourad M, Harrison JD, Ranji SR. Exploring physician perspectives of residency holdover handoffs: a qualitative study to understand an increasingly important type of handoff. *J Gen Intern Med*.
12. Trowbridge RL. Twelve tips for teaching avoidance of diagnostic errors. *Medical Teacher*. 2008;30(5):496-500
13. Graber ML, Franklin N, Gordon R. Diagnostic error in internal medicine. *Arch Intern Med*. 2005;165(13):1493-9.
14. Torre D, Durning S, Rencic J, Lang V, Holmboe E, Daniel M. Widening the lens on teaching and assessing clinical reasoning: from “in the head” to “out in the world”. *Diagnosis*. 2020;7(3): 181-190.
15. Dweck CS, Yeager DS. Mindsets: a view from two eras. *Perspectives on Psychological Science*. 2019;14(3):481-496.

**Publisher’s Note** Springer Nature remains neutral with regard to jurisdictional claims in published maps and institutional affiliations.