

UCLA

UCLA Previously Published Works

Title

Three-year post-loading results of a randomised, controlled, split-mouth trial comparing implants with different prosthetic interfaces and design in partially posterior edentulous mandibles.

Permalink

<https://escholarship.org/uc/item/4g56v500>

Journal

International journal of oral implantology (Berlin, Germany), 7(1)

ISSN

2631-6420

Authors

Pozzi, Alessandro

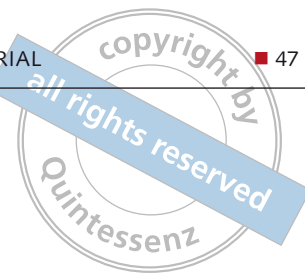
Tallarico, Marco

Moy, Peter K

Publication Date

2014

Peer reviewed



Alessandro Pozzi, Marco Tallarico, Peter K. Moy

Three-year post-loading results of a randomised, controlled, split-mouth trial comparing implants with different prosthetic interfaces and design in partially posterior edentulous mandibles



Alessandro Pozzi, DDS

Researcher, Department of Oral Rehabilitation, Tor Vergata, University of Rome, Italy

Marco Tallarico, DDS

Lecturer, Department of Oral Rehabilitation, Tor Vergata, University of Rome, Italy

Peter K. Moy, DMD

West Coast Oral and Maxillofacial Surgery Center, Nobel Biocare Endowed Chair, Surgical Implant Dentistry, University of California, Los Angeles, USA

Correspondence to:

Alessandro Pozzi
Viale Liegi 44, 00198 Rome, Italy
Tel.: + 39 06 84242567
Fax: + 39 06 84242567
Email: studiopozzi@me.com

Key words bone level, bone loss, dental implants, platform shifting, implant-abutment interface

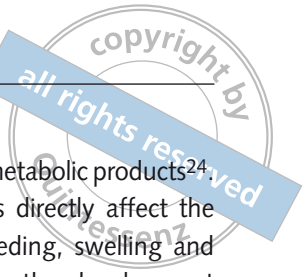Purpose: To compare the clinical and radiological outcomes of two implant designs with different prosthetic interfaces and neck configurations.

Materials and methods: Thirty-four partially edentate patients randomly received at least one NobelActive implant (Nobel Biocare, Göteborg, Sweden) with back-tapered collar, internal conical connection and platform shifting design, and one NobelSpeedy implant (Nobel Biocare) with external hexagon and flat-to-flat implant-abutment interface according to a split-mouth design. Follow-up continued to 3 years post-loading. The primary outcome measures were the success rates of the implants and prostheses, and the occurrence of any surgical and prosthetic complications during the entire follow-up. Secondary outcome measures were: horizontal and vertical peri-implant marginal bone level (MBL) changes, resonance frequency analysis values at implant placement and loading (4 months), sulcus bleeding index (SBI) and plaque score (PS).

Results: No drop-out occurred. No implants and prostheses failures were observed to the 3-year follow-up. MBL changes were statistically significant different with better results for the NobelActive implants for both horizontal and vertical measurements ($P = 0.000$). After 3 years post-loading, the NobelActive implants underwent a mean vertical bone resorption of 0.66 mm, compared with 1.25 mm for the NobelSpeedy Groovy implants ($P = 0.000$); the mean horizontal bone resorption was 0.19 mm for the NobelActive implants and 0.60 mm for the NobelSpeedy Groovy implants ($P = 0.000$). A high ISQ value was found for both implants, and no statistically significant difference was found for ISQ mean values between interventions ($P = 0.941$ at baseline; $P = 0.454$ at implant-abutment connection; $P = 0.120$ at prosthesis delivery). All implants showed good periodontal health at the 3-year-in-function visit, with no significant differences between groups.

Conclusion: The results of this research suggest that in well-maintained patients, the MBL changes could be affected by the different implant design. After 4 months of unloaded healing, as well as after 3 years in function, both implants provided good results, however vertical and horizontal bone loss had statistically significant differences between the two groups (difference of 0.58 ± 0.10 mm for the vertical MBL, and 0.4 ± 0.05 mm for the horizontal MBL), with lower values in the Nobel Active implants, compared to the NobelSpeedy Groovy implants.

Conflict-of-interest statement: *The authors did not receive any materials/products or financial support for this investigation or the writing of the manuscript.*



■ Introduction

Stability of the peri-implant soft tissue and bone contours are prerequisites for a long-term aesthetic and function of implant-supported restoration¹. Nevertheless, dental implants are associated with some peri-implant bone resorption².

Early crestal bone resorption is often observed after the connection of the abutment and delivery of the final prosthesis in two-piece implants. The reformation of biologic width around dental implants has been hypothesised as one of the most likely causes of early implant bone loss³. Implant surface, macrodesign of the implant neck, type of implant/abutment connection, as well as implant placement depth, distance between adjacent implants and distance between the contact point and the alveolar crest, may all contribute to this process^{2,4-7}. Peri-implant crestal bone loss of up to 1.5 mm can occur during the first year of loading, followed by 0.2 mm of bone loss every additional year for two-piece dental implants that are in function⁸. A design strategy including the connection of a smaller-diameter abutment relative to the platform diameter of the titanium implant (referred to as platform shifting) was proven to reduce crestal bone loss^{9,10}.

Initial marginal bone loss has also been attributed to numerous other possible secondary factors, such as periosteal reflection¹¹ and the surgical trauma during implant insertion². In addition, the implant collar design^{2,12}, the implant-abutment connection^{2,13}, the lack of passive fit of the superstructures¹⁴, the occlusal overloading^{12,15,16}, and also the size of the microgap at the implant–abutment interface may contribute to physiological bone remodelling after implant placement^{17,18}. Bacterial colonisation of the gap at the implant–abutment interface has been implicated in this process, influencing the biologic width establishment¹⁹⁻²⁰. For the latter, in most studies, the major part of the marginal bone loss was reported during the first year after implant placement, whereafter, in patients with adequate levels of oral hygiene, the marginal bone levels stabilised over years²¹⁻²³. Regardless of the type of connection (internal versus external), the microleakage at the gap between the implant and the abutment, which is located beneath the gingival margin and at remaining bone level, allows the passage of acids,

enzymes, bacteria and/or their metabolic products²⁴. These bacteria and metabolites directly affect the periodontal tissue, causing bleeding, swelling and odour^{25,26}. Bacteria can trigger the development of inflammation and subsequent bone and implant loss²⁷. Nevertheless, a recent *in vitro* study reported that Morse taper connection implants showed lower levels of microleakage than external connection implants, although the microleakage decreases in the way torque increases²⁸.

The external hexagon connection has been serving well over the years since its introduction. The most commonly used implant design is a threaded cylindrical, turned or with a moderately rough implant surface, with external hexagon implant–abutment connection²¹. However, such connection has some drawbacks due to its limited height and, as a consequence, limited effectiveness when subjected to off-axis loading²⁹. Hence, it has been speculated that, under high occlusal loads, the external hexagon might allow for micromovements of the abutment, thus causing instability of the joint, which may result in abutment screw loosening or even fatigue fracture³⁰. Internal connections have been introduced to lower or eliminate these mechanical complications and reduce the strains transferred to the crestal bone^{15,30-32}. Furthermore, the platform shifting concept, through the use of a smaller abutment diameter, introduces an horizontal inward component to the establishment of the biological width, (that otherwise is a vertical process)¹⁰, contributing in preserving the marginal bone level³³⁻³⁵. Hence, the platform shifting concept results in significantly less radiographically detectable crestal bone loss and better soft tissue support/maintenance in the aesthetic zone^{9,36}.

In January 2010, a multicentre randomised controlled trial of split-mouth design was initiated, aimed at investigating the clinical and radiographic outcome of the new variable-thread implant design with back-tapered neck configuration, conical connection and built-in platform shifting (NobelActive, Nobel Biocare, Göteborg, Sweden), and compared it to a well proven straight neck configuration with flat-to-flat implant-abutment interface and a 0.7-mm-tall external hexagonal connection (NobelSpeedy Groovy, Nobel Biocare), while utilising a conventionally loading protocol³⁷.

An interim 1-year report from this study showed no significant differences regarding survival rates². However, the back-tapered neck configuration with conical connection and built-in platform shifting showed statistically lower marginal bone loss than straight neck configuration with flat-to-flat implant-abutment interface and external-hexagonal connection². This research presents the 3-year outcome from this study. The null hypothesis was that marginal bone remodelling of the new implant-abutment connection would not differ from those of the standard one during function. This null hypothesis was tested against the alternative hypothesis of differences between the study arms. This report was written in accordance with the CONSORT statement (<http://www.consort-statement.org>) for the reporting of randomised controlled trials.

■ Materials and methods

This study was conducted at the Department of Oral Rehabilitation, Tor Vergata, University of Rome, Italy. Any partially edentate patient in the mandible, aged 18 years or over, requiring at least two single implant-supported crowns, able to sign an informed consent form was eligible for this trial. Periapical radiographs were used for initial screening. The inclusion criteria were the following: Kennedy Class I, II, and III in the mandible; teeth extracted at least 6 months before implant placement; and sufficient bone volumes to accommodate dental implants without augmentation procedure (bone height >10 mm and bone width >5 mm).

Patients were not admitted to the study if any of the following exclusion criteria was present: general medical (such as stroke, recent cardiac infarction, severe bleeding disorder, uncontrolled diabetes, or cancer); and/or psychiatric contraindications to implant surgery; pregnancy or nursing; absence of teeth/denture in the opposite jaw; untreated periodontitis; poor oral hygiene and motivation; heavy smoking (more than 10 cigarettes/day); patients who took or were taking bisphosphonates intravenously; an implant insertion torque ≤ 35 Ncm; and patients participating in other trials if the present protocol could not be properly followed. In addition, the minimum distance of an implant to the adjacent

teeth had to be of at least 1.5 mm, and in the case of two or more adjacent implants, at least 3 mm between them.

Eligible patients who met the inclusion criteria were asked to participate and were enrolled between January 2010 and July 2010. A written informed consent was obtained for each patient after detailed explanations of the study protocol. The investigation was conducted according to the principles embodied in the Helsinki Declaration of 1964 for biomedical research involving human subjects, as amended in 2008. According to a prior sample size calculation, 34 patients were recruited and treated in one centre in Rome (Department of Oral Rehabilitation, University of Rome Tor Vergata, Italy) and two experienced surgeons performed all the surgical and prosthetic procedures (17 patients each).

■ Surgical protocol

Patients received professional oral hygiene treatment prior to the surgery and were instructed to use chlorhexidine mouthwash 0.2% (Corsodyl, GlaxoSmithKline, Verona, Italy) for 1 min, twice a day, starting 3 days prior to implant placement and thereafter for 1 week. A single 2 g dose of prophylactic antibiotic (amoxicillin 875 mg and clavulanic acid 125 mg, Augmentin, GlaxoSmithKline, Verona, Italy) was administered 1 h before surgery³⁸. Local anaesthesia was induced using 4% articaine with epinephrine 1:100,000 (Ubistein, 3M ESPE, Milan, Italy). Small flaps were elevated to minimise injury on the periosteum and maintain the blood supply during the healing period.

Two different parallel wall implants were used (Figs 1a and 1b). The NobelActive implant (Nobel Biocare) has a back-tapered collar with in-built platform shifting design, and an internal 12 degrees conical prosthetic interface with a hexagonal interlocking in the bottom. The NobelSpeedy Groovy implant (Nobel Biocare) features a straight neck configuration and a flat-to-flat implant-abutment interface with a 0.7 mm-tall external hexagonal connection. Both implants had a moderately rough, highly crystalline and phosphate-enriched titanium oxide surface (TiUnite, Nobel Biocare). All the implants were placed in the posterior mandible at bone crest level,

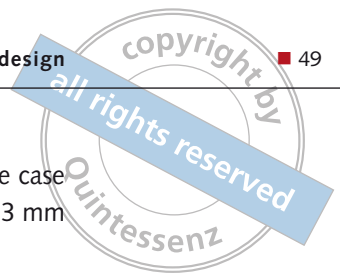
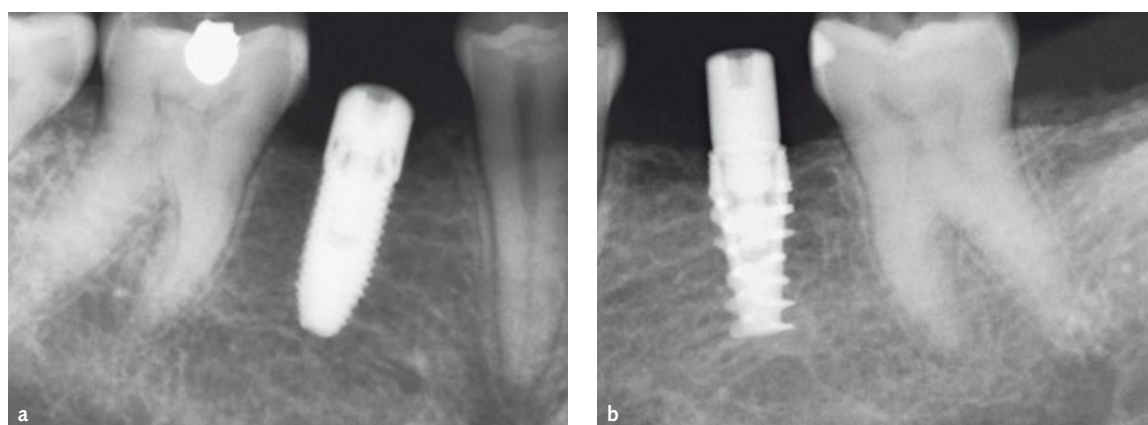


Fig 1 (a) Clinical view of the two investigated implant designs. (b) Characteristics of the two different implant designs and connections used in this study.

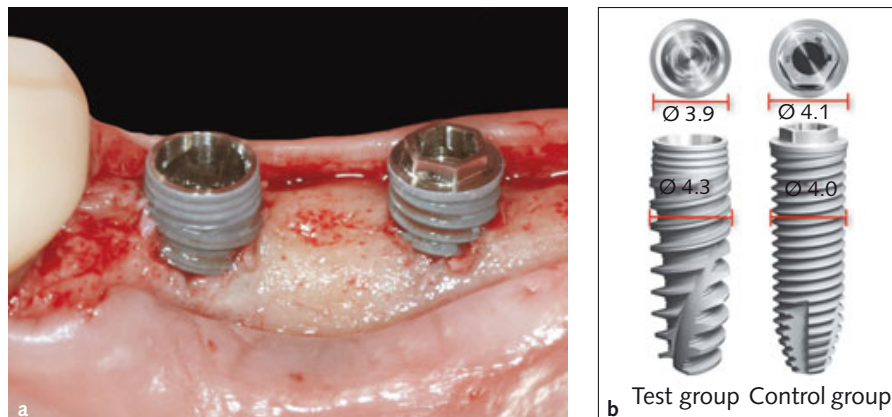

Fig 2 Periapical radiographs at abutment connection in Kennedy Class III patient: (a) a NobelSpeedy Groovy implant (control group); (b) NobelActive implant (test group).



and the drills sequence was chosen according to the manufacturer's instructions in relation to the bone quality (73496 B west 1111 and 23442 ML West 1001). Only regular platform implants were used (NobelActive: 3.9 mm; NobelSpeedy Groovy: 4.1 mm), while the choice of the implant length was left to the surgeon ranging between the following: 8.5, 10, 11.5 and 13 mm). After implant placement, all patients received oral and written recommendations: soft diet for 40 days and soft toothbrush. Moreover, ibuprofen 600 mg was prescribed to be taken every 6 to 8 h if needed and mouth rinsing twice daily for 1 week with a solution of 0.2% chlorhexidine digluconate (Corsodyl, GlaxoSmithKline, Verona, Italy). The implants were exposed 8 weeks after implant placement and healing abutments were connected (Figs 2a and 2b). No implant-supported temporary restoration was used. One week later, the sutures were removed and a preliminary impression was taken. Following this, an open tray impression was taken using a polyether material (Impregum, 3M ESPE, Seefeld, Germany) with a custom open

tray (Diatray Top, Dental Kontor, Stockelsdorf, Germany). Each patient received a single crown per implant. Titanium abutments and metal-ceramic restorations were fabricated by computer-aided design (CAD)/computer-aided manufacturing (CAM) technology (NobelProcera System, NobelBiocare). The abutments were screwed using the Torque Controller (Torq Control, Anthogyr, Sallanches, France) at the 35-Ncm setting. The definitive restorations were delivered 4 months after implant placement, and fixed with a provisional cement (Temp Bond NE, Kerr Corporation, Orange, CA, USA). At the time of prosthesis delivery, occlusion was adjusted. Patients were recalled every 3 months for maintenance and data collection after 1 and 3 years (Figs 3 to 5a and b).

The primary outcome measures were the success rates of the implants and prostheses, and any surgical and prosthetic complications occurred during the entire follow-up. An independent blinded assessor (AV) recorded all of the measurements and gathered the related data, which were statistically analysed for differences between the groups.

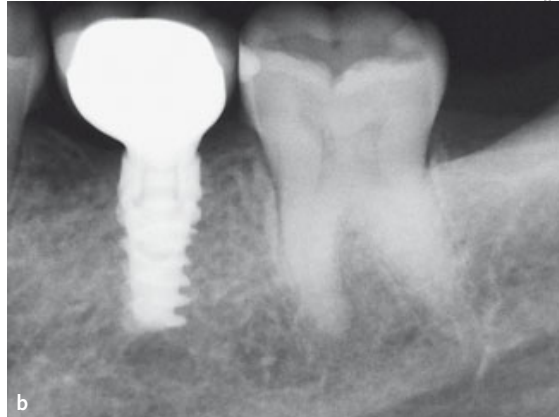
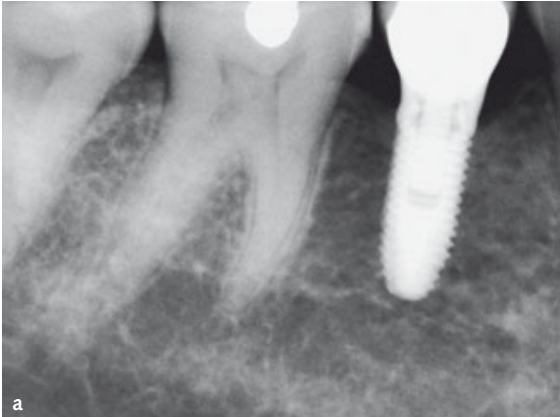



Fig 3 Periapical radiographs after 1 year in function: (a) NobelSpeedy Groovy implant (control group); (b) NobelActive implant (test group).

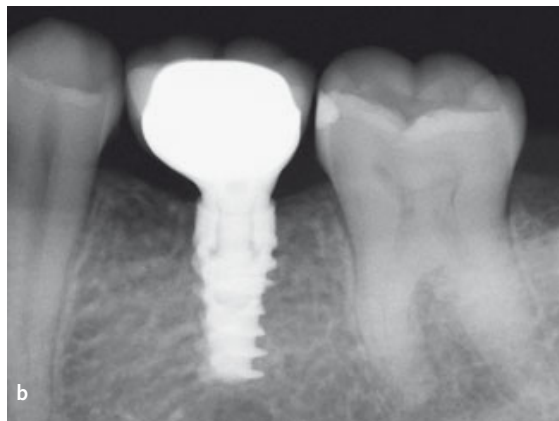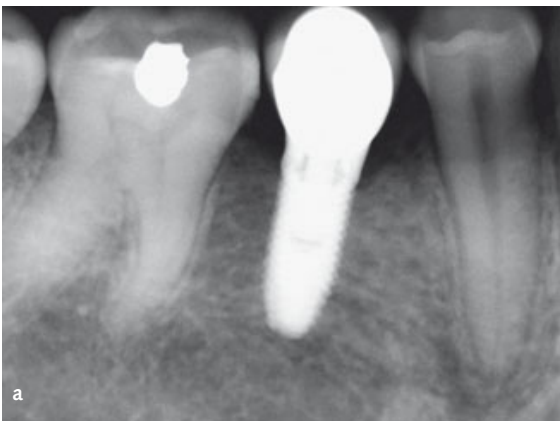


Fig 4 Periapical radiographs after 3 years in function: (a) NobelSpeedy Groovy implant (control group); (b) NobelActive implant (test group).

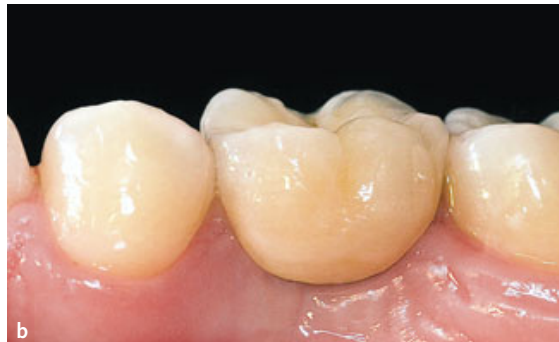
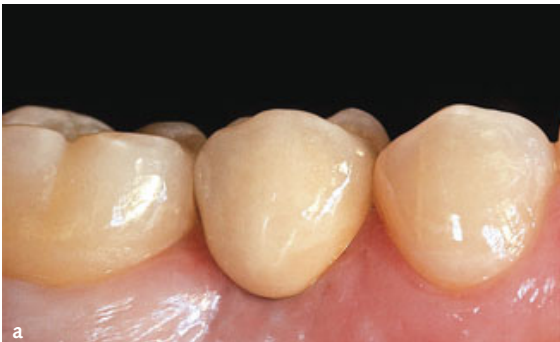
Fig 5 Intraoral photographs after 3 years in function: (a) NobelSpeedy Groovy implant (control group); (b) NobelActive implant (test group).

The criteria were:

- An implant was considered a failure if it presented any mobility, tested by tapping or rocking the implant head with a hand instrument and/or any signs of radiolucency and/or fracture on an intraoral radiograph taken with a paralleling technique strictly perpendicular to the implant-bone interface. The implant stability was assessed at initial loading and after 3 years in function with the prostheses removed.

- A prosthesis was considered a failure if it needed to be replaced by an alternative prosthesis.
- Complications: any biological (pain, swelling, suppuration, etc.) and/or mechanical complication (fracture of the framework and/or the veneering material, screw loosening, etc.) was considered.

Secondary outcome measures were: horizontal and vertical marginal bone level (MBL) changes; reso-




Fig 6 Diagrams showing the measurement locations utilised in this investigation:

VMBL = the distance from the most coronal margin of the implant collar (IC) and the top of the bone crest (BC)

HVBL = the distance from the internal aspect of the socket wall at the level of the alveolar crest (IAC) to the implant surface (I).

nance frequency analysis values at implant placement and loading (4 months); and periodontal parameters, such as sulcus bleeding index (SBI), plaque score (PS) and papilla index.

- MBL changes were assessed using intraoral digital periapical radiographs at the following timepoints: implant placement (baseline); abutment connection (8 weeks); implant loading (4 months); and every year up to 3 years after loading. Intraoral radiographs were taken with the parallel technique by means of a periapical radiographs with customised holder. The radiographs were accepted or rejected for evaluation based on the clarity of the implant threads. All readable radiographs were displayed in an image analysis program (Kodak Digital Imaging Software 6.11.7.0, Eastman Kodak, Rochester, NY, USA) on a 24-inch LCD screen (iMac, Apple, Cupertino, CA, USA) and evaluated under standardised conditions (SO 12646:2004). The software has been calibrated for every single image using the known distance of the implant diameter or length. The distance from the most coronal margin of the implant collar (IC) and the top of the bone crest (BC) was taken as vertical marginal bone level (VMBL). Meanwhile, the distance from the internal aspect of the socket wall at the level of the alveolar crest (IAC) to the implant surface (I) was taken as the horizontal marginal bone level (HMBL) (Fig 6). The average radiographic values of mesial and distal measurements were taken for each implant at the time of implant place-

ment, healing abutment connection (8 weeks), at definitive restoration delivery (4 months) and then at the 1- and 3-years-in-function examination. The difference between the MBLs at various timepoints was taken as bone changes. An independent radiologist performed all the bone measurements (Department of Radiology, University of Rome Tor Vergata, Italy).

- The implant stability quotient was recorded by means of resonance frequency analysis²⁹ at implant placement (baseline), at implant-abutment connection, and at the definitive prosthesis delivery (4 months after implant placement). The Ostell Mentor device (Ostell, Göteborg, Sweden) was used to measure all implants. Two measurements were taken for each implant: one buccopalatal from the buccal side and one mesiodistal from the mesial side. The result was displayed by the device in ISQ units, which range from 1 to 100. The average of these measurements was used. One outcome assessor who was otherwise not involved in the study performed all resonance frequency measurements.
- Soft tissue parameters (SBI and PS) around the implant/abutment interfaces were assessed at the 1- and 3-years examination using a plastic periodontal probe (Plast-o-Probe, Dentsply Maillefer, Ballaigues, Switzerland). The SBI was evaluated at four sites around each implant (mesial, distal, buccal and lingual) according to the Mombelli Index³⁹. The bleeding elicited 20 s after the careful insertion of a periodontal probe 1 mm into the mucosal sulcus, parallel to where the abutment wall was assessed (0 = no bleeding; 1 = spot bleeding, 2 = linear bleeding, and 3 = spontaneous bleeding). The PS, defined as the presence of plaque (yes/no) on the abutment/restoration complex, was measured by running the periodontal probe parallel to the abutment surfaces, and scored at one site for implant. An independent blinded dental hygienist (RI) who was otherwise not involved in the study performed all periodontal measurements.

A descriptive analysis was performed for continuous data such as MBLs, bone levels and ISQ using the mean \pm standard deviation (SD), median and 95% confidence interval (CI) (SPSS for Mac OS X version

22.0; SPSS, Chicago, IL, USA). The patient was used as the statistical unit of the analysis. Comparisons between each timepoints were made for each group by paired *t* test to detect any changes in MBLs during follow-up. Differences of means for continuous outcomes (radiographic bone crest levels and ISQ) between groups were then compared by paired *t* test. Differences in the proportion of patients with early cover screw exposure and bone growth over the cover screw (dichotomous outcome) were compared between the groups using the Fisher's exact probability test. Vertical and horizontal marginal bone loss at the 3-year follow-up was also to be compared between the two surgeons using the one-way analysis of variance. Differences in SBI and PS between implants at 1- and 3-year timepoints were analysed on implant level, using the Mann-Whitney U-tests. A previous independent sample of 34 marginal bone level measurements was calculated with G* Power 3.1.3 for Mac OS X (version 10.7.2); effect size $f^2 = 0.15$, error probability $\alpha = 0.05$ and power = 0.8 ($1-\beta$ error probability). It was decided that the data would be collected 1 year, 3 years and 5 years after loading. For randomisation of the implant type, a pre-generated random sequence was created (Random number generator pro 1.91 for Windows, Segobit Software; www.segobit.com). Opaque envelopes were sealed according to the pre-generated list. An independent consultant prepared all envelopes. Each edentulous site of each patient was randomly assigned to one of two implant groups. Immediately after flap elevation an assistant indicated which implant had to be placed first following the indications contained in the sequentially numbered envelope. When a patient presented a mandible Kennedy Class I and needed to place one implant per side, by convention, it was decided to start from the left side first (Site 1). In addition, when a patient with Kennedy Class I needed to place two or more implants per side, by convention, it was decided to start mesially and to repeat the same procedure proceeding distally. Furthermore, when a patient presented a Kennedy Class II or III, by convention, it was decided to place the implant in the more mesial edentulous region first. Site number 1 of eligible patients was randomised to receive conical connection (NobelActive, Nobel Biocare) or external hexagon (NobelSpeedy Groovy, Nobel Biocare) den-

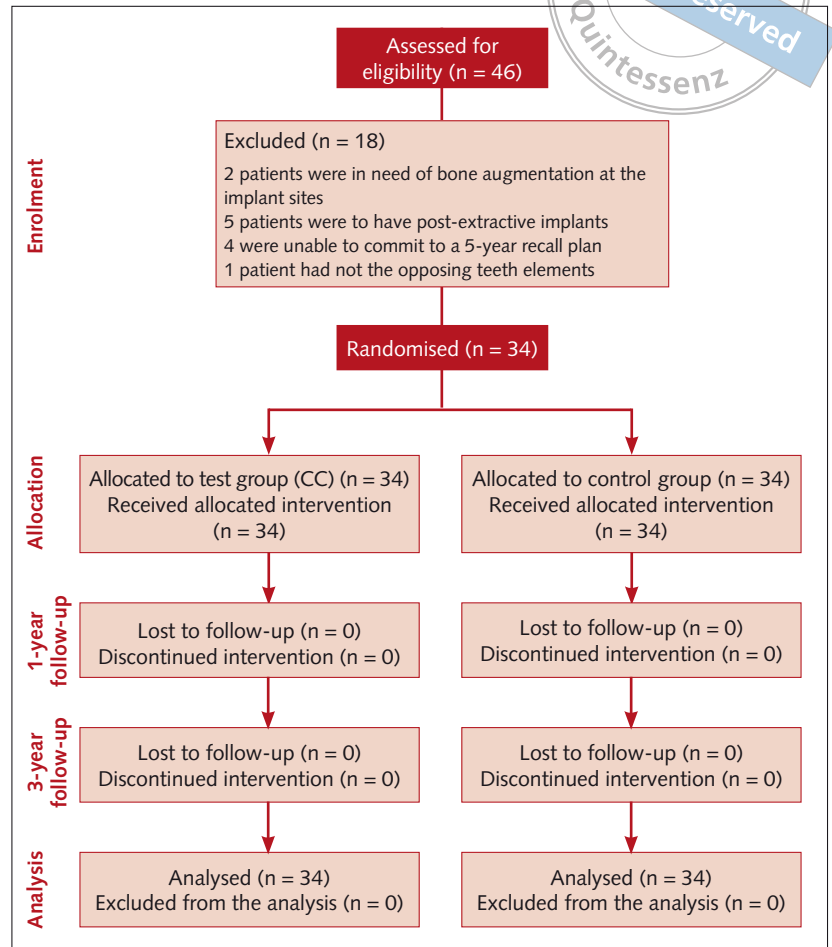


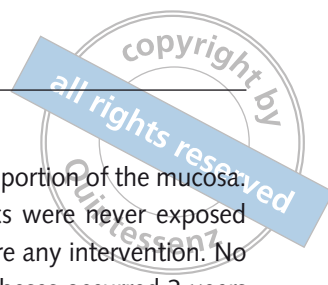Fig 7 CONSORT flow diagram.

tal implants. The internal conical connection (CC) design was the test group; the external hexagon (EH) with flat-to-flat implant-abutment interface was the control group.

Results

A flow diagram of the activities through the phases of the trial is shown in Fig 7.

In total, 46 patients were screened for eligibility in the trial, but 12 were not included for the following reasons: 2 patients were in need of bone augmentation at the implant sites; 5 patients were to have post-extractive implants; 4 were unable to commit to a 5-year recall plan; and 1 had not the opposing teeth elements and the patient was not interested in replacing them. Thirty-four patients were considered eligible and were consecutively enrolled in the study

**Table 1** Patient and intervention characteristics.

Female (n = 19)	19 (56%)
Age 54.2 ± 3.1 (51–59)	
Male (n = 15)	15 (44%)
Age 49.1 ± 5.9 (39–55)	
Total	34
Age 52.2 ± 5.3 (39–59)	
Smokers ≤ 10 cigarettes per day (n = 4)	4 (11.8)
Age 50.7 ± 2.6 (48–53)	
NobelActive implants	34
Sites receiving regular platform implants	34 (100%)
Sites receiving 10 mm-long implants	18 (53%)
Sites receiving 11.5 mm-long implants	16 (47%)
NobelSpeedy Groovy implants	34
Sites receiving regular platform implants	34 (100%)
Sites receiving 10 mm-long implants	18 (53%)
Sites receiving 11.5 mm-long implants	16 (47%)

between January 2010 and June 2010. The mean age was 52.20 ± 5.34 years (a range of 39 to 59 years). A total of 88 implants were placed in the posterior mandible, according to the split-mouth study design (44 implants with conical connection design and 44 external hexagon implant-abutment complex). Fifty-two implants were placed in the molar and 36 implants were placed in the premolar area. All implants were 10 to 13 mm long, depending on the bone height available, and with a regular platform (RP) diameter (3.9 mm for the NobelActive implants and 4.1 mm for the NobelSpeedy Groovy implants, Fig 1b). The last follow-up was done at September 2013. Thirty out of 34 patients were non-smokers, while four patients were light smokers (≤ 10 cigarettes/day). The main baseline patient and intervention characteristics are presented in Table 1.

No drop-outs occurred during the entire follow-up. All the data collected were included in the statistical analysis. No deviation from the original protocol occurred and all the patients were treated according to the allocated interventions. No implants were lost in any group, at the 3-year follow-up examination. In the healing phase, four out of 44 external hexagon implants showed a minimal exposure of the cover

screw, limited to the occlusal portion of the mucosa. In these cases, implant necks were never exposed and did, therefore, not require any intervention. No failure of the definitive prostheses occurred 3 years after implant loading.

Three NobelActive implants showed bone growth over the cover screw and the implant platform during the second-stage surgery, which had been carved off by means of a bendable Micro Blade (American Dental System, Vaterstetten, Germany), without jeopardising the bone around the implant. There were no statistically significant differences between groups (3/17 versus 0/17; $P = 0.114$) Two NobelSpeedy Groovy implants showed a spontaneous early exposure of the cover screw and no surgical intervention was performed to seal off the exposed cover screws. There were no statistically significant differences between groups (2/17 versus 0/17; $P = 0.242$) The patient was asked to clean the cover screw by cotton rolls immersed in 0.2% chlorhexidine three times a day until the second-stage surgery (8 weeks post-surgery). Three years after loading, one patient experienced a peri-implant mucositis around an external hexagon implant, which included pain and bleeding on probing without suppuration, and no evidence of radiographic loss of bone beyond the physiological bone remodelling. After the crown and abutment were removed, the abutment and the crowns were cleaned in an ultrasonic bath with a solution of 0.3% chlorhexidine gluconate for 10 mins at 40°C, and immediately replaced onto the implant. Furthermore, oral hygiene instructions were reinforced and the patient used super-floss with 1% of chlorhexidine gel (GlaxoSmithKline SpA, Verona, Italy) three times a day for 1 week. The soft tissue recovery was assessed in the recall appointment scheduled after 15 days.

The NobelActive implants showed statistically better radiographic results than the NobelSpeedy Groovy implants during the entire investigated period, with statistically significant difference for both vertical and horizontal MBL changes. The results of mean vertical MBLs between implant placement and 3 years after loading at each timepoints are summarised in Table 2a. All the data from both groups showed a gradual loss of a slight amount of vertical peri-implant bone. After 3 years of loading, the NobelActive implants lost a mean of vertical MBL of

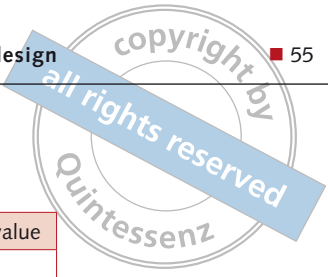


Table 2 (a) Mean radiographic vertical marginal bone levels (mm) between groups and time periods.

		NobelActive n = 34	NobelSpeedy Groovy n = 34	P value
Implant placement (Baseline)	Mean (SD)	0.16 (0.28)	0.05 (0.30)	
	Median	0.10	0.05	
	95% CI	0.07–0.25	-0.05–0.15	
Abutment connection (8 weeks)	Mean (SD)	0.13 (0.30)	0.34 (0.28)*	0.011
	Median	0.18	0.40	
	95% CI	0.03–0.23	0.25–0.43	
Prostheses delivery (4 months)	Mean (SD)	0.54 (0.28)*	0.99 (0.38)*	0.000
	Median	0.40	0.85	
	95% CI	0.45–0.63	0.86–1.12	
After 1 year in function (16 months)	Mean (SD)	0.68 (0.34)*	1.15 (0.34)*	
	Median	0.53	1.08	
	95% CI	0.57–0.79	1.04–1.26	
After 3 year in function (40 months)	Mean (SD)	0.83 (0.27)**	1.29 (0.42)**	0.000
	Median	0.77	1.2	
	95% CI	0.74–0.92	1.15–1.43	

Table 2 (b) Comparison of mean vertical marginal bone loss (mm) with time.

	Baseline to 8 weeks (Submerged healing)	8 to 16 weeks (Non-submerged healing)	Baseline to 16 weeks (Unloaded period)	16 weeks to 3 years in function (36 months) (Loaded period)	After 3 years in function (40-months) Entire follow-up
	Mean (SD)	Mean (SD)	Mean (SD)	Mean (SD)	Mean (SD)
NobelActive n = 34	-0.03 (0.34)	0.40 (0.38)	0.37 (0.23)	0.28 (0.39)	0.67 (0.39)
NobelSpeedy Groovy n = 34	0.29 (0.38)	0.65 (0.40)	0.95 (0.56)	0.30 (0.57)	1.24 (0.47)
P value	0.000	0.000	0.000	0.832	0.000

* Changes from baseline were statistically significantly different ($P < 0.05$).

† Changes from 1 year after loading were no statistically significantly different ($P > 0.05$).

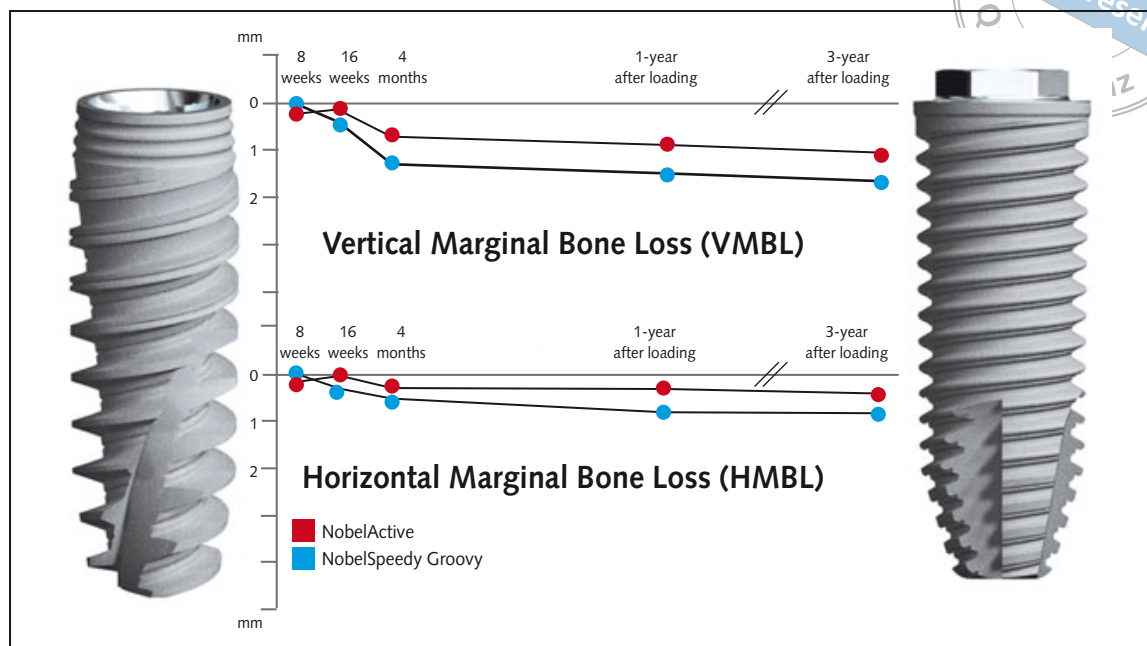
0.67 ± 0.39 mm (median 0.13 mm; 95% CI: 0.07 to 0.19 mm) compared with 1.24 ± 0.47 mm (median 1.25 mm; 95% CI: 1.09 to 1.41 mm) for the NobelSpeedy Groovy implants; the difference between groups was statistically significant ($P = 0.000$). The results of mean vertical MBL between implant placement and 3 years after loading at each timepoints are summarised in Table 2b and Fig 8.

The results of mean horizontal MBLs between implant placement and 3 years after loading at each timepoints are summarised in Table 3a. The mean horizontal bone loss was 0.20 ± 0.21 mm (median

0.30 mm; 95% CI: 0.23 to 0.37 mm) for the NobelActive implants and 0.60 ± 0.20 mm (median 0.57 mm; 95% CI: 0.50 to 0.64 mm) for the NobelSpeedy Groovy implants; once again, the difference between groups was statistically significant ($P = 0.000$). The results of mean horizontal MBL between implant placement and 3 years after loading at each timepoints are summarised in Table 3b and Fig 8.

The comparison between the two surgeons showed no statistically significant differences for both vertical ($P = 0.851$) and horizontal ($P = 0.918$) MBL at the 3-year follow-up.

Fig 8 Graph showing the vertical and horizontal marginal bone loss from implant insertion to 3-year follow-up of all implants



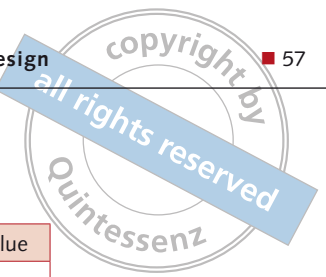
ISQ values were analysed to compare test and control group during healing. A high ISQ value was found in both groups at each timepoint. ISQ mean values at baseline were 78.49 ± 2.35 for the Nobel Active implants and 78.53 ± 2.72 for the NobelSpeedy Groovy implants; at prostheses delivery were 81.50 ± 1.91 for the Nobel Active implants and 82.38 ± 2.37 for the NobelSpeedy Groovy implants, with no statistically significant differences between the two groups ($P = 0.120$). A statistically significant difference for ISQ mean values was observed between baseline and prostheses delivery in each group, with higher values at prostheses delivery ($P = 0.000$).

At the 1-year-in-function visits, bleeding on probing was not detected around any implant in both groups ($P = 1.00$), and only one patient showed a very slight amount of plaque around two implants (one per group), with no significant differences ($P = 1.00$) between the groups. Again, at the 3-year-in-function visits, the mean SBI ($P = 0.558$) and PS ($P = 0.317$) showed no significant differences ($P > 0.05$) between the groups. SBI was found around 1 NobelSpeedy Groovy implant, while PS was recorded around 3 implants (2 NobelActive Groovy implants and 1 NobelSpeedy Groovy implants) in two patients.

■ Discussion

The present, randomised, controlled trial was aimed at comparing two implant types with different prosthetic interface (internal versus external connections), neck configuration and other macrodesign features. This randomised controlled trial (RCT) revealed statistically significant differences both in vertical and horizontal marginal bone loss between the two investigated implants, with lower values for Nobel Active implants (test group). Therefore, the null hypothesis that radiological outcomes of a back-tapered collar with in-built platform shifting and conical prosthetic interface would not differ from those of a straight implant neck configuration with an external flat-to-flat implant-abutment interface was rejected in favour of the alternative hypothesis.

The main limitation of the current trial was the recruitment of Kennedy Class III patients. Thus, the results may be generalised only to the posterior mandibles. Furthermore, the two tested implants were different for the implant platform diameter (3.9 mm the NobelActive and 4.1 mm the NobelSpeedy Groovy). However, the same drilling protocol was used. Thus, it is possible to hypothesise that such limitation of 0.2 mm, intrinsic in the macrodesign of the implants, might not have interfered with the

**Table 3** (a) Mean radiographic horizontal marginal bone levels (mm) between groups and time periods. .

		NobelActive n = 34	NobelSpeedy Groovy n = 34	P value
Implant placement (Baseline)	Mean (SD)	0.12 (0.08)	0.03 (0.05)	
	Median	0.10	0.00	
	95% CI	0.07–0.23	-0.02– 0.12	
Abutment connection (8 weeks)	Mean (SD)	0.08 (0.08)‡	0.26 (0.16)‡	0.000
	Median	0.10	0.20	
	95% CI	0.07–0.13	0.14–0.26	
Prostheses delivery (4 months)	Mean (SD)	0.23 (0.14)‡	0.44 (0.22)‡	0.000
	Median	0.20	0.50	
	95% CI	0.15–0.25	0.43–0.57	
After 1 year in function (16 months)	Mean (SD)	0.28 (0.13)‡	0.62 (0.21)‡	
	Median	0.35	0.50	
	95% CI	0.31–0.39	0.43–0.57	
After 3 year in function (40 months)	Mean (SD)	0.32 (0.21)‡	0.63 (0.18)	0.000
	Median	0.45	0.55	
	95% CI	0.38–0.52	0.49–0.61	

Table 3 (b) Comparison of mean horizontal marginal bone loss (mm) with time

	Baseline to 8 weeks (Submerged healing)	8 to 16 weeks (Non-submerged healing)	Baseline to 16 weeks (Unloaded period)	16 weeks to 3 years in function (36 months) (Loaded period)	After 3 years in function (40 months) Entire follow-up
	Mean (SD)	Mean (SD)	Mean (SD)	Mean (SD)	Mean (SD)
NobelActive n = 34	-0.03 (0.34)	0.40 (0.38)	0.37 (0.23)	0.28 (0.39)	0.67 (0.39)
NobelSpeedy Groovy n = 34	0.29 (0.38)	0.65 (0.40)	0.95 (0.56)	0.30 (0.57)	1.24 (0.47)
P value	0.000	0.000	0.000	0.832	0.000

‡ Changes from 1 year after loading were no statistically significantly different ($P > 0.05$).

results, enabling conclusions to be drawn regarding bone loss differences. In this study, the possible influence of the patient biotype and/or lifestyle on the outcomes could be ruled out due to the split-mouth design⁴⁰. Furthermore, in order to reduce bias, all the implants were placed at the bone crest level with the same drilling protocol and restored with the same type of CAD/CAM cemented retained single crown restorations. In order to compare the two different implant types, the choice of the implant system was

randomised and patients were treated by the same surgical and prosthetic team. Moreover, in order to discern the amount of bone resorption due to the surgical trauma, the biological width establishment and the function, all interventions were performed according to a split mouth protocol design with MBLs recorded at the implant placement, at the healing abutment connection, at the delivery of the definitive prosthesis and at 1- and 3-year-in-function follow-up.

The results of this RCT reported that NobelActive implants showed statistically better radiological results than the NobelSpeedy Groovy implants during the entire investigated period, with statistically significant differences for both vertical and horizontal MBL changes. Both groups gradually lost a slight amount of vertical peri-implant bone. After 3 years of loading, the NobelActive implants had a mean of vertical MBL of 0.67 compared with 1.24 for the NobelSpeedy Groovy implants; the difference between groups was statistically significant ($P = 0.000$). The mean horizontal bone loss was 0.20 for the conical connection implants and 0.60 for the conventional external hexagon ones; once again, the difference between groups was statistically significant ($P = 0.000$). Despite both implants provided good results in terms of bone remodelling during the loaded period (from 4 months to 40 months follow-ups), it is important to realise that both groups exhibited an early amount of bone loss that could be related to the establishment of a biologic seal all around the implant-abutment complex. Such resorption has been referred primarily to the implant exposure into the oral environment, regardless of whether the abutment was connected at the time of implant placement or after completing the initial submerged healing^{2,41}. In the present study, the statistical analysis performed to compare the mean MBL changes between healing abutment connection and definitive prosthesis delivery found significantly lower bone loss around NobelActive implants ($P = 0.002$), with a mean reduction of 0.25 mm. This more favourable bone resorption pattern at this timepoint may be the result of the platform shifting design on the biological width establishment. According to the last review by Schmidt et al⁴², the mean values of the biologic width ranged from 2.15 to 2.30 mm, however, large variances were observed (range: 0.2 to 6.73 mm). The establishment of an implant biological width (IBW) is a multifactorial concept in which the biology is merged with the biomechanics of the connection and loading, that affect horizontally and vertically the bone resorption pattern around the implant. This important natural phenomenon acts as a barrier to the invasion of bacteria and debris⁴³, and has been theoretically linked to the bone remodelling⁴⁴. The management of such bone resorption could be an important fac-

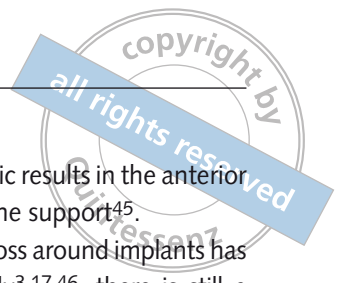tor in achieving good aesthetic results in the anterior maxilla and in optimising bone support⁴⁵.


Although marginal bone loss around implants has been documented extensively^{3,17,46}, there is still a lack of scientific evidence explaining the mechanisms concerning marginal bone loss around implants with different connections and neck configurations³⁵. Nevertheless, most of the studies evaluating crestal bone loss around dental implants focused on differences in implant design, especially with respect to the implant-abutment junction level (crestally versus subcrestally) and surgical approach (submerged versus non-submerged). The NobelSpeedy Groovy implant, due to its external hexagonal flat-to-flat connection system, may allow repetitive micromovements between the parts during clinical function⁴⁷, as well as accumulation of bacteria at its microgap, leading to localised inflammation and crestal bone loss⁴⁸. Koo et al¹³ found a crestal bone resorption significantly greater for the external connection compared to the internal one. The mean linear bone change from implant placement to 1 year after loading was 0.90 mm (SD 0.53 mm) and 0.00 mm (SD 0.28 mm) for the external and internal implant connection technology, respectively. Although, the results obtained suggest that crestal bone loss during the first year of function is more apparent in the external connections, there was no statistically significant difference in the survival rate for both implants^{2,13,49}.

Furthermore, crestal bone remodelling can be reduced through the use of an implant with a back-tapered collar instead of a straight or conical ones, by reducing the outward pressure on the marginal bone after implant placement³².

Implants restored according to a platform shifting concept seem to have a positive effect on peri-implant marginal bone preservation, showing less crestal bone loss than implants restored with a standard protocol⁹. Thus, platform shifting implants, using a conical implant-abutment connection, provides better results in terms of abutment fit, stability, and seal performance⁵⁰.

In the present study, the statistical analysis performed to compare the mean MBL changes between healing abutment connection and definitive prosthesis delivery found significantly lower bone loss around CC implants ($P = 0.002$), with a mean reduction of 0.25 mm. The statistically more favourable





bone resorption pattern at this timepoint may be the result of the platform shifting design on the biological width establishment.


Although a direct correlation between spontaneous cover screw exposure and early crestal bone loss has been reported⁵¹, in our study, the Fisher's exact test ($P = 0.114$) revealed no differences between groups in the number of patients that experienced spontaneous early cover screw exposure as well as bone growth over the cover screw. The statistical analysis performed to compare mean MBL changes between implant placement and healing abutment connection found significantly lower bone loss around NobelActive implants ($P = 0.000$), with a mean reduction in bone loss of 0.32 mm. A possible explanation of the lower MBL changes around NobelActive implants during the submerged period may be the different neck configurations. The back-tapered implant-neck design (4.3 mm body diameter and 3.9 mm platform diameter) of the NobelActive implants might have minimised the surgical injury on crestal bone allowing for maximum bone volume around the implant neck and reduction of bone strain at the same time. On the other hand, the NobelSpeedy Groovy implants with a straight neck configuration (4.0-mm diameter body and a 4.1-mm platform) may have exerted more strain on the surrounding crestal bone, potentially leading to a higher bone resorption.

After the initial bone loss (implant placement-prosthetic delivery), the bone level of both implant designs changed at about 0.1 mm per year. This result has been described for two-piece implants, where the initial bone loss occurred at the 1-year follow-up, was followed up by about 0.1 mm to 0.2 mm of crestal bone loss annually^{22,52}. However, the reduced marginal bone loss experienced with the NobelActive implants during the entire healing period allows for statistically significant differences at the 3-year follow-up examination ($P = 0.000$). Nevertheless, further long-term randomised clinical trials are needed in order to confirm this preliminary result.

Vigolo and Givani⁵³ found that the effect of platform shifting is effective in preventing marginal bone loss, but only up to 1 year after abutment connection. Viceversa, Canullo and colleagues³³ found that the effect of platform shifting in preventing marginal bone loss also occurred 3 years after the prosthe-

sis delivery. Nevertheless, the main limitation of the aforementioned study is that the timepoint considered as baseline measurement was the definitive prostheses delivery. Thus, this study did not assess the platform shifting effect during the submerged healing period and further on the biological width establishment after abutment connection.

Furthermore, the reduced marginal bone loss experienced in this RCT during the entire follow-up with the NobelActive implants may be of importance in areas of aesthetic concern, eventually reducing the risk of an exposed metal implant shoulder and/or reducing the distance between the nearest teeth/implants. The mean horizontal bone resorption after 3 years was 0.20 mm for the back-tapered neck configuration with conical connection and in-built platform shifting, with a 66% improvement assessed over that seen in the flat-to-flat implant-abutment interface and external hexagonal connection (0.60 mm). The major clinical hypothesis of this RCT, according to Elian et al⁴, should be that the reduced vertical and horizontal marginal bone loss experienced with the back-tapered neck configuration with conical connection and in-built platform shifting, may result in a reduction of the safety distance between adjacent implants and between the implant and the neighbouring natural dentition. This bone preservation may broaden the clinical application of the implant supported restorations to all the clinical scenarios featured with a tight restorative space, reducing the risk of jeopardising the periodontal attachment of the adjacent teeth or infringing the marginal bone of adjacent implants. The conical connection implants with in-built platform shifting may be capable of preserving peri-implant bone when implants are placed adjacent to each other. The final amount of bone loss may combine through overlapping, thereby causing loss of the interproximal height of bone and papilla⁴. Tarnow et al⁵ evaluated the lateral bone loss around adjacent external hexagon implants in a retrospective study and observed that when the distance between implants was ≤ 3 mm, the lateral bone loss compromised the magnitude of the crestal bone. Vice versa, Degidi⁴¹ and Rodríguez-Ciurana⁵⁴ showed that two adjacent conical connection implants with in-built platform shifting, can be placed at a distance of 2 mm. In addition, the longer the period of time, the more statistically significant the results were⁴¹. The con-



cal connection implants with in-built platform shifting may help to preserve peri-implant bone and retain the interproximal bone peak better than external hexagon implants. This bone preservation may lead to better support for the soft tissues and improves the crown-to-implant ratio, even with an inter-implant distance of less than 3 mm.

The presented research failed to found statistically significant difference regarding the periodontal parameters (SBI and PS). This result appears contradictory to various studies that suggested that the microgap at the implant-abutment interface plays a significant role in the bacterial colonisation of the implant sulcus, consequently leading to peri-implant inflammatory reactions and bone resorption^{18,28,44}. Moreover the conical connection implant with tight seal implant-abutment interface showed higher sealing capability^{44,45} than the external hexagon implant with flat-to-flat interface. Nevertheless, in the present study, all patients were closely monitored by the research team, and the maintenance protocol was based on recall appointments every 3 months for professional cleaning treatment by a dental hygienist. The latter highlights the value of supportive periodontal therapy in enhancing long-term outcomes of implant-supported restorations.

■ Conclusions

Three years after loading, both implants provided good results in posterior mandibles. However, both horizontal and vertical marginal bone loss had statistically lower significance in the NobelActive implants, compared to the NobelSpeedy Groovy implants.

■ References

- Bahat O, Sullivan RM. Parameters for successful implant integration revisited part II: algorithm for immediate loading diagnostic factors. *Clin Implant Dent and Relat Res* 2010;12:13–22.
- Pozzi A, Agliardi EL, Tallarico M, Barlattani A. Clinical and Radiological Outcomes of Two Implants with Different Prosthetic Interfaces and Neck Configurations: Randomized, Controlled, Split-Mouth Clinical Trial. *Clin Implant Dent and Relat Res* 2012, Jun 1. [Epub ahead of print]
- Oh TJ, Yoon J, Misch CE, Wang HL. The causes of early implant bone loss: myth or science? *J Periodontol* 2002; 73:322–333.
- Elian N, Bloom M, Dard M, Cho SC, Trushkowsky RD, Tarnow D. Effect of interimplant distance (2 and 3 mm) on the height of interimplant bone crest: a histomorphometric evaluation. *J Periodontol* 2011;82:1749–1756.
- Tarnow DP, Cho SC, Wallace SS. The effect of inter-implant distance on the height of inter-implant bone crest. *J Periodontol* 2000;71:546–549.
- Klinge B. Peri-implant marginal bone loss: an academic controversy or a clinical challenge? *Eur J Oral Implantol* 2012; 5:13–19.
- Oh TJ, Yoon J, Misch CE, Wang HL. The causes of early implant bone loss: myth or science? *J Periodontol* 2002; 73:322–333.
- Albrektsson T, Zarb G, Worthington P, Eriksson RA. The long-term efficacy of currently used dental implants. A review and proposed criteria for success. *Int J Oral Maxillofac Implants* 1986;1:11–25.
- Atieh MA, Ibrahim HM, Atieh AH. Platform switching for marginal bone preservation around dental implants: a systematic review and meta-analysis. *Journal of Periodontology* 2010;81:1350–1366.
- Lazzara RJ, Porter SS. Platform switching: a new concept in implant dentistry for controlling postrestorative crestal bone levels. *Int J Periodontics Restorative Dent* 2006;26:9–17.
- Tsoukaki M, Kalpidis CDR, Sakellari D, Tsalikis L, Mikrogorgis G, Konstantinidis A. Clinical, radiographic, microbiological, and immunological outcomes of flapped vs. flapless dental implants: a prospective randomized controlled clinical trial. *Clin Oral Implants Res* 2013;24:969–976.
- Quirynen M, Naert I, van Steenberghe D. Fixture design and overload influence marginal bone loss and fixture success in the Branemark system. *Clin Oral Implants Res* 1992;3: 104–111.
- Koo KT, Lee EJ, Kim JY, Seol YJ, Han JS, Kim TI, Lee YM, Ku Y, Wikesjö UM, Rhyu IC. The effect of internal versus external abutment connection modes on crestal bone changes around dental implants: a radiographic analysis. *J Periodontol* 2012;83:1104–1109.
- Karl M, Winter W, Taylor TD, Heckmann SM. In vitro study on passive fit in implant-supported 5-unit fixed partial dentures. *Int J Oral Maxillofac Implants* 2004;19:30–37.
- Isidor F. Influence of forces on peri-implant bone. *Clin Oral Implants Res* 2006;17:8–18.
- Kitamura E, Stegaroiu R, Nomura S, Miyakawa O. Influence of marginal bone resorption on stress around an implant – a three-dimensional finite element analysis. *J Oral Rehabil* 2005;32:279–286.
- Hermann JS, Buser D, Schenk RK, Schoolfield JD, Cochran DL. Biologic Width around one- and two-piece titanium implants. *Clin Oral Implants Res* 2001;12:559–571.
- Broggini N, McManus LM, Hermann JS, Medina R, Schenk RK, Buser D, Cochran DL. Peri-implant inflammation defined by the implant-abutment interface. *J Dent Res* 2006;85:473–478.
- Callan DP, Cobb CM, Williams KB. DNA probe identification of bacteria colonizing internal surfaces of the implant-abutment interface: a preliminary study. *J Periodontol* 2005;76:115–120.
- Capelli M. Surgical, biologic and implant-related factors affecting bone remodeling around implants. *Eur J Esthet Dent* 2013;8:279–313.
- Laurell L, Lundgren D. Marginal bone level changes at dental implants after 5 years in function: a meta-analysis. *Clin Implant Dent Relat Res* 2011;13:19–28.
- Degidi M, Nardi D, Piattelli A. A 10-Year follow-up of immediately loaded implants with TiUnite porous anodized surface. *Clin Implant Dent Relat Res* 2012;14:828–838.
- Mir-Mari J, Mir-Orfila P, Valmaseda-Castellón E, Gay-Escoda C. Long-term marginal bone loss in 217 machined-surface implants placed in 68 patients with 5 to 9 years of follow-up: a retrospective study. *Int J Oral Maxillofac Implants* 2012;27:1163–1169.

24. Aguiar FHB, Santos AJ, Groppo FC, Lovadino JR. Quantitative evaluation of marginal leakage of two resin composite restorations using two filling techniques. *Oper Dent* 2002;27:475–479.
25. Quirynen M, van Steenberghe D. Bacterial colonization of the internal part of two-stage implants. An in vivo study. *Clin Oral Implants Res*. 1993;4:158–161.
26. Quirynen M, Bollen CM, Eysen H, van Steenberghe D. Microbial penetration along the implant components of the Brånemark system. An in vitro study. *Clin Oral Implants Res* 1994;5:239–244.
27. Brogini N, McManus LM, Hermann JS, Medina RU, Oates TW, Schenk RK, Buser D, Mellonig JT, Cochran DL. Persistent acute inflammation at the implant-abutment interface. *J Dent Res* 2003;82:232–237.
28. Larrucea Verdugo C, Jaramillo Núñez G, Acevedo Avila A, Larrucea San Martín C. Microleakage of the prosthetic abutment/implant interface with internal and external connection: In vitro study. *Clin Oral Implants Res* 2013 Jul 4 [Epub ahead of print].
29. Weinberg LA. The biomechanics of force distribution in implant-supported prostheses. *Int J Oral Maxillofac Implants* 1993;8:19–31.
30. Almeida EO, Freitas AC, Bonfante EA, Marotta L, Silva NRFA, Coelho PG. Mechanical testing of implant-supported anterior crowns with different implant/abutment connections. *Int J Oral Maxillofac Implants* 2013;28:103–108.
31. Winter W, Mohrle S, Holst S, Karl M. Bone loading caused by different types of misfits of implant-supported fixed dental prostheses: a three-dimensional finite element analysis based on experimental results. *Int J Oral Maxillofac Implants* 2010;25:947–952.
32. Arnhart C, Kielbassa AM, Martinez-de Fuentes R, Goldstein M, Jackowski J, Lorenzoni M, Maiorana C, Mericske-Stern R, Pozzi A, Rompen E, Sanz M, Strub JR. Comparison of variable-thread tapered implant designs to a standard tapered implant design after immediate loading. A 3-year multicentre randomised controlled trial. *Eur J Oral Implantol* 2012;5:123–136.
33. Canullo L, Fedele GR, Iannello G, Jepsen S. Platform switching and marginal bone-level alterations: the results of a randomized-controlled trial. *Clin Oral Implants Res* 2010;21:115–121.
34. Canullo L, Iannello G, Peñarocha M, Garcia B. Impact of implant diameter on bone level changes around platform switched implants: preliminary results of 18 months follow-up a prospective randomized match-paired controlled trial. *Clin Oral Implants Res* 2012;23:1142–1146.
35. Rompen E. The impact of the type and configuration of abutments and their (repeated) removal on the attachment level and marginal bone. *Eur J Oral Implantol* 2012;5:83–90.
36. Prosper L, Redaelli S, Pasi M, Zarone F, Radaelli G, Gherlone EF. A randomized prospective multicenter trial evaluating the platform-switching technique for the prevention of postrestorative crestal bone loss. *Int J Oral Maxillofac Implants* 2009;24:299–308.
37. Esposito M, Grusovin MG, Achille H, Coulthard P, Worthington HV. Interventions for replacing missing teeth: different times for loading dental implants. *Cochrane Database Syst Rev* 2013 Mar 28;3:CD003878.
38. Esposito M, Grusovin MG, Worthington HV. Interventions for replacing missing teeth: antibiotics at dental implant placement to prevent complications. *Cochrane Database Syst Rev* 2010;7:CD004152.
39. Mombelli A, Lang NP. The diagnosis and treatment of peri-implantitis. *Periodontol* 2000 1998;17:63–76.
40. Fu JH, Yeh CY, Chan HL, Tatarakis N, Leong DJ, Wang HL. Tissue biotype and its relation to the underlying bone morphology. *J Periodontology* 2010;81:569–574.
41. Degidi M, Novaes AB, Nardi D, Piattelli A. Outcome analysis of immediately placed, immediately restored implants in the esthetic area: the clinical relevance of different interimplant distances. *J Periodontology* 2008;79:1056–1061.
42. Schmidt JC, Sahrman P, Weiger R, Schmidlin PR, Walter C. Biologic width dimensions – a systematic review. *J Clin Periodontol* 2013;40:493–504.
43. McKinney RVJ, Stefflik DE, Koth DL. The biologic response to the single-crystal sapphire endosteal dental implant: scanning electron microscopic observations. *J Prosthet Dent* 1984;51:372–379.
44. Coelho PG, Sudack P, Suzuki M, Kurtz KS, Romanos GE, Silva NR. In vitro evaluation of the implant abutment connection sealing capability of different implant systems. *J Oral Rehabil* 2008;35:917–924.
45. Buser D, Martin W, Belser UC. Optimizing esthetics for implant restorations in the anterior maxilla: anatomic and surgical considerations. *Int J Oral Maxillofac Implants* 2004;19:43–61.
46. Lindhe J, Berglundh T. The interface between the mucosa and the implant. *Periodontol* 2000 1998;17:47–54.
47. Morris HF, Ochi S, Crum P, Orenstein IH, Winkler S. AICRG, Part I: A 6-year multicentered, multidisciplinary clinical study of a new and innovative implant design. *J Oral Implantol* 2004;30:125–133.
48. Chou CT, Morris HF, Ochi S, Walker L, DesRosiers D. AICRG, Part II: Crestal bone loss associated with the Ankylos implant: loading to 36 months. *J Oral Implantol* 2004;30:134–143.
49. Ravald N, Dahlgren S, Teiwik A, Gröndahl K. Long-term evaluation of Astra Tech and Brånemark implants in patients treated with full-arch bridges. Results after 12–15 years. *Clin Oral Implants Res* 2012;24:1144–1151.
50. Schmitt CM, Nogueira-Filho G, Tenenbaum HC, Lai JY, Brito C, Döring H, Nonhoff J. Performance of conical abutment (Morse Taper) connection implants: A systematic review. *J Biomed Mater Res A* 2014;102:522–574.
51. Cehreli MC, Kökat AM, Uysal S, Akca K. Spontaneous early exposure and marginal bone loss around conventionally and early-placed submerged implants: a double-blind study. *Clin Oral Implants Res* 2010;21:1327–1333.
52. Östman PO, Hellman M, Sennerby L. Ten Years Later. Results from a prospective single-centre clinical study on 121 Oxidized (TiUnite™) Brånemark Implants in 46 Patients. *Clin Implant Dent Relat Res* 2012;14:852–860.
53. Vigolo P, Givani A. Platform-switched restorations on wide-diameter implants: a 5-year clinical prospective study. *Int J Oral Maxillofac Implants* 2009;24:103–109.
54. Rodríguez-Ciurana X, Vela-Nebot, Segalà-Torres M, Calvo-Guirado JL, Cambra J, Méndez-Blanco V, Tarnow DP. The effect of interimplant distance on the height of the interimplant bone crest when using platform-switched implants. *Int J Periodontics Restorative Dent* 2009;29:141–151.