

# UC Davis

## UC Davis Previously Published Works

### Title

The Anesthetic Management of the First Lung Transplant for a Patient with COVID-19 Respiratory Failure

### Permalink

<https://escholarship.org/uc/item/4h90v3xp>

### Journal

Journal of Cardiothoracic and Vascular Anesthesia, 35(3)

### ISSN

1053-0770

### Authors

Hu, Chunxiao  
Wang, Guilong  
Zhou, Difei  
[et al.](#)

### Publication Date

2021-03-01

### DOI

10.1053/j.jvca.2020.06.011

Peer reviewed



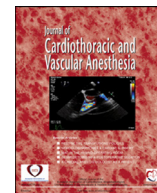
Since January 2020 Elsevier has created a COVID-19 resource centre with free information in English and Mandarin on the novel coronavirus COVID-19. The COVID-19 resource centre is hosted on Elsevier Connect, the company's public news and information website.

Elsevier hereby grants permission to make all its COVID-19-related research that is available on the COVID-19 resource centre - including this research content - immediately available in PubMed Central and other publicly funded repositories, such as the WHO COVID database with rights for unrestricted research re-use and analyses in any form or by any means with acknowledgement of the original source. These permissions are granted for free by Elsevier for as long as the COVID-19 resource centre remains active.



Contents lists available at ScienceDirect

Journal of Cardiothoracic and Vascular Anesthesia

journal homepage: [www.jcvaonline.com](http://www.jcvaonline.com)

## Case Report

## The Anesthetic Management of the First Lung Transplant for a Patient with COVID-19 Respiratory Failure

Chunxiao Hu, MD<sup>\*,2</sup>, Guilong Wang, MD<sup>\*,2</sup>, Difei Zhou, MD<sup>\*,2</sup>,  
Wei Wang, MD<sup>\*,2</sup>, Zhong Qin, MD<sup>\*</sup>, Yanjuan Wang, MD<sup>\*</sup>,  
Jingyu Chen, MD<sup>†</sup>, Hong Liu, MD<sup>‡</sup>, Quan Li, MD, PhD<sup>§</sup>,  
Dongxiao Huang, MD<sup>\*,1</sup>

<sup>\*</sup>Department of Anesthesiology, the Affiliated Wuxi People's Hospital of Nanjing Medical University, Wuxi, Jiangsu, China

<sup>†</sup>Department of Lung Transplant Center, the Affiliated Wuxi People's Hospital of Nanjing Medical University, Wuxi, Jiangsu, China

<sup>‡</sup>Department of Anesthesiology and Pain Medicine, University of California Davis Health, Sacramento, CA

<sup>§</sup>Department of Anesthesiology, National Cancer Center/National Clinical Research Center for Cancer/ Cancer Hospital & Shenzhen Hospital, Chinese Academy of Medical Sciences and Peking Union Medical College, Shenzhen, China

THE NOVEL coronavirus was first detected in China at the end of 2019, and there were 3,517,345 confirmed coronavirus disease 2019 (COVID-19) cases and 243,401 deaths worldwide as of May 5, 2020, including in United States.<sup>1-3</sup> According to Diagnosis and Treatment Protocol for Novel Coronavirus Pneumonia (Trial Version 7),<sup>4</sup> pathologic findings from limited autopsies and biopsy studies indicate variable consolidations are present in the lungs, and organization of alveolar exudates and interstitial fibrosis also are present. Some COVID-19 patients present with severe acute respiratory distress syndrome (ARDS) and irreversible lung injury, even when their severe acute respiratory syndrome coronavirus 2 (SARS-CoV-2) on real-time reverse transcriptase-polymerase chain reaction assay has become negative. For these patients, instead of using long-term extracorporeal membrane oxygenation (ECMO), lung transplant might be an alternative option. Due to the uncharted territory of COVID-19 with unknown outcome after lung transplant, no lung transplant had been performed before this case. The authors report the world's first

double-lung transplant for a patient infected with novel coronavirus.

### Case Report

The patient was a 59-year-old man with confirmed COVID-19 and presented with end-stage respiratory failure and irreversible lung injury despite invasive mechanical ventilation and veno-venous ECMO (V-V ECMO). His height was 170 cm and weight was 70 kg. Chest computed tomography showed bilateral, multifocal ground-glass opacities with patch consolidations (Fig 1). The chest X-ray before surgery showed bilateral lung involvement with “white out” and multifocal consolidation (Fig 2). Arterial blood gas (ABG) before ECMO showed the following: pH 7.44, PaO<sub>2</sub> 94.4 mmHg, PaCO<sub>2</sub> 65.8 mmHg, HCO<sub>3</sub> 44.3 mEq/L, BE (base excess) 17.52 mEq/L on F<sub>I</sub>O<sub>2</sub> 60%, tidal volume 380, rate 32, positive end-expiratory pressure of 10 mmHg, and lactate 0.7 mEq/L. Preoperative ABG on ECMO showed the following: pH 7.65, PaO<sub>2</sub> 81 mmHg, PaCO<sub>2</sub> 19 mmHg, HCO<sub>3</sub> 20.9 mEq/L, BE 1.3 mEq/L, oxygen saturation 98%, flow at 4 L/min, and sweep of 4 L/min on F<sub>I</sub>O<sub>2</sub> 100%. After adjusting the flow and sweep, the ABG showed the following: pH 7.35, PaO<sub>2</sub> 94 mmHg, PaCO<sub>2</sub> 45 mmHg, HCO<sub>3</sub> 24.8 mEq/L, BE-1 mEq/L, and oxygen saturation 97% on F<sub>I</sub>O<sub>2</sub> 100%. Other laboratory results

<sup>1</sup>Address reprint requests to Dongxiao Huang, Department of Anesthesiology, the Affiliated Wuxi People's Hospital of Nanjing Medical University, No.299 Qingyang Road, Wuxi, Jiangsu, 214023, China.

E-mail address: [hdxs88@163.com](mailto:hdxs88@163.com) (D. Huang).

<sup>2</sup>C. Hu, G. Wang, D. Zhou, and W. Wang contributed equally to this article. H. Liu, Q. Li, and D. Huang contributed equally as senior authors.

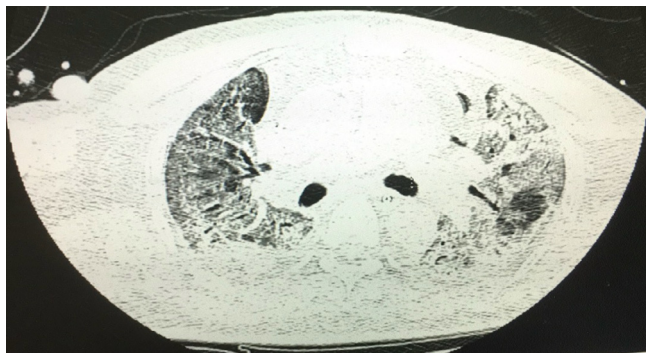


Fig. 1. Preoperative computed tomography images. Bilateral, multifocal ground-glass opacities with patch consolidations.

Table 1  
Levels of Personal Protection for Health Care Workers During the COVID-19 Pandemic\*

	Routine	Level 1	Level 2	Level 3
Hand hygiene	+	+	+	+
Surgical mask	+	+	-	-
Respirator (N95)	-	-	+	+
Eye protection	-	-	±	+
Gloves	±	+	+	++
Scrubs	+	+	+	+
Isolation gown	-	+	±!	-
Protective clothing	-	-	±!	+
Disposable hair cover	-	+	+	+
Head cover	-	-	-	+
Shoe cover	-	-	+	++

\* Based on the regulations established in Wuxi People's Hospital with modifications. Abbreviations: +, mandatory; -, not needed; ±, decision made according to the work scenario; ±!, choice between isolation gown or protective clothing is decided based on the local resources for level 3 protection; ++, double gloves or shoe covers.

included C-reactive protein of 44.89 mg/L and N-terminal 76-amino acid peptide pro brain natriuretic peptide (NT-proBNP) of 431 pg/mL, which were decreased from 1,389 pg/mL from 2 weeks ago. Preoperative repeated SARS-CoV-2 on real-time reverse transcriptase-polymerase chain reaction assays was negative. The patient's medical history included hepatitis B. The patient's SARS-CoV-2 on real-time reverse transcriptase-polymerase chain reaction assay was positive on January 27, 2020, but preoperative multiple tests of novel coronavirus nucleic acid were negative. No significant damage was found in other organs. The surgery was scheduled on February 29, 2020.

The donor lungs came from a 42-year-old man who suffered from traumatic brain injury. He was intubated and mechanically ventilated and was declared brain dead 3 days later. He was ruled out for COVID-19 after novel coronavirus nucleic acid test and computed tomography. The donor selection criteria were in accordance with the Donor Lung Explantation and Protection Specifications for Lung Transplantation in China (2019 Edition).<sup>5</sup>

On the day of surgery, all surgical personnel took the standard Level 3 protection precaution (Table 1), and the surgery was performed in a negative-pressure operating room (OR). The patient was transported to the OR on V-V ECMO and mechanical ventilation under sedation with midazolam and remifentanyl. The patient's heart rate was 89 beats/min, blood pressure 155/81 mmHg, and pulse oxygen saturation 97%.

General anesthesia was induced intravenously with 15 mg of etomidate, 25 µg of sufentanil, and 20 mg of cisatracurium. The single-lumen endotracheal tube was replaced with a left double-lumen endobronchial tube for lung isolation and mechanical ventilation. General anesthesia was maintained with 0.03- to 0.05 mg/kg/min of propofol, 3- to 6 µg/kg/min of cisatracurium, 0.1- to 0.2 µg/kg/min of remifentanyl, and 5- to 10 mg of an oxycodone bolus as needed. Intraoperative monitoring included American Society of Anesthesiologists standard monitoring, stroke volume variation, stroke volume, cardiac output, cardiac index, systemic vascular resistance index via left radial arterial catheter, and left internal jugular venous central line.

The patient was placed in the supine position and double-lung transplantation was performed. After clamshell incision through the fourth intercostal space and the exposure of the heart and lungs, the authors noted poor left and right ventricular contractility, enlarged pulmonary artery, hematoma in the right lower lobe, a bleeding patch on the surface of both lungs, and lung parenchyma fibrosis. Veno-arterial ECMO was added for circulatory support during surgery. Ten thousand units of heparin were given before starting veno-arterial ECMO and activated clotting time was maintained around 180 seconds.

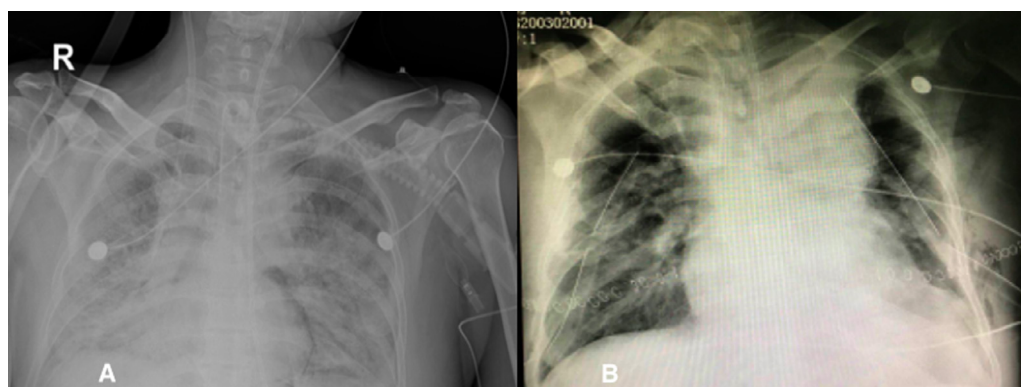


Fig. 2. Chest X-ray before (A) and after (B) lung transplant.

Intraoperative fluid combined with vasoactive drugs were used for volume and hemodynamic management.

The surgery lasted for 6 hours. The right lung cold ischemia time was 8 hours, and the left lung cold ischemia time was 9 hours and 35 minutes. The intraoperative bleeding was 4,000 mL and the blood transfusion was 4,800 mL. After surgery, V-V ECMO and mechanical ventilation were continued in the intensive care unit. The V-V ECMO was successfully weaned on postoperative day 2 and the PaO<sub>2</sub>/F<sub>i</sub>O<sub>2</sub> ratio was 375. The chest X-ray showed significantly improved lung imaging compared with the one before surgery (Fig 2). The patient was successfully weaned off from mechanical ventilation and extubated on postoperative day 14, with PaO<sub>2</sub>/F<sub>i</sub>O<sub>2</sub> ratio of 440. No medical staff caring for this patient contracted COVID-19.

## Discussion

The authors reported the first case of successful double-lung transplant in a COVID-19 patient. Because these patients develop severe irreversible lung damage, lung transplant becomes an alternative choice for COVID-19 patients with terminal respiratory failure. Although the repeated SARS-CoV-2 on real-time reverse transcriptase-polymerase chain reaction assay had converted from positive to negative, the potential risks of infection was still high and the strict protective measures were important for healthcare providers caring for these patients. This is even more important in the perioperative setting where the aerosol-generating procedures are carried out like in this case.

Although ECMO can serve as the life-saving rescue therapy for refractory respiratory failure in the setting of ARDS caused by COVID-19, the mortality rate is 45% according to the Extracorporeal Life Support Organization registry (<https://www.else.org/Home.aspx>). However, there are studies that reported the mortality rate as high as 83%.<sup>6</sup> Yang and colleagues raised concerns about potential harms of ECMO therapy for COVID-19 patients, especially that the immunologic status of patients should be considered when selecting candidates for ECMO.<sup>7</sup> ECMO is just a bridging and supporting measure that does not cure the disease. The lung transplant could be the viable option for COVID-19 patients, with ARDS/terminal respiratory failure, and who are unable to wean off ECMO. The anesthesia management for lung transplantation for COVID-19 patients may be different from other lung transplant patients. Patients with COVID-19 also may have myocardial injury and multiple organ failures,<sup>8</sup> which may cause hemodynamic instability together with low oxygen saturation.

The oxygen reserve in patients with COVID-19 is very low, especially in critically ill patients. This makes intubation a huge challenge. Based on the authors' experience, adequate preoxygenation and rapid-sequence induction to avoid positive ventilation and coughing are recommended.<sup>4</sup> Video laryngoscope should be used to facilitate intubation as soon as muscle relaxation is achieved. However, the patient reported here was already intubated. After adequate sedation and

muscle relaxation, a single-lumen endotracheal tube was replaced with a double-lumen endobronchial tube. Like the anesthesia for other lung transplantation, it is important to avoid hypoxia, hypercarbia, and acidosis, which can lead to pulmonary hypertension and right heart failure. It is also important to avoid respiratory alkalosis caused by ECMO. Other important aspects in perioperative hemodynamic management are to prevent tachycardia and arrhythmia. Restricted fluid management is recommended to avoid pulmonary edema by the combination of colloid and crystal solutions. Invasive hemodynamic monitoring is suggested, which can guide the use of vasoactive agents and fluid management. Maintaining perioperative cardiac function is the key to anesthesia management during surgery. Preload optimization before clamping and unclamping the pulmonary artery are vital in preserving graft and postoperative pulmonary function.<sup>9,10</sup> A protective ventilation strategy should be used for the transplanted lung.<sup>9</sup>

COVID-19 patients who develop ARDS and refractory respiratory failure are treated with mechanical ventilation and ECMO.<sup>11</sup> A significant number of these patients become ECMO-dependent. Even in the patients who could be weaned off ECMO, their lung injuries are irreversible. Lung transplant becomes an alternative option for these patients, just like all the other end-stage lung injury patients who require lung transplant. The COVID-19 patients should be registered on the national lung transplant registry. Because this is a new disease without effective treatment and the outcome is unknown, patients should be given sufficient time for the lungs to heal. Although the SARS-CoV-2 on real-time reverse transcriptase-polymerase chain reaction assay was negative 3 times from both nasopharyngeal swabs and bronchoalveolar lavage samples in this patient, it has been reported that the coronavirus test can become positive again days after patients had recovered from COVID-19.<sup>12</sup> This could be explained by the possible false negative tests, discontinuation of antiviral drugs, and rebounding from residual viruses.<sup>12,13</sup> Because the lung transplant is a resource-limited field, it is important to balance the risks and benefits. The current evidence supports that younger recipients with single-system disorders will have better outcomes.<sup>14</sup>

The protective measures for healthcare providers in the perioperative setting is another important aspect in managing COVID-19 patients.<sup>15-18</sup> During the 2003 SARS outbreak in Ontario, Canada, 51% of cases were healthcare workers. Healthcare-worker involvement with tracheal intubation had a 13-fold higher relative risk ratio for acquiring SARS infection when compared with healthcare workers not participating in tracheal intubation.<sup>19</sup> A more recent publication from the Chinese Center for Disease Control and Prevention (Beijing, China) reported that as of February 11, 2020 there were 1,716 healthcare workers diagnosed with COVID-19 out of 44,672 confirmed cases, although most of the infected healthcare workers were confined to the initial epicenter of the outbreak (Hubei Province, China).<sup>20</sup> Even though the patient's COVID tests were negative, the hospital still mandated using standard Level 3 protection (Table 1). Double masks with N95 inside and surgical mask outside, gowns, and double gloves should

be worn by the intubation team. The person who is performing the intubation should wear a third pair of gloves and remove them immediately after intubation. A dedicated OR only for patients with COVID-19, equipped with a negative- pressure system should be used. If there is no negative- pressure OR available, the positive- pressure system and air conditioning must be turned off.

Anesthesia equipment, supplies, and medications must be used for the patient exclusively. Anesthesia supplies that directly contact the patient's skin or mucosa should be single use, including the video laryngoscope blades, endotracheal tubes, anesthesia masks, filters, breathing balloons, suction tubes, catheters, end-expiratory carbon dioxide sampling tubes, water traps, etc. A closed airway suction system is recommended to reduce aerosol generation. All healthcare workers participating in the surgery should remove their personal protective equipment and place them in a designated waste bag. The doffing of personal protective equipment should be in proper order.

In conclusion, ECMO is just a bridging and supportive method. The use of ECMO is associated with high mortality in patients with ARDS due to COVID-19. Lung transplant could be a viable option for COVID-19 patients with ARDS/terminal respiratory failure and who are unable to wean off ECMO. Surgery and anesthesia for lung transplant in COVID-19 patients should be carried out in a designated negative- pressure OR with Level 3 protection. The key points of anesthesia include maintaining right heart function, managing intravenous fluid, monitoring hemodynamics, correcting coagulation disorders, and choosing the proper ECMO mode, which can effectively support cardiac and pulmonary functions during lung transplant.

## Declaration of Competing Interest

All authors have no conflicts of interest

## References

- Zhu N, Zhang D, Wang W, et al. A novel coronavirus from patients with pneumonia in China, 2019. *N Engl J Med* 2020;382:727–33.
- Wu Z, McGoogan JM. Characteristics of and important lessons from the coronavirus disease 2019 (COVID-19) outbreak in China: Summary of a report of 72314 cases from the Chinese Center for Disease Control and Prevention [e-pub ahead of print]. *JAMA* 2020. <https://doi.org/10.1001/jama.2020.2648>; Accessed on April 26, 2020.
- World Health Organization. Available at: [https://www.who.int/docs/default-source/coronaviruse/situation-reports/20200505covid-19-sitrep-106.pdf?sfvrsn=47090f63\\_2](https://www.who.int/docs/default-source/coronaviruse/situation-reports/20200505covid-19-sitrep-106.pdf?sfvrsn=47090f63_2). Accessed May 5, 2020.
- National Health Commission and National Administrative Office of Chinese Tradition Medicine: National Recommendations for Diagnosis and Treatment of Pneumonia Caused by 2019-nCoV (7th edition). Available at: [http://www.gov.cn/zhengce/zhengceku/2020-03/04/content\\_5486705.htm](http://www.gov.cn/zhengce/zhengceku/2020-03/04/content_5486705.htm) [Chinese only]. Accessed on April 26, 2020
- Liu D, Mao W, Ye S, et al. Donor lung explantation and protection specifications for lung transplantation in China (2019 Edition). *Chin J Transplant (Electronic Edition)* 2019;13:87–90.
- Yang X, Yu Y, Xu J, et al. Clinical course and outcomes of critically ill patients with SARS-CoV-2 pneumonia in Wuhan, China: A single-centered, retrospective, observational study. *Lancet Respir Med* 2020;8:475–81.
- Henry BM. COVID-19, ECMO, and lymphopenia: A word of caution. *Lancet Respir Med* 2020;8:e24.
- Ruan Q, Yang K, Wang W, et al. Clinical predictors of mortality due to COVID-19 based on an analysis of data of 150 patients from Wuhan, China. *Intensive Care Med* 2020;46:846–8.
- Hoeper MM, Benza RL, Corris P, et al. Intensive care, right ventricular support and lung transplantation in patients with pulmonary hypertension. *Eur Respir J* 2019;53:1801906.
- Boasquevisque CH, Yildirim E, Waddel TK, et al. Surgical techniques: Lung transplant and lung volume reduction. *Proc Am Thorac Soc* 2009;6:66–78.
- Li X, Guo Z, Li B, et al. Extracorporeal membrane oxygenation for coronavirus disease 2019 in Shanghai, China. *ASAIO J* 2020;66:475–81.
- Wu F, Zhang W, Zhang L, et al. Discontinuation of antiviral drugs may be the reason for recovered COVID-19 patients testing positive again. *Br J Hosp Med (Lond)* 2020;81:1–2.
- Xing Y, Mo P, Xiao Y, et al. Post-discharge surveillance and positive virus detection in two medical staff recovered from coronavirus disease 2019 (COVID-19), China, January to February 2020. *Euro Surveill* 2020;25:2000191.
- Mitchell AB, Glanville AR. Lung transplantation: A review of the optimal strategies for referral and patient selection. *Ther Adv Respir Dis* 2019;13:1753466619880078.
- Chen X, Liu Y, Gong Y, et al. Perioperative management of patients infected with the novel coronavirus: Recommendation from the Joint Task Force of the Chinese Society of Anesthesiology and the Chinese Association of Anesthesiologists. *Anesthesiology* 2020;132:1307–16.
- Meng L, Qiu H, Wan L, et al. Intubation and ventilation amid the COVID-19 outbreak: Wuhan's experience. *Anesthesiology* 2020;132:1317–32.
- Wax RS, Christian MD. Practical recommendations for critical care and anesthesiology teams caring for novel Coronavirus (2019-nCoV) patients. *Can J Anesth* 2020;67:568–76.
- Park J, Yoo SY, Ko JH, et al. Infection prevention measures for surgical procedures during a Middle East Respiratory Syndrome outbreak in a tertiary care hospital in South Korea. *Sci Rep* 2020;10:325.
- Fowler RA, Guest CB, Lapinsky SE, et al. Transmission of severe acute respiratory syndrome during intubation and mechanical ventilation. *Am J Respir Crit Care Med* 2004;169:1198–202.
- Wu Z, McGoogan JM. Characteristics of and important lessons from the coronavirus disease 2019 (COVID-19) outbreak in China: Summary of a report of 72314 cases from the Chinese Center for Disease Control and Prevention [e-pub ahead of print]. *JAMA* 2020. <https://doi.org/10.1001/jama.2020.2648>; Accessed on April 26, 2020.