

UC Davis

Dermatology Online Journal

Title

Epidermolysis bullosa acquisita

Permalink

<https://escholarship.org/uc/item/4jk4333w>

Journal

Dermatology Online Journal, 23(12)

Authors

Cobos, Gabriela
Mu, Euphemia
Cohen, Jeffrey
et al.

Publication Date

2017

DOI

10.5070/D32312037672

Copyright Information

Copyright 2017 by the author(s). This work is made available under the terms of a Creative Commons Attribution-NonCommercial-NoDerivatives License, available at <https://creativecommons.org/licenses/by-nc-nd/4.0/>

Peer reviewed

Epidermolysis bullosa acquisita

Gabriela Cobos MD, Euphemia Mu MD, Jeffrey Cohen MD, Jenna Beasley MD, Nooshin Brinster MD, and Alisa Femia MD

Affiliations: New York University, New York

Abstract

Epidermolysis bullosa acquisita (EBA) is a rare, acquired subepidermal blistering disease. EBA is characterized by autoantibodies to collagen VII, which serves to link the epidermis to the dermis. The two most common presentations of EBA are classical noninflammatory EBA and bullous pemphigoid-like EBA. Diagnosis of EBA can be challenging as it shares clinical and histopathologic features with other blistering diseases. Treatment is often recalcitrant and will often necessitate multiple therapies. We present a case of a thirty-six-year-old Chinese man with EBA and review the literature.

Keywords: epidermolysis bullosa acquisita, bullous disorders, collagen VII

Introduction

A 36-year-old man without any medical problems presented to the dermatology clinic at Bellevue Hospital for the evaluation of a blistering eruption, which began 20 days prior to his presentation. He noted the eruption initially started with blisters on his face, which had since resolved without any intervention. Subsequently, he continued to develop new blisters on his trunk and extremities. These blisters were associated with pruritus and pain. He endorsed using systemic antibiotics and Chinese herbal medications to self-treat the eruption but denied any new medications prior to the development of the eruption. A thorough review of systems was entirely negative; notably, he denied any gastrointestinal, ophthalmologic, or urinary symptoms.

There were two erosions and one small vesicle on the tongue. On his trunk, distal lower extremities, and forearms, there were tense bulla and vesicles,

some arranged in an annular pattern. Additionally, there were erythematous patches and erosions with minimal scale at the site of resolving bullae.

A comprehensive metabolic panel was within normal limits. collagen VII antibody enzyme-linked immunosorbent assay (ELISA) was pending. BPAG 180 and BPAG230 antibodies were negative.

Two punch biopsies, one lesional for hematoxylin and eosin (H&E) and one perilesional direct immunofluorescence (DIF), were performed on a bulla on the right forearm. There is a subepidermal vesicle within which are numerous neutrophils and eosinophils in addition to a perivascular and interstitial mixed cell infiltrate of lymphocytes, neutrophils and eosinophils. Salt-split direct immunofluorescence shows linear deposits of C3 and IgG at the base of the bullae.

Conclusion

Epidermolysis bullosa acquisita (EBA) is a rare, acquired, chronic subepidermal blistering condition

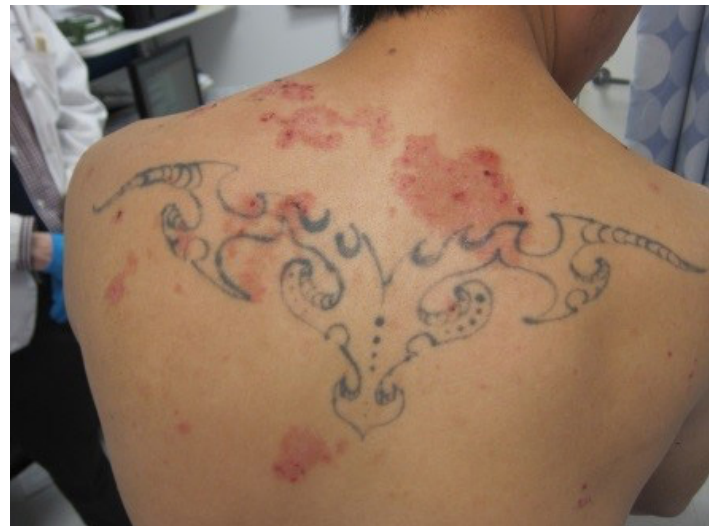

Figure 1. Upper back with scattered, erythematous patches with overlying erosions

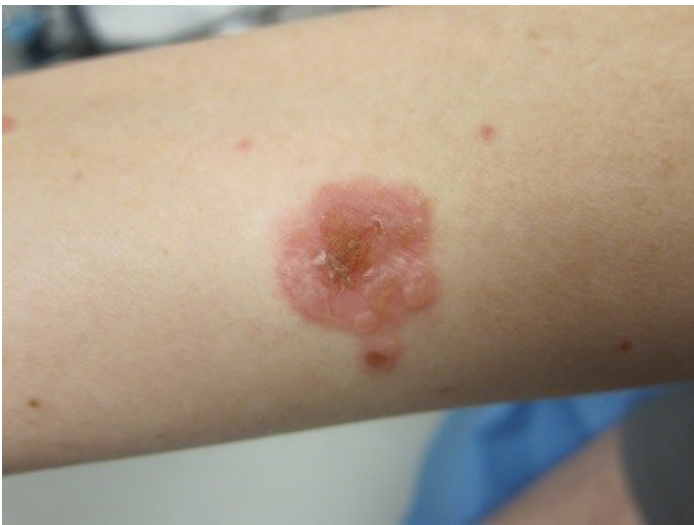

Figure 2. Ventral forearm with central erosion and vesicles at the periphery

that is characterized by autoantibodies targeting type VII collagen. Type VII collagen is located in the basement membrane and is the major component of anchoring fibrils, which serve as adhesion structures that connect the papillary dermis to the lamina densa [1]. Type VII collagen is found not only in skin, but also in the basement membrane of cornea, oral mucosa, cervix, esophagus, colon, anus, and chorioamnion [2]. The prevalence of EBA is estimated at 0.2 per one million people [3]. Although no racial or gender predominance has been identified, EBA may have a higher prevalence in Korean populations [4]. Most cases of EBA begin between the fourth and fifth decades, but there have been cases reported in pediatric patients [5].

The clinical presentation of EBA can be divided into classical, non-inflammatory EBA and various inflammatory subtypes, including bullous pemphigoid (BP)-like EBA, cicatricial pemphigoid-like EBA, linear IgA bullous dermatosis (LABD)-like EBA, and Brunsting-Perry pemphigoid-like EBA. The two most common presentations are the classical non-inflammatory EBA and the BP-like EBA [1, 3].

Classical EBA is a mechanobullous disease characterized by skin fragility over trauma-prone surfaces [1, 3]. Patients with this form of the disorder typically present with erosions, vesicles and bulla without surrounding inflammation, milia, pigmentary alterations, and scars on the dorsal surface of hands, elbows, knees, sacral area and feet. In very severe

cases, esophageal strictures and digital contractures may occur [1, 3, 6-7]. In contrast, patients with the BP-like EBA present with vesiculobullous eruptions that are more widespread, involving trunk, intertriginous areas, and extremities. The bullae are tense and surrounded by erythema and/or urticaria. These patients often lack scarring, milia and skin fragility [1, 3].

The exact inciting factors that lead to EBA are unknown. There may be an association between EBA and inflammatory bowel disease (IBD) as collagen VII is also found in the basement membrane zone of the colon. In the United States, approximately 25% of EBA patients also have IBD. However, in Korean populations with EBA, IBD is a rare occurrence [1, 8-9].

The diagnosis of EBA can be challenging as it shares clinical and histopathologic characteristics with other blistering diseases. On hematoxylin and eosin, a biopsy of classical noninflammatory EBA shows a subepidermal split with minimal inflammation. In contrast, the inflammatory variants have an infiltrate composed of neutrophils, eosinophils, and lymphocytes [1, 3, 10]. A perilesional biopsy should be taken for direct immunofluorescence (DIF) microscopy, which should show linear deposits of IgG and complement at the dermoepidermal junction [10-12]. On direct salt-split skin immunofluorescence, there are immunodeposits on the dermal side, helping to differentiate EBA from bullous pemphigoid.

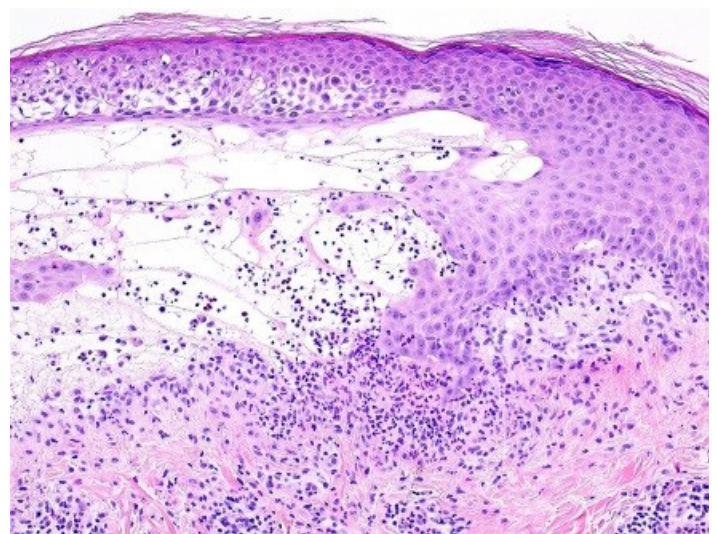


Figure 3. There is a subepidermal vesicle within which are numerous neutrophils and eosinophils in addition to a perivascular and interstitial mixed cell infiltrate of lymphocytes, neutrophils and eosinophils

Enzyme-linked immunosorbent assays (ELISAs) testing for serum antibodies to collagen VII can also be used to help confirm a diagnosis of EBA as they have both a high specificity and sensitivity, at 98.1% and 91.8% to 96.8%, respectively [1, 13].

EBA is often recalcitrant to therapy and requires multiple therapeutic modalities. Colchicine and dapsone can be used alone or in combination [1, 3, 14-15]. Systemic glucocorticoids appear to be more effective in inflammatory variants of EBA but their myriad of adverse effects limit their long-term use [3]. Both rituximab and immunoglobulin therapy (IVIg) have been used successfully in patients with severe EBA [1, 3, 16-19]. Other therapies that have been tried with varying success are high-dose cyclosporine (>6 mg/kg), methotrexate, azathioprine, and cyclophosphamide [1, 3]. Aside from pharmacologic therapy, all patients with EBA require proper wound care. Since EBA can affect ocular and gastrointestinal mucosa, a thorough review of systems should be done at each visit.

In regards to our patient, he has been closely followed in our clinic. On his initial visit, he was started on a course of prednisone that continues to be slowly tapered. Additionally, he is currently on topical corticosteroids, mycophenolate mofetil 1500 milligrams twice daily, and dapsone 100 milligrams daily. He has also received two rituximab infusions and two IVIg infusions. With these interventions, the patient has drastically improved compared to initial presentation, although sparse new vesicle and bulla formation continues.

References

- Kim JH, Kim SC. Epidermolysis bullosa acquisita. *J Eur Acad Dermatol Venereol* 2013; 27: 1204. [PMID: 23368767].
- Sakai LY, Keene DR, Morris NP, Burgeson RE. Type VII collagen is a major structural component of anchoring fibrils. *J Cell Biol* 1986; 103: 1577–1586. [PMID: 3771648].
- Gupta R, Woodley DT, Chen M. Epidermolysis bullosa acquisita. *Clin dermatol* 2012; 30:609. [PMID: 22137228].
- Lee CW. Prevalences of subacute cutaneous lupus erythematosus and epidermolysis bullosa acquisita among Korean/oriental populations. *Dermatology* 1998;197:187. [PMID: 9732174].
- Arpey CJ, Elewski BE, Moritz DK, Gammon WR. Childhood epidermolysis bullosa acquisita: report of three cases and review of literature. *J Am Acad Dermatol* 1991; 24:706-14. [PMID: 1869641].
- Harman KE, Whittam LR, Wakelin SH, Black MM. Severe, refractory epidermolysis bullosa acquisita complicated by an oesophageal stricture responding to intravenous immune globulin. *Br J Dermatol* 1998; 139: 1126-7. [PMID: 9990396].
- Kasperkiewicz M, Sadik CD, Bieber K, et al. Epidermolysis bullosa acquisita: From pathophysiology to novel therapeutic options. *J Invest Dermatol* 2016; 136:24-33. [PMID: 26763420].
- Kim JH, Kim YH, Kim SC. Epidermolysis Bullosa Acquisita: A Retrospective Clinical Analysis of 30 Cases. *Acta Derm Venereol* 2011; 91: 307–312. [PMID: 21394418].
- Chen M, O'Toole EA, Sanghavi J, et al. The epidermolysis bullosa acquisita antigen (type VII collagen) is present in human colon and patients with crohn's disease have autoantibodies to type VII collagen. *J Invest Dermatol* 2002; 118: 1059–1064. [PMID: 12060403].
- Weedon D. The vesicobullous reaction pattern. In: *Weedon's Skin Pathology*, 3rd ed, Elsevier Limited, Edinburgh 2010. p.123.
- Smoller BR, Woodley DT. Differences in direct immunofluorescence staining patterns in epidermolysis bullosa acquisita and bullous pemphigoid. *J Am Acad Dermatol* 1992; 27:674. [PMID: 1430385].
- Yaoita H, Briggaman RA, Lawley TJ, Provost TT, Katz SI. Epidermolysis bullosa acquisita: ultrastructural and immunological studies. *J Invest Dermatol* 1981; 76:288. [PMID: 7009764].
- Saleh MA, Ishii K, Kim YJ, et al. Development of NC1 and NC2 domains of Type VII collagen ELISA for the diagnosis and analysis of the time course of epidermolysis bullosa acquisita patients. *J Dermatol Sci* 2011; 62: 169–175. [PMID: 21482078].
- Megahed M, Scharfetter-Kochnek K. Epidermolysis bullosa acquisita- successful treatment with colchicine. *Arch Dermatol Res* 1984; 286:35-46. [PMID: 8141610].
- Cunningham BB, Kirchmann TT, Woodley DT. Colchicine for epidermolysis bullosa (EBA). *J Am Acad Dermatol* 1996; 34:781-4. [PMID: 8632074].
- Crichlow SM, Mortimer NJ, Harman KE. A successful therapeutic trial of rituximab in the treatment of a patient with recalcitrant, high-titre epidermolysis bullosa acquisita. *Br J Dermatol* 2007; 156:194-6. [PMID: 17199602].
- Sadler E, Schafleitner B, Lanschuetzer C, et al. Treatment-resistant classical epidermolysis bullosa acquisita responding to rituximab. *Br J Dermatol* 2007; 157:417-9. [PMID: 17596155].
- Kofler H, Wambacher-Gasser B, Topar G, et al. Intravenous immunoglobulin treatment in therapy—resistant epidermolysis bullosa acquisita. *J Am Acad Dermatol* 1997; 36:331-5. [PMID: 9039213].
- Caldwell JB, Yancey KB, Engler RJ, James WD. Epidermolysis bullosa acquisita: efficacy of high-dose intravenous immunoglobulins. *J Am Acad Dermatol* 1994;31:827-8. [PMID: 7929940].