

UC Irvine

UC Irvine Previously Published Works

Title

A Patient in Need of a Red Cell Exchange?

Permalink

<https://escholarship.org/uc/item/4jx5880p>

Journal

The journal of applied laboratory medicine, 6(4)

ISSN

2576-9456

Authors

Perez-Alvarez, Ingrid
Crews, Bridgit O
Woo, Jennifer S
et al.

Publication Date

2021-07-01

DOI

10.1093/jalm/jfaa159

Peer reviewed

■ A Patient in Need of a Red Cell Exchange?

Ingrid Perez-Alvarez, Bridgit O. Crews,* Jennifer S. Woo, Sherif Rezk, and Minh-Ha Tran

CASE DESCRIPTION

A 33-year-old man presented to an outside emergency department with right sided weakness and vision loss. The patient had a reported history of sickle cell disease, and prior history of stroke. A head computed tomographic scan showed possible left occipital infarct, and probable old lacunar infarct, with no hemorrhage. In this setting, the patient was transferred to our medical center for emergent red cell exchange, a first-line therapeutic modality for treatment of acute stroke in the setting of sickle cell disease.

Upon arrival, laboratory findings were relatively normal (Table 1). Aside from mild anemia the remainder of a complete blood cell count was normal. Basic chemistries were within normal limits. There was no reticulocytosis and other markers for hemolysis such as lactate dehydrogenase (LDH) and haptoglobin were within normal limits. Peripheral smear showed no sickle cells or evidence of hyposplenism. Limited red cell phenotyping showed mixed field reaction, suggesting recent transfusion. The incompatibility of the basic laboratory findings with diagnosis of sickle cell crisis prompted stat hemoglobinopathy screening, which was performed the same day. An initial sickle solubility screen (sickledex, STRECK) was positive; however, high-pressure liquid

chromatography (HPLC) (D-10, Bio-Rad) did not confirm the presence of hemoglobin S (HbS) (Fig. 1).

DISCUSSION

Sickle cell disease is a group of disorders in which abnormal HbS is present in the blood. HbS is characterized by the substitution of valine for glutamic acid at position 6 in the beta-globin chain. When deoxygenated, HbS aggregates within erythrocytes due to hydrophobic interactions, which results in distortion (sickling) of red blood cells and hemolysis. The sickled red blood cells are observed in a peripheral blood smear.

When only one copy of the beta-globin gene contains the HbS mutation, the condition is defined as sickle cell trait (HbAS), which is relatively indolent owing to modest levels of HbS (<40%) and higher levels of normal HbA (>60%). Sickle cell trait is not associated with chronic hemolysis, and a peripheral blood smear should not contain sickled cells. In states where no HbA is produced, such as the homozygous state HbSS or heterozygous state HbS/beta zero thalassemia ($S\beta^0$), which is caused by mutations in the hemoglobin subunit beta (HBB) gene that result in complete loss of production HbA, the outcome is severe sickle cell

Department of Pathology and Laboratory Medicine, University of California Irvine School of Medicine, Orange, CA.

*Address correspondence to this author at: Department of Pathology and Laboratory Medicine, University of California Irvine School of Medicine, 101 The City Dr., Orange, CA 92868. Fax 714-456-2975; e-mail crewsb@hs.uci.edu.

Received June 15, 2020; accepted August 17, 2020.

DOI: 10.1093/jalm/jfaa159

© American Association for Clinical Chemistry 2020. All rights reserved.
For permissions, please contact: journals.permissions@oup.com.

Table 1. The patient's presenting laboratory results with abnormal results flagged.

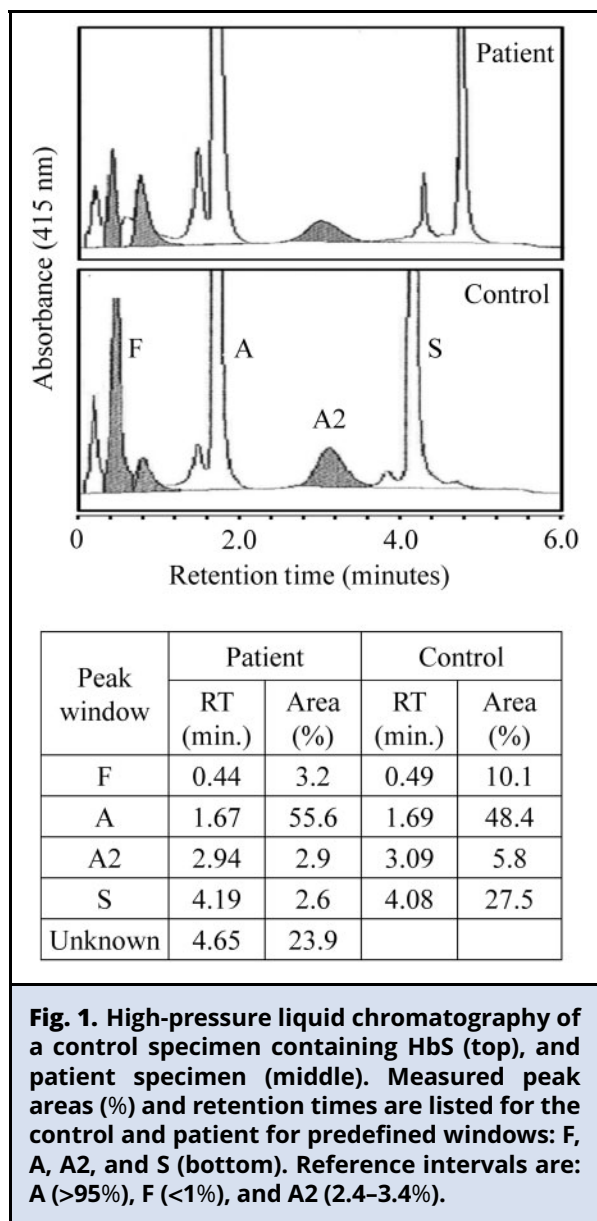
Laboratory (unit)	Result	Reference Interval
Total Bilirubin (mg/dL)	0.4	0.0–1.4
Direct Bilirubin (mg/dL)	0.1	0.0–0.2
Haptoglobin (mg/dL)	78	44–215
LDH (U/L)	220	140–271
Ferritin (ng/mL)	11	23–233
WBC (K/ μ L)	6.4	4.0–10.5
RBC (M/ μ L)	3.26 H	3.70–5.00
Hemoglobin (g/dL)	9.8 L	13.5–16.9
Hematocrit (%)	29.7 L	39.5–50.0
MCV (fL)	91.3	81.5–97.0
RDW-CV (%)	20.1 H	11.6–14.4
Platelet (K/ μ L)	352	150–400
Reticulocyte count (%)	1.7	0.8–2.5
Limited red cell phenotype		
Antigen	Result	
C	1+ mixed field	
E	1+ mixed field	
c	4+ strong	
K	0 (negative)	

anemia (SCA). Compound heterozygous states such as HbS/beta plus thalassemia (S β +), resulting from HBB gene mutations that reduce production of HbA, as well as compound heterozygous states with other variant hemoglobins (i.e., HbSC, and others), have a more variable clinical course, and are referred to as sickle cell disease (SCD). Clinical features of SCA typically become apparent within the first few months of life as the percentage of fetal hemoglobin (HbF) decreases, and the percentage of HbS increases. Clinical complications include vaso-occlusive crises, vascular complications, end-organ dysfunction, and hemolytic anemia of varying degrees of severity (1). Autosplenectomy typically occurs early in the course of the disease and evidenced by nucleated red blood cells and Howell–Jolly bodies in a peripheral blood smear.

Chronic hemolytic anemia of SCA may be marked by acute exacerbations with decreased haptoglobin, increased LDH, and increased bilirubin. Other abnormalities expected during sickle vaso-occlusive crises or in the setting of chronic hemolytic anemia due to SCD include severe anemia defined by Hb <9 g/dL, and an elevated reticulocyte percentage. Iron overload with hyperferritinemia may also be present as a consequence of chronic transfusion therapy. Key indications for red cell exchange in SCD, as defined by the American Society for Apheresis (ASFA) 2019 Guidelines include acute stroke, severe acute chest syndrome, and, in the nonacute setting, stroke prophylaxis/iron overload prevention (2). Red cell exchange as opposed to simple transfusion leads to a replacement of the majority of HbS containing endogenous red cells by HbA containing donor red cells.

Newborn screening of SCD, which is mandated in all 50 states, leads to establishing the diagnosis in most patients; however, gaps still exist. Due to lack of screening or limited access to health care, some individuals may not be diagnosed until they reach later childhood or adulthood (3). Depending on clinical situation, diagnosis of SCD is achieved by a combination of techniques including solubility testing, chromatography, electrophoresis, and molecular testing (4).

In the setting of SCD, electrophoresis or chromatography should reveal HbS, slightly elevated HbF, and low levels or absence of HbA. HbF may be moderately increased in the case of hereditary persistence of fetal hemoglobin or the setting of hydroxyurea therapy, which induces HbF production. HbA can be present in SCD as a result of recent transfusions. The presence of HbA at lower concentrations (5–30%) is also an expected finding in cases of sickle cell beta thalassemia, which may also manifest an increased HbA2 on hemoglobin electrophoresis and is typically accompanied by microcytic red cell morphology. HbSC



disease may be diagnosed by electrophoresis demonstrating the presence of roughly equal amounts of HbS and HbC, with no HbA present. In the setting of HbSC disease, a peripheral blood smear should contain sickled cells and HbC crystals, and target cells may also be observed. Due to the overlap of HbC with other variant hemoglobins in electrophoresis, multiple

techniques may be needed to distinguish HbSC disease from other compound heterozygous states, or to differentiate homozygous HbCC (hemoglobin C disease) from HbC/beta zero thalassemia (C β^0) (5, 6).

In this case, the patient’s circulating Hb was comprised predominantly of HbA and an unknown, variant Hb with a peak area of 24%, eluting in the HbC window, and no HbS (Fig. 1). There is a very small peak eluting in the HbS window that likely arises from a glycosylated form of the variant hemoglobin. A similar pattern may be also observed in the case of heterozygous HbC trait, or in the case of HbC/beta thalassemia, or perhaps in HbCC post transfusion. However, in these scenarios, expected peripheral blood smear findings would include HbC crystals, target cells, and microcytic red cell morphology, with no sickle cells.

Additionally, although no HbS was detected in the patient’s blood, the patient’s solubility screen was positive for sickling hemoglobin. The solubility screen for sickling hemoglobin is performed by lysis of erythrocytes into a phosphate buffer with sodium hydrosulfite, which reduces and precipitates HbS. Solubility screening may be positive in the case of sickle cell trait or in the presence of any Hb variant containing the HbS mutation. False negative results can also occur in SCD if the percentage of HbS is sufficiently low, such as after a recent transfusion, in severe anemia, and in infants (SickleDex, Streck).

Due to the combination of positive sickle solubility test, the absence of hemolytic markers, relatively normal blood cell counts, and normal peripheral blood smear, the unknown Hb variant was preliminarily identified as HbC_{Harlem}. HbC_{Harlem} bears a compound substitution: $\beta 6\text{Glu}>\text{Val}$, $\beta 73\text{Asp}>\text{Asn}$ (6). On capillary electrophoresis, HbC_{Harlem} overlaps with HbC. The variant hemoglobin in this case had an x-axis migration of 251 on the CAPILLARYS2 (Sebia), compared with an expected x-axis migration of

252 for HbC (data not shown) (7). Some HPLC platforms or capillary isoelectric focusing may be capable of resolving HbC and HbC_{Harlem} (8). HbC_{Harlem} would be confirmed by HBB gene sequencing or mutation analysis confirming the presence of a nucleotide substitution of adenine for thymine in codon 6 and adenine for guanine in codon 73 (9). When present as a simple heterozygote, HbC_{Harlem} is a benign clinical condition clinically similar to sickle cell trait; however, when inherited as a compound heterozygote with HbC, or HbS, it has features resembling HbSC disease, or severe SCD, respectively. It is worth noting that the patient also has a slightly elevated HbF and a lower abundance of variant HbC_{Harlem}, than might be expected in a simple heterozygous state (40%) (10). Without accurate timing of transfusion events, an associated thalassemia cannot be excluded (11). In the case of an inconsistent disease course and for reasons of genetic counseling, molecular testing including sequencing of the HBB genes together with the presented protein analyses would be warranted to confirm the diagnosis.

FOLLOW-UP

The patient's neurologic examination was inconsistent and he refused to provide identification and outside pharmacy information. Neurology did not find evidence for acute stroke but recommended magnetic resonance imaging, which the patient refused. He presented multiple requests for additional intravenous pain medications, which were refused. He then left the hospital against medical advice under strong suspicion of malingering. Although the patient has a complicated medical history, he did not have an indication for an RBC exchange. Here, we describe a case where interpretation of basic testing prompted a careful clinical and laboratory investigation into an unclear diagnosis of SCD, which ultimately prevented an unnecessary RBC exchange. Accurate diagnosis of hemoglobinopathies requires multiple approaches including protein analysis and molecular testing, as well as phenotypic evidence for pathology by chemical and hematological analyses. In the acute setting of unclear diagnosis, careful interpretation of phenotypic evidence can be crucial.

TAKEAWAYS

- Hemolytic states are generally accompanied by laboratory findings such as decreased haptoglobin, increased LDH, and increased bilirubin. Hematologic findings include an elevated reticulocyte percentage, and severe anemia (defined by hemoglobin <9 g/dL prior to transfusion).
- In SCA, a peripheral blood smear should show sickled cells. Target cells and features of hyposplenism, including nucleated red blood cells or Howell-Jolly Bodies are also common findings.
- A hemoglobin solubility test will be positive in the presence of any hemoglobin variant containing the hemoglobin S (HbS) mutation, if present in sufficient quantity. Sickle cell trait will also cause a positive solubility test. False negative results can occur in SCD if the percentage of HbS is sufficiently low. This may result after recent transfusion or exchange and in severe anemia.
- HbC_{Harlem} is a rare hemoglobin variant that is difficult to distinguish from the more common HbC variant. Simple heterozygous HbC_{Harlem} is clinically unremarkable as it resembles sickle cell trait; however, compound heterozygous HbC/C_{Harlem} results in clinical features similar to HbSC disease, and compound heterozygous HbS/C_{Harlem} results in severe SCD.

Author Contributions: All authors confirmed they have contributed to the intellectual content of this paper and have met the following 4 requirements: (a) significant contributions to the conception and design, acquisition of data, or analysis and interpretation of data; (b) drafting or revising the article for intellectual content; (c) final approval of the published article; and (d) agreement to be accountable for all aspects of the article thus ensuring that questions related to the accuracy or integrity of any part of the article are appropriately investigated and resolved.

I. Perez-Alvarez, provision of study material or patients.

Authors' Disclosures or Potential Conflicts of Interest: No authors declared any potential conflicts of interest.

REFERENCES

1. Azar S, Wong TE. Sickle cell disease: a brief update. *Med Clin North Am* 2017;101:375–93.
2. Padmanabhan A, Connelly-Smith L, Aqui N, Balogun RA, Klingel R, Meyer E, et al. Guidelines on the use of therapeutic apheresis in clinical practice—evidence-based approach from the writing committee of the American Society for Apheresis: the eighth special issue. *J Clin Apher* 2019;34:171–354.
3. Sarat CN, Ferraz MB, Ferreira Júnior MA, Corrêa Filho RA, Souza AS, Cardoso AI, et al. Prevalence of sickle cell disease in adults with delayed diagnosis. *Acta Paul Enferm* 2019;32:202–9.
4. Greene DN, Vaughn CP, Crews BO, Agarwal AM. Advances in detection of hemoglobinopathies. *Clin Chim Acta* 2015; 439:50–7.
5. O’Keeffe EK, Rhodes MM, Woodworth A. A patient with a previous diagnosis of hemoglobin S/C disease with an unusually severe disease course. *Clin Chem* 2009;55: 1228–31.
6. Steinberg MH, Chui DHK. HbC disorders. *Blood* 2013; 122:3698.
7. Riou J, Szuberski J, Godart C, Wajcman H, Oliveira JL, Hoyer JD, Bardakjian-Michau J. Precision of CAPILLARYS 2 for the detection of hemoglobin variants based on their migration positions. *Am J Clin Pathol* 2018;149: 172–80.
8. Mario N, Baudin B, Aussel C, Giboudeau J. Capillary isoelectric focusing and high-performance cation-exchange chromatography compared for qualitative and quantitative analysis of hemoglobin variants. *Clin Chem* 1997;43:2137–42.
9. Luo H-y, Adewoye A H, Eung S H, Skelton T P, Quillen K, McMahon L, et al. A Novel Sickle Hemoglobin: Hemoglobin S-South End. *Journal of Pediatric Hematology/oncology* 2004;26:773–6.
10. Bookchin RM, Nagel RL, Ranney HM, Jacobs AS. Hemoglobin C Harlem: a sickling variant containing amino acid substitutions in two residues of the beta-polypeptide chain. *Biochem Biophys Res Commun* 1966; 23:122–7.
11. Steinberg MH. Alpha thalassemia in adults with sickle-cell trait. *Br J Haematol* 1975;30:337–42.