

UC Irvine

Western Journal of Emergency Medicine: Integrating Emergency Care with Population Health

Title

Reentrant Supraventricular Tachycardia in a Pediatric Trauma Patient Masquerading as a Cardiac Contusion

Permalink

<https://escholarship.org/uc/item/4jz9526v>

Journal

Western Journal of Emergency Medicine: Integrating Emergency Care with Population Health, 6(4)

ISSN

1936-900X

Authors

Bradbum, Christopher
Westfall, Ryan
McPheeters, Rick

Publication Date

2005

Peer reviewed

Reentrant Supraventricular Tachycardia in a Pediatric Trauma Patient Masquerading as a Cardiac Contusion

Christopher Bradbum, DO
Ryan Westfall, DO
Rick McPheeters, DO
*Department of Emergency Medicine
Kern Medical Center
Bakersfield, California*

Correspondence:

Rick McPheeters, DO, FAAEM
Residency Director
Department of Emergency Medicine
Kern Medical Center
Bakersfield, CA 93305
rlmcpheeters@mac.com
661.326.2160

Previously presented at Kern Medical Center research forum 2004.

ABSTRACT

Establishing the etiology of tachycardia in a trauma patient is often difficult. Pediatric trauma patients present an even tougher challenge. Cardiac contusion should be suspected when other more common traumatic injuries that produce hypoxia and blood loss are excluded. The diagnosis of cardiac contusion is notoriously difficult to make largely due to the controversy over the definition of the disease, and the lack of a true gold standard confirmatory test. Atrioventricular nodal reentrant tachycardia (AVNRT) is a common form of supraventricular tachycardia (SVT) that can also present a diagnostic challenge to emergency physicians. While electrophysiologic studies are the gold standard for confirming the diagnosis, there are certain aspects of the history, electrocardiogram (ECG), and responses to cardiac maneuvers that strongly suggest the diagnosis. We present the case of a pediatric trauma patient that presented with new onset AVNRT masquerading as cardiac contusion.

INTRODUCTION

Tachycardia in a trauma patient is often an ominous sign. Emergency physicians (EPs) must employ a broad differential diagnosis when attempting to identify the etiology of tachycardia in the trauma setting. At the same time, EPs must remain focused on the common causes of tachycardia that are associated with high morbidity and mortality, such as intra-abdominal bleeding or blunt chest trauma.

The incidence of blunt chest injury has been on the rise for the past several years, probably as a result of increased number of motor vehicle accidents.¹ Evidence of blunt chest injury can be subtle at the time of presentation, making clinical suspicion the key to diagnosis.² Further complicating matters in the pediatric population is the fact that the bony thorax of children is less mineralized than that of adults, making it possible to have serious pulmonary or cardiac injuries without associated bony injury.³ Blunt cardiac injuries, including cardiac contusions, can have serious sequelae such as dysrhythmia, myocardial infarction, cardiac rupture, formation of aneurysm, or cardiac tamponade.⁴ There is no gold standard test to confirm the presence of a blunt cardiac injury. Instead, a combination of clinical signs and symptoms, electrocardiographic (ECG) changes, elevation of cardiac enzymes, and echocardiogram are used to confirm the diagnosis.^{2,5}

Supraventricular tachycardia (SVT) includes all tachyarrhythmias that originate above the bifurcation of the bundle of His in a reentrant circuit. Atrial rates by definition must be above 100 beats per minute, although the ventricular rate may be less if the conduction is incomplete. SVT usually has a narrow QRS complex, but it may be wide due to abhorrent conduction, presence of an accessory pathway, or when there is a coexistent bundle branch block.⁶ SVT is further classified as paroxysmal, persistent, or chronic. Paroxysmal supraventricular tachycardia (PSVT) may be caused by AV nodal reentry, Wolff-Parkinson-White (WPW) syndrome, or intra-atrial or sino-atrial reentry. The most common form of PSVT is due to AV nodal reentry.⁶ While electrophysiologic testing is the gold standard for identification of the various PSVT subtypes, there are

specific electrocardiographic (ECG) criteria, as well as important clues in the historical data, and responses to cardiac maneuvers that can aid the EP in making the correct diagnosis.⁷

We present the case of a trauma patient that presented with new onset AVNRT masquerading as cardiac contusion, with a discussion of the clinical differentiation between the two entities.

CASE REPORT


An eight-year-old male riding a bicycle was brought to our emergency department after being struck by a car at moderate speed. The EMT reported that the patient was hemodynamically stable during transport. He had a questionable brief loss of consciousness on scene, but had a Glasgow Coma Scale of 15. Paramedics also noted an obvious right tibia and fibula deformity. Upon arrival to the emergency department the patient was conversant. His airway was intact with unlabored respirations at a rate of 26 breaths per minute and an oxygen saturation of 98% on room air. There were no outward signs of chest trauma. Breath sounds were clear to auscultation bilaterally. Heart rate was 83 beats per minute (bpm) and blood pressure was 121/74 mmHg. Cardiac auscultation was normal. The patient had an obvious tibia and fibula fracture on the right with good distal neurovascular function. There was no active external bleeding. Secondary survey was significant for large abrasion to the left ear and a large left occipital cephalohematoma. The patient had no signs of trauma to the chest, and was non-tender across the bony thorax. The abdomen was soft and non-tender, with no outward signs of trauma. A focused abdominal sonogram for trauma (FAST) was performed and was negative for intraperitoneal or pericardial fluid. The Glasgow Coma Scale was 15, although the patient was s o m e w h a t uncooperative and a g i t a t e d intermittently. The remainder of the physical exam was unremarkable.

Routine laboratory studies were

ordered. Radiographs of the cervical spine, chest and pelvis were normal. Radiographs of the right lower extremity showed a comminuted right tibia and fibula fracture. Computed axial tomography of the head, abdomen and pelvis were normal. The orthopedic service was consulted for the patient's fracture. The patient was given morphine sulfate for pain. The patient subsequently complained of nausea and was administered 12.5 mg of promethazine. A short time later the patient became agitated, restless, and tachycardic to a rate of 150-160 bpm. Blood pressure remained normal. Due to concern of the possibility of occult abdominal bleeding, a repeat FAST exam was performed and remained negative. Repeat hemoglobin and hematocrit was unchanged. Diphenhydramine was administered for suspected akathisia, and a short time later the tachycardia and agitation resolved.

The patient was admitted to the trauma service with a diagnosis of pedestrian versus auto with lower extremity fracture, closed head injury, and rule out blunt abdominal trauma. Once admitted, the patient continued to have runs of tachycardia with a rate of 130-160 bpm. The rhythm appeared to be SVT on telemetry strips (Figure 1). The tachycardia was easily terminated with carotid massage. The patient experienced palpitations during the episodes of tachycardia, but was otherwise asymptomatic.

The possibility of a cardiac contusion was entertained. Resting 12-lead ECG initially demonstrated a junctional rhythm (Figure 2). Six minutes later, a repeat 12-lead ECG demonstrated normal sinus rhythm (Figure 3). Troponin I level was elevated at 1.9 ng/ml. A transthoracic three-dimensional echocardiogram was performed which did not show any evidence of blunt cardiac injury. Pediatric electrophysiology consultation was obtained. The electrophysiologist noted evidence



Telemetry Strip of an 8 year old trauma patient demonstrating supraventricular tachycardia.

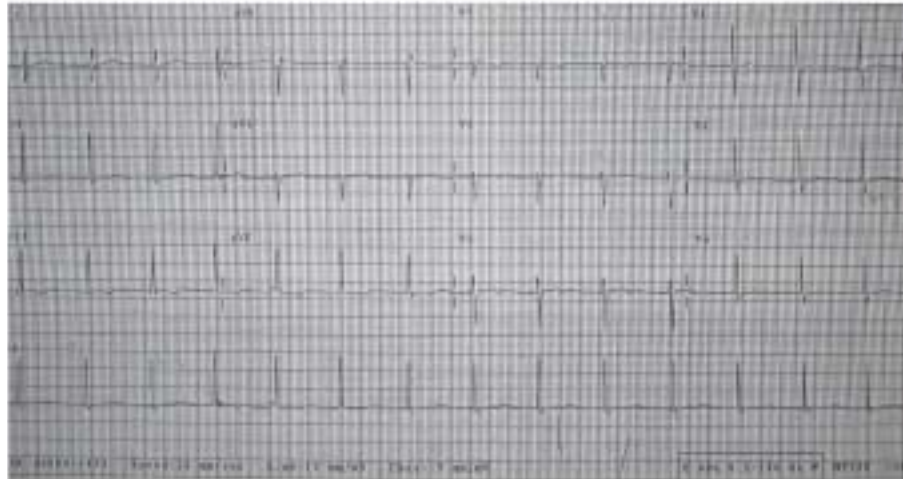
of an atypical AV nodal reentry tachycardia, not considered to be sequelae of blunt cardiac injury. The consultant recommended that the patient be started on flecainide only if symptomatic. Since the patient was experiencing palpitations, he was started on flecainide 50 mg twice daily.

The next day the patient's extremity fracture was operatively repaired by orthopedics. The remainder of his hospital course was uneventful. The patient did not experience any further episodes of tachycardia. On follow-up appointment with pediatric cardiology, the patient was doing well with no further episodes of palpitations. The patient was subsequently lost to further follow-up.

DISCUSSION

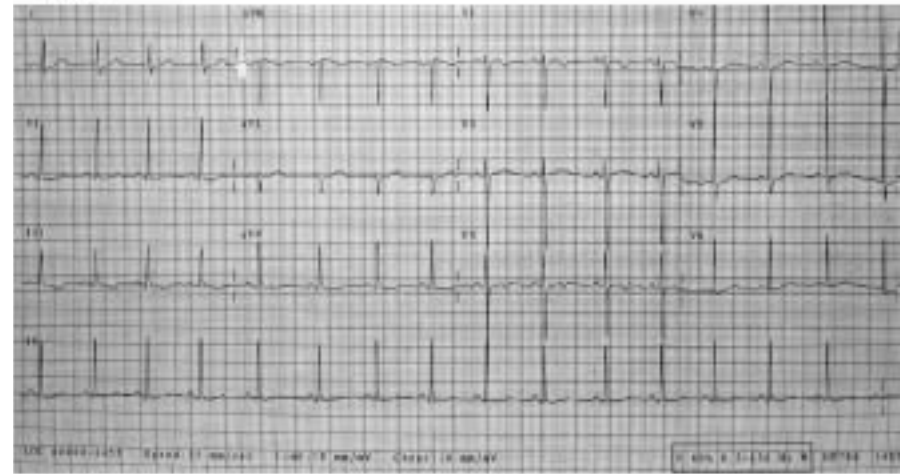
AVNRT is the most common form of PSVT. One third of adolescent cases of PSVT will be secondary to AVNRT.^{8,9} Although rarely life threatening, AVNRT can have significant associated symptoms which can interfere with quality of life.¹⁰ The mechanism of AVNRT is known to be the result of a dual atrial pathway proximal to the AV node that causes rapid conduction through the AV node itself. In contrast, pre-excitation syndromes, such as WPW, rely on an accessory pathway to produce tachycardia by bypassing the AV node.⁶ The reentry circuit is initiated when a premature atrial beat approaches the AV node during a refractory period. This causes an impulse to be conducted in an anterograde fashion via a slow pathway located in the anterior AV node. Simultaneously, a faster pathway in the posterior AV node conducts in a retrograde fashion.^{11,12} The impulses created by the pathways are conducted to the ventricles via the His bundle and then to the right and

Figure 2



Resting electrocardiogram demonstrating a junctional rhythm.

Figure 3

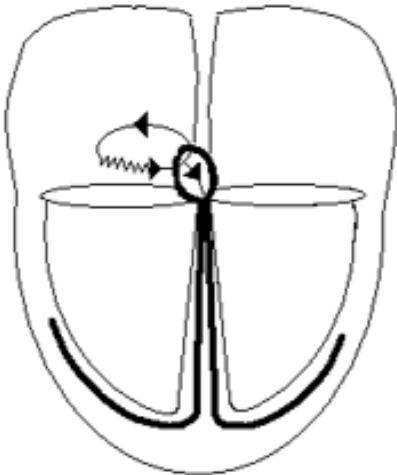


Resting electrocardiogram of an 8 year old trauma patient demonstrating normal sinus rhythm.

left bundle branches (Figure 4). This pattern will continue until the circuit is disrupted. Since the circuit depends on the conduction properties of the AV node itself, vagal maneuvers and medications that block AV conduction, such as adenosine, are usually successful in halting the tachycardia.¹⁰

Electrophysiologic studies are the gold standard for defining the mechanism of SVT, but they are rarely needed to establish the diagnosis. The electrocardiogram is the EP's best diagnostic tool when it comes to diagnosis of PSVT. Studies have attempted to define ECG criteria for diagnosis of the different forms of PSVT, but none have been shown to be highly sensitive or specific.⁷ There are certain

Figure 4



Diagrammatic illustration of a typical AV nodal reentry circuit near the AV node with retrograde conduction via fast pathway and anterograde conduction via a slower, anterior pathway (depicted by wavy line).

characteristics that will favor the diagnosis of reentrant tachycardia.

AVNRT will stop and start suddenly. Since the atria are activated just after the ventricles, the P waves are usually buried in the QRS and are not visible on ECG tracing. Other ECG characteristics of AVNRT are narrow QRS with a usual rate of 160-190 bpm. Often times a "pseudo S" wave can be seen in the inferior leads (Figure 5). This pseudo S wave is the result of ST segment distortion from the conduction of the retrograde P waves. A pseudo R' can also be seen in lead V1 during the tachycardia which is not present during times of normal conduction.¹³

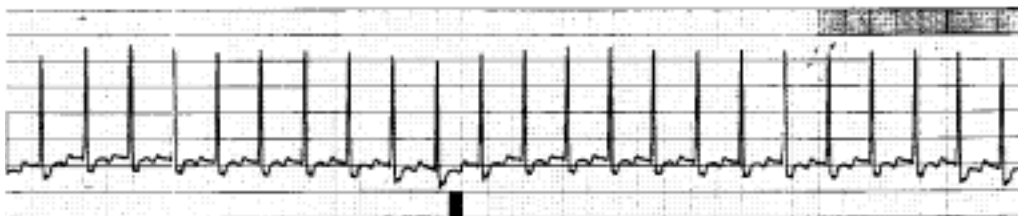
Cases of AVNRT that are asymptomatic do not require any specific therapy.¹⁴ Patients can be taught vagal maneuvers to self terminate episodes.¹⁰ Patients with moderate or frequent symptoms may benefit from drug therapy. Digoxin, beta-blockers, and calcium channel blockers have all been used with some success. Care must be used to rule out the possibility of WPW

syndrome prior to administration of calcium channel blockers. Patients with severe or incessant symptoms are candidates for catheter ablation. Recent advances in ablation techniques have made ablation a very low risk first line therapy. In fact, one recent study concluded that catheter ablation is 43% more cost effective than medical management over the long term, with lower morbidity and mortality.¹⁵

Although blunt cardiac injury lacks a diagnostic gold standard, and the clinical effects can be broad, retrospective analysis of this case does not support the diagnosis. Our patient had a complete absence of chest wall abrasions or contusions during his initial and subsequent evaluations. Many authors agree that isolated blunt cardiac and pulmonary injuries can occur without concomitant bony fracture due to decreased mineralization of the pediatric chest wall; however, one large multi-center analysis found that isolated blunt cardiac injury was rare.^{16,2} Our patient displayed a mild increase in troponin to a level of 1.9 ng/ml. While no strict criteria have been established, Hirsch et al. found that troponin levels can be as high as 2.0 ng/ml in healthy children.¹⁷ Furthermore, the increased cardiac workload associated with AVNRT has been shown to cause a mild increase in the troponin level.¹⁸ Finally, our patient did not show any evidence of cardiac wall dysfunction or valvular damage on echocardiogram.

The historical, clinical, and electrocardiographic data confirm that this patient's tachycardia was the result of an AV nodal reentrant circuit (Table 1). Episodes were sudden in onset and termination. On ECG the heart rate was generally 160-180 bpm, QRS complexes were narrow with no discernable P waves, and a pseudo S wave was noted in inferior leads.

Figure 5



Telemetry strip demonstrating a pseudo S wave which is the result of p waves buried within the QRS complexes.

Finally, the episodes were easily terminated with carotid massage.

In conclusion, pediatric trauma patients with tachycardia can present a significant diagnostic challenge to emergency physicians. In cases where the etiology is not easily explained, 12-lead ECG should be obtained and closely scrutinized for evidence of reentrant or accessory pathways.

REFERENCES

1. Eshel G, Gross B, Bar-Yochai A, Azizi E, Mundel G. Cardiac injuries caused by blunt chest trauma in children. *Pediatric Emergency Care* 1987;3:96-8.
2. Dowd MD, Krug S. Pediatric blunt cardiac injury: Epidemiology, clinical features and diagnosis. *J of Trauma* 1996;40:61-67.
3. Nakayama DK, Ramenofsky ML, Rowe MI. Chest injuries in childhood. *Annals of Surgery* 210:770-5.
4. Waxman K, Soliman MH, Braunstein P, et al. Diagnosis of traumatic cardiac contusion. *Arch Surg* 1986;121:689-92.
5. Langer JC, Winthrop AL, Wesson DE, Spence LJ. Diagnosis and incidence of cardiac injury in children with blunt thoracic trauma. *J Pediatric Surgery* 1989;24:1091-94.
6. Fuster V, Alexander RW, O'Rourke RA. 2001. *Hurst's the heart*. 10th ed. USA: McGraw-Hill; 809-817p.
7. Pollack ML, Brady WJ, Chan TC. Electrocardiographic manifestations: Narrow QRS complex tachycardias. *J of Emergency Med* 2003;24:35-43.
8. Ko JK, Deal BJ, Strasburger, Benson WD. Supraventricular tachycardia mechanisms and their age distribution in pediatric patients. *Am J of Cardiology* 1992;69:1028-32.
9. Crossen JE, Hesslein PS, Thilenius OG, Dunnigan A. AV node reentry tachycardia in infants. *PACE* 1995;18:2144-9.
10. Balaji S. Supraventricular tachycardia in children. *Curr Treat Options in Cardiovasc Med* 2000;2:521-28.
11. Moss, Adams. *Heart disease in infants, children, and adolescents*. 6th edition. Lippincott Williams and Wilkins 2001:502-33.

	Cardiac Contusion	AVNRT
Onset	Variable	Sudden
Rate	Variable	160-180 bpm
Echocardiographic findings	Wall motion abnormalities Valvular dysfunction	Absent
Troponin I level	Elevation (>2 ng/ml)	Possible elevation (Normal – 32 µg/l)*
ECG changes	Sinus tachycardia Nonspecific ST segment changes Supraventricular tachyarrhythmias Ventricular arrhythmias, including fibrillation	P waves absent Narrow QRS complex Pseudo S wave in inferior leads Pseudo R' in V1

Table 1. Comparison of cardiac contusion and AVNRT.

12. Wen Z., Chen S, Tai C, Chiang C. Electrophysical mechanisms and determinants of vagal maneuvers for termination of paroxysmal supraventricular tachycardia. *Circulation* 1998;98:2716-23.
13. Kalbfleish SJ et al. Differentiation of paroxysmal narrow complex tachycardias using the 12-lead electrocardiogram. *J of Am Col of Cardiology* 1993;21:85-9.
14. Kugler JD, Danford DA. Management of infants, children, and adolescents with paroxysmal supraventricular tachycardia. *J Pediatrics* 1996;129:324-38.
15. Garson A, Kanter RJ. Management of the child with Wolff-Parkinson-White syndrome and supraventricular tachycardia: Model for cost effectiveness. *J Cardiovascular Electrophysiology* 1997 Nov;8(11):1320-6.
16. Nakayama DK, Ramenofsky ML, Rowe MI. Chest injuries in childhood. *Ann Surg* Dec;210(6):770-5
17. Hirsch R, Landt Y, Porter S, Canter CE, Jaffe AS, Ladenson JH, Grant JW, Landt M. Cardiac troponin I in pediatrics: normal values and potential use in the assessment of cardiac injury. *J Pediatr* 1997 Jun;130(6):872-7.
18. Zellweger MJ, Schaer BA, Cron TA, Pfisterer ME, Osswald S. Elevated troponin levels in absence of coronary artery disease after supraventricular tachycardia. *Swiss Med Wkly* 2003 Aug 9;133(31-32):439-41.