

Case Presentation

Dermatitis herpetiformis

John Montgomery Yost MD MPH, Christopher S. Hale MD, Shane A. Meehan MD, and Beth N. McLellan MD

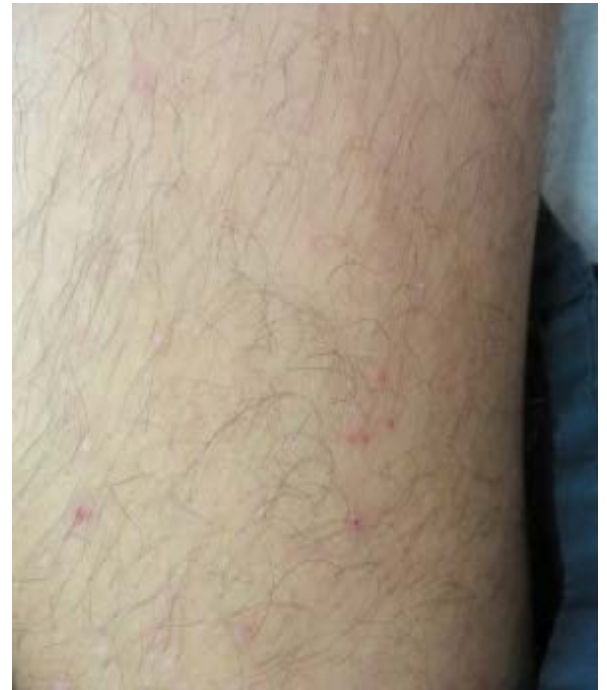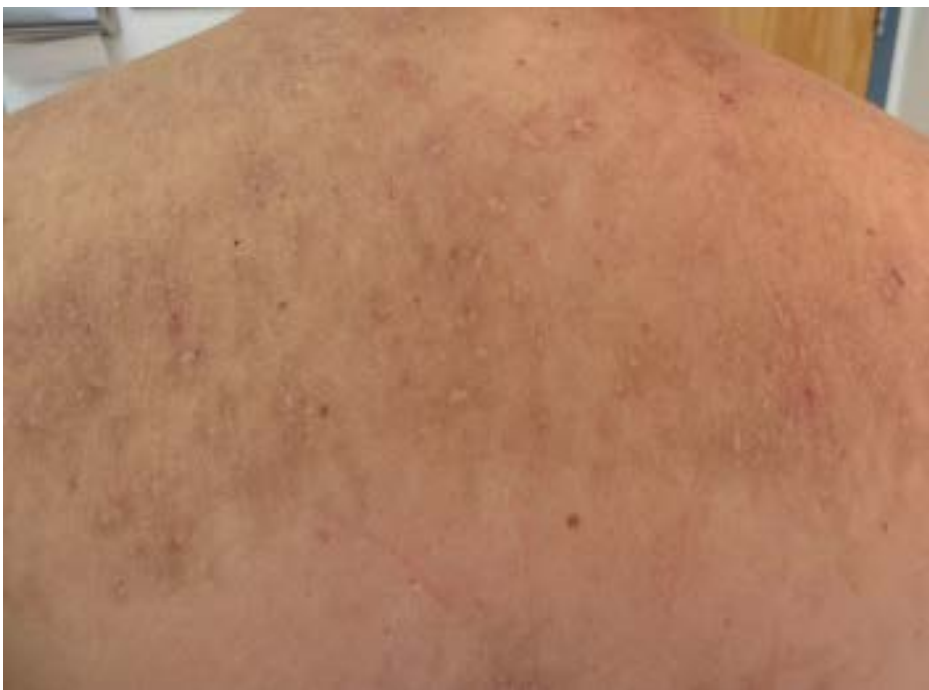Dermatology Online Journal 20 (12): 14

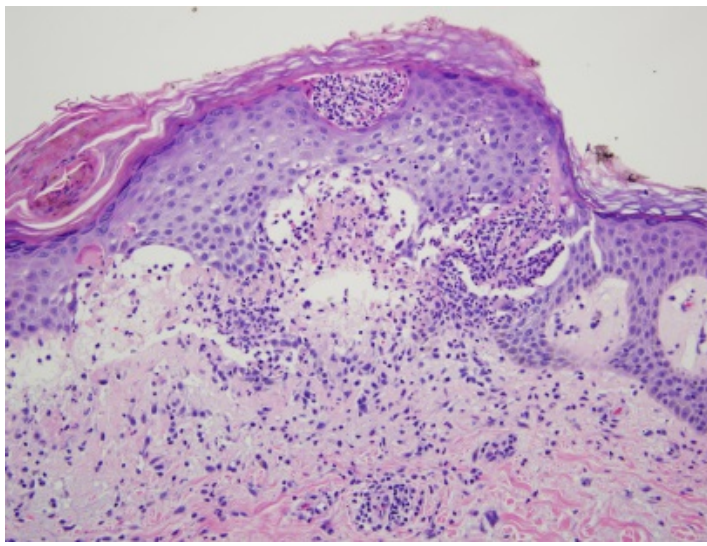
New York University School of Medicine

Special Guest Editor: Nicholas A. Soter, MD

Abstract

Dermatitis herpetiformis (DH) is an autoimmune bullous disease, which represents the cutaneous manifestation of gluten sensitivity, in the setting of celiac disease. Although classical DH is characterized clinically by grouped, vesicles on an erythematous base, primary lesions often are absent owing to the intense, associated pruritus. Instead, many cases present only with erythematous erosions with numerous overlying excoriations. As in celiac disease, the core pathogenic mechanisms of DH are likely mediated by immunoglobulin A class autoantibodies against one of several transglutaminase enzymes. As the production of these autoantibodies is directly correlated with gastrointestinal exposure to gliadin, which is an alcohol-soluble fraction of gluten, a gluten-free diet represents the cornerstone of a DH management regimen. In cases refractory to dietary management alone, dapsone is the first-line agent for the treatment of DH, although many other agents have been anecdotally reported as effective.





Case synopsis

History: A 54-year-old man was referred to the NYU Dermatologic Associates for a nine-month history of pruritus that affected the back, arms, legs, and thighs. Past medical history included a recent unintended 20 pound weight loss, diabetes mellitus, and hypothyroidism. The patient denied any other recent changes in his health and a review of systems was negative for diarrhea, nausea, bloating, or dyspepsia.

A punch biopsy was obtained from a representative lesion on the right thigh.

Physical examination: A few, scattered, erythematous erosions with numerous overlying erythematous-to-hyperpigmented, linear excoriations and lichenification were present on the medial aspects of the thighs, back, and lateral aspects of the arms.

Laboratory data: Serum tissue transglutaminase IgA levels were 15 U/mL (normal range <6 U/mL). Serum endomysial antibody was detected at a titer of 1:20 (normal < 1:5).

Histopathology: There is a superficial, perivascular, lymphocytic infiltrate with a predominantly sub- and intraepidermal collection of neutrophils. Rare eosinophils also are noted. A periodic acid-Schiff with diastase stain fails to reveal fungal hyphae.

Discussion

Diagnosis: Dermatitis herpetiformis

Comment: Initially described by Louis Duhring in 1884, dermatitis herpetiformis (DH) is an autoimmune bullous disease, which represents the cutaneous manifestation of gluten hypersensitivity, in the setting of celiac disease [1]. Whereas DH is characterized clinically by grouped, fragile vesicles on an erythematous base, primary lesions often are absent owing to the intense, associated pruritus. Instead, many cases present only with erythematous erosions, with numerous overlying excoriations. In most cases, the disease distribution is relatively symmetric, with the extensor surfaces of the upper and lower extremities, scalp, and buttocks being the most affected areas [2]. Less commonly, DH may present with palmoplantar purpura and petechiae, with complete sparing of the dorsal aspects of the extremities [2]. Furthermore, although associated mucosal lesions are rare, emerging evidence suggests that dental abnormalities, which include pits of the enamel, are relatively common, but likely underreported [3-5].

As in celiac disease, the core pathogenic mechanisms of DH are likely mediated by immunoglobulin A (IgA) class autoantibodies against one of several transglutaminase enzymes. In celiac disease, the pathogenic autoantibody targets tissue transglutaminase (tTG), which is a ubiquitous cytoplasmic, calcium-dependent enzyme that catalyzes crosslinks between glutamine and lysine protein residues [2,6]. In the setting of celiac disease, tTG modifies gliadin, which is an alcohol-soluble fraction of gluten, into a potent autoantigen with a distinct specificity for T cell stimulation via gut-derived antigen presenting cells [2,6,7]. The resulting autoimmune response is further enhanced by highly immunogenic tTG-gliadin complexes that are formed via protein-protein cross-linking [2,6,7]. This latter mechanism appears to represent the key event in the pathogenesis of DH, with epidermal transglutaminase (eTG) acting as the primary autoantigen. In contrast to tTG, which is largely ubiquitous, eTG only occurs in the small intestine, brain, testes, and epidermis where it functions to facilitate and maintain cornified envelope integrity [2,8,9]. Whereas the relationship between the development of autoantibodies to tTG and eTG remains unclear, emerging data suggests that the two enzymes share a common epitope, which may function as the primary autoantigen [2,10,11].

Epidemiologically, DH is relatively rare, with recent data indicating an estimated incidence and prevalence of 0.98 per 100,000 people per year and 11.2 per 100,000 people, respectively [12]. Among ethnic groups, DH seems to almost exclusively occur in individuals of Northern European descent, particularly those with an HLA-DQ2 or HLA-DQ8 haplotype [2,13,14]. DH is more common in men (male to female ratios ranging from 1.5:1 to 2:1); the prevalence of celiac disease is higher in women (male to female ratio ranging from 2:1 to 4:1) [12,15,16]. In addition to other diseases on the celiac spectrum, which includes atrophic gastritis and pernicious anemia, DH does convey an increased risk for other diseases within the autoimmune diaspora [2,17]. Some anecdotal evidence has demonstrated an increased incidence of type I diabetes mellitus, autoimmune hypothyroidism, Addison disease, vitiligo, alopecia areata, Sjögren syndrome, rheumatoid arthritis, and systemic lupus erythematosus in DH but not in celiac disease [2, 17].

As in many dermatologic conditions, the diagnosis of DH requires clinicopathologic correlation, which includes clinical features, serologic tests, and a biopsy for both routine histopathologic and immunofluorescence analysis. As with most other vesiculobullous diseases, biopsy specimens obtained for histopathologic examination should include an intact vesicle. The classic histopathologic features that are associated with DH include a subepidermal cleft that contains neutrophils and a few sparse eosinophils as well as a perivascular inflammatory infiltrate, although these findings may occur in linear IgA bullous dermatosis and bullous lupus erythematosus [18,19]. Although a direct immunofluorescence analysis that shows granular deposits of IgA at the superficial most aspects of dermal papillae is pathognomonic for DH, the sensitivity of direct immunofluorescence only approaches 90% [20,21]. Since DH is now believed to represent a cutaneous manifestation of gluten intolerance, serologic testing for autoantibodies associated with celiac disease often proves vital in diagnostically challenging cases. These tests include total serum IgA, anti-tTG IgA, IgG, and anti-endomysial IgA and IgG [18].

Because DH is now regarded as a cutaneous manifestation of gluten hypersensitivity, a gluten-free diet represents the cornerstone of a DH management regimen and includes the elimination of all food, beverages, and other dietary supplements that contain wheat, barley, rye, and possibly oats. The data regarding whether oat based proteins have the potential to trigger flares of celiac disease and therefore DH remain indeterminate [18,22-24]. Dapsone, which is a sulfone-based antibiotic with anti-inflammatory properties, remains the other mainstay of the therapeutic management of DH. Dapsone inhibits neutrophil chemotaxis in addition to local tissue injury that is mediated by neutrophil and eosinophil degranulation. Almost all clinical manifestations of DH resolve within one week of initiating dapsone therapy [18,25]. Whereas this agent is generally well tolerated in most cases, rare complications and adverse events include methemoglobinemia, agranulocytosis, hemolysis, and a drug reaction with eosinophilia and systemic symptoms [18,25]. Other anecdotal reports suggest some potential efficacy of other agents, such as cyclosporine, colchicine, heparin, tetracycline, and nicotinamide [18,26-28].

References

1. Duhring LA. Landmark article, Aug 30, 1884: Dermatitis herpetiformis. By Louis Duhring. *JAMA* 1983;250:212 [PMID: 6345814]
2. Bolotin D, Petronic-Rosic V. Dermatitis herpetiformis. Part I: Epidemiology, pathogenesis, and clinical presentation. *J Am Acad Dermatol* 2011;64:1017 [PMID: 21571167]
3. Nicolas ME, *et al.* Dermatitis herpetiformis. *Int J Dermatol* 2003;42:588 [PMID: 12890100]
4. Aine L, *et al.* Coeliac-type enamel defects in patients with dermatitis herpetiformis. *Acta Derm Venereol* 1992;72:25 [PMID:1350136]
5. Aine L, *et al.* Dental enamel defects in children with dermatitis herpetiformis. *J Pediatr* 1991;118:572 [PMID:2007934]
6. Caputo I, *et al.* Tissue transglutaminase in celiac disease: role of autoantibodies. *Amino Acids* 2009;36:693 [PMID: 18600381]
7. Molberg O, *et al.* Tissue transglutaminase selectively modifies gliadin peptides that are recognized by gut-directed T cells in celiac disease. *Nat Med*1998;4:713 [PMID: 9623982]
8. Lorand L, Graham RM. Transglutaminases: crosslinking enzymes with pleotropic functions. *Nat Rev Mol Cell Biol* 2003;4:140 [PMID: 12563291]
9. Hitomi K. Transglutaminases in skin epidermis. *Eur J Dermatol* 2005;15:313 [PMID: 16172037]
10. Sardy M, *et al.* Epidermal transglutaminase (TGase 3) is the autoantigen of dermatitis herpetiformis. *J Exp Med* 2002;195:747 [PMID: 11901200]
11. Hull CM, *et al.* Elevation of IgA anti-epidermal transglutaminase antibodies in dermatitis herpetiformis. *Br J Dermatol* 2008;159:120 [PMID: 18503599]
12. Smith JB, *et al.* The incidence and prevalence of dermatitis herpetiformis in Utah. *Arch Dermatol* 1992;128:1608 [PMID: 1456754]
13. Spurkand A, *et al.* Dermatitis herpetiformis and celiac disease are both primarily associated with the HLA-DQ (alpha 1*0501, beta 1*02) or the HLA-DQ (alpha 1*03, beta 1*0302) heterodimers. *Tissue Antigens* 1997;49:29 [PMID: 9027962]
14. Marietta E, *et al.* A new model for dermatitis herpetiformis that uses HLA-DQ8 transgenic NOD mice. *J Clin Invest* 2004;114:1090 [PMID:15489956]

15. Lanzini A, *et al.* Epidemiological, clinical and histopathological characteristics of celiac disease: results of a case-finding population based program in an Italian community. *Scand J Gastroenterol* 2005;40:950
16. Llorente-Alonso MJ, *et al.* Gluten intolerance: sex and age-related features. *Can J Gastroenterol* 2006;20:719 [PMID: 17111054]
17. Kaplan RP, Callen JP. Dermatitis herpetiformis: autoimmune disease associations. *Clin Dermatol* 1991;9:347 [PMID:1806222]
18. Bolotin D, Petronic-Rosic V. Dermatitis herpetiformis. Part II: Diagnosis, management, and prognosis. *J Am Acad Dermatol* 2011;64:1027 [PMID: 21571168]
19. Caproni , *et al.* Guidelines for the diagnosis and treatment of dermatitis herpetiformis. *J Eur Acad Dermatol Venereol* 2009;23:633 [PMID: 19470076]
20. Beutner EH, *et al.* A case of dermatitis herpetiformis with IgA endomysial antibodies but negative direct immunofluorescent findings. *J Am Acad Dermatol* 2000;43:329 [PMID: 10901714]
21. Huber C, *et al.* Negative direct immunofluorescence and nonspecific histology do not exclude the diagnosis of dermatitis herpetiformis Duhring. *Int J Dermatol* 2013;52;248 [PMID: 23347314]
22. Fry L, *et al.* Long term follow-up of dermatitis herpetiformis with and without gluten dietary gluten withdrawal. *Br J Dermatol* 1982;107:631[PMID: 7171483]
23. Parnell N, *et al.* Absence of toxicity of oats in patient with dermatitis herpetiformis. *N Engl J Med* 1998;338:1470 [PMID: 9583980]
24. Reunala T, *et al.* Tolerance to oats in dermatitis herpetiformis. *Gut* 1998;43:490 [PMID: 9824575]
25. Zhu TI, *et al.* Dapsone and sulfones in dermatology: overview and update. *J Am Acad Dermatol* 2001;45:420 [PMID: 11511841]
26. Shah SA, Ormerod AD. Dermatitis herpetiformis effectively treated with heparin, tetracycline, and nicotinamide. *Clin Exp Dermatol* 2000;25:204 [PMID: 10844495]
27. Stenveld HJ, *et al.* Efficacy of cyclosporine in two patients with dermatitis herpetiformis resistant to conventional therapy. *J Am Acad Dermatol* 1993;28:1014 [PMID: 8496445]
28. Silvers DN, *et al.* Treatment of dermatitis herpetiformis with colchicine. *Arch Dermatol* 1980;116: 1373 [PMID: 7458365]