

# UCSF

## UC San Francisco Previously Published Works

### Title

Primary pulmonary undifferentiated pleomorphic sarcoma (PPUPS).

### Permalink

<https://escholarship.org/uc/item/4kj4j35s>

### Journal

Autopsy and Case Reports, 9(3)

### ISSN

2236-1960

### Authors

Nelson, Scott  
Qorbani, Amir

### Publication Date

2019

### DOI

10.4322/acr.2019.110

Peer reviewed

## Primary pulmonary undifferentiated pleomorphic sarcoma (PPUPS)

Amir Qorbani<sup>a</sup> , Scott D Nelson<sup>b</sup> 

**How to cite:** Qorbani A, Nelson SD. Primary pulmonary undifferentiated pleomorphic sarcoma (PPUPS). *Autops Case Rep* [Internet]. 2019 Jul-Sep;9(3):e2019110. <https://doi.org/10.4322/acr.2019.110>

### ABSTRACT

Undifferentiated pleomorphic sarcoma (UPS) is a high-grade pleomorphic neoplasm with no identifiable line(s) of differentiation using currently available diagnostic techniques. Therefore, it is essentially a diagnosis of exclusion, which requires generous tissue sampling, adequate contextually interpreted immunohistochemistry, and relevant molecular studies. UPS is a common soft tissue sarcoma (historically one of the entities referred to as malignant fibrous histiocytoma (MFH)), which can develop in various organs, but lung involvement is usually due to metastasis. Primary Pulmonary UPS (PPUPS) is exceptionally rare and here we present a 66-year-old man who presented with anemia and weight loss, found to have a 17 cm right lung mass with invasion to the chest wall and diaphragm. Extensive sampling and immunohistochemistry studies failed to reveal any line of differentiation. Upon exclusion of a possible extrapulmonary origin, a diagnosis of PPUPS was rendered. In addition, we reviewed all 84 previously reported cases of PPUPS/PPMFH in the literature since 1979 and summarized the clinical information.

### Keywords

Lung; Lung Neoplasms; Sarcoma; Soft Tissue Neoplasms

### INTRODUCTION

Undifferentiated pleomorphic sarcomas (UPS), one of the entities previously included in the effete diagnosis of malignant fibrous histiocytoma (MFH), most commonly occurs in deep soft tissue of extremities (thigh) of elderly patients (average 50-70 years). So-called MFH was in the past thought to be of fibrohistiocytic origin; however, further studies (electron microscopy, immunohistochemical techniques, or molecular studies) failed to demonstrate evidence of “fibrohistiocytic” differentiation. Additionally, other unrelated poorly differentiated sarcoma was included in this entity, compounding the non-specific and confusing nature of this diagnostic term. MFH was declassified by World Health Organization (WHO) in 2012, and is

no longer listed as a diagnostic entity. Many tumors previously included as MFH have been reclassified as “undifferentiated pleomorphic sarcoma”.<sup>1</sup>

Primary sarcomas in lung are rare (less than 0.5% of all lung cancers)<sup>2</sup>, and primary pulmonary undifferentiated pleomorphic sarcomas (PPUPS) are one of the least common primary lung sarcomas, with 84 reported cases in the English literature (Table 1). Weiss SW and Enzinger FM first described soft tissue MFH of 200 cases in 1978.<sup>3</sup> A year later, Bedrossian et al.<sup>4</sup> reported the first case of primary pulmonary MFH (PPMFH) in a 51-year-old man.

Yousem and Hochholzer<sup>5</sup> reported the most extensive series of primary malignant fibrous

<sup>a</sup> University of California, San Francisco (UCSF), UCSF Medical Center at Mission Bay. San Francisco, CA, United States of America.

<sup>b</sup> University of California, Los Angeles (UCLA), UCLA Santa Monica Medical Center. Santa Monica, CA, United States of America.



**Table 1.** Helpful ancillary tests to differentiate tumors with sarcomatoid features

Tumor	Immunohistochemistry	Molecular
Sarcomatoid Carcinoma (SC)	P63+, P40+, PanKeratin+, TTF1+, epithelial markers (MOC31, BerEP4, BG8, B72.3, monoclonal CEA)+	Gains at chromosomes 8q, 7, 1q, 3q, and 19. KRAS mutation, EGFR mutation
Sarcomatoid Mesothelioma	WT1+, CK5/6+, D2-40+, calretinin+	Inactivation of CDKN2A at 9p21 on PCR
Angiomatoid fibrous histiocytoma (AFH)	Desmin+/-, CD68+/-, EMA+/-	EWSR1-CREB1, EWSR1-ATF1, or FUS-ATF1 fusion
Synovial sarcoma (SS)	TLE1+, Keratin+, EMA+, S100+/-, CD56+, CD99+, Calretinin+/-	t(X;18) involving SS18 (SYT) gene
Epithelioid Sarcoma (ES)	Loss INI, EMA+, Keratin+/-, CD34+/-	SMARCB1 (INI1) gene alterations on (22q11)
Dedifferentiated liposarcoma (DDLPS)	MDM2+, CDK4+, SMA+/-, Desmin+/-	Ring and giant marker chromosomes derived from amplification of 12q13-15 (variable amplification of MDM2, SAS, CDK4, HMGA2)
Anaplastic large-cell lymphoma (ALCL)	CD45+, CD30+, ALK+/-	TCR gene rearrangement, Rearrangement of 2p23 (ALK)
Inflammatory myofibroblastic tumor (IMT)	ALK+/-, SMA+/-, Desmin+/-	Rearrangement of 2p23 (ALK)
Ewing Sarcoma	FLI1+, CD99+	t(11;22) and other translocations involving EWSR1 gene
Melanoma	S100+, SOX10+, MelanA/MART1+, MITF+, Tyrosinase+	BRAF, ARID2, BAP1, GNAQ, HRAS, KIT, NF1, NRAS, and PTEN mutations
Malignant peripheral nerve sheath tumors (MPNST)	S100+/-, GFAP+/-, CD34+/-	Complex
Solitary fibrous tumor (SFT)	STAT6+, CD34+, BCL2+	NAB2-STAT6 fusion
Leiomyosarcoma (LMS)	SMA+, Desmin+, Caldesmon+	Complex
Rhabdomyosarcoma (RMS)	Desmin+, Myogenin+, MyoD1+	Complex
Angiosarcoma	Vascular markers (CD31, CD34, FLI1, ERG)+, Keratin +/- in epithelioid angiosarcoma	MYC (8q24) or FLT4 (VEGFR3) (5q35) amplification, Upregulation of vascular-specific receptor tyrosine kinases (TIE1, KDR, TEK, FLT1)
Kaposi Sarcoma	HHV8 (LANA)+, vascular markers+, Lymphatic markers (D2-40, LYVE1, Prox1)+	KSHV/HHV8 with PCR
Epithelioid hemangioendothelioma (EHE)	Vascular markers+, TFE3+/-, Keratin +/-	WWTr1-CAMTA1 fusion, YAP1-TFE1 fusion
Alveolar soft part sarcoma (ASPS)	TFE3+, Desmin+/-	der(17)t(X;17)(p11.2;q25) translocation (ASPSCR1-TFE3 fusion)
Perivascular epithelioid cell tumor (PECOMA)	SMA+, Desmin+, HMB45+, MITF+, MART1+	TSC2 mutations, TFE3 gene fusions

histiocytomas in the lung in 1987 with 22 cases (patient age range of 18 to 80 years). Previous irradiation is a known pathogenic risk factor for soft tissue UPS. Similarly, few reports are available in the literature regarding patients who develop PPUPS years after radiation therapy for another tumor.<sup>6,7</sup> It is unclear whether de-novo PPUPS and radiation associated undifferentiated pleomorphic sarcomas represent the same entity.

Clinical presentations in pulmonary tumors, as with other types of lung cancers, depends more on

the tumor location rather than the histological type. Primary pulmonary sarcomas often present as a large peripheral or hilar well-circumscribed mass, and may present as an endobronchial tumor in 10% of cases.<sup>8</sup> The majority of patients present with symptoms of cough, chest pain, hemoptysis, or dyspnea. Radiologic findings can show a solitary mass with or without post-obstructive effects (recurrent pneumonia, bronchiectasis, lobar or segmental atelectasis), and in some cases with extraluminal growth and/or local invasion into adjacent structures.<sup>1</sup>

Since clinical and radiographic features of these tumors are nonspecific, pathological tissue examination is required to differentiate them from the much more common epithelial tumors of the lung. The clinical course of these tumors is generally rapidly progressive and metastasis is common.<sup>4</sup> The majority of patients die within a period of 1 to 72 months. Endobronchial masses showed more favorable prognosis compare to other origins.<sup>8</sup>

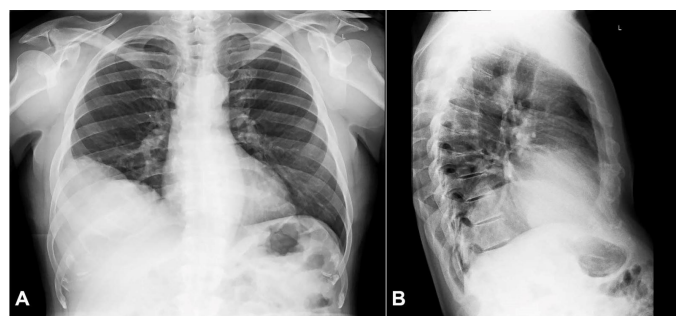
Here we report the only case of PPUPS that was diagnosed at UCLA from 2002 to 2019.

## CASE REPORT

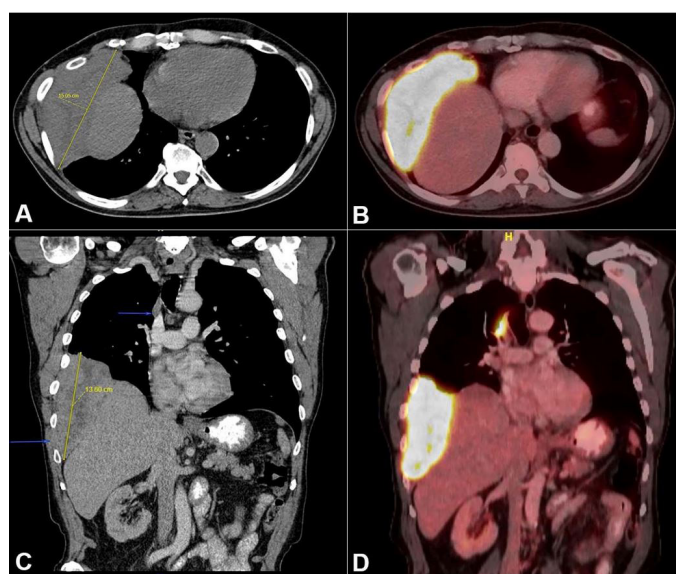
A 66-year-old man who presented with right sided chest wall pain, weight loss (7 kg), fatigue, and night sweats, without any significant past medical history, was found to have normocytic anemia and a large right inferior hemithorax mass on chest X-ray, which was inseparable from the right hemidiaphragm (Figure 1).

Computed tomography (CT) scan showed a large (15 × 13.6 × 6.2 cm), poorly circumscribed, heterogeneous mass within the right base of the lung involving the pleural surface and mildly protruding into the 8<sup>th</sup> and 9<sup>th</sup> intercostal spaces, without eroding of the adjacent bones (Figure 2). Positron emission tomography–computed tomography (PET-CT) scan revealed a large right inferior hemithorax mass with intense fluorodeoxyglucose (FDG) uptake (standardized uptake values (SUVs) of 22.3). The mass abutted the right hemidiaphragm and the chest wall with suggestion of extension into the rib interspaces, most prominent at the right 8<sup>th</sup> rib interspace. A 6.1 cm right superior paramediastinal mass with intense FDG uptake (SUVMax 16.3) was also seen, suspicious for pleural deposit/metastatic disease (Figure 2).

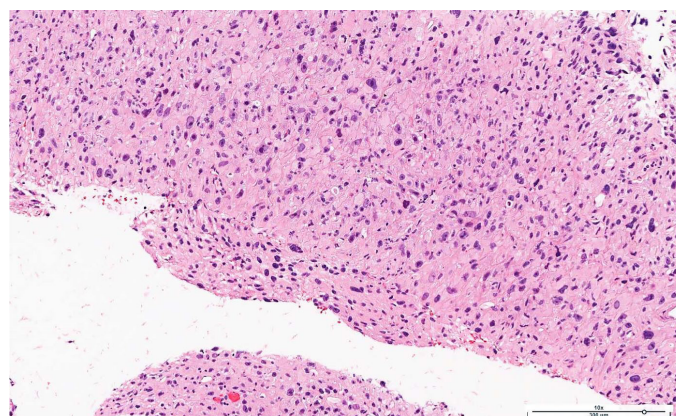
A CT guided core biopsy was subsequently performed. Histological examination revealed a poorly differentiated malignant neoplasm with epithelioid morphology (Figure 3). Microscopic examination did not reveal any line of differentiation by morphology or upon application of immunohistochemistry; tumoral cells were negative for TTF-1, epithelial (pankeratin, EMA, CAM5.2), mesothelial (calretinin), melanocytic (S100 protein, SOX10, MART1), vascular (CD34), and myogenic (desmin, caldesmon) markers. Therefore, the favored diagnosis was poorly differentiated malignant epithelioid neoplasm.



**Figure 1.** Chest X-Ray (A) anteroposterior view; (B) lateral view showing a large right lower lung mass.



**Figure 2.** Imaging study of the thorax. CT scan (A - axial plane, C - coronal plane) shows a 15 × 6 cm poorly circumscribed right lower lung mass protruding into the 8<sup>th</sup> and 9<sup>th</sup> intercostal spaces. (B - axial plane and D - coronal plane) PET scan shows a 15 cm right inferior lung mass and a 6 cm right superior paramediastinal mass with high FDG uptake.



**Figure 3.** Photomicrograph of the CT-Guided biopsy showed a poorly differentiated malignant epithelioid neoplasm (H&E, 10X).

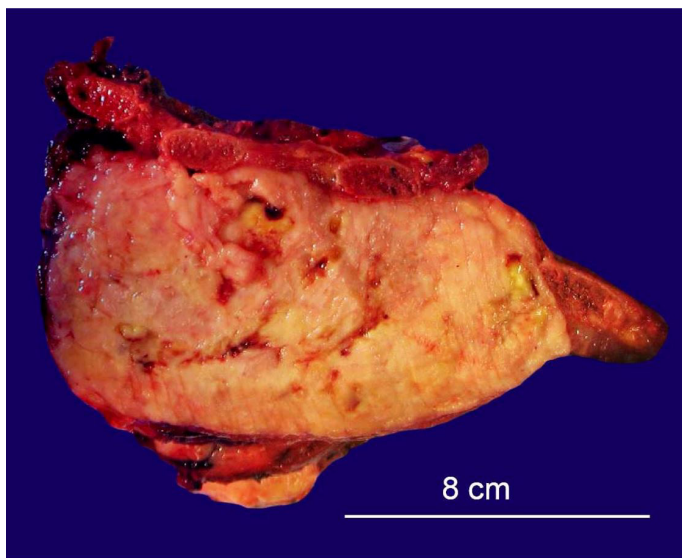


Subsequently, the patient underwent surgical wedge resection of right lower and middle lobes, along with the adjacent right chest wall. Gross examination showed a well-circumscribed light tan and firm mass with areas of necrosis and hemorrhage, which abutted

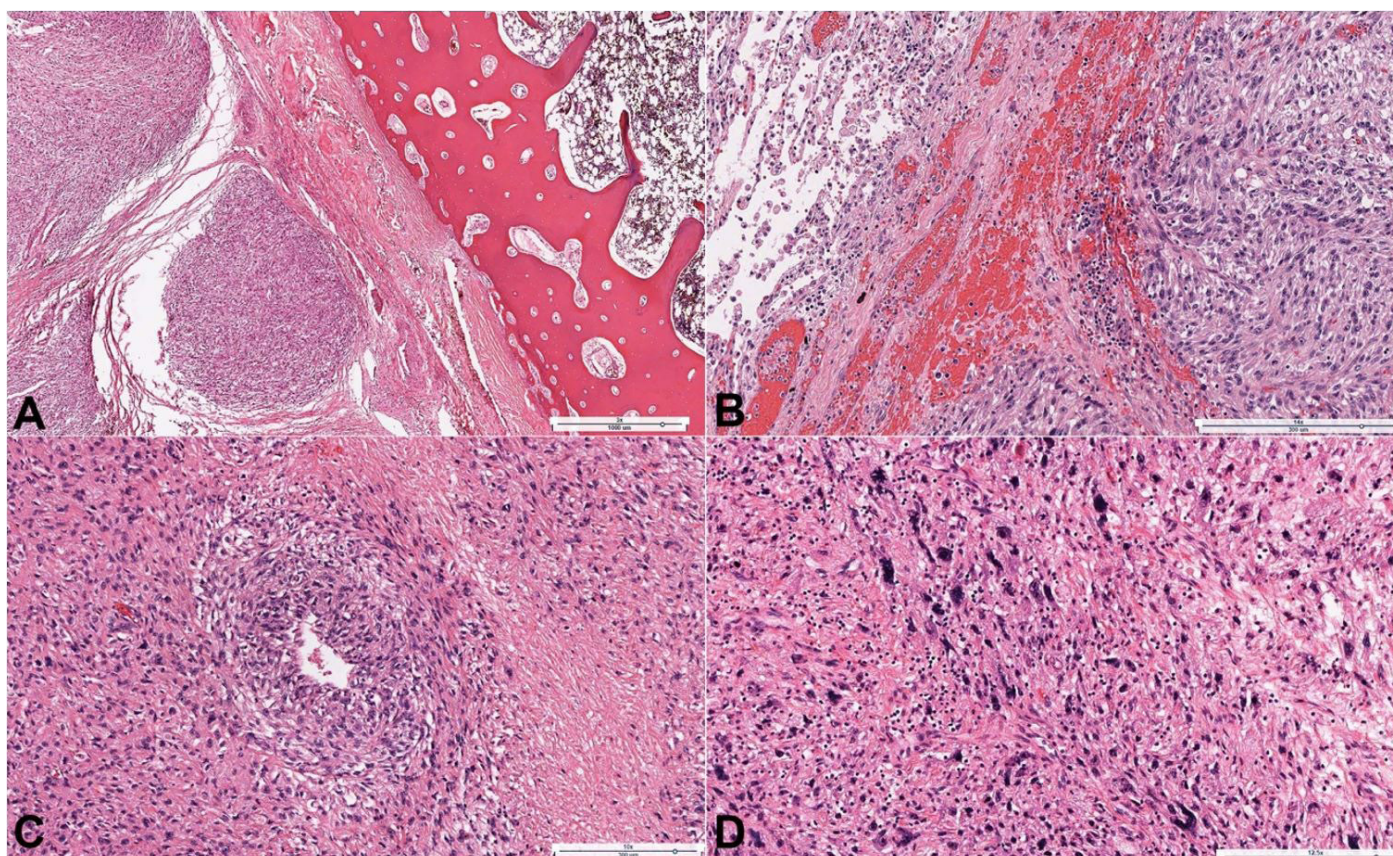
the bone without any gross or microscopic evidence of invasion. The mass measured 17.5 cm × 6.5 cm × 1.5 cm (Figure 4).

Representative sections showed a vaguely nodular mass consists of spindle to epithelioid neoplastic cells arranged in sheets and fascicles some in a storiform pattern. Large, bizarre pleomorphic cells with round to oval nuclei, prominent nucleoli, and moderate amounts of cytoplasm were observed (Figure 5A and 5B). Areas of necrosis (Figure 5C) and high mitotic activity, including atypical mitosis (Figure 5D), were identified.

All surgical margins were free of malignancy and no lymph node metastasis was identified. As with the biopsy, the neoplastic cells did not show any immunoreactivity to epithelial, mesothelial, or glandular markers; negative staining for pankeratin, CAM5.2, Keratin 5/6, p63, calretinin, WT1, D2-40, TTF1, S100, SOX10, MART1, HMB45, desmin, caldesmon, EMA, CD34, STAT6, C-Kit, DOG1, myogenin, MyoD1, CD21, CD23, CD35, chromogranin, TLE1, BCL2, and CD99 (Figure 6). Since no evidence of extrapulmonary origin



**Figure 4.** Gross examination of the lung mass resection.



**Figure 5.** Photomicrographs of the tumor showing in **A** – Vaguely nodular high-grade spindle to epithelioid neoplasm with adjacent rib bone (H&E, 3X); **B** – Neoplastic cells with adjacent normal lung parenchyma (H&E, 14X); **C** – Undifferentiated pleomorphic sarcoma with areas of necrosis (H&E, 10X); **D** – Pleomorphic cells with high mitotic activity, atypical mitoses, chronic inflammatory cell infiltrate and focal necrosis (H&E, 12.5X).



was identified and the tumor did not demonstrate any line of differentiation in our extensive work up, the diagnosis of primary pulmonary undifferentiated pleomorphic sarcoma (PPUPS) was rendered.

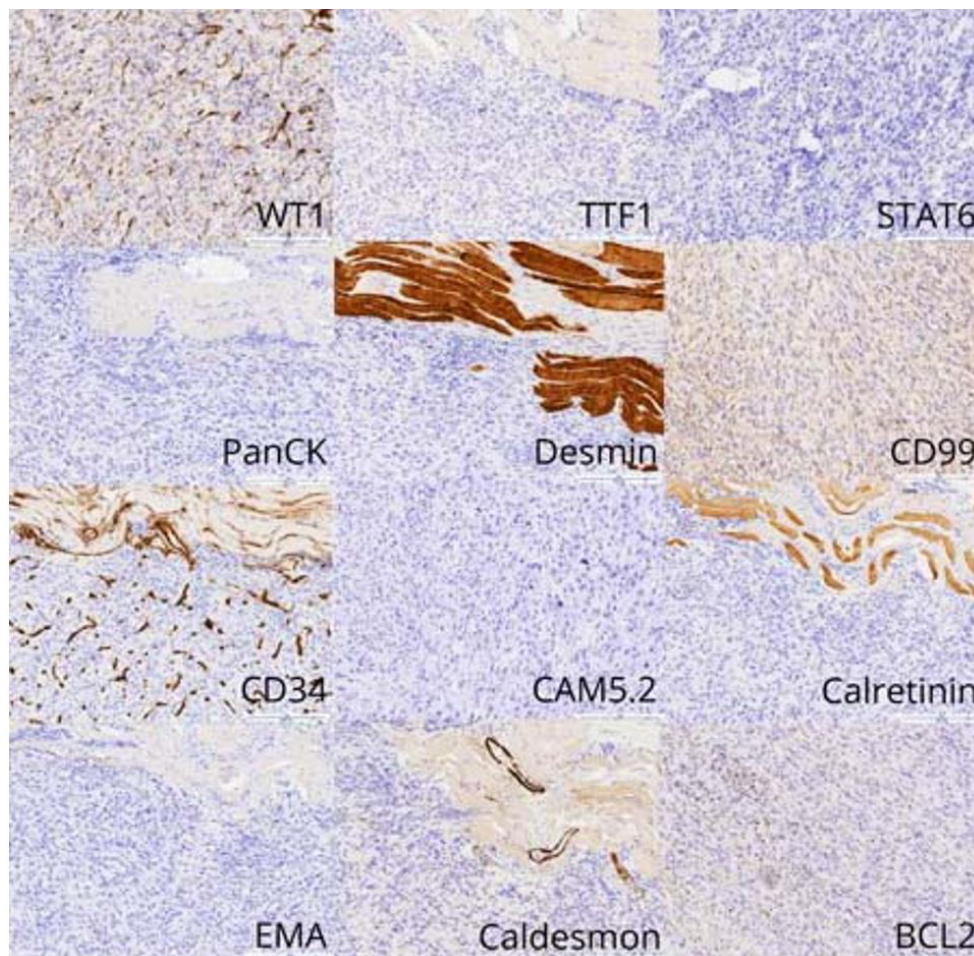
Final Pathologic Diagnosis: (i) Undifferentiated pleomorphic sarcoma, high grade, 17.5 cm; (ii) Surgical margins are uninvolved.

The patient was further treated with radiotherapy and multiple cycles of adjuvant chemotherapy (7 days cycle per month with Ifosfamide 1500mg/m<sup>2</sup> CIV on days 1-7). Patient tolerated the treatment without any evidence of local recurrence or metastasis up to this date (4 months follow up).

## DISCUSSION

Primary lung sarcomas are rare, and represents less than 0.5% of lung malignancies. Cameron<sup>9</sup> and Miller and Allen<sup>10</sup> reported primary lung sarcomas in 0.15% and 0.3% of lung neoplasms in studies of

6000 and 10134 patients with primary lung malignancies respectively. Among the primary pulmonary sarcomas, undifferentiated pleomorphic sarcoma (UPS) is one of the rarest one with less than 84 reported cases. UPS is defined as a high-grade pleomorphic neoplasm that shows no discernible microscopic evidence of any specific form of differentiation (e.g., lipoblasts, bone formation, epithelial structures) using currently available diagnostic techniques. Fletcher CD in a retrospective study on re-analysis of 159 tumors showed that just 26% of previously diagnosed MFH cases were "true" UPSs, and more than half of cases showed an identifiable line of differentiation.<sup>11</sup> The main core of diagnosis of UPS is to exclude other malignant tumors that display similar morphological findings such as malignant melanomas, sarcomatoid carcinomas, anaplastic lymphomas, sarcomatoid mesotheliomas, or other sarcomas (e.g., dedifferentiated liposarcoma and pleomorphic rhabdomyosarcoma, etc.). Therefore, it is a diagnosis of exclusion, which requires careful



**Figure 6.** Photomicrographs of the tumor. Immunohistochemistry studies shows no line of differentiation (Magnification x10).

examination of tissue and generous sampling of the specimen to establish a correct diagnosis.<sup>12</sup> This diagnosis should not be made definitively on a biopsy specimen, because the entire mass is not present in the biopsy materials. Some authors believe that the category of UPS serves primarily as a “wastebasket” for a heterogeneous group of unclassifiable neoplasms with pleomorphic morphology.<sup>13</sup>

UPS characteristically shows positive staining for histiocytic markers (CD68,  $\alpha$ 1-antichymotrypsin, vimentin), a reason why such tumors were identified as “malignant fibrous histiocytoma” (MFH) in the past. Staining for TTF-1, S-100 protein, desmin, actin, myoglobin, caldesmon, D2-40, and calretinin is negative. In some cases, keratin staining may be positive, which makes it difficult to differentiate sarcomatoid carcinomas (SCs) from UPS. Stronger cytokeratin immunoreactivity along with more differentiated carcinomatous elements, as well as immunoreactivity to other epithelial markers (such as P63) can be helpful in the diagnosis of SCs. A wider than usual panel of immunohistochemical studies is necessary to rule out other neoplasms that can resemble UPS including other types of sarcomas, sarcomatoid carcinoma, melanoma, or mesothelioma. (Table 1). Special staining, electron microscopy, or microscopy with ultraviolet surface excitations have not shown strong utility in the diagnosis of UPSs.<sup>14,15</sup>

Non-specific small droplets of neutral fat and PAS-positive, diastase-resistant droplets may be seen especially in the giant cells in this tumor, which probably reflect a degenerative change.<sup>14</sup> Electron microscopic features are helpful for evaluation of better-differentiated tumors; for example, high aspect ratio surface microvilli, perinuclear tonofilaments, and hyaluronic acid crystals are seen in more differentiated mesotheliomas. However, when the tumor is poorly differentiated, the ultrastructural findings are rarely helpful.<sup>16</sup> The genetic profile of primary pulmonary mesenchymal tumors shows complex and nonspecific cytogenetic aberrations, similar to their soft tissue counterparts. Molecular studies can be helpful to rule out other tumors with similar histological findings (Table 1). Molecular mechanisms responsible for primary pulmonary UPS formation and progression are unknown.<sup>14</sup>

It is also important to know that UPS is a relatively common soft tissue tumor and most cases of UPS found in the lung represent metastasis from an extra-pulmonary origin.<sup>6</sup> Therefore, a careful clinical evaluation to exclude a possible extrapulmonary site of origin is necessary before diagnosing primary pulmonary UPS (PPUPS).

We provide a brief review of literature on PPUPS (previously described as PPMFH) in Table 2. 85 cases have been reported in the English literature since 1979,

**Table 2.** Review of literature of primary pulmonary undifferentiated pleomorphic sarcoma/primary pulmonary fibrous histiocytoma PPUPS/PPMFH.

#	Year	Reference	Age	Sex	Location	Size (cm)	LN	Tx	Survival (mos)	F/U
1	1979	Bedrossian et al. <sup>4</sup>	51	M	LLL/RML	3	N	L	14	DOD
2	1979	Kern et al. <sup>17</sup>	53	M	RLL	8	N	L	12	DOD
3	1980	Chowdhury et al. <sup>7</sup>	52	F	RLL	5	U	C	4	DOD
4	1981	Paulsen et al. <sup>18</sup>	53	F	LLL	4	N	L	36	DOD
5	1982	Mills et al. <sup>19</sup>	60	F	RLL	10	N	L	18	AWD
6	1982	Sriumpai et al. <sup>20</sup>	41	M	RLL	9	U	L	18	DOD
7	1983	Misra et al. <sup>21</sup>	45	M	RLL	16	P	X	10	DOD
8	1984	Larsen et al. <sup>22</sup>	75	M	RUL	2.5	N	R	10	NED
9	1984	Lee et al. <sup>23</sup>	62	M	LLL	6	N	L	12	NED
10	1984	Lee et al. <sup>23</sup>	54	M	LUL	7	N	C	7	DOD
11	1984	Lee et al. <sup>23</sup>	69	M	RUL	8	N	Pn,X	8	NED

AWD = alive with disease; C = chemotherapy; DNED = dead with no evidence of disease; DOD = death of disease; DWED = death of non-related cause with evidence of disease; E = endoscopic resection; F/U = follow up; F = female; L = lobectomy; LLL = left lower lobe; LN = lymph node; LUL = left upper lobe; M = male; N = negative; NED = no evidence of disease; Nt = no treatment; Pn = pneumonectomy; P = positive; R = resection; REB = right endobronchial; RLL = right lower lobe; RML = right middle lobe; RUL = right upper lobe; Tx = treatment; U = unavailable data; X = radiotherapy.

Table 2. Continued...

#	Year	Reference	Age	Sex	Location	Size (cm)	LN	Tx	Survival (mos)	F/U
12	1984	Lee et al. <sup>23</sup>	62	F	LLL	5	N	L,X	120	NED
13	1984	Lee et al. <sup>23</sup>	67	M	LUL	4	N	L	60	NED
14	1984	Lessel and Erbstösser <sup>24</sup>	35	F	RLL	25	U	Nt	12	DOD
15	1984	Silverman and Coalson <sup>25</sup>	56	M	LUL	8	-	C	3	AWD
16	1985	Tanino et al. <sup>26</sup>	75	F	LLL	5	+	Nt	5	DOD
17	1986	Venn et al. <sup>27</sup>	32	F	RML/RUL	U	U	L	18	NED
18	1986	Venn et al. <sup>27</sup>	62	M	RUL	8	U	L	60	NED
19	1986	Venn et al. <sup>27</sup>	61	F	LUL	U	U	Pn	15	DWED
20	1986	Venn et al. <sup>27</sup>	62	M	LUL	U	U	X	2	AWD
21	1987	Hsiu et al. <sup>28</sup>	71	F	RUL	5	N	L	10	NED
22	1987	Juettner et al. <sup>29</sup>	68	M	LLL	20	N	Nt	12	DOD
23	1987	Juettner et al. <sup>29</sup>	58	M	RLL	5.5	P	L	12	DOD
24	1987	Ismailer et al. <sup>30</sup>	12	F	RUL	9	N	L	12	AWD
25	1987	Yousem and Hochholzer <sup>5</sup>	54	F	RLL	1.7	N	L	108	NED
26	1987	Yousem and Hochholzer <sup>5</sup>	33	M	RUL	3.8	N	L	84	NED
27	1987	Yousem and Hochholzer <sup>5</sup>	59	M	RLL	5.9	N	L	65	NED
28	1987	Yousem and Hochholzer <sup>5</sup>	73	F	LUL	8.5	P	Pn	36	NED
29	1987	Yousem and Hochholzer <sup>5</sup>	64	M	RUL	5	N	L,X	16	NED
30	1987	Yousem and Hochholzer <sup>5</sup>	42	F	LLL	3	N	L	122	NED
31	1987	Yousem and Hochholzer <sup>5</sup>	57	F	RUL	4	N	Pn	1	DNED
32	1987	Yousem and Hochholzer <sup>5</sup>	80	M	LUL	3	N	L	1	DNED
33	1987	Yousem and Hochholzer <sup>5</sup>	74	M	LUL	U	N	Nt	2	DOD
34	1987	Yousem and Hochholzer <sup>5</sup>	18	M	RLL	10	N	L	1	DOD
35	1987	Yousem and Hochholzer <sup>5</sup>	46	F	RUL	6	P	L,X	8	DOD
36	1987	Yousem and Hochholzer <sup>5</sup>	52	F	RLL	U	N	C	9	DOD
37	1987	Yousem and Hochholzer <sup>5</sup>	52	F	LUL	4	P	L,C,X	72	DOD
38	1987	Yousem and Hochholzer <sup>5</sup>	74	F	RUL	14	P	L	24	DOD
39	1987	Yousem and Hochholzer <sup>5</sup>	69	F	RUL	8	N	X	36	DOD
40	1987	Yousem and Hochholzer <sup>5</sup>	40	F	LLL	4	N	L,X	24	DOD

AWD = alive with disease; C = chemotherapy; DNED = dead with no evidence of disease; DOD = death of disease; DWED = death of non-related cause with evidence of disease; E = endoscopic resection; F/U = follow up; F = female; L = lobectomy; LLL = left lower lobe; LN = lymph node; LUL = left upper lobe; M = male; N = negative; NED = no evidence of disease; Nt = no treatment; Pn = pneumonectomy; P = positive; R = resection; REB = right endobronchial; RLL = right lower lobe; RML = right middle lobe; RUL = right upper lobe; Tx = treatment; U = unavailable data; X = radiotherapy.



Table 2. Continued...

#	Year	Reference	Age	Sex	Location	Size (cm)	LN	Tx	Survival (mos)	F/U
41	1987	Yousem and Hochholzer <sup>5</sup>	74	M	RML	U	N	X	8	DOD
42	1987	Yousem and Hochholzer <sup>5</sup>	19	M	LUL	U	N	L,C,X	14	DOD
43	1987	Yousem and Hochholzer <sup>5</sup>	63	M	LLL	7	N	Nt	14	DOD
44	1987	Yousem and Hochholzer <sup>5</sup>	36	M	RLL	3	N	R	12	DOD
45	1987	Yousem and Hochholzer <sup>5</sup>	32	M	LLL	11	P	Pn,C,X	3	DOD
46	1988	Casey and Peddle <sup>31</sup>	21	M	RUL	3	N	L	96	NED
47	1988	Casey and Peddle <sup>31</sup>	46	M	LLL	10	N	L	8	NED
48	1988	McDonnell et al. <sup>32</sup>	73	F	LLL	6.5	N	L	3	DOD
49	1988	Palmer et al. <sup>33</sup>	62	F	RLL	U	N	L	14	DOD
50	1989	White et al. <sup>34</sup>	55	M	RUL	U	U	Nt	4	DOD
51	1990	In et al. <sup>35</sup>	43	F	RLL	U	U	C,X	U	U
52	1990	Marchán and Pérez <sup>36</sup>	10	F	LLL	5	N	L	U	U
53	1993	Higashiyama et al. <sup>37</sup>	49	F	RLL	6	P	Pn	U	NED
54	1995	Kamath et al. <sup>38</sup>	56	M	RLL	10	U	Nt	3	DOD
55	1996	Gómez-Román and Val-Bernal <sup>39</sup>	61	M	RUL	3	U	R	9	NED
56	1996	Halyard et al. <sup>40</sup>	51	F	LLL	10	N	L,X	60	NED
57	1996	Halyard et al. <sup>40</sup>	77	M	RML	2.2	N	L	36	NED
58	1996	Halyard et al. <sup>40</sup>	40	M	LLL	11	P	R	6	DOD
59	1996	Halyard et al. <sup>40</sup>	57	F	LUL	7.5	U	L	1	DOD
60	1996	Shah et al. <sup>41</sup>	9	M	LUL	6	U	L,C,X	36	NED
61	1997	Nistal et al. <sup>42</sup>	12	F	LUL	7	U	C,X	5	AWD
62	1997	Barbas et al. <sup>43</sup>	37	M	RML/RLL	10	N	Pn	6	DNED
63	2000	Fujita et al. <sup>44</sup>	65	F	LLL	12	U	Nt	6	DOD
64	2000	Herrmann et al. <sup>45</sup>	57	M	RUL	13	U	L	12	NED
65	2001	Nonaka et al. <sup>6</sup>	59	M	U	4.5	U	U	U	U
66	2002	Alhadab et al. <sup>46</sup>	56	M	LUL/LLL	U	U	Nt	4	DOD
67	2002	Etienne-Mastroianni et al. <sup>2</sup>	47	M	U	U	U	L,X	3	NED
68	2003	Wang et al. <sup>47</sup>	86	M	LLL	15	U	Nt	2	DOD
69	2007	Maeda et al. <sup>48</sup>	62	M	LUL	4.5	P	L	24	DNED
70	2007	Rzyman et al. <sup>49</sup>	58	M	LUL	4	N	Pn	121	NED
71	2007	Rzyman et al. <sup>49</sup>	61	M	RUL	7.5	N	L	7	DNED
72	2007	Rzyman et al. <sup>49</sup>	75	M	RUL	8	P	Pn	4	DOD
73	2007	Rzyman et al. <sup>49</sup>	61	F	LUL	3	N	L	2	DOD
74	2007	Rzyman et al. <sup>49</sup>	54	M	RUL	9	P	L	3	DOD
75	2008	Noh et al. <sup>50</sup>	58	F	RUL	5	N	L,X	5	NED
76	2010	Maitani et al. <sup>51</sup>	18	F	LUL	2.2	U	L	36	NED

AWD = alive with disease; C = chemotherapy; DNED = dead with no evidence of disease; DOD = death of disease; DWED = death of non-related cause with evidence of disease; E = endoscopic resection; F/U = follow up; F = female; L = lobectomy; LLL = left lower lobe; LN = lymph node; LUL = left upper lobe; M = male; N = negative; NED = no evidence of disease; Nt = no treatment; Pn = pneumonectomy; P = positive; R = resection; REB = right endobronchial; RLL = right lower lobe; RML = right middle lobe; RUL = right upper lobe; Tx = treatment; U = unavailable data; X = radiotherapy.

**Table 2.** Continued...

#	Year	Reference	Age	Sex	Location	Size (cm)	LN	Tx	Survival (mos)	F/U
77	2010	Tsangaridou et al. <sup>52</sup>	54	M	LLL	U	N	Pn	168	AWD
78	2012	Jeon and Park <sup>53</sup>	55	M	LLL	U	N	Pn,C,X	9	NED
79	2012	Thomas and Koshi <sup>54</sup>	47	M	RUL	U	P	C,X	2	DOD
80	2013	Kim et al. <sup>8</sup>	61	M	REB	3	N	E	14	AWD
81	2013	Li et al. <sup>55</sup>	80	F	RUL	8	U	Nt	1.5	DOD
82	2014	Liu et al. <sup>56</sup>	59	F	LUL	15.7	N	R	8	NED
83	2015	Patel et al. <sup>57</sup>	86	M	RML/RLL	9.6	N	L	6	NED
84	2017	Li et al. <sup>58</sup>	61	M	RUL	8	P	L	U	U
85	2019	This study	66	M	RLL	15	N	L,C	4	NED

AWD = alive with disease; C = chemotherapy; DNED = dead with no evidence of disease; DOD = death of disease; DWED = death of non-related cause with evidence of disease; E = endoscopic resection; F/U = follow up; F = female; L = lobectomy; LLL = left lower lobe; LN = lymph node; LUL = left upper lobe; M = male; N = negative; NED = no evidence of disease; Nt = no treatment; Pn = pneumonectomy; P = positive; R = resection; REB = right endobronchial; RLL = right lower lobe; RML = right middle lobe; RUL = right upper lobe; Tx = treatment; U = unavailable data; X = radiotherapy.

including our case. 51 out of 85 case were male and 35 were female (M:F ratio of 1.45). The patient age ranged from 9 to 85 years with a mean age of 54. The tumor size ranges from 1.7 to 25 cm, with average size of 7.3 cm, and mean survival of 23.73 months. Even though PPUPS has a high local recurrences and mortality rate, long term survival has been reported in some cases, even more than 10 years.<sup>5,23,49,52</sup>

## CONCLUSION

Primary pulmonary undifferentiated pleomorphic sarcoma (PPUPS) is an exceptionally rare tumor and is essentially a diagnosis of exclusion. The approach should be to first establish the absence of any particular line of differentiation, which requires proper sampling, histological analysis, and immunohistochemistry studies. Other ancillary tests such as molecular studies and electron microscopy could also possibly be helpful. The next step is to exclude any possible extrapulmonary origin by clinical examination or by other means such as PET-CT scan. PPUPS is a highly malignant sarcoma with a poor prognosis, with surgery being the primary treatment in most cases. Postoperative chemotherapy has also been reported to be beneficial in some cases. We report here the only case of PPUPS, which was diagnosed in the past 17 years at UCLA, after an extensive work up. The patient was treated with surgical resection and

post-operative chemotherapy. With 4 months follow up, there is no evidence of local recurrence or distant metastasis.

## REFERENCES

1. Fletcher CDM, Bridge JA, Hogendoorn PCW, et al. WHO classification of tumours of soft tissue and bone. Lyon: IARC Press; 2013.
2. Etienne-Mastroianni B, Falchero L, Chalabreysse L, et al. Primary sarcomas of the lung: a clinicopathologic study of 12 cases. *Lung Cancer*. 2002;38(3):283-9. [http://dx.doi.org/10.1016/S0169-5002\(02\)00303-3](http://dx.doi.org/10.1016/S0169-5002(02)00303-3). PMID:12445750.
3. Weiss SW, Enzinger FM. Malignant fibrous histiocytoma: an analysis of 200 cases. *Cancer*. 1978;41(6):2250-66. [http://dx.doi.org/10.1002/1097-0142\(197806\)41:6<2250::AID-CNCR2820410626>3.0.CO;2-W](http://dx.doi.org/10.1002/1097-0142(197806)41:6<2250::AID-CNCR2820410626>3.0.CO;2-W). PMID:207408.
4. Bedrossian CW, Verani R, Unger KM, Salman J. Pulmonary malignant fibrous histiocytoma: light and electron microscopic studies of one case. *Chest*. 1979;75(2):186-9. <http://dx.doi.org/10.1378/chest.75.2.186>. PMID:217571.
5. Yousem SA, Hochholzer L. Malignant fibrous histiocytoma of the lung. *Cancer*. 1987;60(10):2532-41. [http://dx.doi.org/10.1002/1097-0142\(198711\)60:10<2532::AID-CNCR2820601031>3.0.CO;2-5](http://dx.doi.org/10.1002/1097-0142(198711)60:10<2532::AID-CNCR2820601031>3.0.CO;2-5). PMID:2822221.
6. Nonaka M, Kadokura M, Ohkubo F, et al. Post radiation inflammatory malignant fibrous histiocytoma arising from the chest wall. *Ann Thorac Cardiovasc Surg*. 2001;7(6):371-4. PMID:11888478.

7. Chowdhury LN, Swerdlow M, Jao W, Kathpalia S, Desser RK. Post-irradiation malignant fibrous histiocytoma of the lung. Demonstration of alpha1-antitrypsin-like material in neoplastic cells. *Am J Clin Pathol*. 1980;74(6):820-6. <http://dx.doi.org/10.1093/ajcp/74.6.820>. PMID:6255791.
8. Kim JH, Cho SH, Kim EK, Lee JH, Jeong HC. Endobronchial malignant fibrous histiocytoma: case report of an unusual presentation and palliative flexible bronchoscopic resection. *Respir Care*. 2013;58(8):e92-4. <http://dx.doi.org/10.4187/respcare.01996>. PMID:23258577.
9. Cameron EW. Primary sarcoma of the lung. *Thorax*. 1975;30(5):516-20. <http://dx.doi.org/10.1136/thx.30.5.516>. PMID:1198390.
10. Miller DL, Allen MS. Rare pulmonary neoplasms. *Mayo Clin Proc*. 1993;68(5):492-8. [http://dx.doi.org/10.1016/S0025-6196\(12\)60199-2](http://dx.doi.org/10.1016/S0025-6196(12)60199-2). PMID:8386792.
11. Fletcher CD. Pleomorphic malignant fibrous histiocytoma: fact or fiction? A critical reappraisal based on 159 tumors diagnosed as pleomorphic sarcoma. *Am J Surg Pathol*. 1992;16(3):213-28. <http://dx.doi.org/10.1097/00000478-199203000-00001>. PMID:1317996.
12. Hamza A, Alrajjal A, Edens J, et al. Utility of additional tissue sections in surgical pathology. *Int J Surg Pathol*. 2018;26(5):392-401. <http://dx.doi.org/10.1177/1066896918755008>. PMID:29390920.
13. Hornick JL. Practical soft tissue pathology: a diagnostic approach. 2nd ed. Philadelphia: Elsevier; 2019.
14. Goldblum JR, Folpe AL, Weiss SW. Enzinger and Weiss's soft tissue tumors. 6th ed. Philadelphia: Elsevier; 2014.
15. Qorbani A, Fereidouni F, Levenson R, et al. Microscopy with ultraviolet surface excitation (MUSE): A novel approach to real-time inexpensive slide-free dermatopathology. *J Cutan Pathol*. 2018;45(7):498-503. <http://dx.doi.org/10.1111/cup.13255>. PMID:29660167.
16. Oury TD, Hammar SP, Roggli VL. Ultrastructural features of diffuse malignant mesotheliomas. *Hum Pathol*. 1998;29(12):1382-92. [http://dx.doi.org/10.1016/S0046-8177\(98\)90006-5](http://dx.doi.org/10.1016/S0046-8177(98)90006-5). PMID:9865823.
17. Kern WH, Hughes RK, Meyer BW, Harley DP. Malignant fibrous histiocytoma of the lung. *Cancer*. 1979;44(5):1793-801. [http://dx.doi.org/10.1002/1097-0142\(197911\)44:5<1793::AID-CNCR2820440538>3.0.CO;2-1](http://dx.doi.org/10.1002/1097-0142(197911)44:5<1793::AID-CNCR2820440538>3.0.CO;2-1). PMID:227578.
18. Paulsen SM, Egeblad K, Christensen J. Malignant fibrous histiocytoma of the lung. *Virchows Arch A Pathol Anat Histol*. 1981;394(1-2):167-76. <http://dx.doi.org/10.1007/BF00431675>. PMID:6278700.
19. Mills SA, Breyer RH, Johnston FF, et al. Malignant fibrous histiocytoma of the mediastinum and lung. A report of three cases. *J Thorac Cardiovasc Surg*. 1982;84(3):367-72. PMID:6287120.
20. Sriumpai S, Dharamadhach A, Suchatlampong V. Malignant Fibrous Histiocytoma (MFH) of the lung: a case report. *J Med Assoc Thai*. 1982;65(12):667-73. PMID:6298333.
21. Misra DP, Sunderrajan EV, Rosenholtz MJ, Hurst DJ. Malignant fibrous histiocytoma in the lung masquerading as recurrent pulmonary thromboembolism. *Cancer*. 1983;51(3):538-41. [http://dx.doi.org/10.1002/1097-0142\(19830201\)51:3<538::AID-CNCR2820510329>3.0.CO;2-X](http://dx.doi.org/10.1002/1097-0142(19830201)51:3<538::AID-CNCR2820510329>3.0.CO;2-X). PMID:6295607.
22. Larsen K, Vejlsted H, Hariri J. Primary malignant fibrous histiocytoma of the lung: a case report. *Scand J Thorac Cardiovasc Surg*. 1984;18(1):89-91. <http://dx.doi.org/10.3109/14017438409099391>. PMID:6326255.
23. Lee JT, Shelburne JD, Linder J. Primary malignant fibrous histiocytoma of the lung: a clinicopathologic and ultrastructural study of five cases. *Cancer*. 1984;53(5):1124-30. [http://dx.doi.org/10.1002/1097-0142\(19840301\)53:5<1124::AID-CNCR2820530518>3.0.CO;2-V](http://dx.doi.org/10.1002/1097-0142(19840301)53:5<1124::AID-CNCR2820530518>3.0.CO;2-V). PMID:6318959.
24. Lessel W, Erbstösser E. Malignant fibrous histiocytoma of the lung. *Z Erkr Atmungsorgane*. 1984;163(1):70-4. PMID:6091352.
25. Silverman JF, Coalson JJ. Primary malignant myxoid fibrous histiocytoma of the lung: light and ultrastructural examination with review of the literature. *Arch Pathol Lab Med*. 1984;108(1):49-54. PMID:6318685.
26. Tanino M, Odashima S, Sugiura H, Matsue T, Kajikawa M, Maeda S. Malignant fibrous histiocytoma of the lung. *Acta Pathol Jpn*. 1985;35(4):945. PMID:3000133.
27. Venn GE, Gellister J, DaCosta PE, Goldstraw P. Malignant fibrous histiocytoma in thoracic surgical practice. *J Thorac Cardiovasc Surg*. 1986;91(2):234-7. PMID:3003463.
28. Hsiu J-G, Kreuger JK, D'Amato NA, Morris JR. Primary malignant fibrous histiocytoma of the lung: fine needle aspiration cytologic features. *Acta Cytol*. 1987;31(3):345-50. PMID:3035847.
29. Juettner FM, Popper H, Sommersgutter K, Smolle J, Friehs GB. Malignant fibrous histiocytoma of the lung: prognosis and therapy of a rare disease. Report of two cases and review of the literature. *Thorac Cardiovasc Surg*. 1987;35(4):226-31. <http://dx.doi.org/10.1055/s-2007-1020235>. PMID:2444005.
30. Ismailer I, Khan A, Leonidas JC, Wind E, Herman P. Computed tomography of primary malignant fibrohistiocytoma of the lung. *Comput Radiol*. 1987;11(1):37-40. [http://dx.doi.org/10.1016/0730-4862\(87\)90027-8](http://dx.doi.org/10.1016/0730-4862(87)90027-8). PMID:3034505.
31. Casey MT, Peddle LM. Primary pulmonary fibrous histiocytoma: report of three cases. *Can J Surg*. 1988;31(4):251-3. PMID:2839274.



32. McDonnell T, Kyriakos M, Mazoujian G, Roper C. Malignant fibrous histiocytoma of the lung. *Cancer*. 1988;61(1):137-45. [http://dx.doi.org/10.1002/1097-0142\(19880101\)61:1<137::AID-CNCR2820610124>3.0.CO;2-W](http://dx.doi.org/10.1002/1097-0142(19880101)61:1<137::AID-CNCR2820610124>3.0.CO;2-W). PMID:2825958.
33. Palmer AS, Passmann JM, Vega JG. Malignant fibrous histiocytoma of the lung. *IMJ Ill Med J*. 1988;174(5):290-1. PMID:2906925.
34. White A, Graeme-Cooke F, Fitzgerald GR, Clancy L. Malignant fibrous histiocytoma of lung. *Respir Med*. 1989;83(6):521-3. [http://dx.doi.org/10.1016/S0954-6111\(89\)80140-4](http://dx.doi.org/10.1016/S0954-6111(89)80140-4). PMID:2560227.
35. In KH, Byun HJ, Kang KH, Kim JS, Yoo SH. A case of pulmonary malignant fibrous histiocytoma associated with pulmonary artery obstruction. *Korean J Intern Med*. 1990;5(1):79-83. <http://dx.doi.org/10.3904/kjim.1990.5.1.79>. PMID:2176820.
36. Marchán RF, Pérez C. Malignant fibrous histiocytoma of the lung. *Bol Asoc Med P R*. 1990;82(8):362-3. PMID:2175612.
37. Higashiyama M, Doi O, Kodama K, et al. Successful surgery of malignant fibrous histiocytoma in the lung with gross extension into the right main pulmonary artery. *Thorac Cardiovasc Surg*. 1993;41(1):73-6. <http://dx.doi.org/10.1055/s-2007-1013825>. PMID:8396275.
38. Kamath SV, Tenreiro-Picon OR, Ragland RL, Smith TW, Weaver JP, Knorr JR. Brain metastases from primary lung malignant fibrous histiocytoma: a case report. *J Neuroimaging*. 1995;5(2):133-4. <http://dx.doi.org/10.1111/jon199552133>. PMID:7718943.
39. Gómez-Román JJ, Val-Bernal JF. A case of malignant fibrous histiocytoma of the lung arising as a third primary tumor. *Thorac Cardiovasc Surg*. 1996;44(6):321-3. <http://dx.doi.org/10.1055/s-2007-1012048>. PMID:9021914.
40. Halyard MY, Camoriano JK, Culligan JA, et al. Malignant fibrous histiocytoma of the lung. Report of four cases and review of the literature. *Cancer*. 1996;78(12):2492-7. [http://dx.doi.org/10.1002/\(SICI\)1097-0142\(19961215\)78:12<2492::AID-CNCR7>3.0.CO;2-M](http://dx.doi.org/10.1002/(SICI)1097-0142(19961215)78:12<2492::AID-CNCR7>3.0.CO;2-M). PMID:8952556.
41. Shah SJ, Craver RD, Yu LC. Primary malignant fibrous histiocytoma of the lung in a child: a case report and review of literature. *Pediatr Hematol Oncol*. 1996;13(6):531-8. <http://dx.doi.org/10.3109/08880019609030868>. PMID:8940736.
42. Nistal M, Jimenez-Heffernan JA, Hardisson D, Viguier JM, Bueno J, Garcia-Miguel P. Malignant fibrous histiocytoma of the lung in a child: an unusual neoplasm that can mimic inflammatory pseudotumour. *Eur J Pediatr*. 1997;156(2):107-9. <http://dx.doi.org/10.1007/s004310050565>. PMID:9039512.
43. Barbas CS, Capelozzi VL, Takagaki TY, Carvalho CR, Barbas JV Fo. Primary malignant fibrous histiocytoma of the lung. Report of a case with bronchial brushing cytologic features. *Acta Cytol*. 1997;41(3):919-23. <http://dx.doi.org/10.1159/000332729>. PMID:9167727.
44. Fujita Y, Shimizu T, Yamazaki K, et al. Bronchial brushing cytology features of primary malignant fibrous histiocytoma of the lung: a case report. *Acta Cytol*. 2000;44(2):227-31. <http://dx.doi.org/10.1159/000326365>. PMID:10740611.
45. Herrmann BL, Saller B, Kiess W, et al. Primary malignant fibrous histiocytoma of the lung: IGF-II producing tumor induces fasting hypoglycemia. *Exp Clin Endocrinol Diabetes*. 2000;108(8):515-8. <http://dx.doi.org/10.1055/s-2000-11007>. PMID:11149628.
46. Alhadab T, Alvarez F, Phillips NJ, Hauptman PJ. Malignant fibrous histiocytoma of the lung presenting as bronchial obstruction in a heart transplant recipient. *J Heart Lung Transplant*. 2002;21(10):1140-3. [http://dx.doi.org/10.1016/S1053-2498\(02\)00416-3](http://dx.doi.org/10.1016/S1053-2498(02)00416-3). PMID:12398882.
47. Wang C-S, Tsai J-R, Sheu C-C, et al. Primary malignant fibrous histiocytoma of the lung: a case report. *Kaohsiung J Med Sci*. 2003;19(8):428-31. [http://dx.doi.org/10.1016/S1607-551X\(09\)70487-5](http://dx.doi.org/10.1016/S1607-551X(09)70487-5). PMID:12962431.
48. Maeda J, Ohta M, Inoue M, et al. Surgical intervention for malignant fibrous histiocytoma of the lung: report of a case. *Surg Today*. 2007;37(4):316-9. <http://dx.doi.org/10.1007/s00595-006-3369-4>. PMID:17387565.
49. Rzyman W, Jaskiewicz K, Murawski M, et al. Primary malignant fibrous histiocytoma of the lung. *Thorac Cardiovasc Surg*. 2007;55(3):186-9. <http://dx.doi.org/10.1055/s-2006-955874>. PMID:17410507.
50. Noh HW, Park KJ, Sun JS, et al. Primary pulmonary malignant fibrous histiocytoma mimics pulmonary artery aneurysm with partial thrombosis: various radiologic evaluations. *Eur Radiol*. 2008;18(8):1653-7. <http://dx.doi.org/10.1007/s00330-008-0922-0>. PMID:18351344.
51. Maitani F, Fujimori S, Hayashi Y, Hasegawa A, Iwazaki M. A case of juvenile primary pulmonary malignant fibrous histiocytoma. *Tokai J Exp Clin Med*. 2010;35(4):130-2. PMID:21319042.
52. Tsangaridou I, Papamihalis G, Stathopoulos K, Konstantinopoulos O, Thanos L. Primary malignant fibrous histiocytoma of the lung: a case report. *Case Rep Med*. 2010;2010:389692. <http://dx.doi.org/10.1155/2010/389692>. PMID:20671984.
53. Jeon YH, Park KS. Successful management of a recurrent primary malignant fibrous histiocytoma of the lung: report of a case. *Korean J Thorac Cardiovasc Surg*. 2012;45(5):345-7. <http://dx.doi.org/10.5090/kjtcs.2012.45.5.345>. PMID:23130313.
54. Thomas ME, Koshi R. Electron microscopy in the diagnosis of malignant fibrous histiocytoma of the lung presenting as metastasis to the maxillary gingiva. *Int J Oral Maxillofac Surg*. 2013;42(1):99-101. <http://dx.doi.org/10.1016/j.ijom.2012.09.019>. PMID:23092853.

55. Li JQ, Zhang JR, Li L, et al. Inflammatory malignant fibrous histiocytoma of the lung combined with fungal infection. *Chin Med J*. 2013;126(22):4379. PMID:24238532.
56. Liu Y, Chen G, Wu Y, et al. Combined pulmonary lobectomy for surgical treatment of a malignant fibrous histiocytoma of the chest wall: a case report. *Diagn Pathol*. 2014;9(1):21. <http://dx.doi.org/10.1186/1746-1596-9-21>. PMID:24456564.
57. Patel DP, Gandhi YS, Sommers KE, Mangar D, Camporesi EM. Primary pulmonary malignant fibrous histiocytoma. *Case Rep Pulmonol*. 2015;2015:1. <http://dx.doi.org/10.1155/2015/381276>. PMID:25838959.
58. Li X, Liu R, Shi T, et al. Primary pulmonary malignant fibrous histiocytoma: case report and literature review. *J Thorac Dis*. 2017;9(8):E702-8. <http://dx.doi.org/10.21037/jtd.2017.07.59>. PMID:28932590.

**Author contributions:** Qorbani A and Nelson SD performed pathological and clinical analysis of the case, gave a substantial contribution to the study design, data generation and analysis, writing of the manuscript, and have approved the final version.

The institutional patient's consent was retained, and the manuscript is by the Institutional Ethics committee.

**Conflict of interest:** None

**Financial support:** None

**Submitted on:** March 27<sup>th</sup>, 2019

**Accepted on:** July 15<sup>th</sup>, 2019

### Correspondence

Amir Qorbani

University of California – San Francisco (UCSF) – UCSF Medical Center at Mission Bay  
M2369, 1825 4th Street, 94158 – San Francisco/CA – United States of America

CEP: 0000-000

Phone: +1 (949) 609-9916

[amir.qorbani@ucsf.edu](mailto:amir.qorbani@ucsf.edu)