

UC Davis

Dermatology Online Journal

Title

Congenital cutaneous Langerhans cell histiocytosis and cutaneous mastocytoma in a child

Permalink

<https://escholarship.org/uc/item/4kv9x9rh>

Journal

Dermatology Online Journal, 22(4)

Authors

Lozano Masdemont, B
Campos Dominguez, M
Gomez-Recuero Munoz, L
et al.

Publication Date

2016

License

<https://creativecommons.org/licenses/by-nc-nd/4.0/> 4.0

Peer reviewed

Case report

Congenital cutaneous Langerhans cell histiocytosis and cutaneous mastocytoma in a child

B Lozano Masdemont MD¹, M Campos Domínguez MD PhD¹, L Gómez-Recuero Muñoz MD¹, B Moreno García MD², V Parra Blanco MD³, R Suárez Fernández MD PhD¹

Dermatology Online Journal 22 (4): 3

¹Department of Dermatology, Hospital General Universitario Gregorio Marañón, Madrid, Spain

²Department of Ophthalmology, Hospital General Universitario Gregorio Marañón, Madrid, Spain

³Department of Pathology, Hospital General Universitario Gregorio Marañón, Madrid, Spain

Correspondence:

Belén Lozano Masdemont

Department of Dermatology , Hospital General Universitario Gregorio Marañón, Dr Esquerdo st, 46,
28007, Madrid, Spain.

Phone/ Fax: +34 91 586 66 80

Email: belenmasdemont@gmail.com

Abstract

Langerhans cell histiocytosis and mastocytoma are clonal disorders of bone-marrow-derived cells, most commonly seen in the pediatric age. Infiltration of mast cells and Langerhans cells in the same lesion has been published before, but, to our knowledge, this is the first time that the occurrence of two mastocytomas and Langerhans cell histiocytosis is reported. It could be hypothesized that both clonal disorders of bone-marrow-derived cells could have a common origin.

Keywords: Langerhans cell histiocytosis, mastocytoma, mastocytosis, neonate.

Introduction

Langerhans cell histiocytosis is a proliferation of immature myeloid dendritic cells, with a broad clinical spectrum from isolated skin lesions to multisystem life-threatening disease. Mastocytomas are a common type of cutaneous mastocytosis, which generally appear in the first year of life and resolve during childhood. Both are clonal disorders of bone-marrow-derived cells, most commonly seen in the pediatric age. The occurrence of two mastocytomas and Langerhans cell histiocytosis has never been described.

Case synopsis

A 2-week-old boy, born at term after an uncomplicated pregnancy, presented with multiple congenital skin lesions. They consisted of brown to red papules and nodules (3-8 mm in size, 10 lesions), most of them ulcerated, on his scalp, lower left eyelid, trunk, and upper and lower limbs (Figure 1, 2). Physical examination was otherwise normal.

The skin biopsy showed an ulcerated epidermis and a dermal infiltrate of large oval cells, with reniform (coffee bean) nuclei and abundant eosinophilic cytoplasm, admixed with eosinophils, multinucleated histiocytes, and lymphocytes. The large oval cells exhibited strong immunoreactivity for CD1a, CD207 (langerin) and S-100 protein (Figures 3-6). Mastocytes were not increased in number.

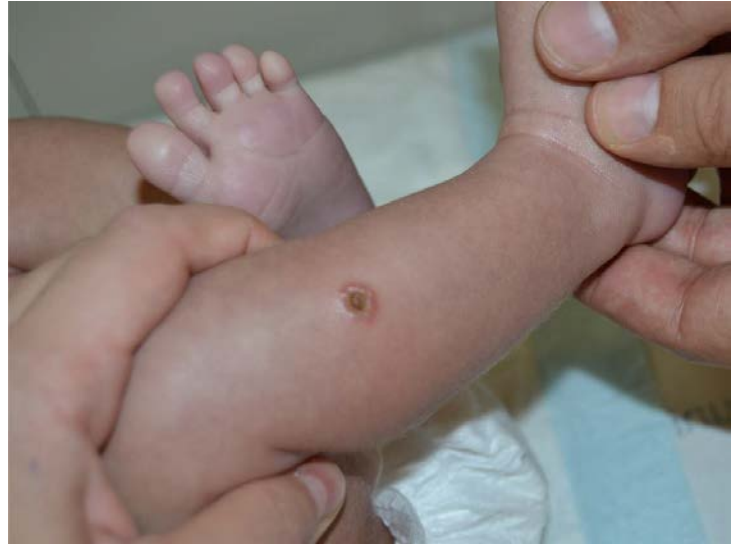
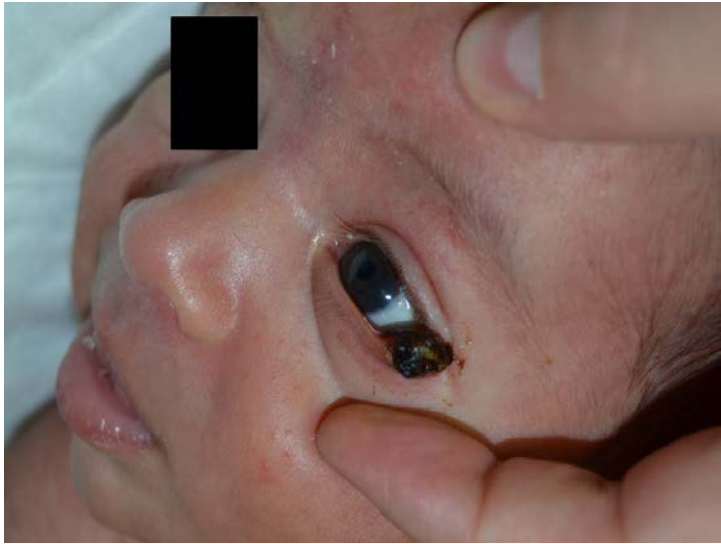
Figure 1. Crusted nodule on the lower left eyelid, 1 month. **Figure 2.** Crusted nodule on the leg, 1 month.

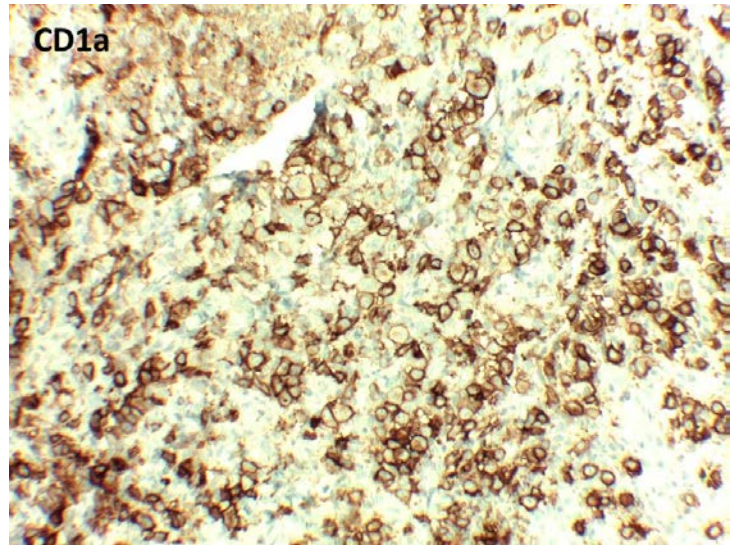
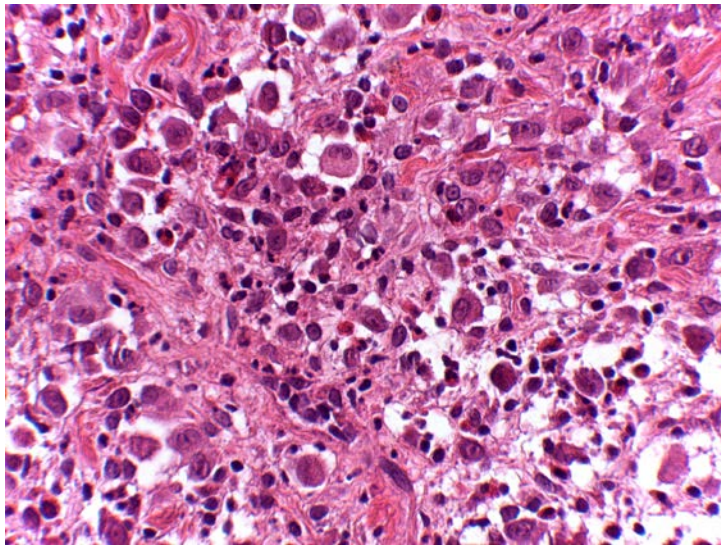


Figure 3. Hematoxylin and eosin. Dermal infiltrate of Langerhans cells, with reniform nuclei and abundant eosinophilic cytoplasm, admixed with eosinophils and lymphocytes, (20x). **Figure 4.** Strong immunoreactivity for CD1a, (20x).

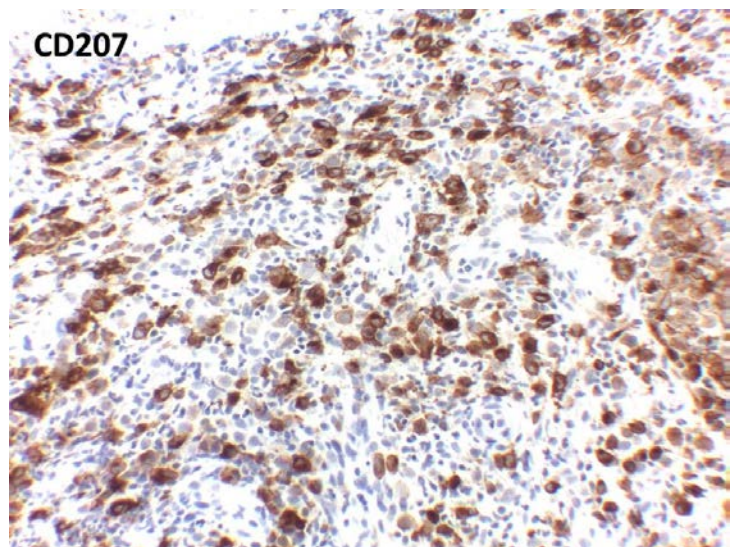
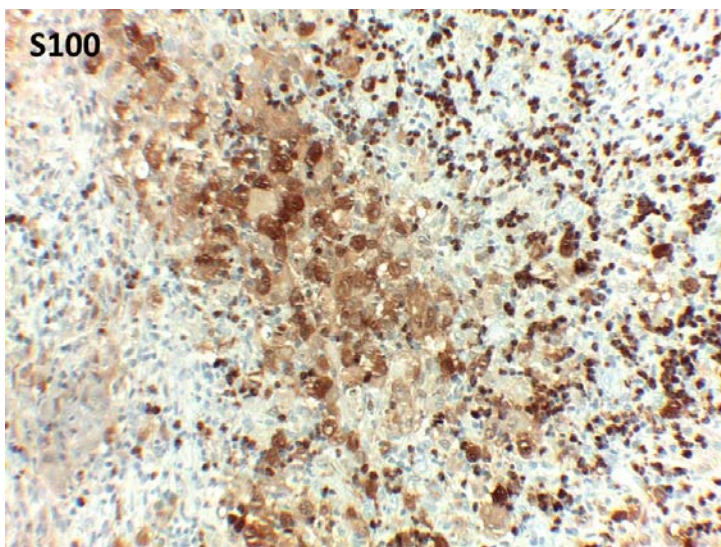


Figure 5. Strong immunoreactivity for S100, (20x). **Figure 6.** Strong immunoreactivity for CD207, (20x).

Blood count, coagulation studies, liver and kidney function tests, urine analysis, chest radiography, skeletal survey, and abdominal ultrasound were normal. Therefore, a diagnosis of congenital skin-limited Langerhans cell histiocytosis was established.

By the age of two months lesions had resolved without treatment (Figure 7), but the follow up examination showed the recent development of an orange abdominal plaque with positive Darier sign —urtication after stroking the lesion— (Figure 8). A new biopsy showed oval cells with abundant amphophilic cytoplasm, round central nuclei, and fried egg appearance (Figure 9). They exhibited strong immunoreactivity for CD117 (c-kit) and tryptase, confirming the clinical diagnosis of mastocytoma. Langerhans cell histiocytes were not observed.

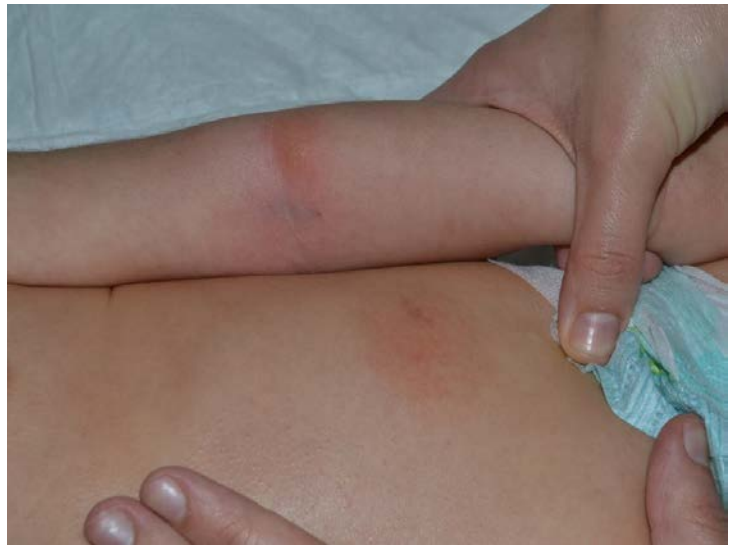
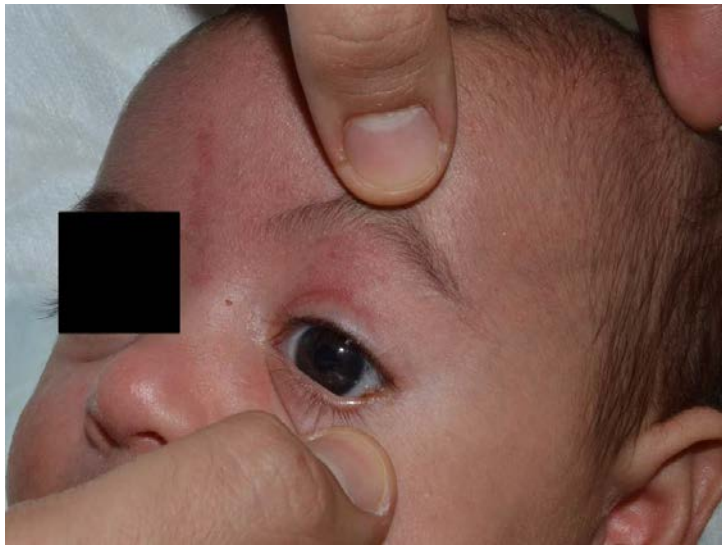
Figure 7. Spontaneous resolution of the nodule on the eyelid by the age of two months. **Figure 8.** Orange plaques on the abdomen and left forearm (see the peau d'orange appearance and Darier's sign in the later).

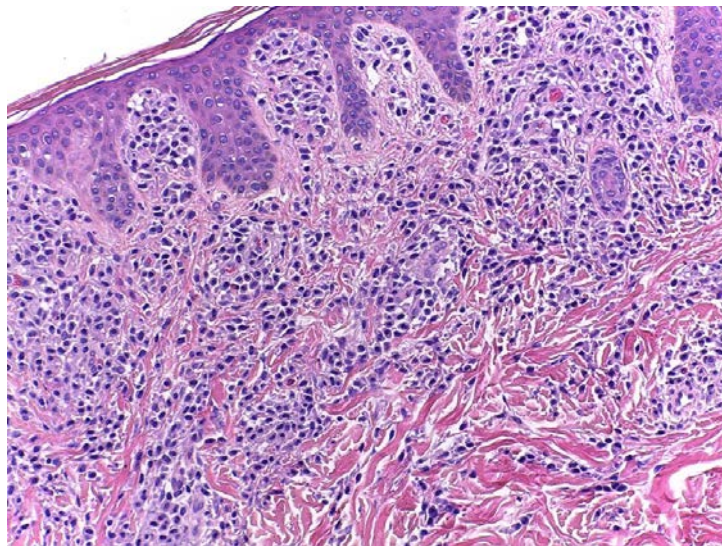


Figure 9. Hematoxylin and eosin. Dermal mast cells infiltrate, with oval abundant amphophilic cytoplasm, round central nuclei and fried egg appearance (10x).

By the age of eight months, a new yellow peau d'orange plaque was observed on his left forearm, again clinically concordant with mastocytoma. Serum tryptase was 5.95 ng/mL (increased tryptase level when greater than or equal to 20 ng/mL). Cytomegalovirus IgM antibodies were positive. Congenital infection was excluded by determining cytomegalovirus IgM antibodies and C-reactive protein in the blood taken for heel prick test at birth. Control serology and urine C-reactive protein were negative too. Physical examination and complementary studies (full blood count, coagulation, liver and kidney function) every 6 months have not shown relapse. Mastocytomas are still present after 2-years of follow-up.

Discussion

Langerhans cells are antigen-presenting dendritic cells derived from bone marrow and generally localized in epidermis and lymph nodes. Langerhans cell histiocytosis is a proliferation of clonal cells more consistent with immature myeloid dendritic cells precursors (CD207 or langerin +) than epidermal Langerhans cells [1], which involve different organs with a broad clinical spectrum from isolated skin lesions to multisystem life-threatening disease [2]. Common (almost 60%) oncogenic somatic BRAF-V600E mutations support the consideration of this disease as a neoplasm [3]. Moreover, a recent report shows that BRAF-V600E expression in circulating blood cells is associated with disease severity and increased risk of recurrence when mutated in tissue [4]. An alternative hypothesis states that Langerhans cell histiocytosis is a reactive disease in the setting of immature dysregulation leading to an aberrant reaction between Langerhans cells and lymphocytes [5]. It could be triggered by viruses (human herpesvirus type 6, cytomegalovirus, Epstein-Barr virus). This point was the reason why

congenital cytomegalovirus infection was studied in our patient. However, other studies have not confirmed the viral association [6-8].

The morphology and evolution of our patient's lesions, as generalized papules and nodules, which tend to ulcerate and resolved without treatment, was previously called "congenital self-healing reticulohistiocytosis." This term is no longer used owing to documented cases that have evolved to multisystem disease years after resolution, which make long-term follow-up required [9]. Nevertheless, neonates with isolated skin involvement usually have a favourable prognosis [10].

Mastocytomas are a common type of cutaneous mastocytosis, which generally appear in the first year of life and resolve during childhood. They present as orange to yellow papules or plaques with positive Darier sign (urtication after stroking a lesion).

Mast cells originate in the bone marrow and mature through activation of the receptor CD117 (KIT), a transmembrane receptor with intrinsic tyrosine kinase activity. Gain of function mutations in c-Kit (mostly D816V) are capable of inducing neoplastic transformation of mast cells [11] and other different lineages, leading to mastocytosis, gastrointestinal stromal tumors (GISTs), and less commonly, melanoma and acute myeloid leukemia.

The association of mastocytosis and histiocytosis is not frequent [12-19]. Patients with coexisting mastocytosis and histiocytosis or coexisting histiocytic and mast cell infiltration are showed in Table 1. Mitsuya et al. described the infiltration of mast cells and Langerhans cells in the same lesion in a 2-year-old boy, diagnosed with mastocytosis with prominent Langerhans cell infiltration [12]. In the same way, significant mast cell infiltration in Langerhans cell histiocytosis has been documented; one case was congenital and self-healing [13, 14]. Tran et al. reported a coexisting mastocytoma with a prominent admixed infiltrate of CD68, xanthomatous histiocytes, and Touton-type giant cells [15]. In addition, there are four documented cases of coexistence of urticaria pigmentosa and juvenile xanthogranuloma in the literature [16, 17, 18, 19]. Tsutsui et al. propose that the increase in mast cells is responsible for the differentiation of histiocytes to dermal dendrocytes in coexisting urticaria pigmentosa and juvenile xanthogranuloma [16]. In our case, dermal mastocytosis appeared once nodules of Langerhans cell histiocytosis were apparently resolved.

Conclusion

Association of mastocytosis and histiocytosis, both bone-marrow-derived cells, is not frequent and the occurrence of mastocytomas and Langerhans cell histiocytosis present in our patient has never been described. Mastocytomas shows an indolent clinical course with spontaneous recovery and neonates with isolated cutaneous Langerhans cell histiocytosis have usually a favorable prognosis. It could be hypothesized that both clonal disorders could have a common origin, but the current knowledge about their pathogeny reveals different mutations, BRAF-V600E in LCH and c-Kit in mastocytosis.

References

1. Allen CE, Li L, Peters TL, Leung HC, Yu A, Man TK, et al. Cell-specific gene expression in Langerhans cell histiocytosis lesions reveals a distinct profile compared with epidermal Langerhans cells. *J Immunol* 2010;184:4557-67. [PMID:20220088]
2. Satter EK, High WA. Langerhans cell histiocytosis: a review of the current recommendations of the Histiocyte Society. *Pediatr Dermatol* 2008;25:291-5. [PMID:18577030].
3. Badalian-Very G, Vergilio JA, Degar BA, MacConaill LE, Brandner B, Calicchio ML, et al. Recurrent BRAF mutations in Langerhans cell histiocytosis. *Blood* 2010;116:1919-23. [PMID:20519626].
4. Berres ML, Lim KP, Peters T, Price J, Takizawa H, Salmon H, et al. BRAF-V600E expression in precursor versus differentiated dendritic cells defines clinically distinct LCH risk groups. *J Exp Med* 2014;211:669-83. [PMID:24638167].
5. Glotzbecker MP, Carpentieri DF, Dormans JP. Langerhans cell histiocytosis: a primary viral infection of bone? Human herpes virus 6 latent protein detected in lymphocytes from tissue of children. *J Pediatr Orthop*. 2004 Jan-Feb;24(1):123-9. [PMID:14676546].
6. McClain K, Jin H, Gresik V, Favara B. Langerhans cell histiocytosis: lack of a viral etiology. *Am J Hematol*. 1994 Sep;47(1):16-20. [PMID:8042610]
7. Jenson HB, McClain KL, Leach CT, Deng JH, Gao SJ. Evaluation of human herpesvirus type 8 infection in childhood langerhans cell histiocytosis. *Am J Hematol*. 2000 Aug;64(4):237-41. [PMID:10911374].
8. Jeziorski E, Senechal B, Molina TJ, Deveze F, Leruez-Ville M, Morand P, Glorion C, Mansuy L, Gaudelus J, Debre M, Jaubert F, Seigneurin JM, Thomas C, Joab I, Donadieu J, Geissmann F. Herpes-virus infection in patients with Langerhans cell histiocytosis: a case-controlled sero-epidemiological study, and in situ analysis. *PLoS One*. 2008 Sep 23;3(9):e3262. [PMID:18810271].
9. Larralde M, Rositto A, Giardelli M et al. Congenital self-healing Langerhans cell histiocytosis: the need of a long term follow up. *Int J Dermatol*. 2003 Mar;42(3):245-6. [PMID:12653927].

10. Simko SJ, Garmezy B, Abhyankar H, Lupo PJ, Chakraborty R, Lim KP, et al. Differentiating skin-limited and multisystem Langerhans cell histiocytosis. *J Pediatr* 2014;165:990-6. [PMID:25441388].
11. Orfao A, Garcia-Montero AC, Sanchez L, et al. Recent advances in the understanding of mastocytosis: the role of KIT mutations. *Br J Haematol* 2007;138:12–30. [PMID:17555444]
12. Mitsuya J, Hara H, Fukuda N, Terui T. A case of cutaneous mastocytosis in a child with prominent Langerhans cell infiltration. *Pediatric Dermatol* 2011;28:412-5. [PMID:20738800].
13. Foucar E, Piette WW, Tse DT, Goeken J, Olmstead AD. Urticating histiocytosis: a mast cell-rich variant of histiocytosis X. *J Am Acad Dermatol*. 1986 May;14(5 Pt 2):867-73. [PMID:2423566].
14. Butler DF, Ranatunge BD, Rapini RP. Urticating Hashimoto-Pritzker Langerhans cell histiocytosis. *Pediatr Dermatol*. 2001 Jan-Feb;18(1):41-4. [PMID:11207970]
15. Tran TD, Jokinen CH, Argenyi ZB. Histiocyte-rich pleomorphic mastocytoma: an uncommon variant mimicking juvenile xanthogranuloma and Langerhans cell histiocytosis. *J Cutan Pathol*. 2009 Nov;36(11):1215-20. [PMID:19602070].
16. Tsutsui K, Asai Y, Kawashima Y. Urticaria pigmentosa occurring with juvenile xanthogranuloma. *Br J Dermatol*. 1999 May;140(5):990-1. [PMID:10354062].
17. De Villez RL, Limmer BL. Juvenile xanthogranuloma and urticaria pigmentosa. *Arch Dermatol*. 1975 Mar;111(3):365-6. [PMID:804295].
18. Mann RE, Friedman KJ, Milgraum SS. Urticaria pigmentosa and juvenile xanthogranuloma: case report and brief review of the literature. *Pediatr Dermatol*. 1996 Mar-Apr;13(2):122-6. [PMID:9122068].
19. Gruber R, Vassilaki I, Zelger B. Concomitant juvenile xanthogranuloma and cutaneous mastocytosis in a 3-year-old Swedish girl: case report and review of the literature. *Int J Dermatol*. 2011 May;50(5):611-4. [PMID:21349079].