

UC Davis

Dermatology Online Journal

Title

Follicularly-based papules on the thigh of a young woman

Permalink

<https://escholarship.org/uc/item/4n16w881>

Journal

Dermatology Online Journal, 22(1)

Authors

Brahmbhatt, Shreena
Wu, Peggy A
Zimarowski, Mary Jane
et al.

Publication Date

2016

License

[CC BY-NC-ND 4.0](#)

Peer reviewed

Photo vignette

Follicularly-based papules on the thigh of a young woman

Shreena Brahmhatt MD¹, Peggy A Wu MD², Mary Jane Zimarowski MD³, Susan Burgin MD²

Dermatology Online Journal 22 (1): 12

¹John T. Mather Memorial Hospital, Stony Brook School of Medicine

²Department of Dermatology and ³Department of Pathology, Beth Israel Deaconess Medical Center, Harvard Medical School.

Correspondence:

Susan Burgin, MD
Beth Israel Deaconess Medical Center
Department of Dermatology
330 Brookline Ave
GZ 522
Boston, MA 02215
Phone (617) 667-4995
Fax (617) 667-4948
Email: sburgin@bidmc.harvard.edu

Abstract

Varicella zoster virus (VZV) is an uncommon cause of folliculitis. We present a case of a 29-year-old woman who presented with an atypical follicularly-based eruption localized to her inner thigh with an associated pain in her lower back and inner thigh prior to the papular eruption. She was successfully treated with valacyclovir 1,000 mg three times daily with no complications.

Keywords: herpes, folliculitis, Varicella zoster virus

Introduction

Varicella zoster virus (VZV) is an uncommon cause of folliculitis that should be considered in the differential diagnosis of an atypical follicularly-based eruption.

Case synopsis

A 29-year-old woman presented with a localized follicularly-based eruption on her right upper inner thigh, which she noticed a week before presentation. She had experienced pain in her lower back and inner thigh prior to noticing the rash, which was partially alleviated by ibuprofen. Other symptoms included pruritus and a burning sensation. The patient was afebrile and systemically well with no significant contributing medical problems.

Cutaneous examination revealed grouped follicular-based papules on the right upper inner thigh, some with a central hemorrhagic crust (Figure. 1). A 4 mm punch biopsy was performed.

The biopsy results confirmed a diagnosis of herpes folliculitis. Sections revealed superficial and deep perivascular, periadnexal (follicular and eccrine), and perineural lymphohistiocytic inflammation, with necrosis and multinucleated cells within the follicular epithelium (Figure. 2a). There was scale crust within the follicular ostium, however, no intraepidermal vesicles were observed. Immunostain was positive for varicella zoster virus (VZV) and negative for herpes simplex virus (HSV) (Figure. 2b).

The patient began a course of valacyclovir 1,000 mg three times daily. Three days after starting therapy she reported improvement in burning and pruritus. Two weeks following her diagnosis, the patient's eruption had completely resolved with no post-herpetic neuralgia.

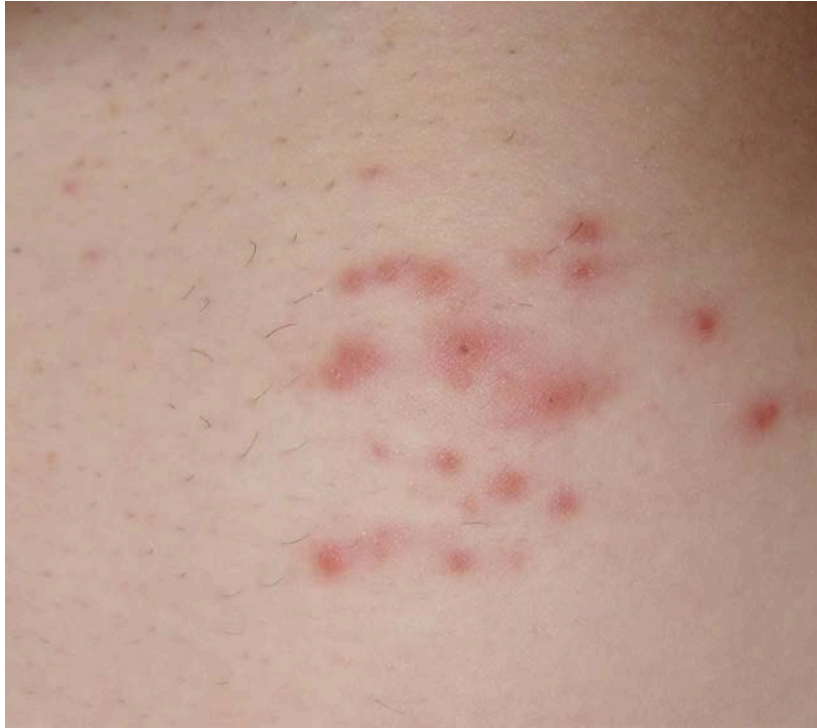

Figure 1. Follicularly-based papules, some eroded and crusted, clustered on the inner upper thigh

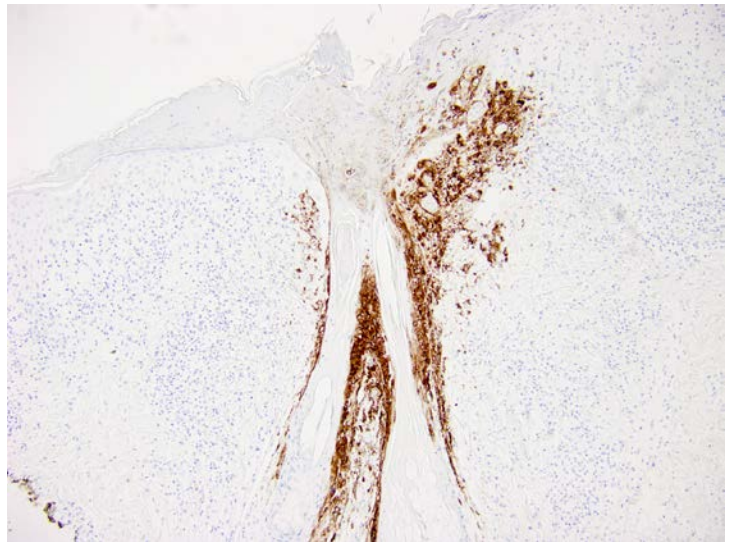
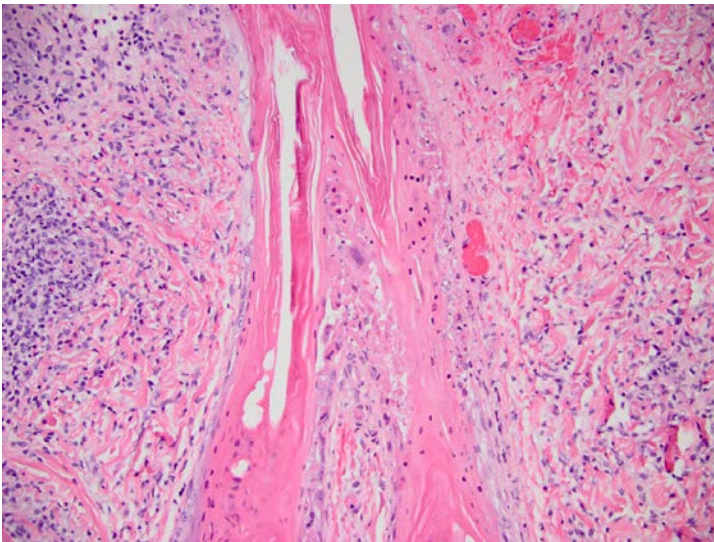


Figure 2A. Marked follicular epithelial necrosis and occasional follicular multinucleated giant cells. There is adjacent perifollicular and perivascular lymphocytic inflammation. H&E 100x. **Figure 2B.** Immunostain for VZV shows strong cytoplasmic staining within the follicular epithelium. The epidermis lacks intraepidermal vesicles and stains negative. VZV stain 40x.

Discussion

Herpes folliculitis is a rare manifestation of the herpesvirus family. Folliculitis secondary to varicella zoster virus has been more frequently reported than herpes simplex folliculitis from HSV 1 and 2 [1].

Making the clinical diagnosis of herpes folliculitis is often difficult as typical signs of herpesvirus infection (vesicles and pustules) are usually absent [2, 3]. HSV folliculitis presents as grouped, painful, follicular papules, usually in the beard area or on the face [2, 3, 4]. VZV folliculitis may be seen in both varicella and zoster infections and has a heterogeneous presentation [1, 5]. Vesicular or pustular folliculitis is typically seen when the infection affects the follicular ostium, whereas a deeper infection presents clinically as non-descript inflammatory papules and plaques, often requiring a biopsy for diagnosis [5]. Microscopic findings of herpes folliculitis infection usually include intraepithelial vesiculation owing to acantholysis, with accompanying cytopathic changes [6]. Dense and deep infiltrates of lymphocytes are seen within and around the adnexal structures, along with necrotic follicular keratinocytes and extravasated erythrocytes [1]. In HSV infections and varicella infections, follicular involvement is usually accompanied by changes in surface epidermis, including intraepidermal vesiculation with ballooning and acantholysis. In zoster infections there are more subtle changes in the epidermis such as scattered lymphocytes in the basal layer of the epidermis and necrotic keratinocytes [1]. Cytopathic changes in herpes folliculitis may be focal and some cases may not show characteristic viral changes related to sampling. Pathologic clues to the diagnosis include inflammation of sebaceous glands (sebaceitis), lichenoid inflammation, focal vasculitic changes, and perineural inflammation.

VZV is reported to travel through sensory myelinated neurons that terminate in folliculosebaceous units, especially the isthmus and sebaceous glands [1, 7, 8]. This may account for the lack of epidermal changes seen in VZV folliculitis [1]. In contrast, HSV travels through unmyelinated neurons that innervate the epidermis directly [6] and HSV folliculitis is thought to occur following compromise of the epidermis, such as by shaving [3].

Although antiviral therapy is indicated for the treatment of herpes folliculitis, the optimal dose of antiviral agents has not yet been studied.

Conclusion

It is important to consider the diagnosis of zoster folliculitis with the presentation of acute-onset, grouped, follicularly-based lesions, so as to prevent the sequelae of VZV infection, such as post-herpetic neuralgia.

References

1. Böer A, Herder N, Winter K, Falk T. Herpes folliculitis: clinical, histopathological, and molecular pathologic observations. *Br J Dermatol* 2006; 154: 743-746. [PMID: 16536821]
2. Sexton M. Occult herpesvirus folliculitis clinically simulating pseudolymphoma. *Am J Dermatopathol* 1991; 13: 234-240. [PMID: 1714247]
3. Weinberg JM, Mysliwiec A, Turiansky GW, Redfield R, James WD. Viral folliculitis. Atypical presentations of herpes simplex, herpes zoster, and molluscum contagiosum. *Arch Dermatol* 1997; 133: 983-986. [PMID: 9267244]
4. Izumi AK, Kim R, Arnold H Jr. Herpetic sycosis. Report of two cases. *Arch Dermatol* 1972; 106: 372-374. [PMID: 4341135]
5. Nikkels AF, Pierard GE. Necrotizing varicella zoster virus folliculitis. *Eur J Dermatol* 2003; 13: 587-589. [PMID: 14721782]
6. Walsh N, Boutilier R, Glasgow D, Shaffelburg M. Exclusive involvement of folliculosebaceous units by herpes: a reflection of early herpes zoster. *Am J Dermatopathol* 2005; 27: 189-194. [15900120]
7. Tilley DH, Satter EK, Kakimoto CV, Lederman ER. Disseminated verrucous varicella zoster with exclusive follicular involvement. *Arch Dermatol* 2012;148(3): 405-407. [PMID: 22431794]
8. Muraki R, Iwasaki T, Sata T, Sato Y, Kurata T. Hair follicle involvement in herpes zoster: pathway of viral spread from ganglia to skin. *Virchows Arch* 1996; 428 :275-280. [PMID: 8764937]