

# UCLA

## UCLA Previously Published Works

### Title

Community acquired *Stenotrophomonas maltophilia* discitis: Diagnosis aided by shotgun metagenomic sequencing

### Permalink

<https://escholarship.org/uc/item/4n85m8jn>

### Journal

International Journal of Infectious Diseases, 81

### ISSN

1201-9712

### Authors

Wang, Gang

Xu, Nannan

Yang, Lulu

et al.

### Publication Date

2019-04-01

### DOI

10.1016/j.ijid.2019.01.032

Peer reviewed



## Case Report

## Community acquired *Stenotrophomonas maltophilia* discitis: Diagnosis aided by shotgun metagenomic sequencing

Gang Wang<sup>a</sup>, Nannan Xu<sup>a</sup>, Lulu Yang<sup>a</sup>, Feng Zheng<sup>a</sup>, Lintao Sai<sup>a</sup>, Jiale Zhou<sup>b</sup>, Shangxin Yang<sup>c,d,\*</sup>

<sup>a</sup> Department of Infectious Diseases, Qilu Hospital, Shandong University, Jinan, Shandong, China

<sup>b</sup> IngeniGen XunMinKang Biotechnology Inc., Hangzhou, Zhejiang, China

<sup>c</sup> Zhejiang-California International Nanosystems Institute, Zhejiang University, Hangzhou, China

<sup>d</sup> Department of Pathology and Laboratory Medicine, UCLA School of Medicine, Los Angeles, CA, USA



## ARTICLE INFO

## Article history:

Received 21 November 2018

Received in revised form 12 January 2019

Accepted 17 January 2019

Corresponding Editor: Eskild Petersen, Aarhus, Denmark

## Keywords:

*Stenotrophomonas maltophilia*

Discitis

Epidural abscess

Shotgun metagenomic sequencing

Dry cupping therapy

## ABSTRACT

We report a rare case of culture negative L4-L5 discitis and epidural abscess in an immunocompetent child who had dry cupping therapy performed to treat low back strain. The causative pathogen was identified as *Stenotrophomonas maltophilia* by shotgun metagenomic sequencing of spinal cord aspirate after more than one month of unsuccessful empirical treatment with 6 different antibiotics. The patient was successfully treated with Sulfamethoxazole-trimethoprim and minocycline. Cupping therapy is a very popular medical procedure widely used in China, but the potential risk for severe infections such as discitis and epidural abscess described in this case should be recognized.

© 2019 The Author(s). Published by Elsevier Ltd on behalf of International Society for Infectious Diseases. This is an open access article under the CC BY-NC-ND license (<http://creativecommons.org/licenses/by-nc-nd/4.0/>).

## Introduction

*Stenotrophomonas maltophilia* is a Gram-negative bacillus found widely in water, soil, plants, animals and hospital environments (Brooke, 2012). A significant opportunistic pathogen in hospitalized patients, *S. maltophilia* frequently causes pneumonia and other infections in the bloodstream, heart, urinary tract, abdominal cavity, skin and soft tissue, bone and joint, eye, and central nervous system (Brooke, 2012; Kataoka et al., 2003). In the community setting, *S. maltophilia* mainly causes infections in patients with underlying conditions such as chronic obstructive pulmonary disease, cystic fibrosis, malignancy, liver disease, HIV infection, transplantation, or other immunosuppressive conditions (Brooke, 2012; Falagas et al., 2009). Other risk factors for community-acquired infections with *S. maltophilia* include use of indwelling devices, antibiotic treatment, prior hospitalization history and trauma (Brooke, 2012; Sattler, 2000). The most prominent characteristic of *S. maltophilia* is its intrinsic resistance to many antibiotics that are routinely used for empirical treatment, including most beta-lactam agents and

aminoglycosides (Brooke, 2012). Therefore, accurate identification of this species is essential for effective treatment.

Cupping therapy is a very popular oriental medical procedure for pain relief in China. There are two types of cupping therapy: dry cupping involves using fire matches to heat the air in a cup and putting the cup upside down on the skin to create negative pressure as the air inside the cup cools down; wet cupping is slightly invasive and involves making small incisions in the skin to let a certain amount of blood be drawn out by the suction. Wet cupping is known to be associated with increased risk of infections, particularly in the spine, and at least 3 cases of wet cupping related epidural abscess have been reported (Lee et al., 2012; Turtay et al., 2014; Yao et al., 2016). Dry cupping, on the other hand, has rarely been associated with severe infections. To date, only two cases of dry cupping associated cutaneous infections have been reported (Jung et al., 2011; Lee et al., 2014). We report a rare case of dry cupping therapy related severe infection in the spinal cord caused by *S. maltophilia* in an immunocompetent 12-year-old child, which was diagnosed with the aid of shotgun metagenomic sequencing and subsequently treated with effective antibiotic combination therapy.

## Case report

A 12-year-old female student without any underlying condition suffered lumbago due to an accidental sprain in the lower back

\* Corresponding author at: Department of Pathology and Laboratory Medicine, UCLA School of Medicine, Los Angeles, CA, USA.

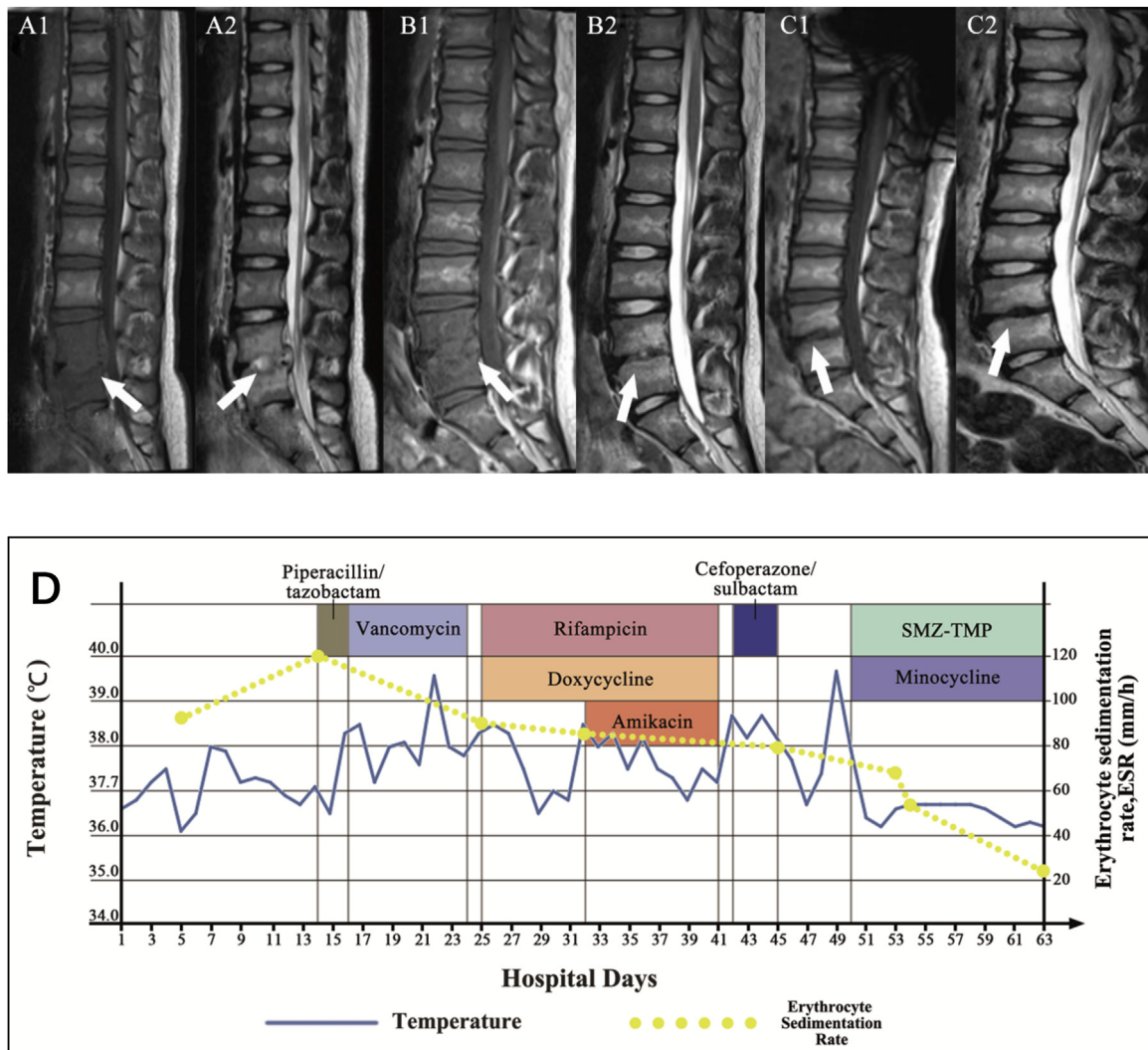
E-mail addresses: [Wang1975@hotmail.com](mailto:Wang1975@hotmail.com) (G. Wang), [shangxinyang@mednet.ucla.edu](mailto:shangxinyang@mednet.ucla.edu) (S. Yang).

when she tried to lift a bucket of water. She was treated for pain at a local clinic where dry cupping followed by pain relief patches were applied to her lower back, but her symptoms worsened after one week. Upon admission to the hospital, the patient was afebrile, and all her vital signs were unremarkable. There was no spine deformity, but the patient had severe pain in the L3–L5 area. Magnetic resonance imaging (MRI) showed abnormality in the L4 and L5 region and paravertebral phlegmon, suggesting discitis and possible epidural abscess (Figure 1A). Laboratory results showed normal white blood cells ( $8.17 \times 10^9/L$ ) with 60.4% neutrophils, normal procalcitonin (0.20 ng/ml), but highly elevated erythrocyte sedimentation rate (ESR) (120 mm/h) and slightly elevated C-reactive protein (CRP) (10.59 mg/l). Patient was given piperacillin/tazobactam 4.5 g q12 h IV. On hospital day 5, the patient started spiking a fever of 38°C accompanied with chills, but blood culture was negative. On hospital day 9, the antibiotic was adjusted to vancomycin 1.0 g q12 h IV. The patient's lower back pain was slightly improved, but her fever persisted, with a temperature fluctuating between 37.2 and 39.6°C.

At this point, a concern for brucellosis was raised since it is common in the region and the infection commonly presents with undulant fever (Zhong et al., 2013). The patient was transferred to a

special infectious disease unit and started treatment with rifampicin 0.6 g qd plus doxycycline 0.1 g bid orally. The patient's fever gradually decreased after 5 days of treatment for presumptive brucellosis; however, on the 8th day of treatment with rifampicin plus doxycycline, the patient's fever spiked again. Due to a concern of inadequate antibiotic treatment, amikacin 0.4 g qd IV was added. However, neither the blood culture nor the brucellosis agglutination test came back positive, and the patient's fever and lower back pain persisted. A second MRI of the spinal cord showed no improvement (Figure 1B).

As brucellosis was ruled out, the patient was transferred back to the main hospital and empirically treated with cefoperazone/sulbactam for 4 days until discontinuation 2 days before a spinal cord biopsy was performed. The spinal cord tissue and aspirate was sent for bacterial and fungal culture as well as histological examination. In addition, an aliquot of the spinal cord aspirate was sent for shotgun metagenomic sequencing (DiAn Diagnostics, Shandong, China). Cultures of the spinal cord samples were all negative and pathological examination indicated epidural abscess with damaged bones and many neutrophils. Three days later, metagenomic sequencing results came back positive for *S. maltophilia* with 784 sequence reads (supplemental Figure S1),



**Figure 1.** Initial MRI (A1, A2) showed high T1 signal and hyperintense T2 signal in the L4–L5 disc, suggesting intervertebral disc inflammation (white arrow) and mild spinal cord compression. MRI (B1, B2) performed one month later showed no change (white arrow). MRI (C1, C2) performed 4 months later showed disappearance of the L4–L5 disc inflammation (white arrow) and alleviation of spinal cord involvement. (D) Hospitalization course with the timeline of antibiotic treatment and the changes in the body temperature and inflammatory marker ESR.

which was categorized as high abundance (>500 reads) according to the reference laboratory. Based on this result, the treatment was changed to Sulfamethoxazole-trimethoprim (SMZ-TMP) 800 mg/160 mg q8 h combined with minocycline 100 mg q12 h administered orally. Within 4 days, the patient's body temperature returned to normal and the back pain had improved significantly. ESR levels also returned to the normal range gradually (Figure 1D). Surgical drainage was recommended but our patient chose not to undergo surgery. Fortunately, 14 days after the start of SMZ-TMP plus minocycline treatment, the patient's back pain had completely resolved and thus she was discharged from the hospital with a prescription to finish up the overall 8-week treatment course. Two months later, a follow-up MRI showed full recovery in the spine (Figure 1C). Five months later, at the time of writing this manuscript, a phone interview with the patient's parent confirmed the patient had no back pain issues and had resumed regular physical activities including attending physical education classes in school.

## Discussion

*S. maltophilia* rarely causes bone or joint infections in the community setting, but cases of spondylodiscitis, arthritis, and bursitis have been reported in patients with immunosuppression or other underlying conditions (Aydemir et al., 2008; German et al., 2007; Papadakis et al., 1996). However, our patient was previously healthy and did not have any remarkable risk factors except that she was given traditional dry cupping therapy at a local clinic one week before her symptoms worsened. We did not recall seeing bruises or injury on her skin in the affected area, but it is possible that small abrasions created by cupping therapy may have compromised the skin barrier and allowed the bacteria to enter the body. This case proved to be very challenging as all culture results were negative, most likely due to empirical antibiotic treatment. When the metagenomic sequencing result identified the pathogen as *S. maltophilia*, we initially suspected that it may have been an environmental contaminant. We performed a laboratory developed PCR test targeting the *smeT* gene specific to *S. maltophilia*, which was positive in the spinal tissues, thus confirming the results of the metagenomic sequencing (supplemental Figure S2). Our case report adds to a growing body of literature illustrating the value of metagenomic sequencing for pathogen detection (Fang et al., 2018; Thoendel et al., 2018) and highlights its utility in cases of culture-negative infections, especially when patients have been empirically treated for a prolonged period of time. To the best of our knowledge, this is the first case report of community acquired discitis and epidural abscess associated with dry cupping therapy in an immunocompetent child. Cupping therapy is a very popular alternative medicine practiced widely in China, but a possible risk for severe infections in the spinal cord should be recognized.

## Acknowledgement

We thank Dr. Fan Li (University of California, Los Angeles Mattel Children's Hospital) who helped edit and revise the manuscript.

## Funding

This study was funded by Shandong University Qilu Hospital Department of Infectious Diseases, and by IngeniGen XunMinKang Biotechnology Inc., Hangzhou, Zhejiang, China.

## Ethical approval

This study was approved by Shandong University Qilu Hospital human research protection committee (IRB # KYLL-2017-612). A written consent was also acquired from the patient and her parents.

## Conflict of interest and declaration

The authors declare no conflict of interest. All authors approve the final version of the case report to be published and agree to be accountable for all aspects of the case report in ensuring that questions related to the accuracy or integrity of any part of the case report are appropriately investigated and resolved.

## Author contributions

Gang Wang, Nannan Xu, Lulu Yang, Feng Zheng and Lintao Sai contributed to the care of the patient. Shangxin Yang, Gang Wang, Nannan Xu and Lulu Yang, and Feng Zheng conceived and designed the experiments. Lulu Yang, Feng Zheng, Lintao Sai performed the experiments, Gang Wang, Nannan Xu, Jiale Zhou, and Shangxin Yang analyzed the data. Gang Wang, Nannan Xu, Jiale Zhou, and Shangxin Yang drafted or revised the manuscript.

## Appendix A. Supplementary data

Supplementary data associated with this article can be found, in the online version, at <https://doi.org/10.1016/j.ijid.2019.01.032>.

## References

- Aydemir C, Aktas E, Eldes N, Kutsal E, Demirel F, Ege A. Community-acquired infection due to *Stenotrophomonas maltophilia*: a rare cause of septic arthritis. *Turk J Pediatr* 2008;50(1):89–90.
- Brooke JS. *Stenotrophomonas maltophilia*: an emerging global opportunistic pathogen. *Clin Microbiol Rev* 2012;25(1):2–41.
- Falagas ME, Kastoris AC, Vouloumanou EK, Dimopoulos G. Community-acquired *Stenotrophomonas maltophilia* infections: a systematic review. *Eur J Clin Microbiol Infect Dis* 2009;28(7):719–30.
- Fang X, Xu M, Fang Q, Tan H, Zhou J, Li Z, et al. Real-time utilization of metagenomic sequencing in the diagnosis and treatment monitoring of an invasive adenovirus B55 infection and subsequent herpes simplex virus encephalitis in an immunocompetent young adult. *Open Forum Infect Dis* 2018;5(6):ofy114.
- German V, Tsimpoukas F, Goritsas C, Ferti A. Spondylodiscitis due to *Stenotrophomonas maltophilia*. *Eur J Intern Med* 2007;18(6):501–3.
- Jung YJ, Kim JH, Lee HJ, Bak H, Hong SP, Jeon SY, et al. A herpes simplex virus infection secondary to acupuncture and cupping. *Ann Dermatol* 2011;23(1):67–9.
- Kataoka D, Fujiwara H, Kawakami T, Tanaka Y, Tanimoto A, Ikawa S, et al. The indirect pathogenicity of *Stenotrophomonas maltophilia*. *Int J Antimicrob Agents* 2003;22(6):601–6.
- Lee JH, Cho JH, Jo DJ. Cervical epidural abscess after cupping and acupuncture. *Complement Ther Med* 2012;20(4):228–31.
- Lee SY, Sin JI, Yoo HK, Kim TS, Sung KY. Cutaneous *Mycobacterium massiliense* infection associated with cupping therapy. *Clin Exp Dermatol* 2014;39(8):904–7.
- Papadakis KA, Vartivarian SE, Vassilaki ME, Anaissie EJ. Septic prepatellar bursitis caused by *Stenotrophomonas (Xanthomonas) maltophilia*. *Clin Infect Dis* 1996;22(2):388–9.
- Sattler CA. *Stenotrophomonas maltophilia* infection in children. *Pediatr Infect Dis J* 2000;19(9):877–8.
- Thoendel MJ, Jeraldo PR, Greenwood-Quaintance KE, Yao JZ, Chia N, Hanssen AD, et al. Identification of prosthetic joint infection pathogens using a shotgun metagenomics approach. *Clin Infect Dis* 2018;67(9):1333–8.
- Turtay MG, Turgut K, Oguzturk H. Unexpected lumbar abscess due to scarification wet cupping: a case report. *Complement Ther Med* 2014;22(4):645–7.
- Yao Y, Hong W, Chen H, Guan Q, Yu H, Chang X, et al. Cervical spinal epidural abscess following acupuncture and wet-cupping therapy: a case report. *Complement Ther Med* 2016;24:108–10.
- Zhong Z, Yu S, Wang X, Dong S, Xu J, Wang Y, et al. Human brucellosis in the People's Republic of China during 2005–2010. *Int J Infect Dis* 2013;17(5):e289–92.