

# UC Irvine

## UC Irvine Previously Published Works

### Title

Epstein-Barr virus-associated lymphoproliferative disorders

### Permalink

<https://escholarship.org/uc/item/4p5017cz>

### Journal

Human Pathology, 38(9)

### ISSN

0046-8177

### Authors

Rezk, Sherif A  
Weiss, Lawrence M

### Publication Date

2007-09-01

### DOI

10.1016/j.humpath.2007.05.020

### Copyright Information

This work is made available under the terms of a Creative Commons Attribution License, available at <https://creativecommons.org/licenses/by/4.0/>

Peer reviewed

**Progress in pathology****Epstein-Barr virus–associated lymphoproliferative disorders****Sherif A. Rezk MD, Lawrence M. Weiss MD\****Department of Pathology, City of Hope National Medical Center, Duarte, CA 91010, USA*

Received 18 April 2007; accepted 22 May 2007

**Keywords:**

Epstein-Barr virus;  
B-cell lymphoproliferative disorders;  
T-cell lymphoproliferative disorders;  
HIV-associated lymphoproliferative disorders

**Summary** Epstein-Barr virus (EBV) is a member of the human herpesvirus family that was initially isolated from a cultured Burkitt lymphoma cell line by Epstein et al in 1964. Subsequent studies have proven that it is the causative agent in most cases of infectious mononucleosis. Primary infection is usually asymptomatic in childhood; but in adulthood, it is associated with a self-limiting infectious mononucleosis syndrome in approximately one third of the cases. EBV has been linked to many human neoplasms including hematopoietic, epithelial, and mesenchymal tumors. In this review, we will only discuss the EBV-associated lymphoproliferative disorders, dividing them into B-cell, T/NK-cell, and HIV-related lymphoproliferative disorders.

© 2007 Published by Elsevier Inc.

**1. Introduction**

Epstein-Barr virus (EBV), a member of the human herpesvirus family, is a linear, double-stranded DNA virus that was initially isolated from a cultured Burkitt lymphoma cell line by Epstein et al in 1964 [1]. Subsequent studies have proven that it is the causative agent in most cases of infectious mononucleosis [2]. Currently, it is estimated that more than 90% of the adult population worldwide are infected by the virus [3]. Primary infection is usually asymptomatic in childhood; but in adolescence or adulthood, it is associated with a self-limiting infectious mononucleosis syndrome in approximately one third of the cases [4,5]. The virus is secreted in the saliva, and human infection occurs through oral transmission [6]. Oropharyngeal infection results in a lytic (productive) infection followed by infection of circulating B cells, leading to persistence of the viral DNA

as an episome in the nucleus, thus establishing latent infection [7,8].

In lytic infection, EBV-encoded genes selectively replicate virion components including viral DNA genomes and proteins. In latent infection, EBV-encoded genes, which include 6 nuclear antigens (EBNA 1, 2, 3A, 3B, 3C, and LP), 3 latent membrane proteins (LMP 1, 2A, and 2B), 2 small noncoding RNAs (EBER1 and EBER2), and *BamHI-A* rightward transcripts, maintain the existence of the viral genome and enable it to evade immune surveillance [3,9]. A summary of the most important latent proteins is tabulated in Table 1. Three distinct latency programs that are equivalent to the differentiation state of B cells have been postulated after analysis of EBV-infected B cells in cell lines and seropositive individuals [3,10]. The presence of different EBV latency programs is thought to have evolved in order for EBV-infected cells to survive in the face of an adaptive immune response and surveillance [10,11].

Type III latency (growth program) pertains to EBV-infected naive B cells that express all the latent antigens (Fig. 1). The naive infected B cells enter the germinal center

\* Corresponding author.

E-mail address: lweiss@coh.org (L. M. Weiss).

**Table 1** Latent EBV-encoded genes

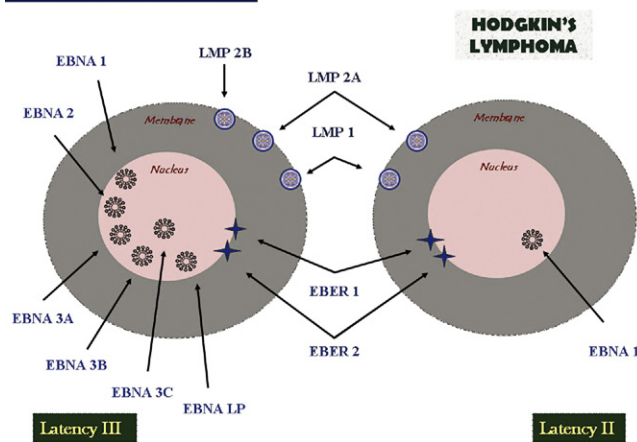
EBV-encoded genes	Location	Function	Latency type
EBNA-1	Nucleus	Considered the viral genome maintenance protein, where it binds to the origin of replication of the EBV episome leading to replication of the virus DNA [8]. It also plays a role in the transcriptional regulation of other latent nuclear and membranous proteins. It is not recognized by cytotoxic T cells.	I, II, III
EBNA-2	Nucleus	Transcriptional regulator and activator of several cellular and viral genes, such as LMP-1 and LMP-2 [8]. It has also been reported that it may target the <i>c-MYC</i> oncogene, thus affecting EBV-induced B-cell proliferation [69].	III
EBNA-3	Nucleus	Transcriptional regulator that influences viral and cellular gene expression in EBV-infected cells and may play a role in alteration of the B-cell homing process [10]. It may also play a role in B-cell transformation.	III
LMP-1	Membrane	Considered the main transforming protein of EBV and the major effector of virus-induced cellular changes. It inhibits apoptosis by activating the NF- $\kappa$ B pathways leading to upregulated expression of <i>bcl-2</i> and other target genes. It can also mimic CD40-induced signaling pathway.	II, III
LMP-2	Membrane	An intrinsic membrane protein that prevents EBV-infected cells from entry into the lytic cycle by sequestering tyrosine kinases from BCR, resulting in inhibition of BCR signaling. It also can mimic BCR and replace survival signals for B cells, normally supplied by BCR.	II, III
EBER1 and EBER2	Nucleus	Nonpolyadenylated RNAs that are not essential for the EBV-induced transformation of B lymphocytes. They are mainly used for the clinical detection of the virus because of their abundant expression. They can induce production of IL-10, which might suppress cytotoxic T cells and stimulate growth of infected B cells. EBERs have also been thought to play a role in modulation of pathways important in interferon response.	I, II, III

(GC) where they proliferate and clonally expand, thus increasing the EBV-infected pool of cells. These GC infected cells show a restricted EBV gene expression pattern (EBNA-1, LMP-1, LMP-2), which is referred to as the *type II latency* (default program) [10]. The infected GC cells then differentiate into memory B cells, which function as the long-term reservoir for EBV. Most of the infected memory B cells in the periphery seem not to express any of the viral antigens (considered by some as type 0 latency); but some only express EBNA-1, which has been referred to as *type I*

*latency* [12,13]. The EBV latency patterns in different EBV-associated diseases are summarized in Table 2.

EBV has been linked to many human neoplasms including hematopoietic, epithelial, and mesenchymal tumors. It has been associated with almost all cases of nasopharyngeal carcinoma [14], a subset of gastric carcinomas [15], lymphoepitheliomas of a variety of foregut sites [14], inflammatory pseudotumors of the liver and spleen [16], and HIV-associated smooth muscle neoplasms [17]. In this review, we will only discuss the EBV-associated lymphoproliferative disorders, dividing them into B-cell, T/NK-cell, and HIV-related lymphoproliferative disorders.

#### EBV latent encoded proteins



**Fig. 1** The different EBV latent encoded proteins expressed in type III latency program and in Hodgkin lymphoma (type II latency).

### 1.1. EBV-associated B-cell lymphoproliferative disorders

Despite its documented infection of T lymphocytes and epithelial cells in certain circumstances, EBV has a major predilection for B cells because they act as the reservoir for it to persist [4]. Consequently, the persistence of latent EBV genes in B cells results in a carrier state; and in certain occasions, transformation into malignant B-cell lymphomas may occur. Because of the preferential infection of B cells, B-cell lymphomas predominate among the EBV-related lymphoproliferative disorders.

EBV-associated B-cell lymphoproliferative disorders include Hodgkin lymphoma, Burkitt lymphoma, posttransplant

**Table 2** EBV latency patterns in different lymphoproliferative disorders

Disease	EBV latency programs
EBV-associated B-cell lymphoproliferative disorders	
Hodgkin lymphoma	Type II
Burkitt lymphoma	Type I
PTLD	Type III/type II
Lymphomatoid granulomatosis	Type III
Pyothorax-associated lymphoma	Type III
Senile EBV-associated B-cell lymphoproliferative disorders	Type III/type II
EBV-associated T/NK-cell lymphoproliferative disorders	
AILT	Presumed type II
Extranodal nasal T/NK-cell lymphoma	Type II
Hepatosplenic T-cell lymphoma	Not known
Nonhepatosplenic $\gamma\delta$ T-cell lymphomas	Type II
Enteropathy-type T-cell lymphoma	Presumed type II
Peripheral T-cell lymphoma	Type II
EBV-associated HIV-related lymphoproliferative disorders	
Primary CNS lymphoma	Type III
Primary effusion lymphoma	Type II
Plasmablastic lymphoma	Type 0 (only EBERs expressed)

lymphoproliferative disorders (PTLDs), lymphomatoid granulomatosis, pyothorax-associated lymphoma, and senile EBV-associated B-cell lymphoproliferative disorders. Hodgkin lymphoma will be discussed among the B-cell disorders because it has a B-cell origin and the role of EBV in the pathogenesis of the disease is probably mediated through infected B cells. Although primary effusion lymphoma and plasmablastic lymphoma are B-cell lymphomas, they will be discussed under HIV-related disorders. Furthermore, angioimmunoblastic T-cell lymphoma (AILT) will be discussed under T-cell disorders despite the fact the EBV acts predominantly through infecting B cells and not T cells.

**Hodgkin lymphoma** is a distinct disorder in which the characteristic neoplastic cells, known as *Reed-Sternberg cells* (HRS), are interspersed among an inflammatory milieu and only constitute about 2% of total tumor mass. Since it was initially described in 1832 by Sir Thomas Hodgkin [18], many classifications have been postulated for the disease. The most recent World Health Organization (WHO) classification divides Hodgkin lymphoma into classic and nonclassic entities based on different morphological, phenotypic, and molecular features [19]. Nodular lymphocyte-predominant Hodgkin lymphoma represents the nonclassic entity, whereas classic Hodgkin lymphomas include the

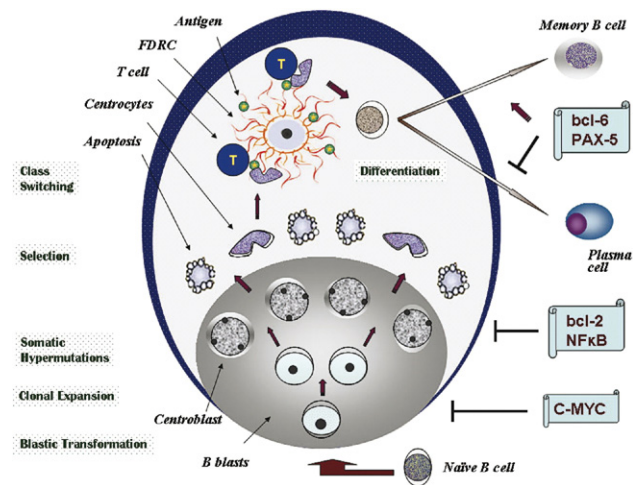
nodular-sclerosis, mixed-cellularity, lymphocyte-rich, and lymphocyte-depleted subtypes [19]. Fueled by the indeterminate immunophenotype possessed by HRS cells, the origin of HRS cells was up for intense debate for many years. The scarcity of HRS cells within the tumor tissue was a limiting factor for many studies in the past to accurately apply many standard molecular techniques. However, after isolation of single HRS cells and analyzing them using a single-cell polymerase chain reaction (PCR), it was determined that they are derived from GC B cells as a result of crippling mutations [20,21]. A rare T-cell origin has also been postulated in about 2% of the cases [22].

The identification of elevated antibodies titers to EBV antigens in Hodgkin lymphoma patients reported by Levine et al [23] in the early 1970s prompted other scholars to further study and investigate a potential role that EBV may play in the pathogenesis of Hodgkin lymphomas. In 1987, EBV DNA was initially detected by Weiss et al in Hodgkin lymphoma specimens using Southern blot hybridization studies [24]; however, localizing EBV DNA to HRS cells was not determined until a couple of years later by using in situ hybridization technique [25]. Subsequently, single-cell PCR has also confirmed the presence of EBV DNA in individual HRS cells [26].

EBV is more commonly associated with classic Hodgkin lymphoma, especially the mixed-cellularity subtype [9]. The nonclassic nodular lymphocyte-predominant Hodgkin lymphoma cases are very rarely associated with EBV [27]. Underdeveloped countries have an increased incidence of EBV-positive cases, which may be attributed to the existence of an underlying immunosuppression [12,28]. This is supported by the higher EBV-positive rates in HIV-positive Hodgkin lymphoma patients [29]. Sex and ethnicity are also factors in the epidemiology of EBV-positive Hodgkin cases, where males from a Hispanic or Asian (Chinese) origin tend to be more commonly affected [12,30]. A bimodal age distribution has been recognized for EBV-positive Hodgkin lymphoma patients; children and the older-age group tend to have much higher rates than young adults, the explanation of which may rely on the more competent immune surveillance in young adults as compared with the less developed or declined immune system in children and older individuals, respectively [30].

To better comprehend the role of EBV in the pathogenesis of Hodgkin lymphoma, one must understand the normal differentiation process of B cells within the GC (Fig. 2). Upon encountering an antigen, naive B cells become activated and migrate into the dormant B-cell follicles (primary follicles), undergo blast transformation, and differentiate into centroblasts (large noncleaved cells). The proliferating centroblasts activate the process of somatic hypermutations within the immunoglobulin variable (V) region, which results in marked intraclonal diversity [31]. Centroblasts then differentiate into centrocytes (small cleaved cells), which are positively selected based on the affinity of their B-cell receptor (BCR) to process the antigen





**Fig. 2** The projected scheme of B-cell differentiation and GC formation. Naive B cells are first activated in the paracortical area, undergo blastic transformation, rapidly duplicate, and clonally expand within hours, giving rise to centroblasts. Numerous somatic hypermutations occur within the immunoglobulin V region, resulting in marked intraclonal diversity to increase the affinity for the antigen trapped within the follicular dendritic meshwork. Centroblasts then differentiate into the less proliferative centrocytes, which are positively selected based on the affinity of their BCR to process the antigen. Centrocytes with mutations that decrease their affinity for the antigen are negatively selected and undergo programmed cell death (apoptosis). After an additional heavy chain class switching, the positively selected B cells leave the GC and differentiate into either memory B cells or plasma cells.

trapped within the follicular dendritic reticular cell (FDRC) meshwork. Centrocytes with mutations that lessen their affinity for the antigen are negatively selected and undergo programmed cell death (apoptosis). After an additional heavy chain class switching, the positively selected B cells leave the GC and differentiate into either memory B cells or plasma cells [31].

In classic Hodgkin lymphoma cases, molecular analysis has shown that the rearranged V regions of HRS cells contain somatic mutations but lack the intraclonal diversity, with considerable amount of such cases carrying nonsense or crippling mutations [21]. Under normal circumstances, such cells are usually eliminated by apoptosis in the GC unless they are rescued by receiving survival signals such as activation of BCR and CD40 receptors. However, in Hodgkin cases, these cells survive, indicating that HRS cells are derived from preapoptotic GC B cells that, aided by certain transforming events, have escaped the programmed cell death process. Some investigators speculate that the near-total loss of the B-cell identity in HRS cells may have enabled them to escape the selection process in the GC [32].

The pattern of expression of latent EBV-encoded genes in HRS indicates an important role for EBV in the rescue of these preapoptotic cells [8]. HRS cells exhibit type II latency, which includes LMP1, LMP2, EBNA1, and the EBERs (Fig. 1) [9]. LMP1 and LMP2A may mimic and replace

survival signals induced by activated CD40 and BCR, respectively. LMP1 resembles a constitutively active CD40 receptor [33], whereas LMP2A has been reported to mimic the presence of BCR in transgenic mice [34]. In addition to mimicking an activated CD40 receptor, LMP1 has also been postulated to prohibit apoptosis by upregulating the antiapoptotic protein bcl-2 [35] and mediating the activation of the nuclear factor- $\kappa$ B (NF- $\kappa$ B) signaling pathway [36]. Aside from inhibiting apoptosis, the activated NF- $\kappa$ B pathway plays a crucial role in the induction of proliferation in HRS cells [36]. NF- $\kappa$ B transcription factors are kept inactive by interactions with the inhibitor I $\kappa$ B. Signaling through various cell-surface receptors activates I $\kappa$ B kinases, which phosphorylate I $\kappa$ B, thus promoting its degradation and the eventual activation of the NF- $\kappa$ B pathway [31]. Although some have postulated a potential role of LMP1 in the deregulation of I $\kappa$ B proteins [37], the exact mechanism of activation of the NF- $\kappa$ B pathway by LMP1 remains largely unknown.

Another potential role for LMP1 is the downregulation of CD99. Loss of CD99 has been reported to be associated with generation of B cells with classic Hodgkin immunophenotype [38]. Kim et al have reported that LMP-1 transcriptionally reduces the expression of CD99 in Hodgkin lymphoma cases, but the mechanism of which is unknown [39]. LMP2 plays an important role in maintaining the EBV latency status and preventing the transition into the lytic cycle. However, other than its postulated role in rescuing HRS cells by mimicking the presence of BCR, its exact function in the pathogenesis of Hodgkin lymphoma remains to be determined. To our knowledge, EBNA1 has not been linked yet to any oncogenic activity in human beings.

**Burkitt lymphoma** was first described in children in equatorial Africa by Denis Burkitt in 1958 [40]. It is a highly proliferative B-cell tumor that includes 3 variants: endemic (affecting children in equatorial Africa and New Guinea), sporadic (children and young adults throughout the world), and immunodeficiency related (primarily in association with HIV infection) [41]. EBV has been detected in virtually all cases of the endemic variant, 15% to 20% of the sporadic variant, and 30% to 40% of the immunodeficiency-related variant [42]. The variable EBV association in the 3 variants has prompted many to contemplate the possibility of the virus being a passenger in the neoplastic process and not the initiating factor. In all variants, irrespective of the EBV status, constitutive activation of the *c-myc* oncogene through its translocation into one of the immunoglobulin loci is clearly the key factor in the oncogenesis of Burkitt lymphoma [41,42]. The detection of somatic hypermutations in the V region of the immunoglobulin genes and the phenotype of the Burkitt lymphoma cells indicate a GC cell origin of the lymphoma [8].

Most EBV-positive cases exhibit a highly restrictive pattern of expression of latent encoded proteins, only expressing EBNA1 and the EBERs (latency I) [42]. However, it has been recently reported that some cases,

in addition to the EBNA1 and the EBERs, express EBNA3A, 3B, 3C, and LP but still lack EBNA2 and the latent membrane proteins [43]. That restrictive latency pattern has prompted an intense ongoing debate about the role of EBV in the pathogenesis of Burkitt lymphoma. EBNA1 plays a crucial role in the maintenance and replication of the viral genome, but its oncogenic potential is highly controversial [42,44]. As the EBERs are believed to possess antiapoptotic activities, as well as the ability to induce the expression of interleukin (IL)-10, which may promote cell growth and survival, it has been postulated that they may play an essential role in the oncogenesis of Burkitt lymphoma [45,46]. This postulation, although endorsed by many investigators, is still debatable; and to date, the role of EBV in the pathogenesis of Burkitt lymphoma remains hypothetical.

Another controversial issue is the possibility of Burkitt lymphoma being a tumor of latently infected memory B cells rather than being of a GC cell origin. This theory is based upon the highly restricted pattern of the EBV-latent proteins, similar to that seen in memory B cells in healthy carriers [13]. However, this theory is heavily negated by the phenotype of the Burkitt lymphoma cells, which is more consistent with a GC origin. Moreover, analysis of the chromosome breakpoints in the MYC translocation indicates that these translocations have occurred because of either somatic mutation or class switch recombination, which are both unique processes for the GC [47].

**PTLD** is a clinicopathological entity encompassing a heterogeneous group of disorders that follow solid organ transplant or bone marrow allograft as a consequence of immunosuppression and range from reactive hyperplasia to malignant monoclonal forms [48,49]. According to the WHO classification, they are divided into early lesions (reactive plasmacytic hyperplasia and mononucleosis-like syndrome), polymorphic lesions, monomorphic lesions, and Hodgkin-like lesions [48]. A GC or a post-GC origin has been recognized for PTLT because of the detection of somatic mutations in a considerable percentage of cases [13].

The risk of developing PTLT varies considerably, which is mainly dependent on several factors such as the transplant type, the age of the patient, the immunosuppressant regimen, and the EBV status. EBV has been linked to most PTLTs, with a near 100% association in the early-occurring cases (within a year) and in PTLT-associated Hodgkin lymphoma [50]. The EBV-negative PTLTs constitute approximately 20% of all cases, have a tendency to late occurrence (>5 years post transplant), and have an unknown etiology [48]. Type III latency is exhibited by the EBV-positive B cells in PTLT, although some studies have reported a more restricted latency pattern [51]. The wide expression of the latent EBV-encoded proteins strongly suggests an important role that EBV may play in the oncogenic process. This is also supported by several other factors including the near 100% EBV association with PTLT cases (especially early-occur-

ring cases), the numerous EBV-positive cells detected by in situ hybridization, and the high EBV viral load measured by PCR in the peripheral blood that declines after decreasing the immunosuppression dosage [48].

The mechanism by which EBV is thought to contribute to the pathogenesis of PTLT is similar to its presumed role in Hodgkin lymphoma. Because approximately 50% of PTLT cases are derived from GC B cells lacking a functional BCR because of certain crippling mutations, and because these cells manage to escape apoptosis despite lacking antigen affinity, it is believed that EBV aids in rescuing these cells from an imminent programmed cell death [52,53]. As in Hodgkin cases, LMP1 and LMP2A may replace survival signals induced by activated BCR and CD40 receptors and also activate the NF- $\kappa$ B signaling pathway, inducing proliferation of neoplastic cells.

The decreased cytotoxic T-cell surveillance because of immunosuppression in PTLT patients is also believed to greatly facilitate the actions of EBV. The similar role that EBV is thought to play in inducing the survival and neoplastic transformation of infected GC cells in both PTLT and Hodgkin lymphoma, in addition to the near 100% EBV positivity in PTLT-associated Hodgkin lymphoma, has led some investigators to speculate a connection between the 2 diseases and the possibility that EBV infection and its GC effects may be the initiating role in the pathogenesis of both entities [52].

**Lymphomatoid granulomatosis** is a rare angiocentric and angiodestructive B-cell lymphoproliferative disorder that is composed predominantly of reactive T cells and fewer neoplastic EBV-positive B cells [54]. The most common site of involvement is the lung, with less frequent involvement of other extranodal sites such as the skin, kidney, liver, and central nervous system (CNS) [55]. Since it was first described in 1972 by Liebow et al [56] and for nearly 2 decades, lymphomatoid granulomatosis was thought to be a T-cell lymphoproliferative disorder because of the predominance of CD4-positive helper T cells and the failure to detect any associated B-cell gene rearrangements [57,58].

The failure to detect B-cell gene rearrangements at that time could be explained by the use of less sensitive techniques and also the scarcity of neoplastic B cells within the tumor (similar to Hodgkin cases). The detection of EBV that was confined to B cells led to the hypothesis that lymphomatoid granulomatosis may represent a B-cell disorder [59]. That hypothesis was later confirmed by the ability to detect immunoglobulin heavy chain gene rearrangements in EBV-infected B cells [60,61]. A 3-tier grading system has been proposed for lymphomatoid granulomatosis that relates to the number of EBV-positive B cells within each case (grade I: <5, grade II: 5-20, and grade III >20 cells) [54].

The latency pattern for EBV has not been extensively studied in lymphomatoid granulomatosis; but one group has reported the detection of LMP1 and EBNA2 by immunohistochemistry and the EBERs by in situ hybridization, which is indicative for type III latency [62]. The near 100%

EBV association with lymphomatoid granulomatosis and the presumed wide expression of EBV latent encoded proteins strongly infer that EBV is not just an innocent bystander but may play a crucial role in the pathogenesis of the disease. The presence of lymphomatoid granulomatosis in a considerable amount of immunosuppressed patients and the presumed latency III pattern of expression make us hypothesize that the role of EBV in the pathogenesis of lymphomatoid granulomatosis is similar to that seen in PTLT, where EBV is believed to play a role in the transformation of infected B cells in the absence of adequate T-cell surveillance [63].

**Pyothorax-associated lymphoma** is an entity that was first described in Japanese patients by Iuchi et al in 1987 [64] and was later incorporated into the WHO classification of lung and pleural tumors in 2004 [65]. Pyothorax-associated lymphoma is considered to be a subcategory of diffuse large B-cell lymphoma that typically exhibits immunoblastic morphology, tends to present as a pleural mass, and results from long-standing pyothorax from pulmonary tuberculosis [65,66]. Its reported association with EBV has ranged from 70% to 100% of the cases [65]. Type III latency has been proposed because the EBV latent encoded proteins LMP1, EBNA1, EBNA2, and EBERs are expressed [66]. The exact role of EBV in the oncogenesis of pyothorax-associated lymphoma has yet to be determined, although some studies have suggested that the production of IL-6 and IL-10 by EBV, in addition to the ability of EBNA1- and LMP1-expressing B cells to escape immunosurveillance in immunocompromised patients, may provide some clues for a potential role for EBV [66-68].

**Senile EBV-associated B-cell lymphoproliferative disorders** constitute a provisional entity, recently described by Oyama et al, in which elderly (>60 years old) immunocompetent patients develop EBV-associated B-cell lymphomas with a predilection for involvement of extranodal sites [69]. The entity was further subdivided into a polymorphic category (broad range of B-cell differentiation in an inflammatory background) and a large cell category (monomorphic large cells) [69]. EBV was detected in all cases; and a latency III program was most often expressed, although some cases lacked EBNA2 expression (latency II) [69,70]. The variable presence of EBNA2 expression may be attributed to the variable degrees of immune surveillance in aging individuals.

## 1.2. EBV and T/NK-cell lymphoproliferative disorders

Most EBV-related lymphoid malignancies are of a B-cell origin [42]. However, since the EBV association with T-cell proliferation was first described [71], many other T-cell lymphoproliferative entities have been linked to EBV, especially in Asia and Latin America. EBV can infect CD4+ and CD8+ peripheral blood T cells as well as NK cells

in a minority of patients with infectious mononucleosis [72]. However, most EBV-associated T-cell lymphomas exhibit a cytotoxic phenotype (granzyme B and TIA-1 positive), which suggests that these tumors may have resulted somehow from the proliferating cytotoxic T cells trying to kill the EBV-infected cells [73]. Because T cells are refractory to EBV infection in vitro (in contrast to B cells), the exact mechanism of how EBV accesses or infects the T cells is largely unknown [42].

Most EBV-associated T-cell lymphomas arise after chronic active EBV infection; and usually, EBV detection indicates an aggressive process or confers a worse prognosis [42]. Patients usually exhibit prolonged fever, hepatosplenomegaly, multiple sites of lymphadenopathy, weight loss, and multiorgan failure, with a median survival of only a few months despite intensive chemotherapy [72]. The immune status of patients usually does not affect longevity, where d'Amore et al have reported a poor prognosis in immunocompetent patients with EBV-associated T-cell lymphomas based on studying a register-based population [74]. In most T-cell lymphoproliferative disorders, a type II latency is recognized in which the expressed EBV latent encoded proteins are LMP1, 2A, and 2B; EBNA1; and EBERs [42,75].

The exact role of EBV in the oncogenesis of T-cell lymphomas is still hypothetical, although Yang et al have reported that increased IL-9 levels induced by the EBERs possess antiapoptotic effects and promote T-cell proliferation and transformation [75]. Another theory regarding EBV and T-cell oncogenesis is similar to Hodgkin lymphoma pathogenesis, in which it has been documented that LMP1 may mimic or act as a viral analogue for members of the family of tumor necrosis factor (TNF) receptors, thereby transmitting growth signals through cytoplasmic TNF receptor-associated factors [76]. Members of the TNF family include CD40, which was previously discussed in the section on Hodgkin lymphoma. Because TNF- $\alpha$  levels, which may be the cause of fever and weight loss in T-cell lymphomas, are believed to reliably correlate with disease activity and with EBV infection, a few authors have suggested that monitoring TNF- $\alpha$  levels would be a useful prognostic marker in EBV-associated peripheral T-cell lymphoma and that agents against TNF- $\alpha$  may be a therapeutic option [77].

T-cell lymphoproliferative disorders that have been reported to be EBV associated include a subset of peripheral T-cell lymphomas [78,79], AILT [80,81], extranodal nasal type NK/T-cell lymphoma [82], enteropathy-type T-cell lymphoma [83,84],  $\gamma\delta$  T-cell lymphomas (hepatosplenic and nonhepatosplenic) [85,86], T-cell lymphoproliferative disorders after chronic EBV infection [87], EBV-associated cutaneous T-cell lymphoproliferative disorders (especially in Asia) [88], and aggressive NK-cell leukemia/lymphoma [89].

**AILT** is a systemic lymphoproliferative disorder that mainly affects older individuals and is characterized by a



polymorphous lymphoid infiltrate; florid vascular proliferation; FDRC proliferation; regressed or, more uncommonly, hyperplastic GCs; and constitutional symptoms (generalized lymphadenopathy, fever, skin rash, hepatosplenomegaly, and polyclonal hypergammaglobulinemia). Clonal rearrangements of the T-cell receptor genes have been detected in most cases [90]. EBV was first detected in AILT cases using Southern blot [80] and subsequently by PCR [81,91] in a variable number of B cells, which raised the question of a potential role for EBV in the pathogenesis of the disease, although T cells are generally not EBV infected. EBV-driven B-cell lymphomas can also superimpose or complicate the course of AILT on a few occasions in which the AILT-associated immunodeficiency followed by the immunosuppressive effects of chemotherapy may have created an ideal environment for a variable number of EBV-infected B cells to proliferate and transform [92].

The EBV-positive B cells have been determined to have ongoing somatic hypermutation, a hallmark of GC cells; however, these mutations are nonfunctional [93]. These crippling mutations are almost restricted to the EBV-infected cells and not detected in EBV-negative cells, which assumes a potential influence of EBV on these proliferating cells [93]. Although crippling mutations are also seen in classic Hodgkin lymphoma, HRS cells lack the intracлонаl diversity because of the shutdown of the ongoing somatic mutations, in contrast to the EBV-infected B cells in AILT that continue to undergo somatic mutations even with the presence of crippling mutations [94]. The reasons for the sustained somatic hypermutation status are largely unknown, although it has been speculated by some that the rich FDRC meshwork and the increased number of CD4-positive helper T cells in AILT cases may stimulate the proliferating B cells to undergo somatic mutations and probably escape apoptosis [8].

The latency pattern for EBV is not known as well, although some have assumed a restricted latency II program similar to that seen in other EBV-associated T-cell lymphoproliferative disorders [93]. This postulation can also be supported by the fact that most of the subsequent EBV-associated B-cell proliferations that follow AILT in few occasions express LMP1 and the EBERs, which is consistent with type II latency [92].

**Extranodal nasal NK/T-cell lymphoma**, previously known as *polymorphic reticulosis*, is an angiocentric and angiodestructive tumor associated with prominent necrosis, which predominantly involves the nasal cavity and has a geographical predilection for Asia and Central America [95]. The EBV association has evolved since the viral genomes were detected in Asian patients by Southern blot and in situ hybridization techniques [96-98]. A latency II program has been reported, which includes the expression of the latent EBV proteins LMP1, EBNA1, and EBER [99]. As in all EBV-associated T-cell lymphoproliferative disorders, the exact mechanism by which EBV gains access and infects T cells has yet to be determined.

Similar to normal NK cells and in contrast to infected B cells, EBV-infected NK cells have been found to require IL-2 for growth and proliferation even with the expression of LMP1 and other type II latency proteins [100,101]. Moreover, the reduction in LMP1 levels in treated cell lines does not lead to growth inhibition or apoptosis within the cells [102]. This, in theory, argues against EBV involvement in the process of transformation and proliferation of the neoplastic T cells [100,101]. One study has suggested, however, that LMP1 may increase the sensitivity of the infected cell to the growth-promoting effects of IL-2 [101].

**Hepatosplenic T-cell lymphoma** is a rare aggressive subtype of peripheral T-cell lymphoma derived from cytotoxic T cells, usually of the  $\gamma\delta$  T-cell receptor type, and is characterized by hepatosplenomegaly and cytopenias [85,103]. Because  $\gamma\delta$  T cells have preferential homing to the sinusoidal areas, marked sinusoidal infiltration is noted in both the liver and spleen [104]. EBV has been reported to be not associated with hepatosplenic T-cell lymphoma in most studies [103,105,106]; however, few studies have reported the detection of EBV genome by Southern blot and in situ hybridization in patients with the disease [85,107]. A hypothesized possible role for EBV in the pathogenesis of the disease can be debated because of the inconsistent EBV detection, although one may argue that it may play a role via chronic antigen exposure [85].

**Nonhepatosplenic  $\gamma\delta$  T-cell lymphomas**, like the hepatosplenic entity, are rare disorders with a predilection for sinusoidal infiltration. They can occur in the skin, intestine, nose, lymph nodes, and other extremely rare sites such as the lung and thyroid [86,107]. In contrast to the hepatosplenic form, the nonhepatosplenic forms have been more consistently reported to be associated with EBV [86,108]. The EBERs have been detected by in situ hybridization on a consistent basis; and LMP1 (but not EBNA2) has been detected by immunohistochemistry in a few studies, which indicates a restricted pattern of latent EBV expression (type II latency) [86,108].

**Enteropathy-type T-cell lymphoma** is an aggressive tumor of intraepithelial T lymphocytes that is common in areas with a high prevalence of celiac disease [109]. The association with EBV is not clear, although a few studies have reported detection of EBV by PCR and in situ hybridization, and rare LMP1 expression by immunohistochemistry [83]. One study has compared EBV association based on geographical and ethnic guidelines, where EBV was detected consistently by PCR and in situ hybridization in patients from Mexico and Central America, whereas rare EBV expression was noted in patients from Western Europe [84].

### 1.3. EBV And HIV-related lymphoproliferative disorders

The incidence of lymphoproliferative disorders is greatly increased in HIV-positive individuals, with lymphoma ranking second (after Kaposi sarcoma) as the most frequent



malignancy encountered in patients with AIDS [12]. Since the introduction of the highly active antiretroviral therapy, the incidence of lymphoma in AIDS patients has decreased significantly [110]. Most HIV-associated lymphoproliferative disorders are highly aggressive and of a B-cell origin [111,112]. Hodgkin lymphoma is reported to have an 8-fold increased incidence in HIV-positive individuals [113].

HIV-related lymphomas are a heterogeneous group of diseases that include (1) lymphomas that can occur in immunocompetent individuals (HIV negative) such as Burkitt lymphoma and diffuse large B-cell lymphoma (often involving the CNS) and (2) lymphomas that occur almost exclusively in the setting of HIV infection such as primary effusion lymphoma and plasmablastic lymphoma of the oral cavity [114]. Several factors are thought to play a role in the pathogenesis of these lymphomas, including genetic abnormalities, chronic antigen stimulation, cytokine deregulation, and possible roles for human herpesvirus 8 (HHV-8) and EBV [115]. EBV has been reported to be detected in up to 60% of all HIV-related lymphomas, including nearly 100% of primary CNS lymphomas, 80% of diffuse large B-cell lymphoma with immunoblastic features, 30% to 50% of Burkitt lymphomas, 60% of plasmablastic lymphomas, 70% of primary effusion lymphoma, and nearly 100% of Hodgkin lymphomas arising in the setting of HIV [115-117].

Because of the heterogeneity of the HIV-related disorders, different patterns of latent EBV gene expression have been described. In the first subgroup of disorders that can occur in immunocompetent individuals, the pattern of EBV expression coincides, more or less, with the histologic subtype of lymphoma irrespective of the HIV status. In the second group of disorders (HIV near-specific lymphomas), the EBV expression is described below. As in most EBV-associated lymphoproliferative disorders, the role of EBV in the pathogenesis of the HIV-related lymphoproliferative disorders is speculative at the current time. In diffuse large B-cell lymphoma with immunoblastic features, some researchers strongly believe that the high EBV association with these tumors (80%) and the consistent expression of LMP1 indicate an EBV-driven proliferation [118,119].

**Primary CNS lymphomas** constitute approximately 20% to 25% of all HIV-related lymphomas and have a thousandfold increased incidence in AIDS patients, although the incidence has decreased significantly since the introduction of highly active antiretroviral therapy [111,115,120]. These tumors have a tendency to occur late in the course of HIV infection and show EBV association in virtually 100% of the cases [121]. A few studies have reported that detection of EBV in the cerebrospinal fluid of HIV-positive patients with a CNS lesion infers a diagnosis of lymphoma [122,123]. These lymphomas have been reported to express all EBV latent encoded proteins (latency III), although the role of EBV in the pathogenesis of these disorders remains unknown [121].

**Primary effusion lymphoma** is a rare and distinct tumor that affects body cavities without a detectable tumor mass [124]. The neoplastic cells have an indeterminate phenotype, where they are CD45 and CD138 positive but negative for pan B-cell markers; however, at the molecular level, unequivocal immunoglobulin gene rearrangements and somatic hypermutations indicate a post-GC B-cell origin [125,126]. Primary effusion lymphoma is predominantly associated with HHV-8 and has been reported to have a variable association with EBV [126]. The consistent detection of both viruses in up to 70% of the cases suggests a possible role for the 2 viruses in the tumorigenesis of the disease [116]. The expression of EBV latent encoded proteins is restricted to EBNA1, LMP1, LMP2A, and EBERs, which is consistent with type II latency [127]. Again, the exact role of EBV has been debated; but the fact that both viruses are detected together in most of the cases suggests that EBV may act as a cofactor in the initiating events (because it can immortalize and transform B cells in vitro and HHV-8 cannot), whereas HHV-8 may be the driving force for the tumor [126].

**Plasmablastic lymphoma** is a rare, aggressive entity mostly reported in the oral cavity in HIV-positive patients that has been recently recognized as a subtype of diffuse large B-cell lymphoma [128,129]. Occurrence outside the oral cavity and in HIV-negative patients has been rarely reported [130]. EBV has been detected in these patients in about 60% of the cases regardless of the HIV status [117,128]. In contrast to other B-cell lymphoproliferative disorders, EBV expression is restricted to the EBERs, which correlates with previous work showing a marked reduction in the expression of EBV latent proteins with terminal B-cell differentiation into plasma cells [131,132]. A potential role for EBV in the pathogenesis of the disease remains unknown, especially with the highly restricted latency expression pattern.

In summary, EBV infects most of the world's adult population, resulting in acute symptoms in a minority of patients; but it is the persistence of EBV in the human body as a latent infection that has been the subject of numerous studies because of its association with neoplastic transformation. Lymphoproliferative disorders constitute most of the EBV-associated neoplasms, in which the mechanism of the induced transformation is better understood in some disorders than in others. Further studies to provide better understanding of the pathophysiology of EBV-induced or EBV-associated transformation may lead to the development of novel therapies for the virus-associated disorder.

## References

- [1] Epstein MA, Achong BG, Barr YM. Virus particles in cultured lymphoblasts from Burkitt's lymphoma. *Lancet* 1964;1:702-3.
- [2] Henle G, Henle W, Diehl V. Relation of Burkitt's tumor-associated herpes-type virus to infectious mononucleosis. *Proc Natl Acad Sci U S A* 1968;59:94-101.

- [3] Rickinson A. Epstein-Barr virus. *Virus Res* 2002;82:109-13 [Review].
- [4] Rickinson A, Kieff E. In: Knipe DM, Howley PM, editors. *Fields virology*. Philadelphia: Lippincott-Raven; 2001. p. 2575-627.
- [5] Williams H, Crawford DH. Epstein-Barr virus: the impact of scientific advances on clinical practice. *Blood* 2006;107:862-9.
- [6] Sixbey JW, Nedrud JG, Raab-Traub N, Hanes RA, Pagano JS. Epstein-Barr virus replication in oropharyngeal epithelial cells. *N Engl J Med* 1984;310:1225-30.
- [7] Gandhi MK, Tellam JT, Khanna R. Epstein-Barr virus-associated Hodgkin's lymphoma. *Br J Haematol* 2004;125:267-81 [Review].
- [8] Kuppers R. B cells under influence: transformation of B cells by Epstein-Barr virus. *Nat Rev Immunol* 2003;3:801-12 [Review].
- [9] Ambinder R, Jarrett R, Weiss LM. Association of Epstein-Barr virus with Hodgkin's disease. In: Mauch P, Armitage J, Diehl V, Hoppe R, Weiss LM, editors. *Hodgkin lymphoma*. Lippincott Williams & Wilkins (2nd ed). [in press].
- [10] Thorley-Lawson DA. Epstein-Barr virus: exploiting the immune system. *Nat Rev Immunol* 2001;1:75-82 [Review].
- [11] Chen A, Zhao B, Kieff E, Aster JC, Wang F. EBNA-3B- and EBNA-3C-regulated cellular genes in Epstein-Barr virus-immortalized lymphoblastoid cell lines. *J Virol* 2006;80:10139-50.
- [12] Murray PG, Young LS. Hodgkin's lymphoma: molecular pathogenesis and the contribution of the Epstein-Barr virus. In: Robertson ES, editor. *Epstein-Barr virus*. Norfolk: Caister Academic Press; 2005.
- [13] Hochberg D, Middeldorp JM, Catalina M, Sullivan JL, Luzuriaga K, Thorley-Lawson DA. Demonstration of the Burkitt's lymphoma Epstein-Barr virus phenotype in dividing latently infected memory cells in vivo. *Proc Natl Acad Sci U S A* 2004;101:239-44 [Electronic publication 2003 Dec 19].
- [14] Iezzoni JC, Gaffey MJ, Weiss LM. The role of Epstein-Barr virus in lymphoepithelioma-like carcinomas. *Am J Clin Pathol* 1995;103:308-15.
- [15] Shibata D, Tokunaga M, Uemura Y, Sato E, Tanaka S, Weiss LM. Association of Epstein-Barr virus with undifferentiated gastric carcinomas with intense lymphoid infiltration. Lymphoepithelioma-like carcinoma. *Am J Pathol* 1991;139:469-74.
- [16] Arber DA, Kamel OW, van de Rijn M, et al. Frequent presence of the Epstein-Barr virus in inflammatory pseudotumor. *HUM PATHOL* 1995;26:1093-8.
- [17] Lee ES, Locker J, Nalesnik M, et al. The association of Epstein-Barr virus with smooth-muscle tumors occurring after organ transplantation. *N Engl J Med* 1995;332:19-25.
- [18] Hodgkin T. On some morbid appearances of the absorbent glands and spleen. *Med Chirurg Trans* 1832;17:69-97.
- [19] Stein H. Hodgkin lymphomas: introduction. In: Jaffe ES, Harris NL, Stein HJ, Vardiman W, editors. *World Health Organization classification of tumors. Pathology and genetics of tumors of hematopoietic and lymphoid tissues*. Lyon: IARC Press; 2001.
- [20] Kuppers R. Molecular biology of Hodgkin's lymphoma. *Adv Cancer Res* 2002;84:277-312 [Review].
- [21] Kanzler H, Kuppers R, Hansmann ML, Rajewsky K. Hodgkin and Reed-Sternberg cells in Hodgkin's disease represent the outgrowth of a dominant tumor clone derived from (crippled) germinal center B cells. *J Exp Med* 1996;184:1495-505.
- [22] Kuppers R, Schweging I, Brauning A, Rajewsky K, Hansmann ML. Biology of Hodgkin's lymphoma. *Ann Oncol* 2002;13(Suppl 1):11-8 [Review].
- [23] Levine P, Ablashi D, Berard C, Carbone P, Waggoner DE, Malan L. Elevated antibody titers to Epstein-Barr virus in Hodgkin's disease. *Cancer* 1971;27:416-21.
- [24] Weiss LM, Strickler JG, Warnke RA, Purtilo DT, Sklar J. Epstein-Barr viral DNA in tissues of Hodgkin's disease. *Am J Pathol* 1987;129:86-91.
- [25] Weiss LM, Movahed LA, Warnke RA, Sklar J. Detection of Epstein-Barr viral genomes in Reed-Sternberg cells of Hodgkin's disease. *N Engl J Med* 1989;320:502-6.
- [26] Roth J, Daus H, Gause A, Trumper L, Pfreundschuh M. Detection of Epstein-Barr virus DNA in Hodgkin- and Reed-Sternberg cells by single cell PCR. *Leuk Lymphoma* 1994;13:137-42.
- [27] Khalidi HS, Lones MA, Zhou Y, Weiss LM, Medeiros LJ. Detection of Epstein-Barr virus in the L & H cells of nodular lymphocyte predominance Hodgkin's disease: report of a case documented by immunohistochemical, in situ hybridization, and polymerase chain reaction methods. *Am J Clin Pathol* 1997;108:687-92.
- [28] Jarrett RF, Gallagher A, Jones DB, et al. Detection of Epstein-Barr virus genomes in Hodgkin's disease: relation to age. *J Clin Pathol* 1991;44:844-8.
- [29] Uccini S, Monardo F, Stoppacciaro A, et al. High frequency of Epstein-Barr virus genome detection in Hodgkin's disease of HIV-positive patients. *Int J Cancer* 1990;46:581-5.
- [30] Flavell KJ, Murray PG. Hodgkin's disease and the Epstein-Barr virus. *Mol Pathol* 2000;53:262-9 [Review].
- [31] Shaffer AL, Rosenwald A, Staudt LM. Lymphoid malignancies: the dark side of B-cell differentiation. *Nat Rev Immunol* 2002;2:920-32 [Review].
- [32] Schweging I, Brauning A, Klein U, et al. Loss of the B-lineage-specific gene expression program in Hodgkin and Reed-Sternberg cells of Hodgkin lymphoma. *Blood* 2003;101:1505-12 [Epub 2002 Sep 26].
- [33] Kilger E, Kieser A, Baumann M, Hammerschmidt W. Epstein-Barr virus-mediated B-cell proliferation is dependent upon latent membrane protein 1, which simulates an activated CD40 receptor. *EMBO J* 1998;17:1700-9.
- [34] Caldwell RG, Wilson JB, Anderson SJ, Longnecker R. Epstein-Barr virus LMP2A drives B cell development and survival in the absence of normal B cell receptor signals. *Immunity* 1998;9:405-11.
- [35] Henderson S, Rowe M, Gregory C, et al. Induction of bcl-2 expression by Epstein-Barr virus latent membrane protein 1 protects infected B cells from programmed cell death. *Cell* 1991;65:1107-15.
- [36] Krappmann D, Emmerich F, Kordes U, Scharschmidt E, Dorken B, Scheidereit C. Molecular mechanisms of constitutive NF-kappaB/Rel activation in Hodgkin/Reed-Sternberg cells. *Oncogene* 1999;18:943-53.
- [37] Jungnickel B, Staratschek-Jox A, Brauning A, et al. Clonal deleterious mutations in the IkappaBalpha gene in the malignant cells in Hodgkin's lymphoma. *J Exp Med* 2000;191:395-402.
- [38] Kim SH, Choi EY, Shin YK, et al. Generation of cells with Hodgkin's and Reed-Sternberg phenotype through downregulation of CD99 (Mic2). *Blood* 1998;92:4287-95.
- [39] Kim SH, Shin YK, Lee IS, et al. Viral latent membrane protein 1 (LMP-1)-induced CD99 down-regulation in B cells leads to the generation of cells with Hodgkin's and Reed-Sternberg phenotype. *Blood* 2000;95:294-300.
- [40] Burkitt D. A sarcoma involving the jaws in African children. *Br J Surg* 1958;46:218-23.
- [41] Griffin BE, Rochford R. Endemic Burkitt's lymphoma. In: Robertson ES, editor. *Epstein-Barr virus*. Norfolk: Caister Academic Press; 2005. p. 113-39.
- [42] Young LS, Rickinson AB. Epstein-Barr virus: 40 years on. *Nat Rev Cancer* 2004;4:757-68 [Review].
- [43] Kelly GL, Milner AE, Baldwin GS, Bell AI, Rickinson AB. Three restricted forms of Epstein-Barr virus latency counteracting apoptosis in c-myc-expressing Burkitt lymphoma cells. *Proc Natl Acad Sci U S A* 2006;103:14935-40 [Electronic publication 2006 Sep 25].
- [44] Wilson JB, Bell JL, Levine AJ. Expression of Epstein-Barr virus nuclear antigen-1 induces B cell neoplasia in transgenic mice. *EMBO J* 1996;15:3117-26.
- [45] Niller HH, Salamon D, Ilg K, et al. EBV-associated neoplasms: alternative pathogenetic pathways. *Med Hypotheses* 2004;62:387-91 [Review].
- [46] Kitagawa N, Goto M, Kurozumi K, et al. Epstein-Barr virus-encoded poly(A)- RNA supports Burkitt's lymphoma growth through interleukin-10 induction. *EMBO J* 2000;19:6742-50.

- [47] Kuppers R, Dalla-Favera R. Mechanisms of chromosomal translocations in B cell lymphomas. *Oncogene* 2001;20:5580-94 [Review].
- [48] Harris NL, Swerdlow SH, Frizzera G, Knowles DM. Post transplant lymphoproliferative disorders. In: Jaffe ES, Harris NL, Stein H, Vardiman JW, editors. World Health Organization classification of tumors. Pathology and genetics of tumors of hematopoietic and lymphoid tissues. Lyon: IARC Press; 2001. p. 264-70.
- [49] Gottschalk S, Rooney CM, Heslop HE. Post-transplant lymphoproliferative disorders. *Annu Rev Med* 2005;56:29-44 [Review].
- [50] Thompson MP, Kurzrock R. Epstein-Barr virus and cancer. *Clin Cancer Res* 2004;10:803-21 [Review].
- [51] Brink AA, Dukers DF, van den Brule AJ, et al. Presence of Epstein-Barr virus latency type III at the single cell level in post-transplantation lymphoproliferative disorders and AIDS related lymphomas. *J Clin Pathol* 1997;50:911-8.
- [52] Timms JM, Bell A, Flavell JR, et al. Target cells of Epstein-Barr-virus (EBV)-positive post-transplant lymphoproliferative disease: similarities to EBV-positive Hodgkin's lymphoma. *Lancet* 2003;361:217-23.
- [53] Capello D, Rossi D, Gaidano G. Post-transplant lymphoproliferative disorders: molecular basis of disease histogenesis and pathogenesis. *Hematol Oncol* 2005;23:61-7 [Review].
- [54] Jaffe ES, Wilson WH. Lymphomatoid granulomatosis. In: Jaffe ES, Harris NL, Stein H, Vardiman JW, editors. World Health Organization classification of tumors. Pathology and genetics of tumors of hematopoietic and lymphoid tissues. Lyon: IARC Press; 2001. p. 185-9.
- [55] Katzenstein AL, Carrington CB, Liebow AA. Lymphomatoid granulomatosis: a clinicopathologic study of 152 cases. *Cancer* 1979;43:360-73.
- [56] Liebow AA, Carrington CR, Friedman PJ. Lymphomatoid granulomatosis. *HUM PATHOL* 1972;3:457-558.
- [57] Lipford Jr EH, Margolick JB, Longo DL, Fauci AS, Jaffe ES. Angiocentric immunoproliferative lesions: a clinicopathologic spectrum of post-thymic T-cell proliferations. *Blood* 1988;72:1674-81.
- [58] Medeiros LJ, Peiper SC, Elwood L, Yano T, Raffeld M, Jaffe ES. Angiocentric immunoproliferative lesions: a molecular analysis of eight cases. *Hum Pathol* 1991;22:1150-7.
- [59] Medeiros LJ, Jaffe ES, Chen YY, Weiss LM. Localization of Epstein-Barr viral genomes in angiocentric immunoproliferative lesions. *Am J Surg Pathol* 1992;16:439-47.
- [60] Guinee Jr D, Jaffe E, Kingma D, et al. Pulmonary lymphomatoid granulomatosis. Evidence for a proliferation of Epstein-Barr virus infected B-lymphocytes with a prominent T-cell component and vasculitis. *Am J Surg Pathol* 1994;18:753-64.
- [61] Myers JL, Kurtin PJ, Katzenstein AL, et al. Lymphomatoid granulomatosis. Evidence of immunophenotypic diversity and relationship to Epstein-Barr virus infection. *Am J Surg Pathol* 1995;19:1300-12.
- [62] Taniere P, Thivolet-Bejui F, Vitrey D, et al. Lymphomatoid granulomatosis—a report on four cases: evidence for B phenotype of the tumoral cells. *Eur J Respir* 1998;12:102-6.
- [63] Wilson WH, Kingma DW, Raffeld M, Wittes RE, Jaffe ES. Association of lymphomatoid granulomatosis with Epstein-Barr viral infection of B lymphocytes and response to interferon-alpha 2b. *Blood* 1996;87:4531-7.
- [64] Iuchi K, Ichimiya A, Akashi A, et al. Non-Hodgkin's lymphoma of the pleural cavity developing from long-standing pyothorax. *Cancer* 1987;60:1771-5.
- [65] Travis WD, Brambilla E, Muller-Hermelink HK, Harris CC, editors. WHO classification of tumors. Pathology and genetics of tumors of the lung, pleura, thymus, and heart. Lyon: IARC press; 2004.
- [66] Aozasa K. Pyothorax-associated lymphoma. *J Clin Exp Hematop* 2006;46:5-10 [Review].
- [67] Kanno H, Naka N, Yasunaga Y, Aozasa K. Role of an immunosuppressive cytokine, interleukin-10, in the development of pyothorax-associated lymphoma. *Leukemia* 1997;11(Suppl 3):525-6.
- [68] Kanno H, Yasunaga Y, Iuchi K, et al. Interleukin-6-mediated growth enhancement of cell lines derived from pyothorax-associated lymphoma. *Lab Invest* 1996;75:167-73.
- [69] Oyama T, Ichimura K, Suzuki R, et al. Senile EBV+ B-cell lymphoproliferative disorders: a clinicopathologic study of 22 patients. *Am J Surg Pathol* 2003;27:16-26.
- [70] Shimoyama Y, Oyama T, Asano N, et al. Senile Epstein-Barr virus-associated B-cell lymphoproliferative disorders: a mini review. *J Clin Exp Hematop* 2006;46:1-4 [Review].
- [71] Jones JF, Shurin S, Abramowsky C, et al. T-cell lymphomas containing Epstein-Barr viral DNA in patients with chronic Epstein-Barr virus infections. *N Engl J Med* 1988;318:733-41.
- [72] Mitarnun W, Suwiwat S, Pradutkanchana J, et al. Epstein-Barr virus-associated peripheral T-cell and NK-cell proliferative disease/lymphoma: clinicopathologic, serologic, and molecular analysis. *Am J Hematol* 2002;70:31-8.
- [73] Young LS, Murray PG. Epstein-Barr virus and oncogenesis: from latent genes to tumors. *Oncogene* 2003;22:5108-21.
- [74] d'Amore F, Johansen P, Houmand A, Weisenburger DD, Mortensen LS. Epstein-Barr virus genome in non-Hodgkin's lymphomas occurring in immunocompetent patients: highest prevalence in nonlymphoblastic T-cell lymphoma and correlation with a poor prognosis. Danish Lymphoma Study Group, LYFO. *Blood* 1996;87:1045-55.
- [75] Yang L, Aozasa K, Oshimi K, Takada K. Epstein-Barr virus (EBV)-encoded RNA promotes growth of EBV-infected T cells through interleukin-9 induction. *Cancer Res* 2004;64:5332-7.
- [76] Liebowitz D. Epstein-Barr virus and a cellular signaling pathway in lymphomas from immunosuppressed patients. *N Engl J Med* 1998;338:1413-21.
- [77] Mori A, Takao S, Pradutkanchana J, Kietthubthaw S, Mitarnun W, Ishida T. High tumor necrosis factor-alpha levels in the patients with Epstein-Barr virus-associated peripheral T-cell proliferative disease/lymphoma. *Leuk Res* 2003;27:493-8.
- [78] Tan BT, Warnke RA, Arber DA. The frequency of B- and T-cell gene rearrangements and Epstein Barr virus in T-cell lymphomas: a comparison between angioimmunoblastic T-cell lymphoma and peripheral T-cell lymphoma, unspecified with and without associated B-cell proliferations. *J Mol Diagn* 2006;8:466-75.
- [79] Dupuis J, Emile JF, Mounier N, et al. Prognostic significance of Epstein-Barr virus in nodal peripheral T-cell lymphoma, unspecified: a Groupe d'Etude des Lymphomes de l'Adulte (GELA) study. *Blood* 2006;108:4163-9 [Electronic publication 2006 Aug 10].
- [80] Staal SP, Ambinder R, Beschoner WE, Hayward GS, Mann R. A survey of Epstein-Barr virus DNA in lymphoid tissue. Frequent detection in Hodgkin's disease. *Am J Clin Pathol* 1989;91:1-5.
- [81] Knecht H, Sahli R, Shaw P, et al. Detection of Epstein-Barr virus DNA by polymerase chain reaction in lymph node biopsies from patients with angioimmunoblastic lymphadenopathy. *Br J Haematol* 1990;75:610-4 [Erratum in: *Br J Haematol* 1990 Nov;76:450].
- [82] Chan AC, Ho JW, Chiang AK, Srivastava G. Phenotypic and cytotoxic characteristics of peripheral T-cell and NK-cell lymphomas in relation to Epstein-Barr virus association. *Histopathology* 1999;34:16-24.
- [83] De Bruin PC, Jiwa NM, Oudejans JJ, Radaszkiewicz T, Meijer CJ. Epstein-Barr virus in primary gastrointestinal T cell lymphomas. Association with gluten-sensitive enteropathy, pathological features, and immunophenotype. *Am J Pathol* 1995;146:861-7.
- [84] Quintanilla-Martinez L, Lome-Maldonado C, Ott G, et al. Primary intestinal non-Hodgkin's lymphoma and Epstein-Barr virus: high frequency of EBV-infection in T-cell lymphomas of Mexican origin. *Leuk Lymphoma* 1998;30:111-21 [Review].
- [85] Ohshima K, Haraoka S, Harada N, et al. Hepatosplenic gamma delta T-cell lymphoma: relation to Epstein-Barr virus and activated cytotoxic molecules. *Histopathology* 2000;36:127-35.
- [86] Arnulf B, Copie-Bergman C, Delfau-Larue MH, et al. Nonhepatosplenic gamma delta T-cell lymphoma: a subset of cytotoxic lymphomas with mucosal or skin localization. *Blood* 1998;91:1723-31.



- [87] Quintanilla-Martinez L, Kumar S, Fend F, et al. Fulminant EBV(+) T-cell lymphoproliferative disorder following acute/chronic EBV infection: a distinct clinicopathologic syndrome. *Blood* 2000;96:443-51.
- [88] Kim YC, Yang WI, Lee MG, et al. Epstein-Barr virus in CD30 anaplastic large cell lymphoma involving the skin and lymphomatoid papulosis in South Korea. *Int J Dermatol* 2006;45:1312-6.
- [89] Chan J, Wong KF, Jaffe ES, Ralfkiaer E. Aggressive NK-cell leukemia. In: Jaffe ES, Harris NL, Stein H, Vardiman JW, editors. World Health Organization classification of tumors. Pathology and genetics of tumors of hematopoietic and lymphoid tissues. Lyon: IARC Press; 2001. p. 198-200.
- [90] Weiss LM, Strickler JG, Dorfman RF, Horning SJ, Warnke RA, Sklar J. Clonal T-cell populations in angioimmunoblastic lymphadenopathy and angioimmunoblastic lymphadenopathy-like lymphoma. *Am J Pathol* 1986;122:392-7.
- [91] Weiss LM, Jaffe ES, Liu XF, Chen YY, Shibata D, Medeiros LJ. Detection and localization of Epstein-Barr viral genomes in angioimmunoblastic lymphadenopathy and angioimmunoblastic lymphadenopathy-like lymphoma. *Blood* 1992;79:1789-95.
- [92] Hawley RC, Cankovic M, Zarbo RJ. Angioimmunoblastic T-cell lymphoma with supervening Epstein-Barr virus-associated large B-cell lymphoma. *Arch Pathol Lab Med* 2006;130:1707-11.
- [93] Brauning A, Spieker T, Willenbrock K, et al. Survival and clonal expansion of mutating "forbidden" (immunoglobulin receptor-deficient) Epstein Barr virus-infected B cells in angioimmunoblastic T cell lymphoma. *J Exp Med* 2001;94:927-40.
- [94] Kuppers R. Somatic hypermutation and B cell receptor selection in normal and transformed human B cells. *Ann N Y Acad Sci* 2003;987:173-9 [Review].
- [95] Chan J, Jaffe ES, Ralfkiaer E. Extranodal NK/T cell lymphoma, nasal type. In: Jaffe ES, Harris NL, Stein H, Vardiman JW, editors. World Health Organization classification of tumors. Pathology and genetics of tumors of hematopoietic and lymphoid tissues. Lyon: IARC Press; 2001. p. 204-8.
- [96] Ho FC, Srivastava G, Loke SL, et al. Presence of Epstein-Barr virus DNA in nasal lymphomas of B and 'T' cell type. *Hematol Oncol* 1990;8:271-81.
- [97] Presence of Epstein-Barr virus DNA in nasal lymphomas of B and 'T' cell type. *Hematol Oncol* 1990;8:271-81.
- [98] Epstein-Barr virus in nasal T-cell lymphomas in patients with lethal midline granuloma. *Lancet* 1990;335:128-30.
- [99] Xu ZG, Iwatsuki K, Oyama N, et al. The latency pattern of Epstein-Barr virus infection and viral IL-10 expression in cutaneous natural killer/T-cell lymphomas. *Br J Cancer* 2001;84:920-5.
- [100] Matsuo Y, Drexler HG. Immunoprofiling of cell lines derived from natural killer-cell and natural killer-like T-cell leukemia-lymphoma. *Leuk Res* 2003;27:935-45.
- [101] Takahara M, Kis LL, Nagy N, et al. Concomitant increase of LMP1 and CD25 (IL-2-receptor alpha) expression induced by IL-10 in the EBV-positive NK lines SNK6 and KAI3. *Int J Cancer* 2006;119:2775-83.
- [102] Noguchi T, Ikeda K, Yamamoto K, et al. Antisense oligodeoxynucleotides to latent membrane protein 1 induce growth inhibition, apoptosis and Bcl-2 suppression in Epstein-Barr virus (EBV)-transformed B-lymphoblastoid cells, but not in EBV-positive natural killer cell lymphoma cells. *Br J Haematol* 2001;114:84-92.
- [103] Jaffe ES, Ralfkiaer E. Hepatosplenic T-cell lymphoma. In: Jaffe ES, Harris NL, Stein H, Vardiman JW, editors. World Health Organization classification of tumors. Pathology and genetics of tumors of hematopoietic and lymphoid tissues. Lyon: IARC Press; 2001. p. 210-2.
- [104] Falini B, Flenghi L, Pileri S, et al. Distribution of T cells bearing different forms of the T cell receptor gamma/delta in normal and pathological human tissues. *J Immunol* 1989;143:2480-8.
- [105] Jaffe ES, Krenacs L, Raffeld M. Classification of T-cell and NK-cell neoplasms based on the REAL classification. *Ann Oncol* 1997;8(Suppl 2):17-24 [Review].
- [106] Belhadji K, Reyes F, Farcet JP, et al. Hepatosplenic gammadelta T-cell lymphoma is a rare clinicopathologic entity with poor outcome: report on a series of 21 patients. *Blood* 2003;102:4261-9 [Electronic publication 2003 Aug 7. Review].
- [107] Taguchi A, Miyazaki M, Sakuragi S, Shinohara K, Kamei T, Inoue Y. Gamma/delta T cell lymphoma. *Intern Med* 2004;43:120-5 [Review].
- [108] Kagami Y, Nakamura S, Suzuki R, et al. A nodal gamma/delta T-cell lymphoma with an association of Epstein-Barr virus. *Am J Surg Pathol* 1997;21:729-36.
- [109] Isaacson P, Wright D, Ralfkiaer E, Jaffe ES. Enteropathy type T-cell lymphoma. In: Jaffe ES, Harris NL, Stein H, Vardiman JW, editors. World Health Organization classification of tumors. Pathology and genetics of tumors of hematopoietic and lymphoid tissues. Lyon: IARC Press; 2001.
- [110] Matthews GV, Bower M, Mandala S, Powles T, Nelson MR, Gazzard BG. Changes in acquired immunodeficiency syndrome-related lymphoma since the introduction of highly active antiretroviral therapy. *Blood* 2000;96:2730-4.
- [111] Krause J. AIDS-related non-Hodgkin's lymphomas. *Microsc Res Tech* 2005;68:168-75 [Review].
- [112] Knowles DM, Chamulak GA, Subar M, et al. Lymphoid neoplasia associated with the acquired immunodeficiency syndrome (AIDS). The New York University Medical Center experience with 105 patients (1981-1986). *Ann Intern Med* 1988;108:744-53.
- [113] Goedert JJ. The epidemiology of acquired immunodeficiency syndrome malignancies. *Semin Oncol* 2000;27:390-401 [Review].
- [114] Carbone A, Gloghini A. AIDS-related lymphomas: from pathogenesis to pathology. *Br J Haematol* 2005;130:662-70 [Review].
- [115] Raphael M, Borisch B, Jaffe ES. Lymphomas associated with infection by the human immunodeficiency virus (HIV). In: Jaffe ES, Harris NL, Stein H, Vardiman JW, editors. World Health Organization classification of tumors. Pathology and genetics of tumors of hematopoietic and lymphoid tissues. Lyon: IARC Press; 2001.
- [116] Trivedi P, Takazawa K, Zompetta C, et al. Infection of HHV-8+ primary effusion lymphoma cells with a recombinant Epstein-Barr virus leads to restricted EBV latency, altered phenotype, and increased tumorigenicity without affecting TCL1 expression. *Blood* 2004;103:313-6 [Epub 2003 Sep 11].
- [117] Lee OJ, Kim KW, Lee GK. Epstein-Barr virus and human immunodeficiency virus-negative oral plasmablastic lymphoma. *J Oral Pathol Med* 2006;35:382-4.
- [118] Hamilton-Dutoit SJ, Rea D, Raphael M, et al. Epstein-Barr virus-latent gene expression and tumor cell phenotype in acquired immunodeficiency syndrome-related non-Hodgkin's lymphoma. Correlation of lymphoma phenotype with three distinct patterns of viral latency. *Am J Pathol* 1993;143:1072-8.
- [119] Carbone A. Emerging pathways in the development of AIDS-related lymphomas. *Lancet Oncol* 2003;4:22-9 [Review].
- [120] Beral V, Peterman T, Berkelman R, Jaffe H. AIDS-associated non-Hodgkin lymphoma. *Lancet* 1991;337:805-9.
- [121] Cohen JI. Clinical aspects of Epstein-Barr virus infection. In: Robertson ES, editor. Epstein-Barr virus. Norfolk: Caister Academic press; 2005. p. 35-55.
- [122] Cinque P, Vago L, Dahl H, et al. Polymerase chain reaction on cerebrospinal fluid for diagnosis of virus-associated opportunistic diseases of the central nervous system in HIV-infected patients. *AIDS* 1996;10:951-8.
- [123] Ivers LC, Kim AY, Sax PE. Predictive value of polymerase chain reaction of cerebrospinal fluid for detection of Epstein-Barr virus to establish the diagnosis of HIV-related primary central nervous system lymphoma. *Clin Infect Dis* 2004;38:1629-32 [Electronic publication 2004 May 5].
- [124] Banks PM, Warnke RA. Primary effusion lymphoma. In: Jaffe ES, Harris NL, Stein H, Vardiman JW, editors. World Health Organization classification of tumors. Pathology and genetics of



- tumors of hematopoietic and lymphoid tissues. Lyon: IARC Press; 2001. p. 179-81.
- [125] Matolesy A, Nador RG, Cesarman E, Knowles DM. Immunoglobulin VH gene mutational analysis suggests that primary effusion lymphomas derive from different stages of B cell maturation. *Am J Pathol* 1998;153:1609-14.
- [126] Fan W, Bubman D, Chadburn A, Harrington Jr WJ, Cesarman E, Knowles DM. Distinct subsets of primary effusion lymphoma can be identified based on their cellular gene expression profile and viral association. *J Virol* 2005;79:1244-51.
- [127] Szekely L, Chen F, Teramoto N, et al. Restricted expression of Epstein-Barr virus (EBV)-encoded, growth transformation-associated antigens in an EBV- and human herpesvirus type 8-carrying body cavity lymphoma line. *J Gen Virol* 1998;79(Pt 6):1445-52 [Erratum in: *J Gen;79*(Pt 11):2875].
- [128] Gatter KC, Warnke RA. Diffuse large B-cell lymphoma. In: Jaffe ES, Harris NL, Stein H, Vardiman JW, editors. World Health Organization classification of tumors. Pathology and genetics of tumors of hematopoietic and lymphoid tissues. Lyon: IARC Press; 2001.
- [129] Verma S, Nuovo GJ, Porcu P, Baiocchi RA, Crowson AN, Magro CM. Epstein-Barr virus- and human herpesvirus 8-associated primary cutaneous plasmablastic lymphoma in the setting of renal transplantation. *J Cutan Pathol* 2005;32:35-9.
- [130] Folk GS, Abbondanzo SL, Childers EL, Foss RD. Plasmablastic lymphoma: a clinicopathologic correlation. *Ann Diagn Pathol* 2006; 10:8-12.
- [131] Rochford R, Hobbs MV, Garnier JL, Cooper NR, Cannon MJ. Plasmacytoid differentiation of Epstein-Barr virus-transformed B cells in vivo is associated with reduced expression of viral latent genes. *Proc Natl Acad Sci U S A* 1993;90:352-6.
- [132] Dong HY, Scadden DT, de Leval L, Tang Z, Isaacson PG, Harris NL. Plasmablastic lymphoma in HIV-positive patients: an aggressive Epstein-Barr virus-associated extramedullary plasmacytic neoplasm. *Am J Surg Pathol* 2005;29:1633-41.