

UC San Diego

UC San Diego Previously Published Works

Title

Genomic Landscape of Appendiceal Neoplasms.

Permalink

<https://escholarship.org/uc/item/4p6154kf>

Authors

Ang, Celina
Shen, John
Hardy-Abeloos, Camille
[et al.](#)

Publication Date

2018

DOI

10.1200/PO.17.00302

Peer reviewed

Genomic Landscape of Appendiceal Neoplasms

Purpose Appendiceal neoplasms are heterogeneous and are often treated with chemotherapy similarly to colorectal cancer (CRC). Genomic profiling was performed on 703 appendiceal cancer specimens to compare the mutation profiles of appendiceal subtypes to CRC and other cancers, with the ultimate aim to identify potential biomarkers and novel therapeutic targets.

Methods Tumor specimens were submitted to a Clinical Laboratory Improvement Amendments–certified laboratory (Foundation Medicine, Cambridge, MA) for hybrid-capture–based sequencing of 3,769 exons from 315 cancer-related genes and 47 introns of 28 genes commonly rearranged in cancer. Interactions between genotype, histologic subtype, treatment, and overall survival (OS) were analyzed in a clinically annotated subset of 76 cases.

Results There were five major histopathologic subtypes: mucinous adenocarcinomas (46%), adenocarcinomas (30%), goblet cell carcinoids (12%), pseudomyxoma peritonei (7.7%), and signet ring cell carcinomas (5.2%). *KRAS* (35% to 81%) and *GNAS* (8% to 72%) were the most frequent alterations in epithelial cancers; *APC* and *TP53* mutations were significantly less frequent in appendiceal cancers relative to CRC. Low-grade and high-grade tumors were enriched for *GNAS* and *TP53* mutations, respectively (both $\chi^2 P < .001$). *GNAS* and *TP53* were mutually exclusive (Bonferroni corrected $P < .001$). Tumor grade and *TP53* mutation status independently predicted OS. The mutation status of *GNAS* and *TP53* strongly predicted OS (median, 37.1 months for *TP53* mutant *v* 75.8 *GNAS-TP53* wild type *v* 115.5 *GNAS* mutant; log-rank $P = .0031$) and performed as well as grade in risk stratifying patients.

Conclusion Epithelial appendiceal cancers and goblet cell carcinoids show differences in *KRAS* and *GNAS* mutation frequencies and have mutation profiles distinct from CRC. This study highlights the benefit of performing molecular profiling on rare tumors to identify prognostic and predictive biomarkers and new therapeutic targets.

JCO Precis Oncol. © 2018 by American Society of Clinical Oncology

INTRODUCTION

The rarity of appendiceal neoplasms has made it difficult to conduct prospective or randomized clinical trials to guide therapy for these tumors. The small number of appendiceal tumors that are detected, in many cases as an incidental finding in $< 1\%$ of appendectomy specimens,¹ comprise multiple histopathologic subtypes, including noninvasive mucinous neoplasms, mucinous and nonmucinous adenocarcinomas, carcinoids, goblet cell carcinoids (GCCs, now also called goblet cell tumors), and signet ring cell carcinomas.² Early-stage cancers can be treated definitively with surgery, and selected patients derive long-term benefit from cytoreductive surgery and heated intraperitoneal

chemotherapy (HIPEC).³ However, there is no standard of care for the systemic treatment of advanced, unresectable disease.

In the absence of randomized phase III data, the majority of medical oncologists use colorectal cancer (CRC) chemotherapy regimens for the treatment of unresectable epithelial appendiceal neoplasms, as is currently recommended by the National Comprehensive Cancer Network guidelines. Support for the use of fluoropyrimidine-based combinations with platinum agents or mitomycin-C comes from retrospective single-institution reviews, case reports, and single-arm prospective studies.⁴⁻⁷ Although there are reports of similar response and survival outcomes for contemporary regimens, including infusional

Celina S.-P. Ang
John Paul Shen
Camille J. Hardy-Abeloos
Justin K. Huang
Jeffrey S. Ross
Vincent A. Miller
Miriam T. Jacobs
Ingrid L. Chen
David Xu
Siraj M. Ali
Joel Baumgartner
Andrew Lowy
Paul Fanta
Trey Ideker
Sherri Z. Millis
Olivier Harismendy

Author affiliations and support information (if applicable) appear at the end of this article.

C.S.P.A., J.P.S., S.Z.M., and O.H. contributed equally to this work.

Corresponding author: John Paul Shen, MD, 9500 Gilman Dr, San Diego, CA 92101; e-mail: jpshe@ucsd.edu.

Table 1. Clinical and Demographic Patient Characteristics by Subtype

Subtype	No.	Median Age (years)	Sex Ratio M:F (%)
Mucinous adenocarcinoma	320	54	43:57
Adenocarcinoma	208	56	42:58
Goblet cell carcinoid	84	54	36:64
Pseudomyxoma peritonei	54	54	46:54
Signet ring carcinoma	37	56	49:51

fluorouracil, leucovorin, and oxaliplatin; fluorouracil, leucovorin, and irinotecan; and targeted agents in appendiceal adenocarcinomas compared with CRC,^{8,9} it is known that appendiceal neoplasms have a better prognosis after cytoreductive surgery with HIPEC treatment.¹⁰ There is also a growing body of data showing that there are clear molecular differences between appendiceal and colorectal cancers.¹¹⁻¹⁴ Here we present a cohort of 703 molecularly profiled appendiceal neoplasms, the largest such cohort to date in this rare disease. Comparing the mutational landscapes across histologic subtypes we find significant differences in *KRAS*, *GNAS*, and *FAT3* mutation prevalence and confirm that mutational profiles of appendiceal neoplasms are distinct from CRC and other GI cancers. In addition, we identify that patients can be risk stratified using the combined mutation status of *GNAS* and *TP53* and that outcomes are favorable for patients with *KRAS* wild-type disease when treated with irinotecan.

RESULTS

Mutation Landscape of Appendiceal Neoplasms

The 703 cases were categorized into four different histopathological subtypes consistent with the recently updated consensus classification from the Peritoneal Surface Oncology Group International; in addition, cases of pseudomyxoma peritonei (PMP) were included, because this syndrome usually arises from the appendix.² The majority were either mucinous adenocarcinomas (MAd, 46%) or adenocarcinomas (Ad, 30%), with the rest being GCCs (12%), PMPs (7.7%), or signet ring cell carcinoma (SRCC, 5.3%; Appendix; Table 1). The majority of specimens submitted for sequencing came from intraperitoneal metastatic deposits, although there were also primary appendiceal tumors and a small number of lung, liver, and bone metastases (Fig 1A).

Mutation analysis revealed *KRAS* to be the most frequently mutated gene in MAd (77%), Ad (56%), and PMP (81%) and the second most frequently mutated gene in SRCC (35%). In contrast, *KRAS* mutations were significantly less frequent in GCCs (13%; $\chi^2 P < .001$), where *TP53* (33%) was the most frequently mutated gene (Fig 1B; Appendix Fig A1A). *GNAS* mutations were the second most frequent alteration in MAds (52%) and PMP (72%) and third most frequent in Ad (25%). *GNAS* mutations were significantly less frequent in SRCC (8%) and GCC (6%) compared with the rest of the cohort ($\chi^2 P < .001$). *TP53* mutations were most common in Ads (47%) and SRCCs (43%), slightly less common in MAds (33%) and GCCs (33%), and significantly less common in PMP (7%; $\chi^2 P < .001$). Mutations in *KRAS* were almost exclusively at codon 12, and *GNAS* mutations at codon 201, consistent with gain-of-function, whereas mutations in *TP53* were spread across the gene and included many frameshift mutations, consistent with loss of function (Appendix Figs A1B-A1D).¹⁵ *FAT3* mutations were significantly more frequent in GCCs (17%; $\chi^2 P < .001$). *BRAF*, *BRCA1*, *CDKN1B*, *CDKN2A*, *MYC*, *PTEN*, and *TGFBR2* mutations were present in < 10% of cases across all subtypes (Table 2). Given its unique mutation profile relative to the other histologies, GCCs were excluded from comutation and mutual exclusivity analysis. *GNAS* and *KRAS* were the only gene pair significantly comutated (odds ratio, 6.8; Bonferroni corrected $P = 8.6 \times 10^{-17}$); *GNAS* and *TP53* were the only gene pair significantly mutually exclusive (odds ratio, 0.20; Bonferroni corrected $P = 6.7 \times 10^{-13}$; Fig 1C; Data Supplement).

Pathway-Based Analysis of Mutation Profiles

Genetic aberrations were subsequently grouped by signaling pathway (Appendix Table A1). Components of the *RAS/RAF* signaling pathway (ie, *BRAF*, *HRAS*, *KRAS*, and *NRAS*) were the most frequently altered genes in epithelial appendix cancers, occurring in > 80% of MAds and PMPs, 60% of Ads, but only 33% of GCCs ($\chi^2 P < .001$; Fig 1D). Alterations in homologous recombination deficiency genes were observed in > 50% of all subtypes but were most prevalent in SRCC (80%)

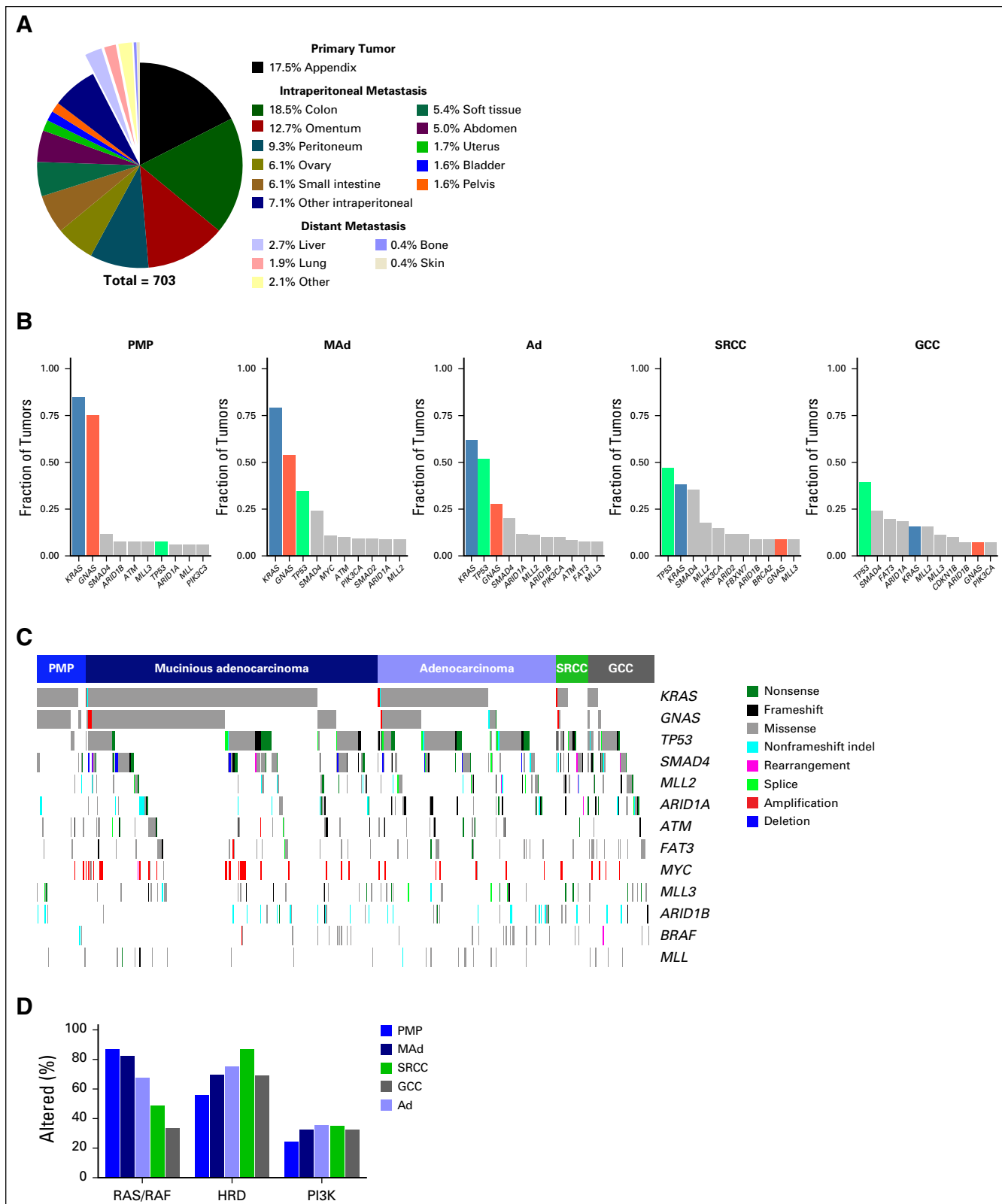


Fig 1. Genomic profiles of appendiceal tumors. (A) Distribution of tissue site submitted for sequencing. (B) Frequency of mutation for selected genes, separated by histologic subtype. (C) Comutation plot from targeted sequencing of 703 appendiceal cancer tumors. A selection of genes relevant to the disease is represented. (D) Frequency of alteration for specific pathways. Ad, adenocarcinoma; GCC, goblet cell carcinoma; MAd, mucinous adenocarcinoma; PMP, pseudomyxoma peritonei; SRCC, signet ring cell carcinoma.

Table 2. Comparison of Mutation Frequencies of Key Genes in Appendiceal, Pancreatic, and Colorectal Cancer

Gene	MAd	Ad	PMP	SRCC	CRC	PDAC	GCC	Neuroendocrine Pancreas
<i>KRAS</i>	77	56	81	35	51	87	13	9
<i>GNAS</i>	52	25	72	8	6	9	6	2
<i>SMAD4</i>	23	18	11	30	16	28	19	3
<i>APC</i>	6	17	2	11	78	5	2	3
<i>ARID1A</i>	8	11	6	3	7	12	15	5
<i>TP53</i>	33	47	7	43	75	71	33	23
<i>RBI</i>	2	3	0	0	1	2	4	11
<i>ERBB2</i>	3	3	4	5	5	3	2	1
MSI-H	1.4	3.2	0.0	3.2	5.0	1.0	2.8	
> 20 mutations/mB	1.3	3.4	0.0	2.7	6.0	1.0	1.2	

NOTE. Data presented as % frequency.

Abbreviations: Ad, adenocarcinoma; CRC, colorectal cancer; GCC, goblet cell carcinoid; MAd, mucinous adenocarcinoma; MSI-H, microsatellite instability-high; PDAC, pancreatic ductal adenocarcinoma; PMP, pseudomyxoma peritonei.

Comparison of Genomic Aberrations in Appendix, Colorectal, and Pancreas Cancers

Given the clinical practice of treating metastatic appendiceal cancers with CRC regimens, we compared genomic alteration profiles of the appendiceal subtypes with those of 10,000 CRCs profiled by the same laboratory (Table 2). CRCs and appendiceal Ads had similar frequencies of *KRAS* (51% *v* 56%, respectively) and *SMAD4* (16% *v* 18%, respectively) mutations. However, all appendiceal subtypes had significantly less-frequent alterations in *TP53* and *APC* relative to CRC ($\chi^2 P < .001$). *GNAS* mutations were significantly more common in MAd, Ad, and PMP ($\chi^2 P < .001$) but not GCC or SRCC (Table 2). The high frequency of *KRAS* mutations observed in multiple appendiceal subtypes prompted inquiry into possible parallels with pancreatic ductal adenocarcinoma (PDAC), which harbors *KRAS* mutations in up to 95% of cases.¹⁶ Sequencing of 2,800 pancreatic tumors revealed *KRAS* mutations in 87% of PDACs. *TP53* mutations were significantly more frequent in PDACs (71%) compared with appendiceal cancers ($\chi^2 P < .001$).

Given their unique alteration landscape relative to other appendiceal subtypes, GCCs, which demonstrate both glandular and neuroendocrine differentiation, were also compared with pancreatic neuroendocrine tumors (PNETs). PNETs and GCCs exhibited similar frequencies of *KRAS*, *GNAS*, and *APC* mutations, but GCCs had significantly more frequent mutations of *SMAD4*, *ARID1A*, and *TP53* ($\chi^2 P < .001$).

Conversely, GCCs exhibited significantly lower rates of *RBI* alteration than PNETs (2% *v* 11%; $\chi^2 P < .001$). High tumor mutational burden (≥ 20 mutations/Mb) and microsatellite-unstable tumors were both slightly more frequent in CRC compared with appendiceal cancers. There tended to be a higher frequency of microsatellite-unstable or tumor mutational burden–high SRCCs and Ads compared with MAd (Table 2; Appendix Fig A1E).

Histopathologic and Molecular Features Predictive of Survival

To determine the influence of histologic and molecular features on clinical outcomes, a retrospective review of a single-institution case series was performed. Similar to the full 703-patient cohort, the majority of cases were either Ads (n = 17) or MAd (n = 33), with fewer low-grade appendiceal mucinous neoplasms that manifested as PMPs (n = 13) and few SRCCs (n = 9). Median follow-up was 29.9 months, with 42 (55%) patients alive at the time of analysis. Data for chemotherapy treatment were available for 60 patients, showing that the majority were treated with a fluoropyrimidine and either oxaliplatin or irinotecan (Appendix; Table 3).

Overall survival (OS), determined from time of initial diagnosis, was similar for Ad and MAd (log-rank $P = .29$; Appendix Fig A2A), so these groups were combined in subsequent analyses. There was a trend toward better OS for low-grade appendiceal mucinous neoplasms/PMPs and worse OS

Table 3. Clinical and Demographic Characteristics, University of California, San Diego, Cohort

Category	Measure
Total patients	76
Men	31 (40.8)
Women	45 (59.2)
Age, years, median	53.4
Age, years, range	23.6-82.8
Follow-up, months, median	29.9
Follow-up, months, range	3.1-143.5
Patients alive at time of analysis	42 (55.2)
Histology	
Adenocarcinoma	17 (24.4)
Mucinous adenocarcinoma	33 (43.4)
Signet ring cell carcinoma	9 (11.8)
LAMN/PMP	13 (17.1)
Goblet cell carcinoid	4 (5.3)
Grade	
High	34 (44.7)
Moderate	9 (11.8)
Low	29 (38.2)
HIPEC surgery	40 (52.6)
Patients with chemotherapy data	60
Lines of chemotherapy, average	1.83
Lines of chemotherapy, SD	0.88
Treated with	
Fluorouracil/capecitabine	57 (95.0)
Oxaliplatin	36 (60.0)
Irinotecan	37 (61.7)
Anti-VEGF antibody	38 (63.3)
Anti-EGFR antibody	8 (13.3)
Anti-PD1/PD-L1 antibody	5 (8.3)
Other	3 (5.0)

NOTE. Data presented as No. (%) unless otherwise noted.

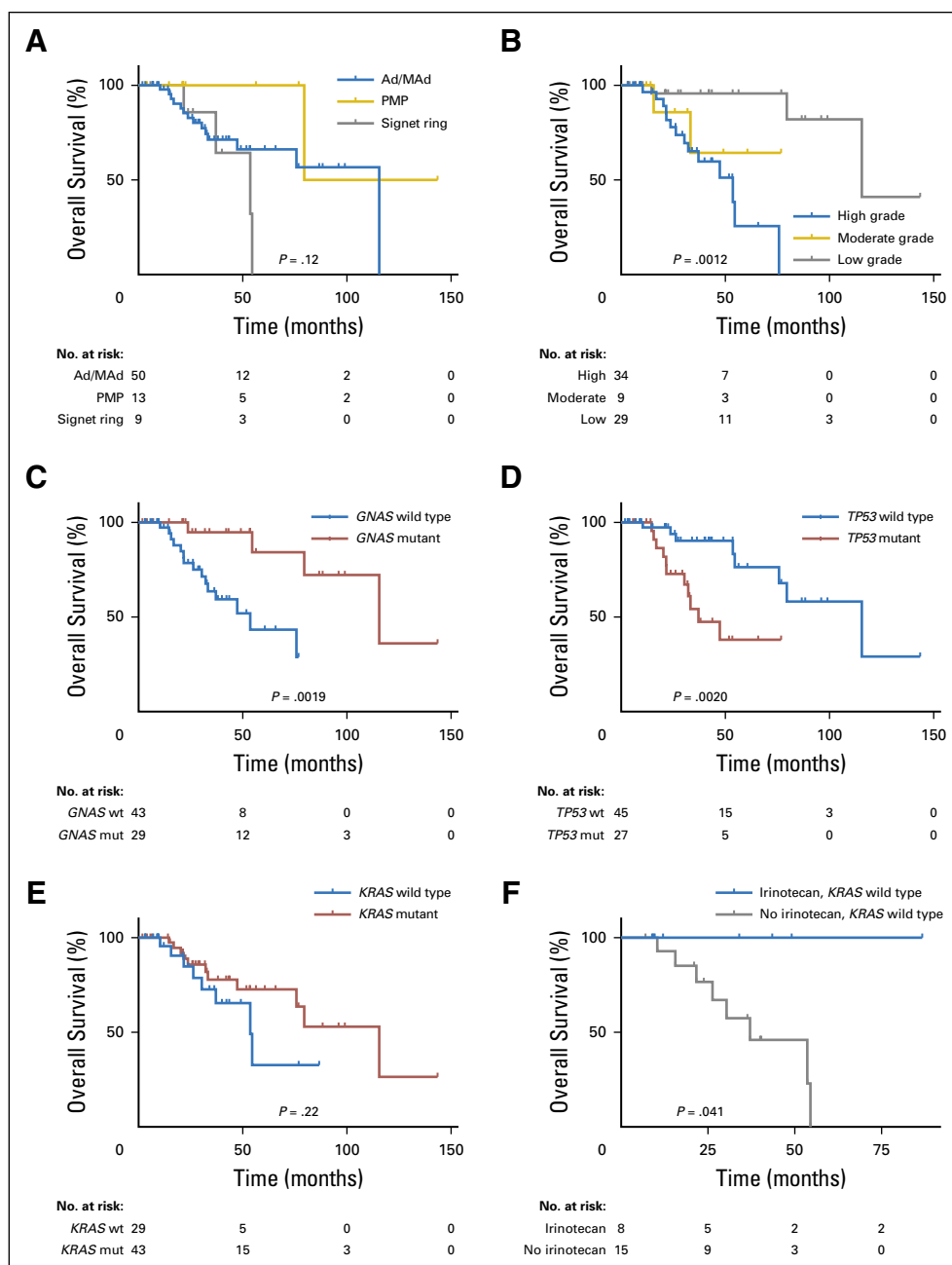
Abbreviations: EGFR, epidermal growth factor receptor; HIPEC, heated intraperitoneal chemotherapy; LAMN, low-grade appendiceal mucinous neoplasms; PD1, programmed cell death protein 1; PD-L1, programmed death ligand 1; PMP, pseudomyxoma peritonei; SD, standard deviation; VEGF, vascular endothelial growth factor.

for SRCCs ($P = .11$; Fig 2A). Consistent with prior reports, tumor grade was strongly predictive of survival, with low-grade tumors (well differentiated) having median OS more than double that of high-grade (poorly differentiated) tumors (115.5 *v* 53.6 months; log-rank $P = .0012$; Fig 2B).¹⁷ Associating mutations with survival, tumors with *GNAS* mutation had significantly better OS than *GNAS* wild-type tumors (log-rank $P = .0019$; Fig 2C). In contrast,

tumors with a *TP53* mutation had significantly worse OS than *TP53* wild-type tumors (37.1 *v* 115.5 months; log-rank $P = .0020$; Fig 2D). *KRAS* mutation status was not significantly associated with survival (log-rank $P = .22$; Fig 2E). However, use of irinotecan in any line of therapy was associated with a survival advantage in *KRAS* wild-type tumors (log-rank $P = .041$; Fig 2F) but not in *KRAS* mutant tumors (log-rank $P = .32$; Appendix Fig A2B). Tumor grade was significantly associated with *GNAS* and *TP53*, but not *KRAS* mutation status. Low-grade tumors were enriched for *GNAS* mutations (72% *v* 18% for high grade; $\chi^2 P < .001$; Appendix Fig A3A), consistent with our prior report,¹⁴ whereas high-grade tumors were enriched for *TP53* mutations (56% *v* 6.9% for low grade; $\chi^2 P < .001$; Appendix Fig A3B).

To assess the relative contributions of mutation and grade to the observed OS differences, a Cox proportional hazard analysis was performed including age, sex, *KRAS*, *GNAS*, *TP53*, and grade as covariates. This identified age (hazard ratio [HR], 1.06/y; $P = .017$), grade (HR, 10.48; $P = .047$), and *TP53* mutation status (HR, 4.51; $P = .022$) as the only significant predictors of survival (Wald Test $P = .0086$). Consistent with the Cox analysis, the rare high-grade tumors with a *GNAS* mutation had OS similar to that of other high-grade tumors (median, 54.5 months *v* 53.6 months for all high-grade tumors; Figs 2B and 3A). However, the effect of *TP53* mutation on survival was independent of grade, with the rare low-grade, *TP53*-mutant tumors having OS similar to other *TP53*-mutant tumors (median, 24.6 months; Fig 3B). Combining *TP53* and *GNAS* mutation status as a prognostic biomarker allowed for stratification of patients into three groups with distinctly different survival outcomes (Fig 3C). Tumors with only a *GNAS* mutation had the best prognosis (median OS, 115.5 months), followed by those with mutation in neither gene (75.8 months), whereas tumors with a *TP53* mutation had the worst prognosis (37.1 months; log-rank $P = .0031$). The survival separation seen between *TP53*- and *GNAS*-mutated tumors was similar to that between high- and low-grade tumors (Fig 3D), suggesting that mutation status and grade have similar prognostic value.

Fig 2. Clinical and molecular features predictive of survival. (A) Overall survival (OS) stratified by histologic subtype. Goblet cell carcinoid (four tumors) was removed from survival analysis. (B) OS stratified by histologic grade. (C) OS stratified by *GNAS* mutation status. (D) OS *TP53* mutation status. (E) OS stratified by *KRAS* mutation status. (F) OS of patients with *KRAS* wild-type disease, stratified by irinotecan use. Ad, adenocarcinoma; MAd, mucinous adenocarcinoma; mut, mutant; PMP, pseudomyxoma peritonei; wt, wild type.

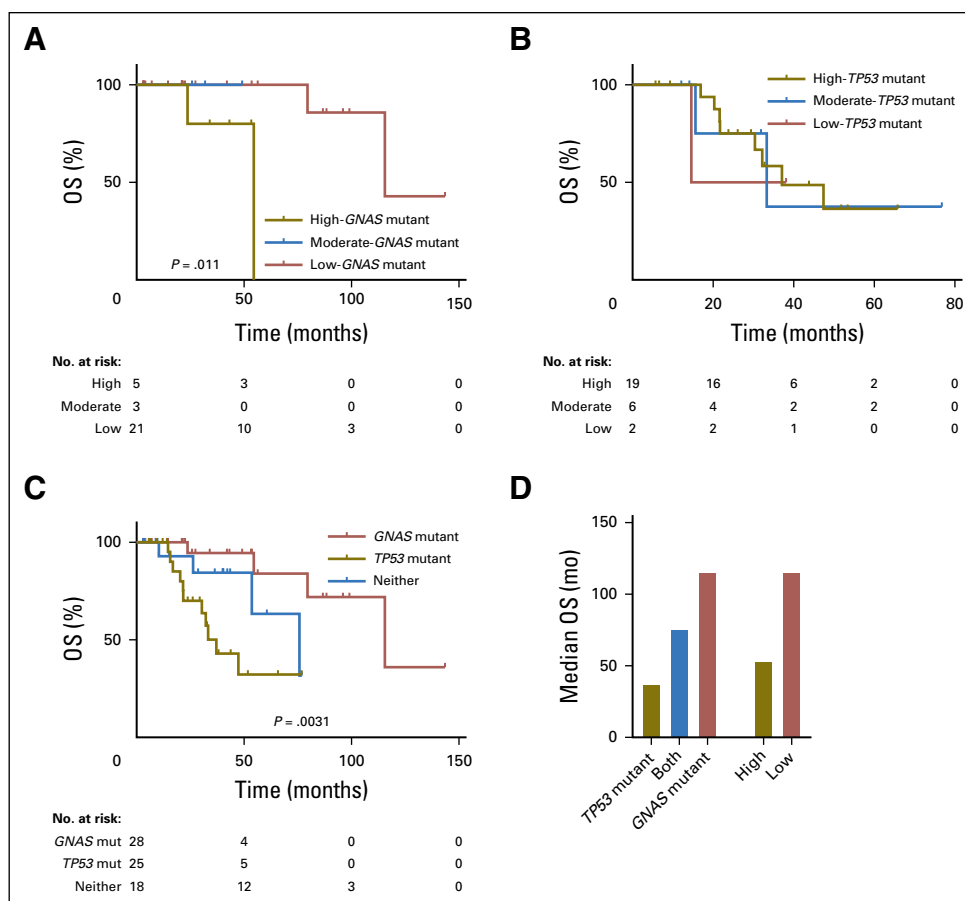


DISCUSSION

The mutational profile of 703 appendix neoplasms provides insight into the molecular aberrations that differentiate histologic subtypes and identifies putative prognostic and predictive biomarkers that may help guide treatment in this rare malignancy. Most striking are differences in mutational spectrum between GCCs and epithelial appendiceal cancers, especially Ad, MAd, and PMP subtypes. Compared with Ad, MAd, and PMP, *KRAS* and *GNAS* mutations were much less frequent in GCCs, whereas mutations in *FAT3* and *ARID1A* were more frequent (Figs 1B and 1C).

These differences were also seen in the pathway analysis, in which GCCs had less-frequent alterations of the RAS/RAF pathway relative to epithelial appendiceal cancers (Fig 1D). The mutational spectrum of GCC was similar to PNETs with respect to *GNAS*, *KRAS*, *APC*, and *RBI* mutation frequency, perhaps not surprising given these tumors are known to display neuroendocrine features (Table 2).¹⁸ In addition, although not significant after multiple hypothesis corrections, there was a trend toward comutation for *GNAS* and *TP53* in GCCs (OR, 8.7; Data Supplement), opposite of what was seen in epithelial appendiceal

Fig 3. Association of tumor grade with *GNAS* and *TP53* mutation status. (A) Overall survival (OS) of patients with *GNAS* mutation, stratified by grade. (B) OS of patients with *TP53* mutation, stratified by grade. (C) OS stratified by combined *TP53*-*GNAS* mutation status. There was only one tumor with both *TP53* and *GNAS* mutations; this group was not included in the survival analysis. (D) Median OS of selected subpopulations.



cancers, providing additional evidence that GCCs are a distinct disease entity.¹⁹

The profiles of epithelial appendiceal cancers were generally similar to each other, showing frequent mutation in *KRAS* and *GNAS* followed by *TP53* and *SMAD4*, consistent with previously reported case series^{13,14,20-26} (Appendix Table A2). These data also show that all of the appendiceal subtypes are molecularly distinct from CRC, with more frequent *GNAS* mutation and significantly lower prevalence of *APC* and *TP53* mutations, which are key pathogenic alterations in CRC. This is a clinically important point, because this case series confirms that most patients with appendix cancer are treated with CRC chemotherapy regimens (Table 3). The mutation profiles of Ad and SRCC bore the most resemblance to CRC, with Ad and CRC sharing similar frequencies of mutation in *KRAS*, *SMAD4*, and *ARID1A*; of note, appendiceal Ads have been referred to as colonic-type adenocarcinoma, given clinical behavior more similar to CRC.^{20,27} In this series, SRCC had the worst prognosis of the epithelial appendiceal tumors and also has a clinical course similar to CRC.²⁸

The frequent comutation of *KRAS* and *GNAS* in MAAd, Ad, and PMP parallels the molecular profile of intraductal papillary mucinous neoplasms.^{14,29} Notably, both intraductal papillary mucinous neoplasms and, in particular, *GNAS* mutant appendiceal cancers are characterized by mucin production and a generally indolent clinical course. The differences in mutation profiles between the epithelial appendiceal tumors can be at least partially explained by grade, with significant association of *GNAS* mutation with low-grade tumors and *TP53* mutation with high-grade tumors (Appendix Figs A3A and A3B). Consistent with this is the higher incidence of *TP53* mutation and lower incidence of *GNAS* mutation in SRCCs, which are by definition all high grade.

Histologic grade was also a strong predictor of survival (Fig 2B), consistent with prior reports.^{17,30} We did not observe a significant difference in OS between Ad and MAAd; however, the distribution of tumor grade was similar between these two subtypes in our study. In contrast, in prior case series that reported better survival for MAAd, MAAds were enriched for

low-grade tumors.²⁰ Although *GNAS* mutant tumors were significantly associated with better survival, Cox proportional hazard analysis confirmed that this effect was due to the association of *GNAS* mutation and low histologic grade. Conversely, *TP53* mutation was an independent predictor of poor survival, with low-grade, *TP53*-mutant tumors having survival similar to that of high-grade tumors. Accurately assessing the grade of appendiceal tumors is difficult. Frequently, not all tumor deposits can be surgically removed, giving rise to possible sampling errors where focal high-grade lesions could be missed. In addition, because appendiceal tumors are so rare, they are difficult to diagnose pathologically and are frequently overinterpreted by community pathologists.³¹ Although *GNAS* mutation is not an independent predictor of survival, because *GNAS* and *TP53* mutations occur mutually exclusive of each other and are associated with low- and high-grade tumors, respectively, the two genes can be substituted for grade to predict survival. The survival stratification achieved with the *GNAS-TP53* biomarker is similar to grade, an important observation, given that it is now much easier to obtain a mutation profile than an expert pathology review in the community oncology setting.

The absence of a *GNAS* mutation in the majority of high-grade tumors and the mutual exclusivity of *TP53* and *GNAS* mutations both strongly suggest that most high-grade appendiceal tumors occur de novo, rather than progressing from low-grade tumors, confirming, on a larger scale, our previous observations.¹⁴ However, there were a minority of tumors with both *TP53* and *GNAS* mutation (n = 41; 6.7%), suggesting that transformation from low grade to high grade can occur. Serial biopsy or serial measurement of circulating tumor DNA would be needed to confirm that these *TP53* mutations did in fact occur after the formation of a low-grade, *GNAS*-mutant tumor. However, given the low propensity for appendiceal tumors to spread beyond the abdominal cavity, there may be limited tumor DNA in circulation, potentially making blood-based tumor detection difficult. Indeed, three of the four University of California, San Diego, patients who underwent circulating tumor DNA sequencing had no reportable alterations.

Regarding predictive biomarkers, *KRAS* wild-type status was associated with better survival in

the subset of patients treated with irinotecan. A retrospective study in metastatic CRC reported better response to irinotecan in patients with wild-type versus mutant plasma *KRAS*.³² However, a larger prospective study found that mutant *KRAS* was associated with poor survival but not with response to irinotecan in CRC.³³ Regarding targeted therapies, there are unfortunately few clinically actionable mutations in appendiceal cancers, although the RAS/RAF signaling pathway is frequently altered in epithelial appendiceal cancers. Data on therapeutic targeting of the RAS/RAF cascade in appendiceal tumors are limited, although a recent case report described clinical benefit in a patient with appendiceal MAd harboring a *GNAS R201H* mutation who was treated with trametinib.³⁴ Because only eight patients in this cohort received an anti-EGFR antibody, we were unable to assess interactions between *KRAS* mutation status and response to these agents.

A major limitation of this study is its retrospective design. With regard to the 703-patient cohort, clinical information such as precise TNM stage was not available, but the fact that > 80% of specimens submitted came from metastases indicates that the majority of patients had stage IV disease. Although specimens were independently reviewed by pathologists to confirm the diagnosis before undergoing sequencing, subtype definitions are potentially subject to variability and overlap, because there was no consensus classification system for appendiceal neoplasms and PMP until recently.² For example, PMP is an inherently imprecise term used to describe the clinical syndrome of mucinous peritoneal dissemination from an appendiceal neoplasm. PMP encompasses a spectrum of both high- and low-grade lesions but does not reference the histopathologic characteristics of the appendiceal primary from which it arises. Newer classification schemes separate PMPs with low-grade and high-grade features (also known as disseminated peritoneal adenomucinosis and peritoneal mucinous carcinomatosis, respectively³⁵) and PMP with signet ring cells.² Because this study did not distinguish between these subtypes, we are unable to report on genomic differences associated with grade in the larger 70-patient cohort. With respect to the 76-patient University of California, San Diego, cohort, this analysis is also limited by its single-institution and retrospective nature,

small sample size, and relatively limited time of follow-up. Chemotherapy treatment data were not available for those patients who were referred to an academic center for surgery but received chemotherapy in a community setting. In addition, analysis of interactions between genotype and specific drugs are confounded by the fact that most patients received multiple lines of therapy.

In conclusion, appendiceal neoplasms have molecular profiles that are distinct from CRC and are characterized by frequent *GNAS* and *KRAS* mutations, especially in low-grade tumors.

This study of unprecedented size in this rare disease highlights important molecular differences between different subtypes of appendix cancer and identifies *GNAS* and *TP53* mutation status as a prognostic biomarker. This comprehensive portrait of the molecular landscape of appendix cancer will help with the design of future clinical studies to develop and test therapeutic strategies specific to this disease.

DOI: <https://doi.org/10.1200/PO.17.00302>

Published online on ascopubs.org/journal/po on August 8, 2018.

AUTHOR CONTRIBUTIONS

Conception and design: Celina S.-P. Ang, John Paul Shen, Paul Fanta, Trey Ideker, Sherri Z. Millis, Olivier Harismendy

Financial support: John Paul Shen, Paul Fanta, Trey Ideker

Administrative support: John Paul Shen, Paul Fanta

Provision of study material or patients: John Paul Shen, Jeffrey S. Ross, Joel Baumgartner, Andrew Lowy, Paul Fanta, Sherri Z. Millis

Collection and assembly of data: John Paul Shen, Jeffrey S. Ross, Miriam T. Jacobs, Ingrid L. Chen, David Xu, Siraj M. Ali, Andrew Lowy, Paul Fanta, Sherri Z. Millis

Data analysis and interpretation: Celina S.-P. Ang, John Paul Shen, Camille J. Hardy-Abeloos, Justin K. Huang, Jeffrey S. Ross, Vincent A. Miller, Miriam T. Jacobs, Ingrid L. Chen, Siraj M. Ali, Joel Baumgartner, Paul Fanta, Trey Ideker, Sherri Z. Millis, Olivier Harismendy

Manuscript writing: All authors

Final approval of manuscript: All authors

Jeffrey S. Ross

Employment: Foundation Medicine

Leadership: Foundation Medicine

Stock and Other Ownership Interests: Foundation Medicine

Research Funding: Foundation Medicine

Vincent A. Miller

Employment: Foundation Medicine

Leadership: Foundation Medicine

Stock and Other Ownership Interests: Foundation Medicine

Patents, Royalties, Other Intellectual Property: Receive periodic royalties related to T790M patent awarded to Memorial Sloan Kettering Cancer Center

Miriam T. Jacobs

No relationship to disclose

Ingrid L. Chen

Employment: Pfizer (I)

Stock and Other Ownership Interests: Pfizer (I)

David Xu

No relationship to disclose

Siraj M. Ali

Employment: Foundation Medicine

Leadership: Incyte

Stock and Other Ownership Interests: Exelixis, Blueprint Medicines, Agios Pharmaceuticals, Genocera Biosciences

Patents, Royalties, Other Intellectual Property: Patents via Foundation Medicine and Seres Health

Joel Baumgartner

Research Funding: Merck

Andrew Lowy

Consulting or Advisory Role: Halozyme, Merck

Research Funding: Mitsubishi Tanabe Pharma, Syros Pharmaceuticals

Expert Testimony: Merck

Travel, Accommodations, Expenses: Pfizer

AUTHORS' DISCLOSURES OF POTENTIAL CONFLICTS OF INTEREST

The following represents disclosure information provided by authors of this manuscript. All relationships are considered compensated. Relationships are self-held unless noted. I = Immediate Family Member, Inst = My Institution. Relationships may not relate to the subject matter of this manuscript. For more information about ASCO's conflict of interest policy, please refer to www.asco.org/rwc or ascopubs.org/po/author-center.

Celina S.-P. Ang

No relationship to disclose

John Paul Shen

No relationship to disclose

Camille J. Hardy-Abeloos

No relationship to disclose

Justin K. Huang

Stock and Other Ownership Interests: Anavex Life Sciences

Travel, Accommodations, Expenses: Guardant Health

Paul Fanta
No relationship to disclose

Trey Ideker
Leadership: Data4Cure

Consulting or Advisory Role: Ideaya BioSciences, Genetic Modifiers Newco, Merck, La Jolla Institute for Allergy and Immunology

Research Funding: Pfizer

Travel, Accommodations, Expenses: Sage Bionetworks

Sherri Z. Millis
Employment: Foundation Medicine

Olivier Harismendy
No relationship to disclose

Affiliations

Celina S.-P. Ang, Camille J. Hardy-Abeloos, Jeffrey S. Ross, Paul Fanta, and Trey Ideker, Mount Sinai Hospital, New York, NY; **John Paul Shen, Justin K. Huang, Miriam T. Jacobs, Ingrid L. Chen, David Xu, Joel Baumgartner, Andrew Lowy, Paul Fanta, Trey Ideker, and Olivier Harismendy,** University of California, San Diego, La Jolla, CA; **Jeffrey S. Ross,** Albany Medical College, Albany, NY; **Vincent A. Miller, Siraj M. Ali, and Sherri Z. Millis,** Foundation Medicine, Cambridge, MA.

Support

Supported by a Career Development Grant from the Tower Cancer Research Foundation (J.P.S.); National Cancer Institute Grants No. U54 CA209891 (T.I.), L30 CA171000 (J.P.S.), and 2P30 CA023100 and U01 CA196406 (O.H.); and National Institute for General Medical Sciences Grant No. P50 GM085764 (T.I.).

Prior Presentation

Presented at the ASCO Gastrointestinal Cancers Symposium, San Francisco, CA, January 18-20, 2018.

REFERENCES

1. Connor SJ, Hanna GB, Frizelle FA: Appendiceal tumors: Retrospective clinicopathologic analysis of appendiceal tumors from 7,970 appendectomies. *Dis Colon Rectum* 41:75-80, 1998
2. Carr NJ, Cecil TD, Mohamed F, et al: A consensus for classification and pathologic reporting of pseudomyxoma peritonei and associated appendiceal neoplasia: The results of the Peritoneal Surface Oncology Group International (PSOGI) modified Delphi process. *Am J Surg Pathol* 40:14-26, 2016
3. Reghunathan M, Kelly KJ, Valasek MA, et al: Histologic predictors of recurrence in mucinous appendiceal tumors with peritoneal dissemination after HIPEC. *Ann Surg Oncol* 25:702-708, 2018
4. Sugarbaker PH, Bijelic L, Chang D, et al: Neoadjuvant FOLFOX chemotherapy in 34 consecutive patients with mucinous peritoneal carcinomatosis of appendiceal origin. *J Surg Oncol* 102:576-581, 2010
5. Farquharson AL, Pranesh N, Witham G, et al: A phase II study evaluating the use of concurrent mitomycin C and capecitabine in patients with advanced unresectable pseudomyxoma peritonei. *Br J Cancer* 99:591-596, 2008
6. Shapiro JF, Chase JL, Wolff RA, et al: Modern systemic chemotherapy in surgically unresectable neoplasms of appendiceal origin: A single-institution experience. *Cancer* 116:316-322, 2010
7. Garin L, Corbinais S, Boucher E, et al: Adenocarcinoid of the appendix vermiformis: Complete and persistent remission after chemotherapy (folfox) of a metastatic case. *Dig Dis Sci* 47:2760-2762, 2002
8. Lieu CH, Lambert LA, Wolff RA, et al: Systemic chemotherapy and surgical cytoreduction for poorly differentiated and signet ring cell adenocarcinomas of the appendix. *Ann Oncol* 23:652-658, 2012
9. Tejani MA, ter Veer A, Milne D, et al: Systemic therapy for advanced appendiceal adenocarcinoma: An analysis from the NCCN Oncology Outcomes Database for colorectal cancer. *J Natl Compr Canc Netw* 12:1123-1130, 2014
10. Sugarbaker PH, Jablonski KA: Prognostic features of 51 colorectal and 130 appendiceal cancer patients with peritoneal carcinomatosis treated by cytoreductive surgery and intraperitoneal chemotherapy. *Ann Surg* 221:124-132, 1995

11. Raghav KPS, Loree JM, Fournier KF, et al: Comprehensive genomic profiling of appendiceal adenocarcinoma. *J Clin Oncol* 36, 2018 (suppl; abstr 298)
12. Johncilla M, Stachler M, Misdrayi J, et al: Mutational landscape of goblet cell carcinoids and adenocarcinoma ex goblet cell carcinoids of the appendix is distinct from typical carcinoids and colorectal adenocarcinomas. *Mod Pathol* 31:989-996, 2018
13. Borazanci E, Millis SZ, Kimbrough J, et al: Potential actionable targets in appendiceal cancer detected by immunohistochemistry, fluorescent in situ hybridization, and mutational analysis. *J Gastrointest Oncol* 8:164-172, 2017
14. Alakus H, Babicky ML, Ghosh P, et al: Genome-wide mutational landscape of mucinous carcinomatosis peritonei of appendiceal origin. *Genome Med* 6:43, 2014 [Erratum: *Genome Med* 6:53, 2014]
15. Vogelstein B, Papadopoulos N, Velculescu VE, et al: Cancer genome landscapes. *Science* 339:1546-1558, 2013
16. Tatarian T, Winter JM: Genetics of pancreatic cancer and its implications on therapy. *Surg Clin North Am* 96:1207-1221, 2016
17. Grotz TE, Royal RE, Mansfield PF, et al: Stratification of outcomes for mucinous appendiceal adenocarcinoma with peritoneal metastasis by histological grade. *World J Gastrointest Oncol* 9:354-362, 2017
18. Clift AK, Kornasiewicz O, Drymoussis P, et al: Goblet cell carcinomas of the appendix: Rare but aggressive neoplasms with challenging management. *Endocr Connect* 7:268-277, 2018
19. Reid MD, Basturk O, Shaib WL, et al: Adenocarcinoma ex-goblet cell carcinoid (appendiceal-type crypt cell adenocarcinoma) is a morphologically distinct entity with highly aggressive behavior and frequent association with peritoneal/intra-abdominal dissemination: An analysis of 77 cases. *Mod Pathol* 29:1243-1253, 2016
20. Kabbani W, Houlihan PS, Luthra R, et al: Mucinous and nonmucinous appendiceal adenocarcinomas: different clinicopathological features but similar genetic alterations. *Mod Pathol* 15:599-605, 2002
21. Liu X, Mody K, de Abreu FB, et al: Molecular profiling of appendiceal epithelial tumors using massively parallel sequencing to identify somatic mutations. *Clin Chem* 60:1004-1011, 2014
22. Raghav KP, Shetty AV, Kazmi SM, et al: Impact of molecular alterations and targeted therapy in appendiceal adenocarcinomas. *Oncologist* 18:1270-1277, 2013
23. Szych C, Staebler A, Connolly DC, et al: Molecular genetic evidence supporting the clonality and appendiceal origin of pseudomyxoma peritonei in women. *Am J Pathol* 154:1849-1855, 1999
24. Gleeson EM, Feldman R, Mapow BL, et al: Appendix-derived pseudomyxoma peritonei (PMP): Molecular profiling toward treatment of a rare malignancy. *Am J Clin Oncol* [10.1097/COC.0000000000000376](https://doi.org/10.1097/COC.0000000000000376) [Epub ahead of print on March 3, 2017]
25. Nishikawa G, Sekine S, Ogawa R, et al: Frequent GNAS mutations in low-grade appendiceal mucinous neoplasms. *Br J Cancer* 108:951-958, 2013
26. Singhi AD, Davison JM, Choudry HA, et al: GNAS is frequently mutated in both low-grade and high-grade disseminated appendiceal mucinous neoplasms but does not affect survival. *Hum Pathol* 45:1737-1743, 2014
27. Shaib WL, Assi R, Shamseddine A, et al: Appendiceal mucinous neoplasms: Diagnosis and management. *Oncologist* 22:1107-1116, 2017
28. McCusker ME, Coté TR, Clegg LX, et al: Primary malignant neoplasms of the appendix: A population-based study from the surveillance, epidemiology and end-results program, 1973-1998. *Cancer* 94:3307-3312, 2002
29. Tan MC, Basturk O, Brannon AR, et al: GNAS and KRAS mutations define separate progression pathways in intraductal papillary mucinous neoplasm-associated carcinoma. *J Am Coll Surg* 220:845-854.e1, 2015

30. Asare EA, Compton CC, Hanna NN, et al: The impact of stage, grade, and mucinous histology on the efficacy of systemic chemotherapy in adenocarcinomas of the appendix: Analysis of the National Cancer Data Base. *Cancer* 122:213-221, 2016
31. Valasek MA, Thung I, Gollapalle E, et al: Overinterpretation is common in pathological diagnosis of appendix cancer during patient referral for oncologic care. *PLoS One* 12:e0179216, 2017
32. Spindler KG, Appelt AL, Pallisgaard N, et al: KRAS-mutated plasma DNA as predictor of outcome from irinotecan monotherapy in metastatic colorectal cancer. *Br J Cancer* 109:3067-3072, 2013
33. Richman SD, Seymour MT, Chambers P, et al: KRAS and BRAF mutations in advanced colorectal cancer are associated with poor prognosis but do not preclude benefit from oxaliplatin or irinotecan: results from the MRC FOCUS trial. *J Clin Oncol* 27:5931-5937, 2009
34. Ang C, Stollman A, Zhu H, et al: Clinical benefit from trametinib in a patient with appendiceal adenocarcinoma with a GNAS R201H mutation. *Case Rep Oncol* 10:548-552, 2017
35. Ronnett BM, Zahn CM, Kurman RJ, et al: Disseminated peritoneal adenomucinosis and peritoneal mucinous carcinomatosis. A clinicopathologic analysis of 109 cases with emphasis on distinguishing pathologic features, site of origin, prognosis, and relationship to "pseudomyxoma peritonei." *Am J Surg Pathol* 19:1390-1408, 1995

Appendix

Tumor tissue from 703 patients with appendiceal cancer was submitted to a Clinical Laboratory Improvement Amendments–certified laboratory (Foundation Medicine, Cambridge, MA) for DNA sequencing and variant calling. Pathology reports and a subset of hematoxylin and eosin slides were reviewed by board-certified pathologists to independently confirm the diagnosis and subtype of appendiceal cancer. However, grade was not reported in the majority of cases. A minimum of 50 ng of DNA was extracted and a hybrid-capture method used to capture 3,769 exons from 315 cancer-related genes and 47 introns of 28 genes commonly rearranged in cancer; this material was then sequenced to high (average, 756X) uniform coverage allowing for evaluation of genomic alterations, including base substitutions, indels, amplifications, copy number alterations, and fusions/rearrangements. Actionable genomic alterations were defined as those identifying anticancer drugs on the market or in registered clinical trials. Tumor mutational burden was calculated from a minimum of 1.11 Mb sequenced DNA and reported as mutations per megabase. Microsatellite status was determined by evaluating the insertion/deletion characteristics at 114 homopolymer repeat loci in targeted regions of the genes.

Approval for this study, including a waiver of informed consent and a Health Insurance Portability and Accountability Act waiver of authorization, was obtained from the Western Institutional Review Board (protocol No. 20152817). Separately, the University of California, San Diego (UCSD) Institutional Review Board granted approval for a retrospective study of UCSD patients with appendix cancer. Clinical characteristics and outcomes, including tumor histology, grade, stage, overall survival (OS), and chemotherapy given were determined from review of the electronic medical record. All UCSD patients with appendix cancer with Foundation Medicine sequencing were initially included in the study. A total of 80 patients with stage IV appendix cancer and somatic mutation profiling were identified. Sequencing failed quality control in two cases, and two patients with only blood-based cell-free DNA sequencing were excluded, leaving 76 patients available for analysis. Because there were only four goblet cell carcinoids, these were removed from survival analysis.

For mutual exclusivity and comutation analysis, goblet cell carcinoid tumors and microsatellite instability-high tumors were removed, and a Fisher's exact test was performed for all gene combinations, followed by Bonferroni multiple hypothesis correction. Kaplan-Meier plotting, log-rank, and χ^2 statistical tests were performed using Prism version 7.04 (GraphPad, La Jolla, CA). Cox proportional hazard analysis for predictors of overall survival was performed including age, sex, *KRAS*, *GNAS*, *TP53*, and grade as covariates.

Fig A1. Mutation burden and spectrum in appendiceal tumors. (A) Tumor mutation frequency (mutations per megabase) for each subtype. Incidence and location of mutations in (B) *KRAS*, (C) *GNAS*, and (D) *TP53*. (E) Tumor mutation burden (mutations per megabase) for each histologic subtype. Ad, adenocarcinoma; GCC, goblet cell carcinoid; MAD, mucinous adenocarcinoma; PMP, pseudomyxoma peritonei; TMB, tumor mutational burden.

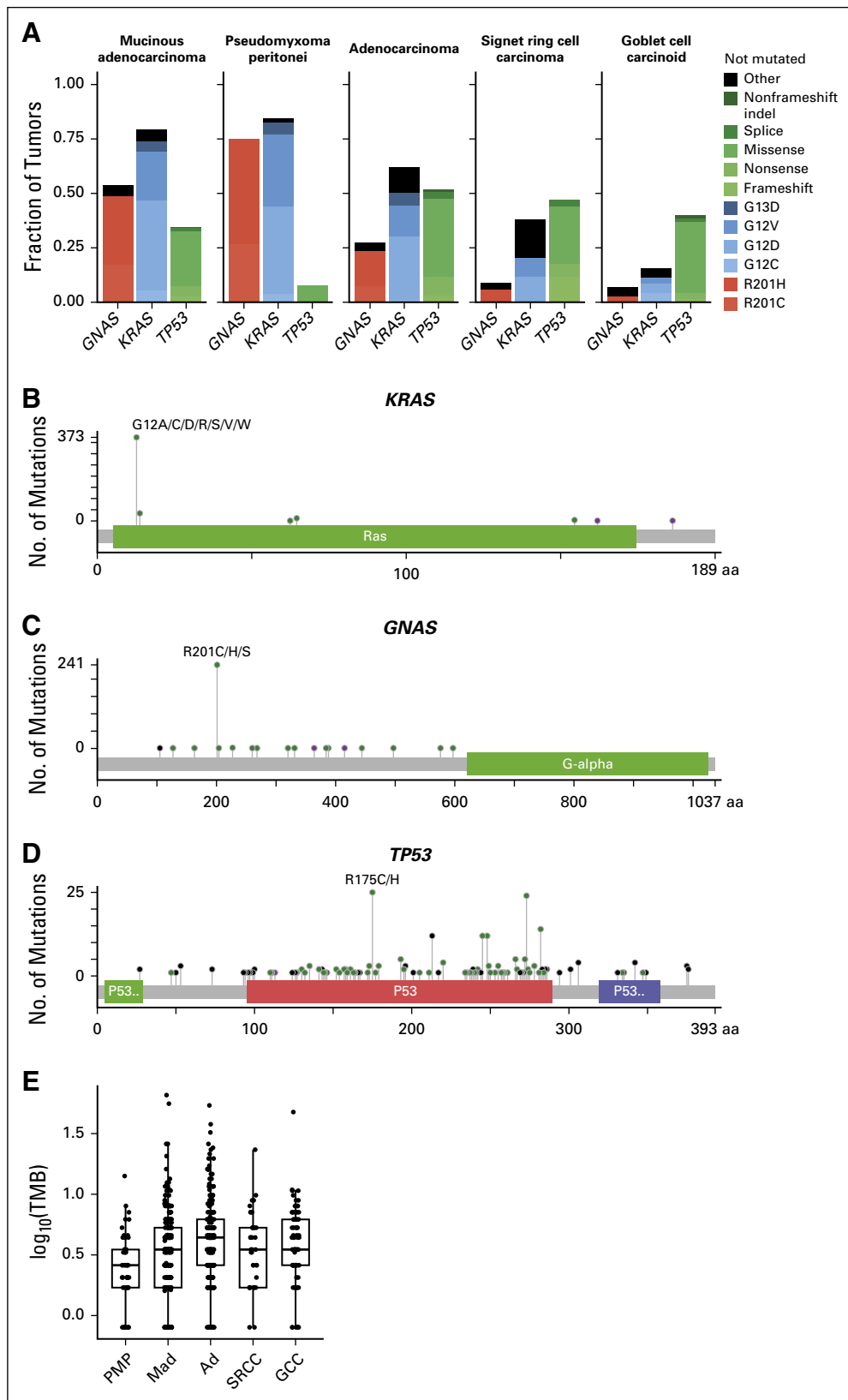


Fig A2. Clinical and molecular features predictive of survival. (A) Overall survival of adenocarcinoma (Ad) versus mucinous adenocarcinoma (MAd). (B) Overall survival of patients with *KRAS* mutations, stratified by irinotecan use.

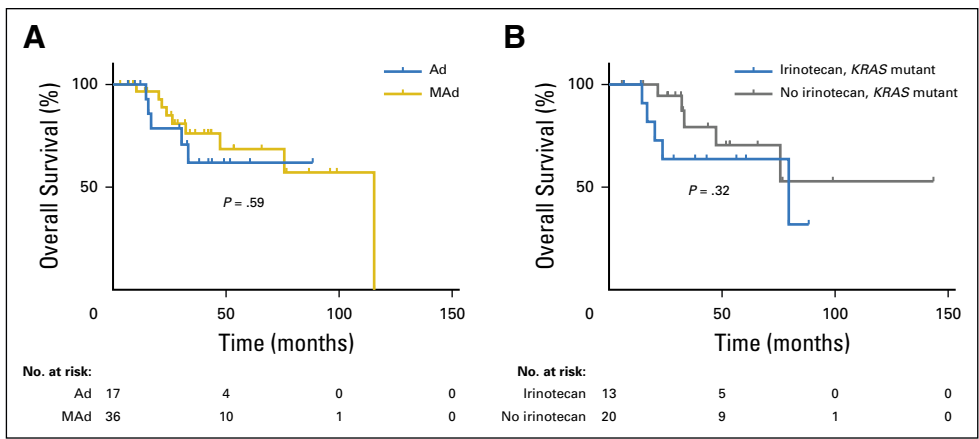


Fig A3. Correlation of grade with *GNAS*, *TP53* mutation status. (A) *GNAS* mutation frequency, by grade. (B) *TP53*, by grade. (C) Adenocarcinoma versus mucinous adenocarcinoma frequency, by grade.

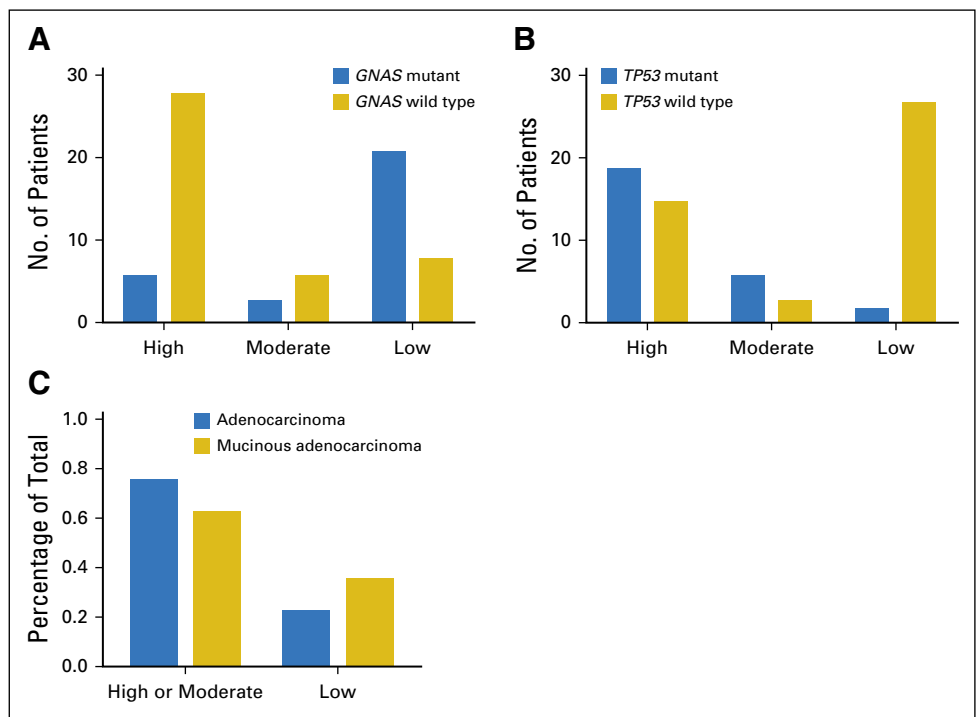


Table A1. Gene Lists for Pathway Analysis

HRD	PI3K Pathway	RAS/RAF Pathway
<i>APC</i>	<i>AKT1</i>	<i>BRAF</i>
<i>ARID1A</i>	<i>AKT2</i>	<i>ERBB2</i>
<i>ARID1B</i>	<i>AKT3</i>	<i>ERBB3</i>
<i>ARID2</i>	<i>FBXW7</i>	<i>ERBB4</i>
<i>ATM</i>	<i>INPP4B</i>	<i>HRAS</i>
<i>ATR</i>	<i>MTOR</i>	<i>KRAS</i>
<i>ATRX</i>	<i>PIK3C2B</i>	<i>MAP2K1</i>
<i>BAP1</i>	<i>PIK3C2G</i>	<i>MAP2K2</i>
<i>BARD1</i>	<i>PIK3CA</i>	<i>MAP2K4</i>
<i>BLM</i>	<i>PIK3CB</i>	<i>MET</i>
<i>BRCA1</i>	<i>PIK3CG</i>	<i>NRAS</i>
<i>BRCA2</i>	<i>PIK3R1</i>	
<i>BRIP1</i>	<i>PIK3R2</i>	
<i>CHEK2</i>	<i>PTEN</i>	
<i>FANCA</i>	<i>RICTOR</i>	
<i>FANCC</i>	<i>RPTOR</i>	
<i>FANCD2</i>	<i>STK11</i>	
<i>KDM5A</i>	<i>TSC1</i>	
<i>MRE11A</i>	<i>TSC2</i>	
<i>MUTYH</i>		
<i>NBN</i>		
<i>PALB2</i>		
<i>RAD51</i>		
<i>RAD51B</i>		
<i>RAD51C</i>		
<i>SMAD4</i>		
<i>TP53</i>		

Abbreviations: HRD, homologous recombination deficiency; PI3K, phosphoinositide 3-kinase.

Table A2. Literature Review of Genomic Profiling Results in Appendiceal Cancer Subtypes

Subtype	KRAS (%)	GNAS (%)	SMAD4 (%)	APC (%)	TP53 (%)	Other (%)	Reference	Test Technology
MAd	77	49	13	5	33		Current study	Full exon 315 genes, intronic regions in 28 genes
	65	34	15	7	24		Borazanci ¹³	Hot spot NGS, PCR (<i>KRAS</i> only)
	50				0	MSS 100	Kabbani ^{20a}	PCR, IHC
	43	22			14	<i>RB</i> 7	Liu ^{21b}	
	100	0 ^c					Nishikawa ²⁵	PCR of select exons
		37					Singhi ²⁶	
	100	90					Alakus ¹⁴	Whole-exome sequencing
Ad	52	22	22	14	37		Current study	Full exon 315 genes, intronic regions in 28 genes
	47	17	22	32	32		Borazanci ¹³	Hot spot NGS, PCR (<i>KRAS</i> only)
	75				14	MSS 100	Kabbani ²⁰	PCR, IHC
	55					<i>BRAF</i> V600E 4 <i>PI3K</i> 4 MSS 94 <i>EGFR</i> 0	Raghav ^{22d}	PCR, IHC
GCC	12	2	20	2	37		Current study	Full exon 315 genes, intronic regions in 28 genes
	9	3	13	3	11		Borazanci ¹³	Hot spot NGS, PCR (<i>KRAS</i> only)
	4		20	12	20	<i>NRAS</i> 4 <i>PIK3CA</i> 8 <i>IDH1</i> 4 <i>ATM</i> 8	Liu ^{21e}	
		15					Singhi ²⁶	

(Continued on following page)

Table A2. Literature Review of Genomic Profiling Results in Appendiceal Cancer Subtypes (Continued)

Subtype	KRAS (%)	GNAS (%)	SMAD4 (%)	APC (%)	TP53 (%)	Other (%)	Reference	Test Technology
PMP	82	72	11	0	39		Current study	Full exon 315 genes, intronic regions in 28 genes
	83	57	14	0	0		Borazanci ¹³	Hot spot NGS, PCR (<i>KRAS</i> only)
	95, ^f 83 ^g	95, ^f 33 ^g	33 ^f	0	17 ^g	<i>TGFBR1/2</i> 17 ^f <i>PRKACA</i> 17 ^g	Alakus ¹⁴	Whole-exome sequencing
	100 ^h						Szych ²³	PCR
	81	74	16	11	5	<i>MSS</i> 93 <i>ATM</i> 16 <i>PIK3CA</i> 10 <i>BRAF</i> 8 <i>MET</i> 11	Gleeson ^{24h}	Hot spot NGS

Abbreviations: Ad, nonmucinous adenocarcinoma; GCC, goblet cell carcinoid; IHC, immunohistochemistry; MAd, mucinous adenocarcinoma; MSS, microsatellite stable; NGS, next-generation sequencing; PCR, polymerase chain reaction; PMP, pseudomyxoma peritonei.

^a16% mucinous adenocarcinomas with PMP.

^bWith PMP.

^cn = 3.

^dAppendiceal adenocarcinomas (mucinous/nonmucinous not differentiated).

^eAppendiceal adenocarcinomas with/without goblet cell/signet ring features.

^fLow-grade MCP only.

^gHigh-grade MCP only.

^hAll-female population.