

UC San Diego

UC San Diego Previously Published Works

Title

Technique and role of embolization using ethylene vinyl-alcohol copolymer before carotid body tumor resection

Permalink

<https://escholarship.org/uc/item/4t85q100>

Journal

Clinics and Practice, 4(3)

ISSN

2039-7275

Authors

Thakkar, Rajiv
Qazi, Umair
Kim, Young
et al.

Publication Date

2014-10-01

DOI

10.4081/cp.2014.661

Peer reviewed

Technique and role of embolization using ethylene vinyl-alcohol copolymer before carotid body tumor resection

Rajiv Thakkar,¹ Umair Qazi,¹ Young Kim,¹ Elliot K. Fishman,¹ Frank J. Veith,² Mahmoud B. Malas¹

¹Johns Hopkins Medical Institutions, Baltimore, MD; ²New York University Medical Center, New York, NY, USA

Abstract

A 45-year old female referred for a large carotid body tumor resection. The tumor was encasing the internal (ICA) and external carotid arteries (ECA). She underwent angiogram and embolization of the ascending pharyngeal artery and a distal branch of the ECA using ethylene vinyl-alcohol copolymer (EVOH). Two days later, surgical resection of the tumor with regional lymph node dissection was performed along with an interposition reversed vein graft anastomosis between the mid common carotid and distal ICA. Devascularization of carotid body tumor can be performed using EVOH delivered through trans-arterial and percutaneous routes. Embolization may facilitate surgical resection and decrease blood loss but does not decrease the rate of neurological complications. Embolization can be performed by the vascular surgeon before a large carotid body tumor resection with minimal migration and or stroke risk.

Case Report

A 45-year old female referred for a slow growing painless left neck swelling for last 5 years. There were no symptoms of cranial nerve involvement or dysphagia. Physical examination showed a large non-tender left neck mass extending from about 4 cm above the clavicle to the angle of the mandible. Computerized axial tomography scan and magnetic resonance imaging confirmed a 6.2×5.4×5.2 cm carotid body tumor at the carotid bifurcation completely encasing internal (ICA) and external carotid arteries (ECA) (Figure 1A).

Step 1: Embolization using ethylene vinyl-alcohol copolymer

Patient underwent angiogram (Figure 1B) and embolization of the ascending pharyngeal artery and a distal branch of the ECA using ethylene vinyl-alcohol copolymer (EVOH) (Onyx®

34, LES, Covidien, Plymouth, MN, USA) (Figure 1C) as follows.

Ultrasound guided trans-femoral arterial access was established using a 5 French micro puncture needle and 5 French micro sheath (Cook Medical, Indianapolis, IN, USA). Seldinger's technique was used to exchange to a 6-French, 90 cm Shuttle Select Sheath (Cook Medical) over 0.035, 260 cm Magic Torque wire (Boston Scientific Corp., Natick, MA, USA). She received heparin 80 U/kg intravenously. Activated clotting time was kept between 250-300 s range. Diagnostic angiogram of the aortic arch at 45-degree lateral anterior oblique angle was performed utilizing 4-French, 125 cm pigtail catheter (Cook Medical), which showed a normal aortic arch with patent major branches. The left common carotid artery (CCA) was selected utilizing 6-French, 125 cm JB-1 slip catheter (Cook Medical) and 0.035, 260 cm angle tip Glide wire (Terumo Medical Corp., Somerset, NJ, USA). The shuttle select was advanced over the JB-1 compatible catheter into the mid CCA. Diagnostic angiogram through the Shuttle Select Sheath showed a large hyper-vascular tumor slaying ICA and ECA (Lyre sign) and patent carotid vessels (Figure 1A). Selection of ECA was established with the JB-1 slip catheter and glide wire. Angiogram of ECA showed several branches feeding the tumor. Roadmap and fluoroscopy Fade technique were utilized to super select these branches. This was done using a 0.014, 300cm Transend Guide wire (Boston Scientific Corp.) and a 150 cm, 2.1 French outer diameter 0.017 inch inner diameter Echelon 10 Micro Catheter with 45 degree angled tip (EV3 Endovascular Inc., Irvine, CA, USA) through the JB-1 slip catheter. Once the contrast dye from the micro catheter was flushed using 10ml normal saline, the dead space was filled with 1 mL dimethyl sulfoxide (DMSO) to prevent premature solidification of EVOH. We mixed 6.5 mL (5 vials) of EVOH continuously for about 25 min up until ready to be injected when DMSO syringe was removed and EVOH syringe was attached to the catheter hub. Under fluoroscopic visualization, EVOH was slowly injected at the rate of 0.3 mL/min to embolize ascending pharyngeal and a distal branch of ECA. Once completed, the micro-catheter was slowly pulled out. Fade technique was utilized to ensure there was no backflow in ECA, and ICA. Post embolization angiogram showed good EVOH filling with complete devascularization in the superior portion but incomplete de-vascularization in the inferior portion of the tumor.

Step 2: Surgical tumor resection and vascular reconstruction

Two days later, under evoked potential monitoring, surgical resection of the tumor (Figure

Correspondence: Rajiv Thakkar, Johns Hopkins Medical Institutions, 5200 Eastern Avenue, MFL Bldg West Tower 6th Floor, Baltimore, MD 21224, USA. Tel.: +1.4105505018. E-mail: rthakka1@jhmi.edu

Key words: embolization, carotid body tumor, ethylene vinyl-alcohol copolymer, Onyx®.

Received for publication: 27 May 2014.

Revision received: 10 September 2014.

Accepted for publication: 30 September 2014.

This work is licensed under a Creative Commons Attribution NonCommercial 3.0 License (CC BY-NC 3.0).

©Copyright R. Thakkar et al., 2014
Licensee PAGEPress, Italy
Clinics and Practice 2014; 4:661
doi:10.4081/cp.2014.661

1D) with regional lymph node dissection was performed as follows.

Using harmonic scissor (Ethicon, Somerville, NJ, USA), skin and subcutaneous tissues were incised. Tumor was completely encasing the carotid vessels. Vagus and hypoglossal nerves were adherent to it and were isolated intact after a difficult dissection. ECA and its branches feeding the tumor were identified and ligated. After that, ICA and CCA were transected along with tumor. An interposition reversed vein graft was anastomosed between the mid CCA and distal ICA at the base of the skull using a greater saphenous vein harvested from right lower extremity. An intra-operative duplex scan showed excellent flow through the graft with no evidence of stenosis. Approximate blood loss was 800 cubic centimeters and she received 4 units of blood. Postoperatively, she had a transient XII cranial nerve dysfunction. Biopsy showed paraganglioma with negative lymph nodes. Follow-up carotid duplex showed occlusion of the bypass graft; however, patient had no neurological deficits.

Discussion

Carotid body tumors are and rare benign vascular neoplasms arising from the small chemoreceptor organ in the adventitia of the CCA bifurcation. Smaller tumors not encasing the vessels (Shamblin I) may be treated with radiation but surgical resection remains the treatment of choice for tumors partially (Shamblin II) or completely (Shamblin III) encasing the vessels. Due to proximity of nerves, the rate of neurological complications is higher with tumors of higher Shamblin groups.¹ Devascularization of the tumor can be

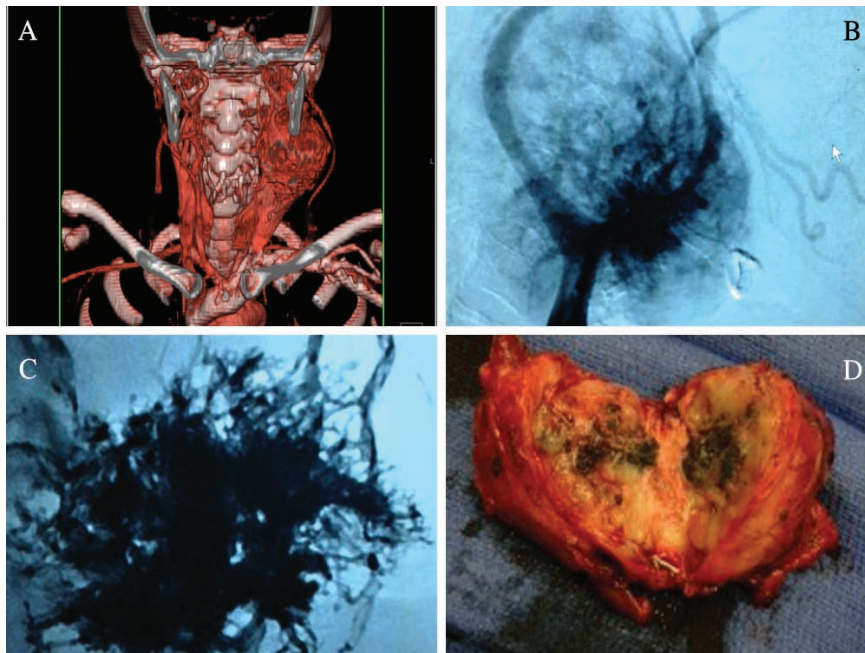


Figure 1. A) Computerized axial tomography scan confirming a 6.7×5.4×5.2 cm carotid body tumor; B and C) angiogram and embolization of the ascending pharyngeal artery; D) surgical resection of the tumor.

safely and effectively performed using embolysate delivered through transarterial² and percutaneous³ (direct injection into the tumor) routes.

One of the concerns for embolization is inadequate devascularization,² another is embolysate migration² into ICA causing stroke. Failure to identify and embolize all feeders can lead to inadequate devascularization.

The embolization technique described in our case report is mainly intended to reduce blood loss. However, our patient experienced 800 cc blood loss despite embolization. We believe that blood loss may have been higher if embolization was not performed. There could be several potential reasons for more than average blood loss including large hyper-vascular tumor, failure to identify and embolize all feeders and not using enough ETOH to devascularize the tumor. Abdel-Aziz *et al.* has shown that percutaneous tumor embolization may

achieve a higher degree of devascularization.⁴ However, we were concerned about any over flow that might leak into the ICA and cause a stroke due to the nature of the copolymer, which cannot be captured in any distal embolic protection device (Filter).

In our case, migration was avoided by direct visualization of vessels during embolization procedure utilizing fluoroscopy fade technique.³ Embolization may facilitate surgical resection and decrease blood loss but does not reduce the rate of neurological complications.⁵ Acrylic glue, endovascular coils or EVOH can be utilized for pre-operative embolization. EVOH may be easier to use and may have better tumor penetration because it can be injected slowly for precise delivery into the feeding vessels² compared to acrylic glue, which polymerize immediately on contact with blood. Embolization can be safely performed by the treating vascular surgeon to devascularize a

large carotid body tumor with minimal risk of migration and stroke.

Recommendations

- A standard guideline needs to be setup about the amount of copolymer needed to embolize according to the tumor size before surgical resection.
- A follow-up angiogram a day or two after copolymer use to confirm adequate de-vascularization of the tumor prior to surgical resection may be helpful in reducing excessive blood loss and avoiding any serious intra-operative complications.

References

1. Sen I, Stephen E, Malepathi K, et al. Neurological complications in carotid body tumors: a 6-year single-center experience. *J Vasc Surg* 2013;57:64S-8S.
2. Kalani MY, Ducruet AF, Crowley RW, et al. Trans-femoral transarterial onyx embolization of carotid body paragangliomas: technical considerations, results, and strategies for complication avoidance. *Neurosurgery* 2013;72:9-15; discussion 15.
3. Shah HM, Gemmete JJ, Chaudhary N, et al. Preliminary experience with the percutaneous embolization of paragangliomas at the carotid bifurcation using only ethylene vinyl alcohol copolymer (EVOH) Onyx. *J Neurointerv Surg* 2012;4:125-9.
4. Abdel-Aziz T, Lehmann M, Dietrich U, et al. Surgical outcome of carotid body tumour resection after percutaneous embolization using Onyx((R)), an ethylene-vinyl alcohol copolymer(dagger). *Head Neck Oncol* 2013;5:5.
5. Power AH, Bower TC, Kasperbauer J, et al. Impact of preoperative embolization on outcomes of carotid body tumor resections. *J Vasc Surg* 2012;56:979-89.