

UC Irvine

UC Irvine Previously Published Works

Title

Experimental facial myokymia in cat

Permalink

<https://escholarship.org/uc/item/4tp9x2f2>

Journal

Acta Neurologica Scandinavica, 95(1)

ISSN

0001-6314

Authors

Zaaroor, M
Starr, A

Publication Date

1997

DOI

10.1111/j.1600-0404.1997.tb00062.x

Copyright Information

This work is made available under the terms of a Creative Commons Attribution License, available at <https://creativecommons.org/licenses/by/4.0/>

Peer reviewed

Experimental facial myokymia in cat

Zaaroor M, Starr A. Experimental facial myokymia in cat. Acta Neurol Scand 1997; 95: 19–22. © Munksgaard 1997.

Introduction – The objective of this study was to describe facial myokymia in experimental animals accompanying kainic acid effects on facial motor neurons. **Material & methods** – Anesthetized cats were injected with kainic acid into the pons adjacent to the facial nucleus. Facial movements appeared shortly after the injections and facial electromyographic potentials were recorded. Cats were killed up to 4 weeks later, the brainstems were processed histologically, and the number of neurons in the facial nucleus counted. **Results** – Cats receiving injection of kainic acid adjacent to facial nucleus all developed spontaneous writhing movements of the face ipsilateral to the injection site, clinically resembling facial myokymia in humans. Transient facial paresis, lasting several weeks, appeared in some of the cats. Facial myokymia occurred independent of histological evidence of neuronal loss in facial nucleus, whereas facial paresis occurred in all but one of the animals with significant neuronal loss in the facial nucleus. Placing a needle into the superior olive without injecting kainic acid or injections of kainic acid into cochlear nucleus was not accompanied by facial myokymia or subsequent facial paresis. **Conclusion** – Facial movements in cats similar to myokymia in humans accompanies kainic acid injections adjacent to the nucleus of the facial nerve.

M. Zaaroor¹, A. Starr²

¹Department of Neurosurgery, Ramborn Medical Center Faculty of Medicine, Technion, Haifa, Israel

²Department of Neurology, University of California Irvine, Irvine, USA

Key words: Myokymia; Kainic acid; Glutamate; Cat; brainstem lesion

Arnold Starr MD, Department of Neurology, University of California Irvine, Irvine, California 92717, USA

Accepted for publication September 9, 1996

Facial myokymia refers to involuntary, wavelike, undulating, vermicular movements, of the face usually restricted to a portion of one side of the face (1–3). The EMG shows continuous irregular discharges of individual facial motor units. Facial myokymia can occur in patients with brainstem disorders such as multiple sclerosis, pontine glioma, and syringobulbia or with proximal facial nerve lesions both within and adjacent to brainstem (1–6). The condition can also be benign appearing in otherwise normal individuals during fatigue or after excessive alcohol ingestion (4). Electromyography (EMG) of the facial muscles during facial myokymia reveals continuous irregular discharges of normal motor units. Occasionally motor units discharge in short bursts followed by a brief period of quiescence. The EMG of facial myokymia is easily distinguished from other ‘spontaneous’ facial motor activities accompanying hemifacial spasm, motor tics, palatal myoclonus, and focal cortical seizures (2–4).

The pathophysiology underlying facial myokymia is unknown but has been attributed to a disorder of the motor neurons in facial nucleus induced by lesions either within or adjacent to that structure, by lesions remote from facial nucleus but affecting inputs to the facial nucleus, or by lesions of the

facial nerve within (3) or close to the brainstem (5). In the course of studies of the generation of auditory brainstem potentials in cats, we observed facial myokymia to appear following the injection of kainic acid, an excitatory amino acid, into the superior olive, which lies adjacent to the facial nucleus (6, 7). Kainic acid, an excitatory neurotoxic amino acid binding to glutamate receptors, elicits a sustained depolarization of neurons that can be followed by neuronal death. Kainic acid selectively affects neurons and spares axons of passage and nerve terminals of extrinsic origin (8–11). In our studies, the injection of kainic acid into the pons was followed, within thirty minutes, by continuous undulating movements of the face and whiskers ipsilateral to the injection. The movements clinically resembled those of facial myokymia in humans.

Methods

Animals

Thirteen adult cats (2700–3400 g) were injected with kainic acid, 8 into the superior olivary complex (SOC) and 5 into cochlear nucleus (CN) to define changes in auditory brainstem evoked potentials (6

for methods). Two of these cats received bilateral injections into the SOC; three other cats had a needle inserted into the SOC without injection of kainic acid to serve as 'controls'.

Operation

The cats were operated twice using sodium pentobarbital (35 mg/kg) as the anesthetic agent. Body temperature were maintained with a heating blanket and electrocardiogram (ECG) was monitored. In the first operation the animal was prepared for electrophysiological study with four small recording screws implanted into the skull for recording auditory evoked potentials. The animal was given penicillin (300,000 units) preoperatively. The second operation occurred after an interval of at least 3 weeks. The cat was anesthetized, placed in stereotaxic frame, the posterior portion of the skull exposed, a small craniectomy made and the dura mater opened for the stereotaxic insertion of a glass insulated needle attached to a 10 μ L Hamilton syringe which served both as a recording probe and a vehicle to transmit a 1% solution of kainic acid into the brainstem.

The electrode was lowered through the cerebellum to the region of the SOC in 11 cats, and into the CN in 5 cats. Kainic acid was injected in 0.1–0.2 μ L aliquot over 0.5 h to attain a total volume of 0.5 μ L. The first few cats studied developed a marked bradycardia with junctional rhythm as an escape mechanism after sinus arrest. Subsequently, intermittent atrial activity appeared, albeit sporadically, and after 20 min heart rhythms returned to normal. The arrhythmia could be prevented by prior treatment with atropine (0.04 mg/kg). No cardiac arrhythmia developed after injection into the cochlear nucleus or by placing a needle in the brainstem in the control cats.

Kainic acid preparation

Kainic acid (2-carboxyl-3-carboxymethyl-4-isopropenylpyrrolidine, ICN C.N 195264) was mixed with 0.9% sodium chloride in water to form a 1% solution. The solution was brought to PH=6 with sodium hydroxide. A fresh solution of kainic acid was made prior to each injection.

Electromyography (EMG)

Monopolar needle electrodes (Grass needle electrodes type E2-monopolar) were inserted into the orbicularis oris and orbicularis oculi bilaterally. The electromyographic signals were amplified 50,000 times at a bandpass of 3–3000 Hz and recorded for several hours after injection.

Histology

Up to 40 days after the Kainic acid injection, the animals were deeply anesthetized with sodium pentobarbital (100 mg/kg) and perfused through the heart with normal saline followed by 10% buffered formalin. The brain was removed and stored in 10% buffered formalin for 15 days. Frozen section of the brainstem, 30 μ m in thickness, were cut and serially stained with crystal violet for cell bodies alternating with Kluver-Barrera stain or chromoxane cyanine R with crystal violet for myelin. The number of neurons in the facial nucleus and their morphology was defined under high magnification (\times 400) bilaterally. Neuronal loss in the facial nucleus ipsilateral to the side of injection was expressed as a percentage of the number of neurons in the facial nucleus on the opposite side. When the injections were bilateral, neuronal loss was expressed as a percentage of the number of neurons in control cats.

Results

Myokymia

Within 30 min of the injection of kainic acid into the superior olivary complex, flickering movements of the face and whiskers developed; ipsilateral to the injection site in the 6 cats with uni-lateral injection into SOC and bilaterally in the cats with bilateral injections into SOC (Fig. 1). The myokymia persisted for up to 3 hours. The EMG demonstrated continuous activity of the orbicularis oris and oculi involving many motor units. No spontaneous facial movements (myokymia) were detected in the three control cats (with only a needle placed into SOC) and in the six cats injected into the cochlear nucleus. Four of the eight animals with myokymia subsequently developed facial paresis affecting both perioral and periocular muscles: their eyelids did not close and the extent of facial movements on the affected side(s) was greatly reduced. The facial paresis recovered within two weeks except in one cat (#14).

Histology

In the animals with kainic acid injection into the superior olivary complex, the extent of neuronal loss in the facial nucleus varied from 0–40% (Table 1). Myokymia appeared in all of these animals and was independent of the presence or absence of neuronal loss. In contrast, the appearance of facial paresis occurred only in those animals with neuronal loss greater than 10% (Table 1). In all cats the extent of neuronal loss was substantially greater in

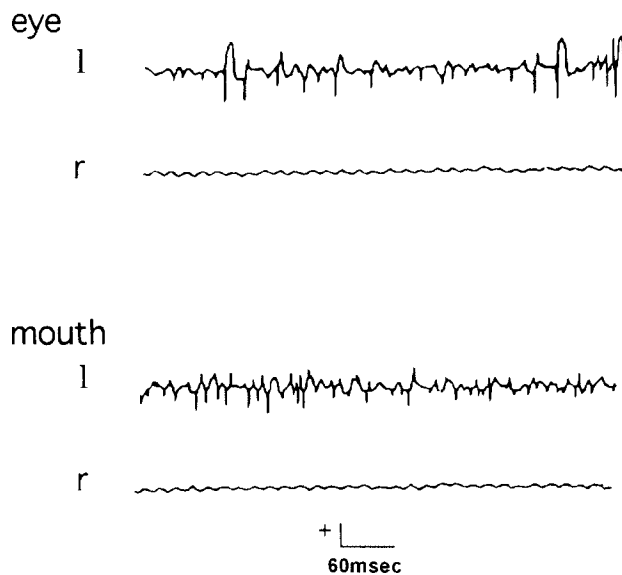


Fig. 1. Kainic acid injection into the region of the superior olivary nucleus was accompanied by facial myokymia ipsilateral to the injection. The EMG of facial muscles showed repetitive irregular bursting motor units ipsilateral to the injected side. There were no movements or EMG discharges in contralateral facial muscles.

the superior olivary complex, the site of injection, than in the adjacent seventh cranial nerve nucleus (7).

Discussion

In the course of studying the effects of kainic acid-induced neuronal damage of auditory brainstem nuclei on auditory brainstem potentials (6), facial movements best classified as myokymia appeared in those animals in whom the site of injection was in the superior olivary complex, a structure lying just adjacent to the nucleus of the seventh cranial nerve. The facial movements were small, continuous, and had a writhing character, features that are all seen in facial myokymia in humans (2, 3). The EMG of the affected facial muscles in these cats showed continuous asynchronous discharges which differed from the EMG patterns described accompanying facial myokymia in humans. In such patients the EMG consists of 1) frequent burst activity at 2–10 times/s with each burst containing high frequency (30–100 c/s) discharges; and 2) slow grouping of activity occurring at relatively long intervals (0.2–2/s) with discharges in each burst containing discharges at 30–300/s (12). In these cats with myokymia-like facial movements, the discharge pattern was different from the human patterns which may have reflected the relatively short duration of EMG sampled (500 ms) as well as the brief interval between the injury to the facial nucleus and the EMG recording.

Table 1. Facial myokymia, facial paresis, and facial motor neuronal loss accompanying kainic acid or saline solution injection into the brainstem

Cat	Injection site	Myokymia	Paresis	Cell loss (%)
Kainic acid injection				
5	SOC unilateral	yes	yes	30
8	SOC unilateral	yes	yes	22
7	SOC unilateral	yes	no	7
17	SOC unilateral	yes	no	25
23	SOC unilateral	yes	no	0
26	SOC unilateral	yes	no	0
14	SOC bilateral	yes	yes	40,40
20	SOC bilateral	yes	yes	25,22
21	Cochlear Nuc.	no	no	0
22	Cochlear Nuc.	no	no	0
24	Cochlear Nuc.	no	no	0
25	Cochlear Nuc.	no	no	0
28	Cochlear Nuc.	no	no	0
30	Cochlear Nuc.	no	no	0
Saline injection				
6	SOC unilateral	no	no	0
11	SOC unilateral	no	no	0
18	SOC unilateral	no	no	0

SOC; Superior Olivary Complex
Cochlear Nuc.; Cochlear nucleus

Kainic acid alters neuronal function through its action on glutamate receptors (14, 16), one of which has been designated a kainate receptor because of its selective activation by kainic acid. The activation of the kainate receptors results in the opening of ion channels for Na, K, and Ca (13, 16) leading to the neuron's depolarization (9, 10). The depolarization is sustained and may be accompanied by cell death depending on the density of kainate receptors on the neuron and the concentration and amount of kainic acid injected (15). In the present experiments, the facial myokymia accompanying kainic acid injection was transitory, lasting up to 3 h, most likely reflecting a transient depolarization of neurons of the seventh nerve nucleus by diffusion of the kainic acid injected from the adjacent superior olivary complex.

The superior olivary complex in cats is only 1.5 mm cephalad to the facial nucleus, allowing easy diffusion of the kainic acid to the neurons of the facial nucleus. Certainly when the kainic acid was injected farther and more lateral to the facial nucleus (e.g., the cochlear nucleus) no facial myokymia was seen. In two of the cats injected bilaterally into the superior olivary complexes, the amount of kainic acid which diffused to the facial nucleus was sufficient to cause cell loss in the facial nucleus and transient total facial paralysis. Further experiments testing whether inhibitors of kainic acid would alter the appearance of myokymia can not be done in our current laboratories. The resemblance of these movements to facial myokymia in

humans raises the possibility that a disorder of glutamate receptors of facial motor neurons may contribute to the expression of some cases of human myokymia. Kainic acid-induced transient neuronal changes at brainstem sites regulating cardiac rhythms may also account for the transient cardiac arrhythmia that followed injections of kainic acid into the pons. These effects could be blocked by a single dose of atropine.

Excitatory amino acid, such as glutamate and aspartate, are major neurotransmitters in the mammalian central nervous system. While these amino acids are responsible for normal excitatory transmission, and are involved in neuronal survival, synapse formation, neuronal plasticity and learning and memory processes (13), they also represent a possible mechanism for neuronal dysfunction and neurotoxicity (11, 13). Normally, the concentration of glutamate around its receptors is regulated by several mechanisms (13, 14). Abnormally low level of glutamate can compromise excitation, whereas excessive level can produce toxic effects (15). Excitotoxicity refers to a paradoxical phenomenon whereby the neuroexcitatory action of glutamate and related compounds (e.g., kainic acid), becomes transformed into a neuropathological process that can lead to neuronal death (14).

Pathological examination of the brainstem of patients with myokymia have demonstrated lesions of the pontine tegmentum and basis pontis (3, 18, 20) or demyelinating lesions of both the intra-axial (19) and extra-axial facial nerve (5). Demyelination can be associated with an increase in the affected fibers' excitability leading to both spontaneous and induced discharges as demonstrated both experimentally (17) and in common clinical experience (e.g., tic douloureux). Lesions of the brainstem that spare the facial nucleus and facial nerve can be associated with myokymia, presumably due to the lesions' effects on descending inputs to the facial nucleus. The results of the present study are that facial myokymia can also accompany altered facial neuronal excitability induced by kainic acid activation of glutamate receptors. Facial myokymia is an expression of several different processes altering the functioning of facial motor neurons and their axons. These include (1) disconnection of facial motor neurons from other brain regions by brainstem lesions; (2) alterations of the excitability of facial nerves accompanying demyelinating lesions of proximal facial motor nerves; and (3) alterations of facial motor neuron receptors.

Acknowledgement

Supported in part by a grant Number NS11876, The National Institutes of Health.

References

1. MATTEWS WB. Facial myokymia. *J Neurol Neurosurg Psychiatry* 1966; 29: 35-39.
2. GUTMANN L. Facial and limb myokymia. *Muscle Nerve* 1991; 14: 1043-1049.
3. JACOBS L, KABA S, PULLICINO P. The lesion causing continuous facial myokymia in multiple sclerosis. *Arch Neurol* 1994; 51: 1115-1119.
4. GILROY J, MEYER JS. *Medical neurology*, Macmillan: New York, 1975: 657-658.
5. WASSERSTROM WR, STARR A. Facial myokymia in the Guillain-Barré syndrome. *Arch Neurol* 1977; 34: 576-577.
6. SCAIOLI V, SAVOJARDO M, BUSSONE G, REZZONICO M. Brainstem auditory evoked potential (BAEPs) and magnetic resonance imaging (MRI) in case of facial myokymia. *Electroencephalogr Clin Neurophysiol* 1988; 71: 153-156.
7. ZAARoor M, STARR A. Auditory brain-stem evoked potentials in cat after kainic acid induced neuronal loss. I. Superior olivary complex. *Electroencephalogr Clin Neurophysiol* 1991; 80: 422-435.
8. ZAARoor M, STARR A. Auditory brain-stem evoked potentials in cat after kainic acid induced neuronal loss. II. Cochlear nucleus. *Electroencephalogr Clin Neurophysiol* 1991; 80: 436-445.
9. COYLE JT, MOLLIVER ME, KUJAR MJ. *In situ* injection of kainic acid: a new method for selectively lesioning neuronal cell bodies while sparing axons of passage. *J Compr Neurol* 1978; 180: 301-324.
10. MASTERTON RB, GLENDENNING KK, HUTSON KA. Preservation of trapezoid body fibers after biochemical ablation of superior olives with kainic acid. *Brain Res* 1979; 173: 156-159.
11. ROONEY BJ, KAVANAGH GL, KELLY JB. Preservation of fibers of passage following kainic acid lesions of the superior olivary complex in the ferret. An HRP analysis. Abstracts Society for Neuroscience. 18th annual meeting Toronto, Ont., 1988: 201.
12. SIVAK M, OSHOA J, FERNANDEZ J. Positive manifestation of nerve fiber dysfunction: Clinical electrophysiologic and pathologic correlates. In: Brown WF, Bolton CF, eds. *Clinical electromyography*, Second edition, Boston, Butterworth-Heinemann, 1993: 131-133.
13. FAROOQUI AA, HORROCKS LA. Excitatory amino acid receptors, neuronal membrane phospholipid metabolism and neurological disorders. *Brain Res Rev* 1991; 16: 171-191.
14. MAYER ML, WESTBROOK GL. The physiology of excitatory amino acids in the vertebrate central nervous system. *Prog Neurobiol* 1987; 28: 197-276.
15. ROTHMAN SM, OLNEY JW. Glutamate and the pathophysiology of hypoxic-ischemic brain damage. *Ann Neurol* 1986; 19: 105-111.
16. MONAGHAN DT, BRIDGES RJ, COTMAN CW. The excitatory amino acid receptors: their classes pharmacology, and distinct properties in the function of the central nervous system. *Annu Rev Pharmacol Toxicol* 1989; 29: 365-402.
17. SMITH KJ, McDONALD WI. Spontaneous and evoked electrical discharges from central demyelination lesion. *J Neurol Sci* 1982; 55: 39-47.
18. WAYBRIGHT EA, GUTMANN L, CHOU SM. Facial myokymia. *Arch Neurol* 1979; 36: 244-245.
19. CHERINGTON M, SADLER KM, RYAN D. Facial myokymia. *Surg Neurol* 1979; 11: 478-480.
20. SETHI PK, SMITH BH, KALYANARAMAN. Facial myokymia: a clinicopathological study. *J Neurol Neurosurg Psychiatry* 1974; 37: 745-759.