

# UC San Diego

## UC San Diego Previously Published Works

### Title

Atypical central neurocytoma with novel EWSR1-ATF1 fusion and MUTYH mutation detected by next-generation sequencing.

### Permalink

<https://escholarship.org/uc/item/4vb125n3>

### Journal

BMJ case reports, 12(1)

### ISSN

1757-790X

### Authors

Aghajan, Yasmin  
Malicki, Denise M  
Levy, Michael L  
et al.

### Publication Date

2019

### DOI

10.1136/bcr-2018-226455

Peer reviewed

## CASE REPORT

# Atypical central neurocytoma with novel EWSR1-ATF1 fusion and MUTYH mutation detected by next-generation sequencing

Yasmin Aghajan,<sup>1</sup> Denise M Malicki,<sup>2</sup> Michael L Levy,<sup>3</sup> John Ross Crawford<sup>4</sup>

<sup>1</sup>School of Medicine, UC San Diego, La Jolla, California, USA  
<sup>2</sup>Department of Pathology, Rady Children's Hospital University of California San Diego, San Diego, California, USA

<sup>3</sup>Department of Neurosurgery, University of California San Diego, San Diego, California, USA

<sup>4</sup>Department of Neurosciences and Pediatrics, University of California San Diego, San Diego, California, USA

**Correspondence to**  
 Dr John Ross Crawford,  
 jrcrawford@ucsd.edu

Accepted 17 December 2018

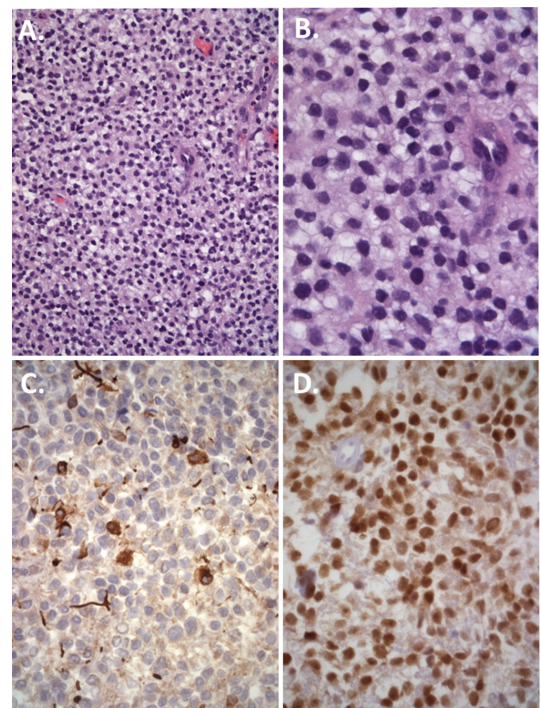
## SUMMARY

We present the case of a 13-year-old boy with a very unusual periventricular atypical central neurocytoma with unique molecular features treated with subtotal surgical resection and photon intensity-modulated radiotherapy. Histological features were most consistent with atypical central neurocytoma. However, next-generation sequencing analysis revealed a novel EWSR1-ATF1 gene fusion (EWSR1-ATF1) as well as a MUTYH mutation. The EWSR1-ATF1 raised the possibility of Ewing sarcoma or angiomatoid fibrous histiocytoma, however, FLI-1 immunohistochemistry was negative. MUTYH mutations have been reported in diffuse midline paediatric glioma. The role of EWSR1-ATF1 and MUTYH mutations in central nervous system tumours is not well established. We present the first case of EWSR1-ATF1 and MUTYH mutation in a rare paediatric atypical central neurocytoma. Further studies are indicated to elucidate the consequences of these gene alterations in the context of paediatric central nervous system tumours as well as to investigate the potential role for targeted therapies.

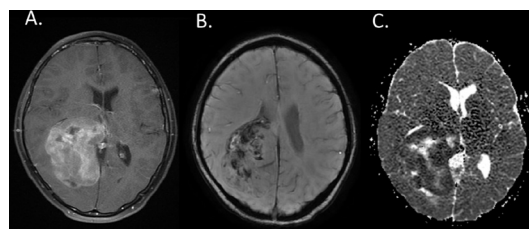
## BACKGROUND

Central neurocytomas are rare WHO grade II tumours of the central nervous system typically located in the ventricles and are associated with favourable outcome.<sup>1</sup> Atypical neurocytomas are more aggressive, with features of focal necrosis, vascular proliferation and increased mitotic activity associated with worse clinical outcomes.<sup>1</sup>

Atypical neurocytomas are more aggressive, with features of focal necrosis, vascular proliferation and



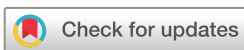**Figure 2** Histopathology reveals sheet-like proliferation of polygonal cells with mildly pleomorphic nuclei, brisk mitotic activity and pink-fibrillar to clear cytoplasm at low (A) and high power (B). Immunohistochemistry staining was positive for both glial (GFAP) (C) and neuronal (Neu1) (D) markers most consistent with a histopathological diagnosis of atypical central neurocytoma.



**Figure 1** T1-weighted axial MRI with contrast at presentation showing a large lobulated enhancing heterogeneous mass centred within the posterior right lateral ventricle and surrounding parenchyma with mass effect and leftward midline shift (A), with features of internal haemorrhage on susceptibility weighted imaging (B), and reduced diffusivity on apparent diffusion coefficient sequences (C).

increased mitotic activity associated with worse clinical outcomes.<sup>1</sup> Molecular genetics of neurocytomas are not yet well characterised, however, studies have shown chromosome 17 deletion and gain of chromosomes 2p, 10q, 18q and 7.<sup>1</sup> Other studies have demonstrated upregulation of genes involved in the Wnt/B-catenin and sonic hedgehog pathways<sup>2</sup> as well as IGF2, N-myc and platelet-derived growth factor.<sup>3</sup> There are currently no therapeutic targets identified to treat neurocytomas.

EWSR1-ATF1 is classically implicated in mesenchymal neoplasms and has not previously been reported in neurocytomas. MUTYH mutations are typically associated with intestinal malignancy syndromes but have been described in paediatric glioma.<sup>4,5</sup> The role of EWSR1-ATF1 and MUTYH mutations in central nervous system tumours is not



© BMJ Publishing Group Limited 2019. No commercial re-use. See rights and permissions. Published by BMJ.

**To cite:** Aghajan Y, Malicki DM, Levy ML, et al. *BMJ Case Rep* 2019;**12**:e226455. doi:10.1136/bcr-2018-226455

## Rare disease

well established. We present the first case of EWSR1-ATF1 and MUTYH mutations in a rare paediatric atypical central neurocytoma. Further studies are indicated to elucidate the consequences of these gene alterations in the context of paediatric central nervous system tumours as well as to investigate the potential for targeted therapies.

### CASE PRESENTATION

A 13-year-old previously healthy boy presented with worsening headaches and vomiting. Neurological examination was notable for left-sided homonymous hemianopsia. MRI of the brain revealed a lobulated enhancing heterogeneous mass within the posterior right lateral ventricle and surrounding parenchyma with midline shift and components of internal haemorrhage, necrosis and reduced diffusivity (figure 1A–C). MRI of the spine revealed no evidence of leptomeningeal metastasis. He underwent subtotal resection where pathology revealed a sheet-like proliferation of polygonal cells with brisk mitotic activity and immunopositivity for both glial and neuronal markers, whose histological features were best classified as an atypical central neurocytoma (figure 2A–D).

### INVESTIGATIONS

Immunohistochemistry was positive for GFAP and NeuN. Negative staining was observed for synaptophysin, EMA, Olig2 and HMB-45. Next-generation sequencing analysis revealed an EWSR1-ATF1 fusion as well as MUTYH G382D mutation. Following molecular diagnosis, Fli-1 immunohistochemistry was performed that revealed absent staining.

### DIFFERENTIAL DIAGNOSIS

The histological differential diagnosis included atypical central neurocytoma, atypical glioneuronal tumour and ependymoma. Based on the EWSR1-ATF1 detected by next-generation sequencing, Ewing's sarcoma, primitive neuroectodermal tumour and angiomatoid fibrous histiocytoma were included in the differential.

### TREATMENT

The patient's family initially declined adjunctive therapies and the 6-month follow-up MRI showed progressive disease. The patient underwent re-resection at the time followed by focal photon intensity-modulated radiotherapy.

### OUTCOME AND FOLLOW-UP

One year postdiagnosis follow-up MRI showed a third local recurrence that was treated with surgery only at the family's request. The patient currently remains stable with no evidence of tumour recurrence 3 years postdiagnosis without evidence of dissemination.

### DISCUSSION

Molecular genetics of neurocytomas are not yet well characterised, however, studies have shown chromosome 17 deletion and gain of chromosomes 2p, 10q, 18q and 7.<sup>1</sup> Other studies have demonstrated upregulation of genes involved in the Wnt/B-catenin and sonic hedgehog pathways<sup>6</sup> as well as IGF2, N-myc and platelet-derived growth factor.<sup>7</sup> There are currently no therapeutic targets identified to treat neurocytomas.

EWSR1 (Ewing sarcoma breakpoint region 1) encodes the RNA-binding protein EWSR1 whose specific function is largely unknown, however, it is thought to play a role in regulating hematopoietic stem cells.<sup>6</sup> The ATF1 gene encodes cyclic AMP-dependent transcription factor ATF1.<sup>7</sup> Fusion of EWSR1-ATF1 has been

implicated in angiomatoid fibrous histiocytoma, clear cell sarcoma, clear cell sarcoma-like tumour of the gastrointestinal tract, primary pulmonary myxoid sarcoma, hyalinising clear cell carcinoma and myoepithelial tumour of soft tissue.<sup>7</sup> EWSR1 mutations are present in <1% of central nervous system tumours (0.13%, COSMIC, July 2017). EWSR1 mutations have not been reported in cerebral neurocytoma to date. Thus, our findings highlight the first reported case of EWSR1-ATF1 in atypical central neurocytoma.

MUTYH encodes a DNA glycosylase involved in base excision repair. Loss of function mutations, such as MUTYH G382D, results in increased mutagenesis and tumourigenesis.<sup>8</sup> MUTYH mutations are classically implicated in familial colorectal cancer syndromes such as familial adenomatous polyposis. They have also been shown to increase the incidence of non-intestinal malignancies such as ovarian, bladder and skin cancers.<sup>8</sup> MUTYH mutations are present in <1% of CNS tumours, most frequently in high-grade gliomas (0.18%, COSMIC, July 2017). Mutations in MUTYH have been reported in midline paediatric glioma.<sup>4,5</sup> The role of MUTYH mutation in the pathogenesis of brain tumours is not well established. We present the first reported case of MUTYH mutation in an atypical central neurocytoma.

### Learning points

- ▶ Atypical central neurocytoma is a rare tumour with no currently identified molecular therapeutic targets.
- ▶ EWSR1-ATF1 gene fusions have been described in Ewing sarcoma and other mesenchymal neoplasms. We highlight the first reported case of EWSR1-ATF1 in atypical central neurocytoma.
- ▶ MUTYH mutations are classically implicated in intestinal malignancies and are uncommon in central nervous system tumours. We present the first reported case of MUTYH mutation in atypical central neurocytoma.
- ▶ Next-generation sequencing of paediatric brain tumours may lead to an expanded differential diagnosis and potential of targeted therapy.

**Contributors** All authors have contributed equally to the design and writing of the manuscript and approve of its contents. YA, DMM, MLL and JRC: responsible for the design, interpretation and writing of the manuscript.

**Funding** The authors have not declared a specific grant for this research from any funding agency in the public, commercial or not-for-profit sectors.

**Competing interests** None declared.

**Patient consent** Obtained.

**Provenance and peer review** Not commissioned; externally peer reviewed.

### REFERENCES

- 1 Sharma MC, Deb P, Sharma S, et al. Neurocytoma: a comprehensive review. *Neurosurg Rev* 2006;29:270–85.
- 2 Vasiljevic A, Champier J, Figarella-Branger D, et al. Molecular characterization of central neurocytomas: potential markers for tumor typing and progression. *Neuropathology* 2013;33:149–61.
- 3 Bonney PA, Boettcher LB, Krysiak RS, et al. Histology and molecular aspects of central neurocytoma. *Neurosurg Clin N Am* 2015;26:21–9.
- 4 Kline CN, Joseph NM, Grenert JP, et al. Inactivating MUTYH germline mutations in pediatric patients with high-grade midline gliomas. *Neuro Oncol* 2016;18:752–3.
- 5 Aghajan Y, Levy ML, Newbury RO, et al. Disseminated pilomyxoid astrocytoma in infancy with novel MUTYH mutation. *BMJ Case Rep* 2016;2016:bcr2016217764.
- 6 Cho J, Shen H, Yu H, et al. Ewing sarcoma gene Ews regulates hematopoietic stem cell senescence. *Blood* 2011;117:1156–66.
- 7 Thway K, Fisher C. Tumors With EWSR1-CREB1 and EWSR1-ATF1 Fusions. *Am J Surg Pathol* 2012;36:e1–11.
- 8 Mazzei F, Viel A, Bignami M. Role of MUTYH in human cancer. *Mutat Res* 2013;743-744:33–43.

Copyright 2018 BMJ Publishing Group. All rights reserved. For permission to reuse any of this content visit <https://www.bmj.com/company/products-services/rights-and-licensing/permissions/>  
BMJ Case Report Fellows may re-use this article for personal use and teaching without any further permission.

Become a Fellow of BMJ Case Reports today and you can:

- ▶ Submit as many cases as you like
- ▶ Enjoy fast sympathetic peer review and rapid publication of accepted articles
- ▶ Access all the published articles
- ▶ Re-use any of the published material for personal use and teaching without further permission

For information on Institutional Fellowships contact [consortiasales@bmjgroup.com](mailto:consortiasales@bmjgroup.com)

Visit [casereports.bmj.com](http://casereports.bmj.com) for more articles like this and to become a Fellow