

UCSF

UC San Francisco Previously Published Works

Title

Sulcus-Deepening Trochleoplasty as an Isolated or Combined Treatment Strategy for Patellar Instability and Trochlear Dysplasia: A Systematic Review.

Permalink

<https://escholarship.org/uc/item/4vg204q7>

Journal

Arthroscopy, sports medicine, and rehabilitation, 2(5)

ISSN

2666-061X

Authors

Davies, Michael Robert
Allahabadi, Sachin
Diab, Tarek Elliott
et al.

Publication Date

2020-10-01

DOI

10.1016/j.asmr.2020.06.009

Peer reviewed

Sulcus-Deepening Trochleoplasty as an Isolated or Combined Treatment Strategy for Patellar Instability and Trochlear Dysplasia: A Systematic Review



Michael Robert Davies, M.D., Sachin Allahabadi, M.D., Tarek Elliott Diab, Ryan David Freshman, M.D., Nirav Kiritkumar Pandya, M.D., Brian Thomas Feeley, M.D., and Drew Anderson Lansdown, M.D.

Purpose: To highlight the indications and outcomes for sulcus-deepening trochleoplasty, when used as an isolated procedure as well as in combination with other stabilization techniques for patellar instability. **Methods:** We performed a systematic review focused on outcomes and complications following trochleoplasty performed either as an isolated procedure or in combination with other procedures to address patellar instability. Inclusion criteria included studies in English that reported on outcomes following primary open trochleoplasty, including Kujala scores and recurrent instability or dislocation events. **Results:** Twelve papers including 702 patients who underwent sulcus-deepening trochleoplasty were included. A total of 504 patients underwent isolated sulcus-deepening trochleoplasty, whereas 198 patients underwent trochleoplasty in combination with 1 or more additional stabilization procedures. In total, 67% of patients were female compared with 33% male. The procedure was done as a primary surgical intervention 74% of the time. Postoperative Kujala scores for isolated trochleoplasty ranged from 80 to 92, whereas those for combined stabilization procedures ranged from 76 to 95. The dislocation rate among the studies ranged from 0 to 8%. There was a persistent J-sign in 0 to 12% of treated knees among all studies, and a persistent apprehension test in 0 to 29% of treated knees. Return to play ranged from 65% to 83% in studies in which this was reported as an outcome. **Conclusions:** Sulcus-deepening trochleoplasty performed for recurrent patellar instability in the setting of trochlear dysplasia results in improved Kujala scores and a low redislocation rate, when performed as an isolated procedure or in combination with other stabilization procedures. Greater-level evidence is needed to better evaluate the overall efficacy of this procedure in addressing patellar instability. **Level of Evidence:** Level of Evidence, IV; Systematic review of level III and IV studies

Patellar instability, a debilitating condition that affects approximately 6 of 100,000 individuals in the United States, has several anatomic etiologies, including medial patellofemoral ligament (MPFL) complex incompetence, trochlear dysplasia, an excessively externally rotated or proximally located tibial tuberosity, insufficiency of the vastus medialis obliquus and quadriceps musculature, and excessive internal rotation of the femur.¹ Diverse procedures exist to address these

differing etiologies, including repair or reconstruction of the MPFL, trochleoplasty, tibial tubercle osteotomy, and femoral osteotomy. The successful treatment of patellar instability continues to be a challenge, given the multiple etiologies that may be responsible for the pathology. Although MPFL reconstruction and tibial tubercle osteotomies are common approaches for patellar stabilization, trochlear dysplasia continues to be a risk factor for poor surgical outcomes in many series.²⁻⁶

From the Department of Orthopaedic Surgery, University of California San Francisco, San Francisco, California, U.S.A.

The authors report the following potential conflicts of interest or sources of funding: N.K.P. reports consultant for Orthopediatrics. B.T.F. reports Editorial Board: Journal of Shoulder Elbow Surgery and Current Reviews in Musculoskeletal Medicine and stock/options in Kaliber. D.A.L. reports grants from the Arthroscopy Association of North America and American Orthopedic Society of Sports Medicine and research/education support from Arthrex, Smith & Nephew; and Wright Medical/Tornier. Full ICMJE author disclosure forms are available for this article online, as [supplementary material](#).

Received December 27, 2019; accepted June 21, 2020.

Address correspondence to Drew Anderson Lansdown, M.D., San Francisco Orthopaedic Institute, University of California, 1500 Owens St., San Francisco, CA 94158. E-mail: Drew.Lansdown@ucsf.edu

© 2020 by the Arthroscopy Association of North America. Published by Elsevier Inc. This is an open access article under the CC BY-NC-ND license (<http://creativecommons.org/licenses/by-nc-nd/4.0/>).

2666-061X/191576

<https://doi.org/10.1016/j.asmr.2020.06.009>

Trochlear dysplasia is defined functionally as shallowness of the trochlea that may predispose to patellar maltracking and instability with knee flexion.^{5,6} It has been reported to be present in more than 80% of patients with patellar instability.⁵ The following 4 anatomic variations based on radiographic evaluation of a lateral view of the knee have been described: presence of a crossing sign, which is present when the contour of the trochlear floor intersects with or protrudes anterior to the contour of the lateral femoral condyle (type A); a crossing sign with a supratrochlear spur (type B); a crossing sign with a double-contour sign reflecting a hypoplastic medial femoral condyle (type C); and absence of the trochlea, when all three signs are present (type D).⁵⁻⁷ In addition, on the Merchant view the sulcus angle can be calculated: an angle greater than 145° is defined as dysplastic.^{6,8} Despite the high prevalence of trochlear dysplasia in patients with patellar instability, the surgical treatment of trochlear dysplasia with a trochleoplasty has been rarely used due to the highly technical nature of the procedure and some concern for disruption of the articular cartilage.⁹

There are 3 principal types of trochleoplasty: lateral facet elevation, sulcus deepening, and recession wedge, which are often performed in combination with bony or soft-tissue corrective procedures.^{2-4,6,9-12} The modern sulcus-deepening technique was described by Dejour in 1987 and additionally modified by Bereiter and Gautier in 1994.^{2,13-16} Dejour et al. suggested that the sulcus-deepening procedure may be most appropriate for type B and type D dysplasia, whereas type C dysplasia may be more amenable to the lateral facet-elevating technique.^{2,5,7} In the modified sulcus-deepening procedure described by Bereiter and Gautier, a cartilage “flake” is elevated in the trochlear groove and a burr or straight osteotome is used to remove the underlying bone to effectively deepen the trochlear groove, after which the cartilage flake is replaced and secured such that it plastically conforms over the contour of the deepened groove.^{2,3,9,16} More recently, a variation of this approach has been described in which a thick osteochondral flap is elevated rather than a thin cartilage flake.¹⁴

A sulcus-deepening technique is the most common form of trochleoplasty performed.⁹ Compared with other patellar-stabilization techniques such as MPFL reconstruction and tibial tubercle transfer, less evidence is available regarding trochleoplasty. The purpose of this systematic review is to highlight the indications and outcomes for sulcus-deepening trochleoplasty, when used as an isolated procedure as well as in combination with other stabilization techniques for patellar instability. Given the high prevalence of trochlear dysplasia among individuals with recurrent patellar instability, we hypothesize that trochleoplasty alone or in combination with additional bony or soft-tissue techniques will prove an effective

method for reducing the occurrence of patellar instability and improving patient-reported outcomes.

Methods

A systematic review and meta-analysis were performed according to PRISMA (Preferred Reporting Items for Systematic Reviews and Meta-Analyses) guidelines.

Study Eligibility

Inclusion criteria were studies in the English language (levels of evidence 1-4) that evaluated standardized patient-reported outcome measures as well as recurrent dislocation or instability following trochleoplasty as a surgical treatment for patellar instability and/or trochlear dysplasia. Surgical treatment was set to include sulcus-deepening trochleoplasty as either an isolated or combined procedure used in treatment. Exclusion criteria included reviews of the literature, expert opinions, nonclinical studies, isolated case reports, and clinical series that did not involve commonly used, validated outcomes scoring systems or report on clinical and/or functional patient outcome measures.

Literature Search

An electronic search was performed in MEDLINE via PubMed and Embase. The search included the key words “trochleoplasty” OR “trochlear dysplasia.” The final search was performed on March 20, 2020.

Study Selection and Data Abstraction

Three authors (M.R.D., T.E.D., R.D.F.) independently selected relevant articles based on title from the search results. The abstracts of all titles chosen by any one of the authors were then analyzed and data were recorded in spreadsheet format.

Risk of Bias Assessment

Study bias was analyzed using the Methodological Index for Non-Randomized Studies (MINORS) criteria, a validated instrument of assessment of non-randomized studies, by 2 independent reviewers (M.R.D., S.A.).¹⁷

Data Analysis

Data extraction followed a standardized protocol developed before the search. The pertinent characteristics of each study were collected, including study design, year of publication, patient number, and level of evidence, as well as the characteristics of study participants (age, sex, primary vs revision surgery). Treatment technique was recorded, specifying the type of sulcus-deepening trochleoplasty performed, and primary clinical outcome measures including Kujala score and re-dislocation rate. Markers of clinical (physical examination findings and return-to-sport) and radiologic

Table 1. Studies Meeting Inclusion Criteria

Study Title	First Author	Year	LOE	MINORS Score ¹⁷
Combined Trochleoplasty and Medial Patellofemoral Ligament Reconstruction for Recurrent Patellar Dislocations in Severe Trochlear Dysplasia ¹⁸	Nelitz	2013	III	8
Trochleoplasty as a Solitary Treatment for Recurrent Patellar Dislocation Results in Good Clinical Outcome in Adolescents ¹⁹	Camathias	2016	IV	8
Sulcus Deepening Trochleoplasty for Patellofemoral Instability: A Series of 34 Cases After 15 Years Postoperative Follow-up ²⁰	Rouanet	2015	IV	8
A Prospective Evaluation of Trochleoplasty for the Treatment of Patellofemoral Dislocation and Instability ²¹	Utting	2008	IV	12
Trochleoplasty for Recurrent Patellar Dislocation in Association With Trochlear Dysplasia. A 4- to 14-Year Follow-Up Study ¹⁴	Von Knoch	2006	IV	10
Trochleoplasty for Patellar Instability due to Trochlear Dysplasia: A Minimum 2-Year Clinical and Radiological Follow-Up of 19 Knees ²²	Schöttle	2005	IV	8
Midterm Results of Comprehensive Surgical Reconstruction Including Sulcus-Deepening Trochleoplasty in Recurrent Patellar Dislocations With High-Grade Trochlear Dysplasia ²³	Ntangiopoulos	2013	IV	8
No Growth Disturbance After Trochleoplasty for Recurrent Patellar Dislocation in Adolescents With Open Growth Plates ²⁴	Nelitz	2018	IV	8
Trochleoplasty With a Flexible Osteochondral Flap: Results From an 11-Year Series Of 214 Cases ²⁵	Metcalfe	2017	IV	8
Trochleoplasty Is a Viable Option for Patellar Instability in Patients With Severe Trochlear Dysplasia: Early Outcomes Analysis of the U.S. Experience ²⁶	Diduch	2017	IV	10
Classification of Trochlear Dysplasia as Predictor of Clinical Outcome After Trochleoplasty ²⁷	Fucentese	2011	III	11
Thick-Osteochondral Flap Deepening Trochleoplasty for Patellar Instability ²⁸	Donel	2016	IV	12

LOE, level of evidence; MINORS, Methodological Index for Non-Randomized Studies.

outcomes were also documented, in addition to complications. Given the heterogeneity of outcomes and low level of available evidence on this subject (Table 1), a formal meta-analysis could not be performed, although results of isolated trochleoplasty compared with trochleoplasty as part of a combined stabilization procedure were considered qualitatively. Redislocation rate following surgery was recorded, and the Kujala score was the most frequently reported clinical outcome measure.

Results

Using the study-acquisition algorithm detailed in Figure 1, we identified 888 studies related to the keywords “trochleoplasty” OR “trochlear dysplasia” and narrowed our search to 12 studies related to sulcus-deepening trochleoplasty and its impact on patient-reported outcomes and patellar instability, as well as complications encountered^{14,18-28} (Table 1). Final studies were selected based on inclusion of all or most of the following metrics: (1) use of standardized patient-reported outcome scores such as the Kujala score, (2) inclusion of dislocation rates as an outcome measure, (3) inclusion of clinical outcome measures such as presence of a J-sign or positive apprehension test, and (4) inclusion of any relevant complications related to the procedure. All studies had lower quality assessment as per MINORS criteria, with each study being non-comparative with a score <16 (Table 1).¹⁷ All included studies were either Level III or Level IV evidence (Table 1). Among the 12 studies included, there were 702 cases of trochleoplasty performed on

639 patients, 67% of whom were female (Table 2). Trochleoplasty was performed as a first-time surgical intervention in 74% of cases and was an isolated stabilization intervention in 33.9% of cases.

As the Kujala scoring questionnaire was the most widely used patient-reported clinical outcomes measure across studies, it was considered qualitatively between trochleoplasty that was performed as an isolated intervention and trocheoplasty as part of a combined stabilization procedure. Mean Kujala scores ranged from 81 to 92 postoperatively in the isolated trochleoplasty group and 76 to 95 in the combined group. Recurrent

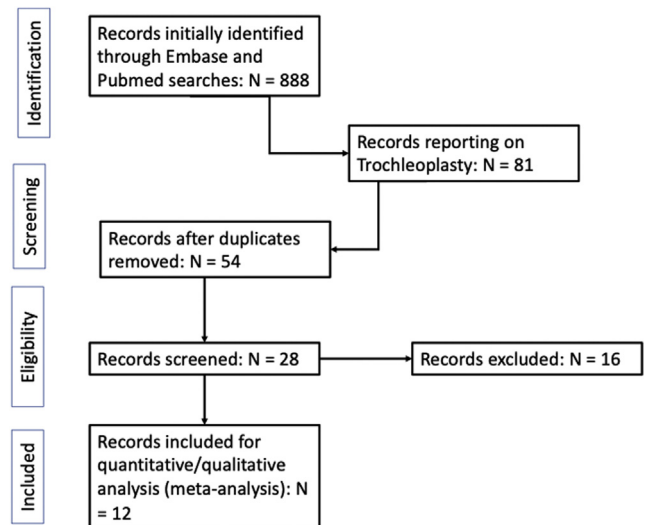


Fig 1. Study acquisition flowchart demonstrating the algorithm to reach the 12 studies ultimately included.

Table 2. Demographic Baseline Data Including Sex, Preoperative Dislocations, and Type (Primary Versus Revision) of Procedure

Study	Patients (Knees)	Sex	Dislocations Before Surgery	Primary vs Revision Stabilization Procedure
Nelitz et al., 2013 ¹⁸	23 (26)	M: 10 F: 16	>2	26/26 primary
Camathias et al., 2016 ¹⁹	44 (50)	M: 20 F: 30	Recurrent dislocations not responding to nonoperative treatment for 6 mo	50/50 primary
Rouanet et al., 2015 ²⁰	34	M: 10 F: 24	Average of 6 dislocations per patient preoperatively	21/34 primary; 13/34 revision
Utting et al., 2008 ²¹	54 (59)	M: 15 F: 44	Unspecified	43/59 primary, 16/59 revision
Von Knoch et al., 2006 ¹⁴	38 (45)	M: 22 F: 16	Unspecified	30/45 primary, 15/45 revision
Schöttle et al., 2005 ²²	19	M: 4 F: 15	≥2 dislocations, or 1 + persistent apprehension sign	14/19 primary, 5/19 revision
Ntagiopoulos et al., 2013 ²³	27 (31)	M: 14 F: 13	>3 dislocations	Not stated
Nelitz et al., 2018 ²⁴	18 (18)	M: 6 F: 12	>2	12/12 primary
Metcalfe et al., 2017 ²⁵	185 (214)	M: 52 F: 133	Unspecified	154/214 primary, 60 revision
Diduch et al., 2017 ²⁶	43 (49)	M: 10 F: 39	Unspecified	26/49 primary, 23/49 revision
Fucentese et al., 2011 ²⁷	38 (44)	M: 11 F: 33	>2 dislocations, or 1 with persistent apprehension	31/44 primary, 13/44 revision
Donel et al., 2016 ²⁸	90 (107)	M: 36 F: 54	>1 dislocation, failed conservative management or prior surgery	64/107 primary surgery, 43/107 revision

F, female; M, male.

dislocation was an overall rare occurrence, ranging from 0 to 8%. No recurrent dislocations were reported in 7 of the studies reviewed (N = 218 total knees).^{14,18,20,22-24,26} Three studies reported a single recurrent dislocation.^{19,21,27} Metcalfe et al.²⁵ reported a total of 16 recurrent dislocation events of 199 cases (8%) in the largest case series included (Table 3).

Among the most common clinical metrics for persistent instability following trochleoplasty were presence of a J-sign or a positive apprehension test. Following surgery, 0 to 12% of patients had a persistent J-sign, and 0 to 29% exhibited a positive apprehension test (Table 4). Among studies that reported return to sport metrics, there was a return to play rate that ranged from 65% to 83%.^{18,21,25,26} Among the most frequently documented radiographic metrics was the progression of radiographic arthritis following trochleoplasty (Table 4). The presence of at least mild radiographic arthritis was documented in up to 97% of patients over 15 years after surgery by Rouanet et al.,²⁰ whereas Metcalfe et al.²⁵ documented approximately 3% of cases that showed radiographic progression to arthritis. Von Knoch et al.¹⁴ and Schöttle et al.²² additionally assessed for the presence of a “crossing sign” as a radiographic indication of persistent trochlear dysplasia following surgery and found it to be present in 2 of 45 patients and 3 of 19 patients, respectively.

Reported complications were relatively infrequent across studies, with the most prevalent being persistent

knee stiffness or loss of flexion after surgery (Table 5). Diduch et al.²⁶ reported an arthrofibrosis rate of 18% requiring manipulation under anesthesia in their series of 49 cases. Rouanet et al.²⁰ reported stiffness limiting flexion to less than 90° in 8 of 34 patients (24%). In addition, over the 15-year follow-up period, 6 of 34 knees were revised to either a patellofemoral or total knee arthroplasty, and 1 of 34 underwent revision by tibial tubercle osteotomy given persistent instability.²⁰ Nelitz et al.²⁴ in 2018 reported that 4 of 18 patients had either reduced flexion requiring further rehabilitation, adhesions requiring repeated arthroscopy, or a persistent flexion contracture of up to 5° at final follow-up. Wound-related complications were rare, reported in 2 of 59 cases by Utting et al.²¹ and 1 of 44 cases in Fucentese et al.²⁷

Discussion

Overall, Kujala scores increased postoperatively compared with preoperatively in cases in which trochleoplasty was performed as an isolated or combined procedure. A 2019 case series of 211 isolated MPFL reconstructions reported an average Kujala score of 88.8 postoperatively.²⁹ Similarly, a 2018 case series by Liu et al.³⁰ of anteromedialization tibial tubercle osteotomy in 48 patients found average postoperative Kujala scores of 82.6. Thus, it appears that on average, Kujala scores for either isolated trochleoplasty or combined stabilization surgery involving trochleoplasty are similar to previously reported scores for other

Table 3. Primary Outcomes Including Type of Procedure (Isolated Trochleoplasty Versus Combined Procedure), Kujala Scores, and Redislocation Rates

Study	No. Isolated Trochleoplasty	No. Combined Procedures	Kujala (Isolated)	Kujala (Combined)	Redislocation (Isolated)	Redislocation (Combined)	Mean Follow-up Length, y
Nelitz et al., 2013 ¹⁸	0/26	26/26	—	79 preoperative 90 follow-up Diff = 11	—	0/26 (0%)	2.5
Camathias et al., 2016 ¹⁹	50/50	0/50	71 preoperative 92 postoperative Diff = 21	—	1/50 (2%)	—	2.75
Rouanet et al., 2015 ²⁰	17/34	17/34	—	81 postoperative	—	0/34 (0%)	7
Utting et al., 2008 ²¹	32/59	27/59	—	62 preoperative 76 postoperative Diff = 14	—	1/59 (1.7%)	2
Von Knoch et al., 2006 ¹⁴	0/45	45/45	—	94.9	—	0/45 (0%)	8.3
Schöttle et al., 2005 ²²	19/19	0/19	56 preoperative 80 postoperative Diff = 24	—	0/19 (0%)	—	3
Ntagiopoulos et al., 2013 ²³	0/27	27/27	—	59 preoperative 87 postoperative Diff = 28	—	0/27 (0%)	7
Nelitz et al., 2018 ²⁴	0/18	18/18	—	67 preoperative 89.5 postoperative Diff = 22.5	—	0/18 (0%)	2.3
Metcalfe et al., 2017 ²⁵	36/224	188/224	—	51.5 preoperative 82.5 postoperative Diff = 31	—	16/199 (8.0%)	4.43
Diduch et al., 2017 ²⁶	0/49	49/49	—	54.5 preoperative 82.5 postoperative Diff = 28	—	0/49 (0%)	0.88
Fucntese et al., 2011 ²⁷	44/44	0/44	68 preoperative 90 postoperative Diff = 22	—	1/44 (2.2%)	—	4 (median)
Donel et al., 2016 ²⁸	40/107	67/107	—	63 preoperative 79 postoperative Diff = 16	—	—	6

Diff, difference; pre, preoperative; post, postoperative.

well-established stabilization techniques. Among the studies included in this review, more than one half of cases involved an isolated sulcus-deepening technique without other concurrent stabilization procedures, and surgery was more frequently performed as a primary surgical intervention than a revision surgery.

The shared purpose of trochleoplasty, MPFL reconstruction, and tibial tubercle osteotomy is to prevent redislocation of the patella and treat persistent instability. Thus, one important focus of this review was to assess redislocation rates, in addition to persistence of clinical instability as evidenced by the J-sign and positive apprehension test. We found that, overall, there was a low dislocation rate among all cases involving trochleoplasty as either an isolated or combined procedure, ranging from 0 to 8%. In addition, we found that the persistence of a J-sign after surgery was a relatively rare occurrence, ranging from 0 to 12%, whereas a positive patellofemoral apprehension test was more common postoperatively, ranging from 0 to

29%. One perceived benefit of trochleoplasty compared with other stabilization techniques is that it directly addresses the bony deformity involved in trochlear dysplasia that contributes to instability. However, a recent case series by Liu et al.³¹ of 121 isolated MPFL reconstructions performed in patients with Dejour B, C, or D trochlear dysplasia demonstrated mean Kujala scores of 90 and a total of 3 of 121 redislocations over an average follow-up of 44 months. Thus, even in patients with trochlear dysplasia, soft-tissue procedures may prove to be effective in improving clinical outcomes and preventing redislocation with appropriate patient selection.

A topic of recent interest is the use of trochleoplasty as an isolated versus combined procedure in addressing patellar instability. Ren et al.³² performed a systematic review of 192 cases comparing isolated trochleoplasty to that performed in conjunction with MPFL reconstruction, and found a significantly lower redislocation rate with the combined procedure.

Table 4. Clinical (Including Physical Examination and Return to Sport) and Radiologic Outcomes

Study	Persistent J Sign	Persistent Apprehension	Return to Sport	Radiological Parameters
Nelitz et al., 2013 ¹⁸	0/26 (0%)	—	1 returned to higher level, 16 to same level, 6 to lower level 17/26 (65.4%) resumed same level or higher	—
Camathias et al., 2016 ¹⁹	6/50 (12%)	8/50 (16%)	—	—
Rouanet et al., 2015 ²⁰	—	10/34 (29.4%)	—	97% with mild radiographic arthritis over 15 years
Utting et al., 2008 ²¹	—	—	36/54 (66.7%) returned to sport	—
Von Knoch et al., 2006 ¹⁴	—	—	—	2/45 positive crossing sign
Schöttle et al., 2005 ²²	—	4/19 (21.0%)	—	3/19 positive crossing sign (grade I)
Ntagiopoulos et al., 2013 ²³	0/31 (0%)	6/31 (19.4%)	—	—
Nelitz et al., 2018 ²⁴	1/18 (5.5%)	3/18 (16.7%)	—	—
Metcalfe et al., 2017 ²⁵	—	—	145/173 (83.4%) resumed sport/activity	6/199 radiographic OA
Diduch et al., 2017 ²⁶	0/49 (0%)	0/49 (0%)	35/43 (81.4%) returned to sport	Sulcus angle 144 to 133 postoperatively
Fucentese et al., 2011 ²⁷	—	11/44 (25%)	—	16/44 with radiographic deterioration to OA
Donel et al., 2016 ²⁸	—	—	—	—

OA, osteoarthritis.

Balcarek et al.³³ further performed a meta-analysis comparing isolated MPFL reconstruction to MPFL reconstruction performed with trochleoplasty and similarly found that the combined procedure dislocation rate was significantly lower at 2.1% compared with 7% in the isolated MPFL group. The study by Metcalfe et al.²⁵ included in this review is the largest case series of sulcus-deepening trochleoplasty performed to date, of which the majority of surgeries were performed as combined procedures involving trochleoplasty and a soft-tissue balancing procedure. Of note, this study also reported the highest redislocation rate postoperatively, at 8%.²⁵ Nine of 16 of the redislocations occurred in the first half of the surgeries performed, and the remainder in the second half, suggestive that the effect of a technical learning curve, if present, is minimal according to the authors.²⁵

Among the studies included, the most common indication for including trochleoplasty in a surgical intervention was recurrent patellar instability, frequently defined as greater than 2 dislocation events, or a single dislocation event with a persistent apprehension sign on examination. Additionally, most studies considered the radiographic presence of Dejour trochlear dysplasia in the setting of recurrent dislocations as an indication for trochleoplasty. A consideration against performing trochleoplasty as an isolated stabilization procedure is the risk of arthrofibrosis and decreased post-operative range of motion, as well as the risk of radiographic progression of patellofemoral arthritis that it carries.^{18-21,24,26,34} Although dislocation rates with trochleoplasty may be similar to other stabilization procedures such as MPFL reconstruction, the risk of limited range-of-motion and flexion contracture post-operatively may be more

prevalent with trochleoplasty. Song et al.³⁵ performed a systematic review of trochleoplasty compared with non-trochleoplasty procedures in 2014 and found that there was a lower patellar redislocation rate in procedures involving trochleoplasty as well as a lower percentage of radiographic patellofemoral osteoarthritis (Iwano grade 2 or greater) compared with nontrochleoplasty procedures; however, there was an inferior outcome with respect to range of motion at follow-up. In the present review, however, radiographic progression of arthritis was a commonly cited outcome after trochleoplasty, with Rouanet et al.²⁰ noting 97% of patients having developed some degree of patellofemoral arthritis over the 15-year follow-up period, the longest follow-up period included in this review.

Given the risk of postoperative stiffness following trochleoplasty, postoperative rehabilitation protocols must balance protection of bony healing with adequate range of motion. While specific descriptions of rehabilitation protocols were not consistently included in the studies analyzed, Carstensen al.³⁶ published a recent case series on postoperative arthrofibrosis following trochleoplasty, in which patients began physical therapy three days after their index procedure. During the first 2 weeks after surgery, patients were kept 50% weight-bearing, after which time they were advanced to full weightbearing. Flexion was limited 0° to 70° for weeks 1 and 2 postoperatively, then advanced to 90° of flexion for weeks 3 and 4, before being advanced to full range of motion.³⁶ Even with the early initiation of this protocol, 11 of 62 knees developed arthrofibrosis and underwent manipulation under anesthesia within 3 months of the index procedure, with 9 of these patients subsequently requiring arthroscopic lysis of adhesion. Following

Table 5. Reported Complications

Study	Complications Reported
Nelitz et al. 2013 ¹⁸	<ul style="list-style-type: none"> • Prolonged rehab >6 weeks to regain full flexion: 1/26 knees (3.8%)
Camathias et al. 2016 ¹⁹	<ul style="list-style-type: none"> • Reoperation for arthroscopic lysis of adhesions: 4/50 (8%) • Redirection: 1/50 (2%)
Rouanet et al. 2015 ²⁰	<ul style="list-style-type: none"> • Postoperative stiffness: 8/34 (23.5%) • Manipulation under anesthesia: 6/34 (17.6%) • Revision to knee arthroplasty over 15-year follow-up: 6/34 (17.6%) • Tibial tubercle osteotomy for persistent pain/instability: 1/34 (2.9%)
Utting et al. 2008 ²¹	<ul style="list-style-type: none"> • Superficial wound infection: 2/59 (3.4%) • Redirection: 1/59 (1.7%) • Manipulation under anesthesia: 1/59 (1.7%) • Anaphylactic reaction to intraoperative antibiotic: 1/59 (1.7%)
Von Knoch et al. 2006 ¹⁴	<ul style="list-style-type: none"> • Patella baja: 1/45 (2.2%) • Persistent subluxation requiring distal realignment osteotomy: 1/45 (2.2%)
Schöttle et al. 2005 ²²	<ul style="list-style-type: none"> • No complications explicitly reported for 19/19 knees (0%)
Ntagiopoulos et al. 2013 ²³	<ul style="list-style-type: none"> • Staple breakage, removed arthroscopically: 2/31 (6.5%) • Deep venous thrombosis, treated with anticoagulation: 2/31 (6.5%)
Nelitz et al. 2018 ²⁴	<ul style="list-style-type: none"> • Flexion contracture up to 5°: 2/18 (11.1%) • Reduced flexion treated with intense rehabilitation: 1/18 (5.6%) • Reoperation for arthroscopic lysis of adhesions: 1/18 (5.6%)
Metcalf et al. 2017 ²⁵	<ul style="list-style-type: none"> • Reoperation: 27/224 (12.1%) • Partial detachment of cartilage flap, treated with debridement and microfracture at 6 weeks postoperatively: 1/224 (0.45%) • Complex regional pain syndrome: 1/224 (0.45%) • Foot drop despite normal MRI/nerve conduction studies: 1/224 (0.45%)
Diduch et al. 2017 ²⁶	<ul style="list-style-type: none"> • Arthrofibrosis requiring manipulation under anesthesia: 9/49 (18.4%)
Fucentese et al. 2011 ²⁷	<ul style="list-style-type: none"> • Repeat arthroscopy for ongoing pain: 3/44 (6.8%) • Residual instability requiring further stabilization procedures: 2/44 (4.5%) • New atraumatic dislocation postoperatively: 1/44 (2.3%) • Loose body removal: 1/44 (2.3%) • Transient postoperative femoral nerve palsy: 1/44 (2.3%) • Wound-healing complication: 1/44 (2.3%) • Postoperative complex regional pain syndrome: 1/44 (2.3%)
Donel et al. 2016 ²⁸	<ul style="list-style-type: none"> • No complications reported (0%)

MRI, magnetic resonance imaging.

these interventions, there was no significant difference in range of motion between the arthrofibrotic and non-arthrofibrotic knees at final mean follow-up of 32.5 months.³⁶

Patellofemoral instability is multifaceted in its underlying pathogenesis compared with many orthopaedic conditions, and thus it deserves an individualized

treatment approach that carefully takes into account the pathoanatomy and biomechanics that result in an individual's recurrent patellar dislocations. Based on the present data, we would recommend cautious consideration of trochleoplasty as part of an individualized, combination approach to patellar stabilization in patients with refractory instability and evident trochlear dysplasia, for whom an isolated soft-tissue procedure such as MPFL reconstruction may not fully address their underlying pathoanatomy resulting in instability.

Limitations

This review has several limitations. Trochleoplasty as a treatment for patellofemoral instability is relatively sparse compared with other more common stabilization techniques such as MPFL reconstruction and tibial tubercle osteotomy, and thus the studies included were all nonrandomized case series. Due to the relative lack of higher-level studies currently available and inconsistent data reporting, a meta-analysis could not be performed, and weighted averages of outcome measures could not be presented due to the risk of introducing bias. Given the nonrandomized nature of the cases included in the review, it is not possible to control for all variables that may contribute to the outcomes reported. There is also heterogeneity in the surgical technique in sulcus-deepening trochleoplasty between studies, with differences in the shape of the bony resection between the techniques described by Masse, Dejour et al., and Bereiter and Gautier, as well as variations in the use of a thin cartilage flake compared with a thick osteochondral flap.^{2,5,7,12,13,15,16} Studies frequently lacked detail regarding individual patient pathology that resulted in treatment with trochleoplasty with or without other stabilization procedures, so the specific indications for trochleoplasty remain difficult to elucidate given the available data. In addition, given the highly technical nature of trochleoplasty, which frequently necessitates a specialized center and expert, high-volume surgeon, the results reported by the studies included may not reflect those of the community-at-large. Overall, however, this review represents a large collection of consistently reported data that help give a broader view of the patient-reported and clinical outcomes and complications of sulcus-deepening trochleoplasty.

Conclusions

Sulcus-deepening trochleoplasty performed for recurrent patellar instability in the setting of trochlear dysplasia results in improved Kujala scores and a low redirection rate, when performed as an isolated procedure or in combination with other stabilization procedures. Greater-level evidence is needed to better evaluate the overall efficacy of this procedure in addressing patellar instability.

References

- Fisher B, Nyland J, Brand E, Curtin B. Medial patellofemoral ligament reconstruction for recurrent patellar dislocation: A systematic review including rehabilitation and return-to-sports efficacy. *Arthroscopy* 2010;26:1384-1394.
- Dejour D, Saggin P. The sulcus deepening trochleoplasty—the Lyon’s procedure. *Int Orthop* 2010;34:311-316.
- Nolan JE, Schottel PC, Endres NK. Trochleoplasty: Indications and technique. *Curr Rev Musculoskelet Med* 2018;11:231-240.
- Albee F. The bone graft wedge in the treatment of habitual dislocation of the patella. *Med Rec* 1915;88:257-259.
- Dejour H, Walch G, Nove-Josserand L, Guier C. Factors of patellar instability: An anatomic radiographic study. *Knee Surg Sports Traumatol Arthrosc* 1994;2:19-26.
- LaPrade RF, Cram TR, James EW, Rasmussen MT. Trochlear dysplasia and the role of trochleoplasty. *Clin Sports Med* 2014;33:531-545.
- Dejour D, Le Coultre B. Osteotomies in patello-femoral instabilities. *Sports Med Arthrosc Rev* 2007;15:39-46.
- Malghem J, Maldague B. Depth insufficiency of the proximal trochlear groove on lateral radiographs of the knee: Relation to patellar dislocation. *Radiology* 1989;170:507-510.
- Ntagiopoulos PG, Dejour D. Current concepts on trochleoplasty procedures for the surgical treatment of trochlear dysplasia. *Knee Surg Sports Traumatol Arthrosc* 2014;22:2531-2539.
- Blønd L, Schöttle PB. The arthroscopic deepening trochleoplasty. *Knee Surg Sports Traumatol Arthrosc* 2010;18:480-485.
- Goutallier D, Raou D, Van Driessche S. Retro-trochlear wedge reduction trochleoplasty for the treatment of painful patella syndrome with protruding trochlea. Technical note and early results. *Rev Chir Orthop Reparatrice Appar Mot* 2002;88:678-685 [in French].
- Masse Y. Trochleoplasty. Restoration of the intercondylar groove in subluxations and dislocations of the patella. *Rev Chir Orthop Reparatrice Appar Mot* 1978;64:3-17 [in French].
- Batailler C, Neyret P. Trochlear dysplasia: imaging and treatment options. *EFORT Open Rev* 2018;3:240-247.
- von Knoch F, Böhm T, Bürgi ML, von Knoch M, Bereiter H. Trochleaplasty for recurrent patellar dislocation in association with trochlear dysplasia. A 4- to 14-year follow-up study. *J Bone Joint Surg Br* 2006;88:1331-1335.
- Dejour H, Walch G. Pathologie fémoro-patellaire, 6ème Journée Lyonnaise de Chirurgie du Genou. Lyon: Sauramps Medical, 1987.
- Bereiter H, Gautier E. The trochleaplasty as a surgical therapy of recurrent dislocation of the patella in dysplastic trochlea of the femur. *Arthroscopie* 1994;7:281-286.
- Slim K, Nini E, Forestier D, Kwiatkowski F, Panis Y, Chipponi J. Methodological index for non-randomized studies (minors): Development and validation of a new instrument. *ANZ J Surg* 2003;73:712-716.
- Nelitz M, Dreyhaupt J, Lippacher S. Combined trochleoplasty and medial patellofemoral ligament reconstruction for recurrent patellar dislocations in severe trochlear dysplasia: A minimum 2-year follow-up study. *Am J Sports Med* 2013;41:1005-1012.
- Camathias C, Studer K, Kiapour A, Rutz E, Vavken P. Trochleoplasty as a solitary treatment for recurrent patellar dislocation results in good clinical outcome in adolescents. *Am J Sports Med* 2016;44:2855-2863.
- Rouanet T, Gougeon F, Fayard JM, Rémy F, Migaud H, Pasquier G. Sulcus deepening trochleoplasty for patellofemoral instability: A series of 34 cases after 15 years postoperative follow-up. *Orthop Traumatol Surg Res* 2015;101:443-447.
- Utting MR, Mulford JS, Eldridge JD. A prospective evaluation of trochleoplasty for the treatment of patellofemoral dislocation and instability. *J Bone Joint Surg Br* 2008;90:180-185.
- Schöttle PB, Fucentese SF, Pfirrmann C, Bereiter H, Romero J. Trochleaplasty for patellar instability due to trochlear dysplasia: A minimum 2-year clinical and radiological follow-up of 19 knees. *Acta Orthop* 2005;76:693-698.
- Ntagiopoulos PG, Byn P, Dejour D. Midterm results of comprehensive surgical reconstruction including sulcus-deepening trochleoplasty in recurrent patellar dislocations with high-grade trochlear dysplasia. *Am J Sports Med* 2013;41:998-1004.
- Nelitz M, Dreyhaupt J, Williams SRM. No growth disturbance after trochleoplasty for recurrent patellar dislocation in adolescents with open growth plates. *Am J Sports Med* 2018;46:3209-3216.
- Metcalfe AJ, Clark DA, Kemp MA, Eldridge JD. Trochleoplasty with a flexible osteochondral flap: Results from an 11-year series of 214 cases. *Bone Joint J* 2017;99-B:344-350.
- Diduch DR, Burrus MT, Cancienne JM, et al. Trochleoplasty is a viable option for patellar instability in patients with severe trochlear dysplasia: Early outcomes analysis of the U.S. experience. *Orthop J Sports Med* 2017;5:2325967117S0038 (7_suppl6).
- Fucentese SF, Zingg PO, Schmitt J, Pfirrmann CWA, Meyer DC, Koch PP. Classification of trochlear dysplasia as predictor of clinical outcome after trochleoplasty. *Knee Surg Sports Traumatol Arthrosc* 2011;19:1655-1661.
- Donel S, Ali K, Smith DrT, McNamara I. Thick-osteochondral flap deepening trochleoplasty for patellar instability. *Orthop J Sports Med* 2016;4:2325967116S0004 (3_suppl 2).
- Sappey-Marinié E, Sonnery-Cottet B, O’Loughlin P, et al. Clinical outcomes and predictive factors for failure with isolated MPFL reconstruction for recurrent patellar instability: A series of 211 reconstructions with a minimum follow-up of 3 years. *Am J Sports Med* 2019;47:1323-1330.
- Liu JN, Wu H-H, Garcia GH, Kalbian IL, Strickland SM, Shubin Stein BE. Return to sports after tibial tubercle osteotomy for patellofemoral pain and osteoarthritis. *Arthroscopy* 2018;34:1022-1029.
- Liu JN, Brady JM, Kalbian IL, et al. Clinical outcomes after isolated medial patellofemoral ligament reconstruction for patellar instability among patients with trochlear dysplasia. *Am J Sports Med* 2018;46:883-889.

32. Ren B, Zhang X, Zhang L, et al. Isolated trochleoplasty for recurrent patellar dislocation has lower outcome and higher residual instability compared with combined MPFL and trochleoplasty: A systematic review. *Arch Orthop Trauma Surg* 2019;139:1617-1624.
33. Balcarek P, Rehn S, Howells NR, et al. Results of medial patellofemoral ligament reconstruction compared with trochleoplasty plus individual extensor apparatus balancing in patellar instability caused by severe trochlear dysplasia: A systematic review and meta-analysis. *Knee Surg Sports Traumatol Arthrosc* 2017;25:3869-3877.
34. Verdonk R, Jansegers E, Stuyts B. Trochleoplasty in dysplastic knee trochlea. *Knee Surg Sports Traumatol Arthrosc* 2005;13:529-533.
35. Song G-Y, Hong L, Zhang H, et al. Trochleoplasty versus nontrochleoplasty procedures in treating patellar instability caused by severe trochlear dysplasia. *Arthroscopy* 2014;30:523-532.
36. Carstensen SE, Feeley SM, Diduch DR. Manipulation under anesthesia with lysis of adhesions is effective in arthrofibrosis after sulcus-deepening trochleoplasty: A prospective study. *Orthop J Sports Med* 2019;7:2325967119864868.