

UCSF

UC San Francisco Previously Published Works

Title

Stereotactic radiosurgery at a low marginal dose for the treatment of pediatric arteriovenous malformations: obliteration, complications, and functional outcomes.

Permalink

<https://escholarship.org/uc/item/4wb3k1kp>

Journal

Journal of Neurosurgery Pediatrics, 14(1)

ISSN

1933-0707

Authors

Potts, Matthew B

Sheth, Sunil A

Louie, Jonathan

et al.

Publication Date

2014-07-01

DOI

10.3171/2014.3.peds13381

Peer reviewed

# Stereotactic radiosurgery at a low marginal dose for the treatment of pediatric arteriovenous malformations: obliteration, complications, and functional outcomes

## Clinical article

MATTHEW B. POTTS, M.D.,<sup>1</sup> SUNIL A. SHETH, M.D.,<sup>2</sup> JONATHAN LOUIE, B.A.,<sup>1</sup>  
MATTHEW D. SMYTH, M.D.,<sup>8</sup> PENNY K. SNEED, M.D.,<sup>3</sup> MICHAEL W. McDERMOTT, M.D.,<sup>1</sup>  
MICHAEL T. LAWTON, M.D.,<sup>1,7</sup> WILLIAM L. YOUNG, M.D.,<sup>4,7</sup> STEVEN W. HETTS, M.D.,<sup>5</sup>  
HEATHER J. FULLERTON, M.D., M.A.S.,<sup>2,6</sup> AND NALIN GUPTA, M.D., PH.D.<sup>1,6</sup>

Departments of <sup>1</sup>Neurological Surgery, <sup>2</sup>Neurology, <sup>3</sup>Radiation Oncology, <sup>4</sup>Anesthesia and Perioperative Care, <sup>5</sup>Radiology, and <sup>6</sup>Pediatrics, and the <sup>7</sup>Center for Cerebrovascular Research, University of California, San Francisco, California; and <sup>8</sup>Department of Neurological Surgery, Washington University School of Medicine, St. Louis, Missouri

**Object.** Stereotactic radiosurgery (SRS) is an established treatment modality for brain arteriovenous malformations (AVMs) in children, but the optimal treatment parameters and associated treatment-related complications are not fully understood. The authors present their single-institution experience of using SRS, at a relatively low marginal dose, to treat AVMs in children for nearly 20 years; they report angiographic outcomes, posttreatment hemorrhage rates, adverse treatment-related events, and functional outcomes.

**Methods.** The authors conducted a retrospective review of 2 cohorts of children (18 years of age or younger) with AVMs treated from 1991 to 1998 and from 2000 to 2010.

**Results.** A total of 80 patients with follow-up data after SRS were identified. Mean age at SRS was 12.7 years, and 56% of patients had hemorrhage at the time of presentation. Median target volume was 3.1 cm<sup>3</sup> (range 0.09–62.3 cm<sup>3</sup>), and median prescription marginal dose used was 17.5 Gy (range 12–20 Gy). Angiograms acquired 3 years after treatment were available for 47% of patients; AVM obliteration was achieved in 52% of patients who received a dose of 18–20 Gy and in 16% who received less than 18 Gy. At 5 years after SRS, the cumulative incidence of hemorrhage was 25% (95% CI 16%–37%). No permanent neurological deficits occurred in patients who did not experience post-treatment hemorrhage. Overall, good functional outcomes (modified Rankin Scale Scores 0–2) were observed for 78% of patients; for 66% of patients, functional status improved or remained the same as before treatment.

**Conclusions.** A low marginal dose minimizes SRS-related neurological deficits but leads to low rates of obliteration and high rates of hemorrhage. To maximize AVM obliteration and minimize posttreatment hemorrhage, the authors recommend a prescription marginal dose of 18 Gy or more. In addition, SRS-related symptoms such as headache and seizures should be considered when discussing risks and benefits of SRS for treating AVMs in children. (<http://thejns.org/doi/abs/10.3171/2014.3.PEDS13381>)

**KEY WORDS** • arteriovenous malformation • pediatric • stereotactic radiosurgery • vascular disorders

**S**TEREOTACTIC radiosurgery (SRS) is a well-established treatment for brain arteriovenous malformations (AVMs) in children.<sup>17</sup> The decision whether to use SRS rather than resection is influenced by a number of factors including clinical presentation, patient age, natural history risk for AVM, location of AVM in eloquent or deep areas, and patient preference. Stereotactic radiosurgery is believed to act by causing a progressive vasculopathy that results in eventual occlusion of vessels within

the AVM nidus. This process can take 1–3 years, during which time AVM hemorrhage can occur. In general, the surgical risk should be balanced against the annual risk for hemorrhage after SRS treatment.

The reported obliteration rates derived from retrospective studies of pediatric patients vary widely, ranging from 45% to 84% in studies reporting 3-year radiographic outcomes.<sup>2,3,5,9,10,18,24,31,32</sup> The reported median marginal prescription doses range from 16 to 25 Gy; most studies used a median of 20 Gy or more. We have previously shown that in our own experience the rate of complete obliteration was 10-fold higher when marginal prescription doses of 18 Gy or more were used than when doses

Abbreviations used in this paper: AVM = arteriovenous malformation; mRS = modified Rankin Scale; SRS = stereotactic radiosurgery; UCSF = University of California, San Francisco.

less than 18 Gy were used.<sup>26</sup> In that study, the median prescription dose was 18 Gy and the obliteration rate was 35%. Since that time, we have maintained a prospective database of AVM patients and have increased our dose/volume guidelines for treatment of AVM in children. In the study reported here, we expand our experience with SRS treatment of brain AVMs in children and specifically focus on posttreatment complications and functional outcomes.

## Methods

### *Patients*

This study was approved by the Institutional Review Board of the University of California, San Francisco (UCSF) and conducted in compliance with Health Insurance Portability and Accountability Act regulations. The study comprised 2 cohorts of children 18 years of age or younger with brain AVMs treated with SRS. The first cohort consisted of 43 patients who received treatment from 1991 to 1998. Data for these patients were retrospectively collected as part of a prior study<sup>26</sup> and were updated through retrospective review of medical records. Patients who had been excluded from this prior study because of the short duration of their follow-up were included in the present study. The second cohort consisted of 37 children who received treatment from 2000 to 2010 and were identified through the prospective registries of the UCSF Brain Arteriovenous Malformation Study Project and Department of Radiation Oncology. For this study, we retrospectively reviewed these databases, medical records, pre- and post-SRS imaging studies, and clinical follow-up evaluations. Of note, although AVMs in children were treated during the intervening time, data for those patients were not readily available for analysis. Data for both cohorts included presenting symptoms, AVM characteristics (location, volume, Spetzler-Martin grade), and SRS parameters (prescription marginal dose, treated isodose line, number of stages). Modified Pollock radiosurgery-based AVM grading system scores<sup>22</sup> were calculated based on the AVM target volume used for SRS planning. At the time of treatment, all patients were reviewed by a multidisciplinary cerebrovascular team consisting of neurologists, neurosurgeons, interventional neuroradiologists, and radiation oncologists. For patients with larger, less surgically accessible AVMs, SRS is typically recommended instead of microsurgery.

### *Stereotactic Radiosurgery Technique*

For all patients, SRS was performed with a model B, C, 4C, or Leksell Gamma Knife Perfexion (Elekta Instruments). General anesthesia or conscious sedation, based on patient age, was administered by a pediatric anesthesiologist. After administration of local anesthesia, a Leksell head frame was placed. Patients then underwent pre-SRS stereotactic angiography and MRI, including precontrast T1-weighted and Gd-enhanced time-of-flight sequences. Results of these studies were superimposed to aid in target delineation, which was performed by the attending radiation oncologist and neurosurgeon after the interventional

neuroradiologist had outlined the nidus on orthogonal angiograms. The treatment plan was created by a physicist who used GammaPlan treatment planning software (Elekta AB) and approved by the attending radiation oncologist and neurosurgeon. Volume-staged SRS was considered if the treatment volume exceeded 8–10 cm<sup>3</sup>; for these patients, approximately 8–10 cm<sup>3</sup> was treated per stage at 3- to 6-month intervals. Subsequent registration for staged procedures was accomplished by using anatomical landmarks defined on thin-slice MR images obtained after frame placement.<sup>7</sup> After treatment and recovery from anesthesia, patients were discharged home.

### *Outcome Measurements*

Outcome measures for this study included post-SRS complications (hemorrhage, seizure, headaches, or new neurological deficits) and radiographic outcome (complete vs incomplete obliteration of the AVM) based on 3-year post-SRS follow-up angiography. All post-SRS angiograms were reviewed by a single attending neuroradiologist (S.W.H.) who was blinded as to radiosurgical treatment dose. In addition, for the 2000–2010 cohort, we recorded functional neurological status before and after SRS. Status was based on pediatric, radiation oncology, and neurosurgery clinic notes and was measured by using the modified Rankin Scale (mRS).<sup>6</sup>

### *Statistical Analyses*

All statistical analyses were performed by using JMP 10.0 software (SAS Institute, Inc.). Univariate analyses were performed on preidentified factors by using the Mann-Whitney U-test for continuous variables (that is, age and prescription dose) and Pearson chi-square tests for categorical variables (that is, Spetzler-Martin grade, patient sex). Multivariate analyses were performed by using a logistic regression model. Survival analysis of time to post-SRS hemorrhage or censorship was also performed, and survival curves were compared with a log-rank test, measuring from the date of the first or only SRS treatment. We considered *p* values less than 0.05 to be significant.

## Results

### *Patient and AVM Characteristics*

We identified 83 children with AVMs treated with SRS at UCSF during the 2 study periods (1991–1998 and 2000–2010). We excluded from the study 3 patients for whom no follow-up data were available after the date of their SRS treatment. Table 1 lists the baseline characteristics for the remaining 80 patients who constituted our final study cohort, data for each subcohort (1991–1998 and 2000–2010), and data for a subcohort of 47 patients from either study period for whom 3 or more years of follow-up angiographic data were available. Overall, mean patient age at SRS was 12.7 years; male patients predominated slightly (61%). The most common presenting sign was hemorrhage (56%). The most common AVM location was in the basal ganglia/thalamus (35%), and 64% were in the left hemisphere. No patient had a known family history of hereditary hemorrhagic telangiectasia.

## Radiosurgery for pediatric AVMs

**TABLE 1: Baseline characteristics of 80 children who underwent SRS for brain AVMs**

Characteristic	Patients in 1991–1998 Cohort	Patients in 2000–2010 Cohort	p Value*	All Patients	Patients w/ 3-Yr Follow-Up Angiograms
patients (no.)	43	37		80	47
mean age at SRS in yrs ( $\pm$ SD)	11.8 $\pm$ 3.9	13.9 $\pm$ 3.4	<b>0.009</b>	12.7 $\pm$ 3.8	12.1 $\pm$ 3.9
male, no. (%)	29 (67)	20 (54)	0.22	49 (61)	30 (64)
chief presentation, no. (%)			0.46		
hemorrhage	24 (56)	21 (57)		45 (56)	30 (64)
seizure	7 (16)	10 (27)		17 (21)	7 (15)
headache	3 (7)	3 (8)		6 (8)	5 (11)
focal neurological deficit	4 (9)	2 (5)		6 (8)	3 (6)
other†	5 (12)	1 (3)		6 (8)	2 (4)
location, no. (%)			<b>0.036</b>		
frontal lobe	8 (19)	7 (19)		15 (19)	8 (17)
basal ganglia/thalamus	13 (30)	15 (41)		28 (35)	19 (40)
temporal lobe	7 (16)	1 (3)		8 (10)	4 (9)
parietal lobe	2 (5)	5 (14)		7 (9)	4 (9)
occipital lobe	2 (5)	5 (14)		7 (9)	5 (11)
ventricle	5 (12)	0		5 (6)	1 (2)
brainstem	2 (5)	2 (5)		4 (5)	2 (4)
corpus callosum	3 (7)	0		3 (4)	2 (4)
insula	0	2 (5)		2 (3)	1 (2)
vein of Galen	1 (2)	0		1 (1)	1 (2)
laterality, no. (%)			0.28		
left	24 (56)	27 (73)		51 (64)	32 (68)
right	15 (35)	8 (22)		23 (29)	10 (21)
bilateral	4 (9)	3 (5)		6 (8)	5 (11)
prior hematoma evacuation, no. (%)	1 (2)	4 (11)	0.12	5 (6)	4 (9)
prior AVM treatment, no. (%)	12 (28)	11 (30)	0.86	13 (16)	6 (13)
resection	0	8 (22)	<b>0.0013</b>	8 (10)	3 (6)
endovascular embolization‡	12 (28)	8 (22)	0.52	10 (13)	5 (11)
radiosurgery	2 (5)	1 (3)	0.65	3 (4)	2 (4)
modified Pollock AVM score, mean ( $\pm$ SD)	1.1 $\pm$ 1.4	1.5 $\pm$ 1.0	<b>0.015</b>	1.3 $\pm$ 1.2	1.0 $\pm$ 0.8
mean AVM vol in cm <sup>3</sup> ( $\pm$ SD)	7.3 $\pm$ 13.5	9.6 $\pm$ 10.6	0.096	8.4 $\pm$ 12.2§	5.8 $\pm$ 7.4
Spetzler-Martin grade, no. (%)			0.16		
II	7 (16)	3 (8)		10 (13)	6 (13)
III	27 (63)	18 (49)		45 (56)	30 (64)
IV	6 (14)	12 (32)		18 (23)	9 (19)
V	3 (7)	4 (11)		7 (9)	2 (4)

\* Comparison of 1991–1998 and 2000–2010 cohorts. Boldface indicates statistical significance.

† Other presentations included increasing head circumference (n = 1), diplopia (n = 1), and incidental finding during workup for multiple congenital abnormalities (n = 2) and a posterior fossa tumor (n = 1).

‡ Eight patients underwent prior treatments with multiple modalities.

§ AVM volume data were not available for 4 patients in the 1991–1998 cohort; these patients were not part of the 3-year angiographic cohort.

### Radiosurgical Treatment

The primary treatment was SRS for 84% of patients. For the remaining patients, prior treatments included subtotal resection and endovascular embolization. In addition, 3 patients had previously undergone SRS at an outside institution and 8 patients had previously undergone treatment with multiple modalities (Table 1). Table 2 de-

tails the SRS parameters for the overall cohort and aforementioned subcohorts. Overall, the median prescription dose was 17.5 Gy (range 12–20 Gy), prescribed to the 50% isodose line for all but 9 patients. Radiosurgery was staged for 25% of patients (2 stages for 16%, 3 stages for 9%). For patients who underwent staged SRS, the median time between the first and final stage was 7 months.

**TABLE 2: Stereotactic radiosurgery treatment parameters for 80 patients who underwent SRS for brain AVMs**

Parameter	1991–1998 Cohort	2000–2010 Cohort	Patients w/ 3-Year Follow-Up Angiograms	Patients Who Received <18 Gy	Patients Who Received ≥18 Gy	All Patients
patients (no.)	43	37	47	43	37	80
mean target vol in cm <sup>3</sup> (±SD)	7.3 ± 13.5	9.6 ± 10.6	5.8 ± 7.4	14.2 ± 14.1	1.6 ± 2.1	8.4 ± 12.2
median prescription dose, Gy (mean, range)	17.5 (16.7–12–19)	17.5 (17.6, 15–20)	17.5 (17.1, 12–20)	16.5 (16.0, 12–17.5)	18 (18.5, 18–20)	17.5 (17.1, 12–20)
prescription isodose line (%) <sup>*</sup>	50	50	50	50	50	50
stages, no. (%)						
1	38 (88)	23 (62)	39 (83)	26	35	60 (75)
2	4 (9)	8 (22)	4 (9)	10	2	13 (16)
3	1 (2)	6 (16)	4 (9)	7	0	7 (9)
median time from first to last stage, mo. (range) <sup>†</sup>	12 (6–14)	5.5 (3–15)	7 (3–13)	7 (3–15)	7 (4–10)	7 (3–15)

<sup>\*</sup> Of the total group, 71 patients (89%) received treatment to the 50% isodose line; for the remaining 9 patients, the isodose line varied from 40% to 90%.

<sup>†</sup> For patients who underwent staged SRS.

*Differences Between Cohorts*

Several significant differences were detected between the 2 cohorts (Tables 1 and 2), reflecting changes in practice patterns at UCSF. Differences in mean patient age (11.8 vs 13.9 years,  $p = 0.009$ ), modified Pollock score (1.1 vs 1.5,  $p = 0.015$ ), and Spetzler-Martin grades (21% vs 43% Grade IV or V,  $p = 0.03$ ) indicated increased complexity of the AVMs being treated with SRS in the more recent cohort. Although the overall proportion of patients who had undergone prior treatments did not differ, prior subtotal resection had been performed for 22% of patients in the 2000–2010 cohort and no patients in the 1991–1998 cohort ( $p = 0.013$ ). In addition, SRS was staged for more patients in the 2000–2010 cohort than in the earlier cohort (38% vs 12%, respectively,  $p = 0.006$ ). Notably, the unbalanced mean prescription marginal doses did not significantly differ between the 1991–1998 and 2000–2010 cohorts ( $p = 0.19$ ). However, when AVM volume was controlled for, least-squares analysis showed that the mean prescription dose increased from 16.5 Gy for the 1991–1998 cohort to 17.7 Gy for the 2000–2010 cohort ( $p = 0.0019$ ; Fig. 1).

*Angiographic Outcomes*

Angiographic evaluation was performed 3 years after SRS treatment for 47 patients (59%). A complete response was seen for 16 patients (34%), and an incomplete response was seen for the remaining 31 (66%). Univariate logistic regression identified higher prescription dose ( $p = 0.006$ ; Fig. 2) and target volume ( $p = 0.038$ ) as being significantly associated with complete obliteration. When tested as a dichotomous variable, higher prescription dose was also significantly associated with angiographic obliteration ( $\geq 18$  vs  $< 18$  Gy,  $p = 0.015$ , Fisher exact test). Factors not associated with angiographic response included patient age ( $p = 0.56$ ), hemorrhage at presentation ( $p = 0.07$ ), Pollock score ( $p = 0.067$ ), and Spetzler-Martin score ( $p = 0.77$ ). Because our target volume is used to guide prescription dose,<sup>26</sup> we analyzed the association between these 2 variables and found a weak but significant association between prescription dose and the log of the target volume ( $R^2 = 0.16$ ,  $p = 0.005$ , 1-way ANOVA). A logistic regression model incorporating prescription dose and log(target volume) showed a significant association between these 2 variables and angiographic outcome (overall model  $p = 0.02$ , prescription dose  $p = 0.03$ , log[target volume]  $p = 0.75$ ).

*Complications Associated With Treatment*

Overall, a post-SRS complication was recorded for 38 patients (48%), among whom multiple complications were recorded for 13 (16%). Posttreatment hemorrhage occurred in 16 patients (20%), 1 of whom died. The cumulative incidence of hemorrhage 5 years after SRS was 25% (95% CI 16%–37%) (Fig. 3). The median time to hemorrhage was 15 months (range 4–136 months). For 11 patients (69%) who experienced posttreatment hemorrhage, the hemorrhage occurred during the radiosurgical latency period (defined as within 3 years after the first stage of treatment). Of these patients, 10 underwent



## Radiosurgery for pediatric AVMs

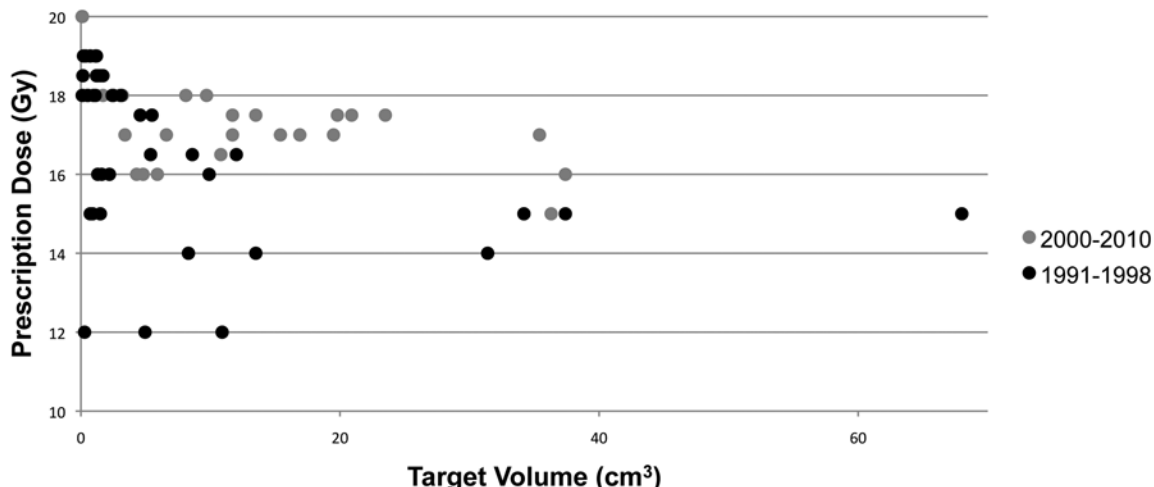


Fig. 1. Graph showing AVM volume-dose relationship between the 1991–1998 and 2000–2010 cohorts. Results of an initial analysis of SRS to treat AVMs in children at UCSF<sup>26</sup> led to use of a higher prescription marginal dose for a given AVM volume for the more recent (2000–2010) cohort than was used for the initial (1991–1998) cohort.

3-year follow-up angiography; all angiograms revealed a residual AVM nidus. Of note, 7 patients who experienced post-SRS hemorrhages had undergone staged SRS, but for only 2 did hemorrhage occur before completion of the final stage of SRS. Hemorrhage was more likely among patients who received a dose of less than 18 Gy than among those who received 18–20 Gy (Fig. 3; Table 3). Table 3 details the proportion of patients for whom SRS-related complications during follow-up were documented (mean 50 months, median 46 months, range 2–187 months). No patient experienced hemorrhage after angiographically documented AVM obliteration.

### Additional Treatments

A total of 25 patients (31%) underwent subsequent

treatment for residual AVM. Of these, 18 patients underwent salvage SRS, 6 resection, 2 endovascular embolization alone, and 1 salvage SRS followed by resection. Follow-up images were available for 12 of these patients. Of the patients who underwent salvage SRS, complete obliteration was seen on long-term images for 3 patients; on MR images taken 1 year after salvage SRS, reduced AVM shunting was seen for 1 patient and no change was seen for 1 patient. Of the 6 patients who ultimately underwent surgery, complete resection was achieved for 4 and partial resection for 2. One patient with a giant hemispheric AVM underwent palliative embolization for severe headaches, which improved modestly after this treatment.

### Functional Outcome

For 32 of the 37 patients in the 2000–2010 cohort, functional status was measured before SRS and at the time of the last follow-up visit (Fig. 4). Mean time to follow-up mRS measurement was 2.9 years (median 2.4 years, range 2.5 months to 7.9 years). Good outcomes (mRS Score 0–2) were seen for 25 patients (78%); of these, improvement or no change from pre-SRS functional baseline was noted for 21 patients (66%) and worsening was noted for 11 patients. Of the 11 patients with worsened functional status, 5 experienced hemorrhages during the follow-up time and the remaining 6, although worsened, still had mRS scores of 1 or 2. One patient in this series died of posttreatment hemorrhage.

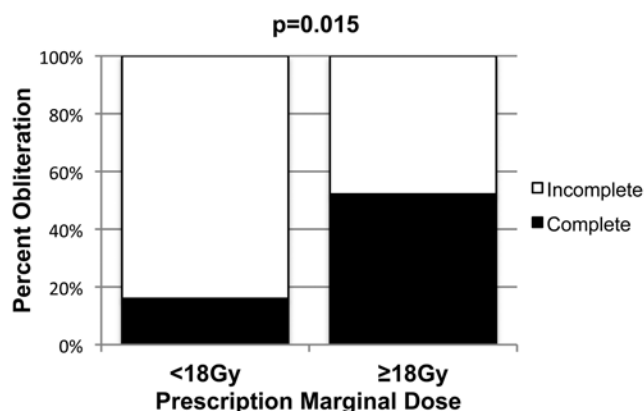
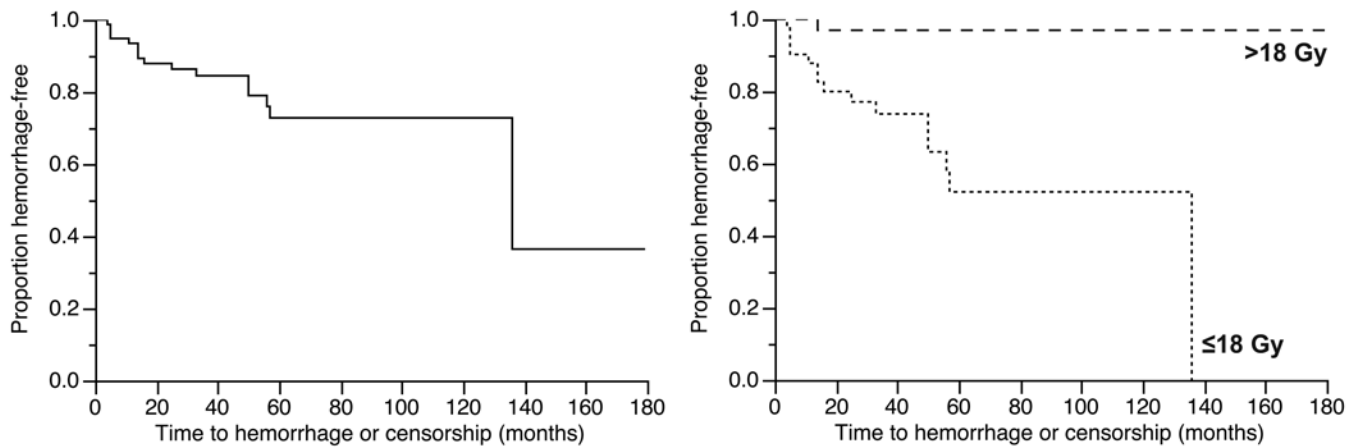


Fig. 2. Angiographic outcomes according to prescription marginal dose. Univariate analysis showed that both prescription dose and target volume were significantly associated with angiographic outcome, although only prescription dose remained significant when a logistic regression model incorporating both variables was constructed (overall model,  $p = 0.01$ ; prescription dose,  $p = 0.03$ ; target volume,  $p = 0.25$ ). Overall, complete obliteration on 3-year angiogram was achieved for 52% of patients who received 18–20 Gy and only 16% who received less than 18 Gy ( $p = 0.015$ , Fisher exact test).

## Discussion

The reported efficacy of SRS for the treatment of brain AVMs in children varies widely (Table 4). Definitive conclusions from studies to date are difficult to reach because of variations in duration of follow-up, patient selection criteria, and SRS parameters used to treat pediatric AVMs. In the present study, we report a series of children with AVM treated with a relatively low prescription marginal dose and describe angiographic outcomes, rates of posttreatment hemorrhage, other treatment-related ad-



**Fig. 3.** Hemorrhage-free survival among children with brain AVM treated with SRS. Overall hemorrhage-free survival (**left**) and hemorrhage-free survival based on marginal prescription dose (**right**). Mean time to last follow-up visit was 50 months (median 46 months, range 2–187 months). Significantly fewer hemorrhages occurred among patients who received a marginal dose of 18–20 Gy than among those who received less than 18 Gy ( $p = 0.0003$ , log-rank test).

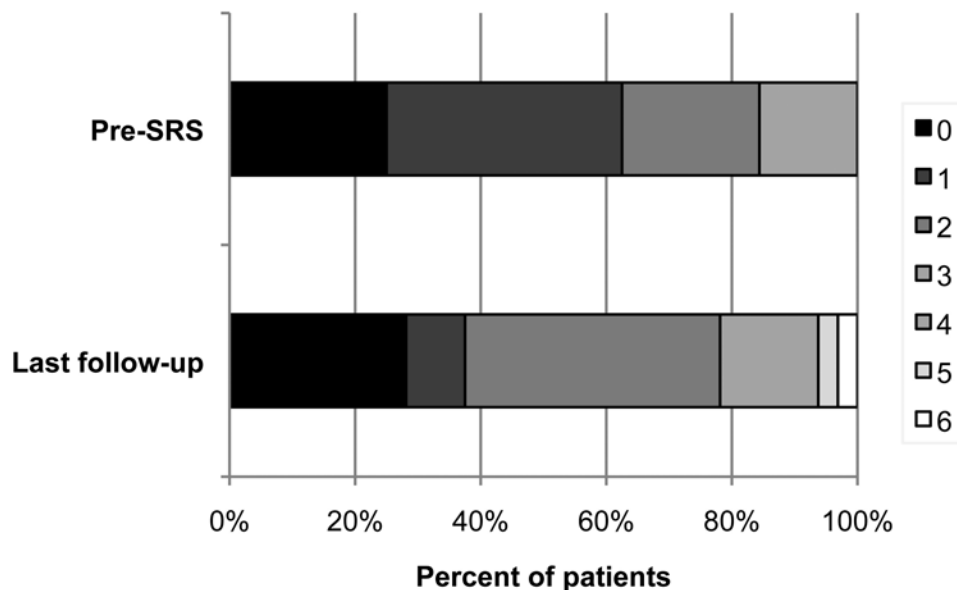
verse events, and functional outcomes. Several differences exist between our population and previously reported populations. For our study population, we favored a lower prescription marginal dose (median 17.5 Gy) and tended to treat larger, more complex AVMs with SRS and smaller and less complex AVMs with resection. When compared with other studies that reported median target volumes, in our study, median target volumes did not differ substantially, but the proportion of patients with Spetzler-Martin Grades IV or V was higher (Table 4). Our practice has changed with time, as can be seen in the differences between the 1990–1998 and 2000–2010 cohorts. Our practice is to follow a dose-volume toxicity curve<sup>26</sup> and to use lower doses for larger volumes. From our initial experience using SRS to treat AVMs in children, we found that a prescription dose of 18 Gy or more was associated with an improved rate of obliteration.<sup>26</sup> On the basis of this finding, we slightly increased our marginal doses for a given AVM volume (Fig. 1). In addition, we have taken a more aggressive stance with microsurgical management of small and low-grade AVMs. SRS is therefore now used for larger AVMs and more often used for patients who have undergone prior attempts at resection.

In this study, we found that prescription dose is a critical factor associated with both obliteration and posttreatment hemorrhage; our lower prescription doses therefore probably explain our lower rates of obliteration (34% at 3 years). The overall prescription marginal doses used ranged from 12 to 20 Gy. Several studies have advocated for higher doses of at least 20 Gy. Most recently, Dinca et al. reported a large series of children with AVM treated with Gamma Knife radiosurgery.<sup>5</sup> Nearly all of those patients received prescription marginal doses of 20–25 Gy. At those high prescription doses, Dinca et al. found no differences in angiographic outcomes; obliteration rate for patients undergoing SRS for the first time was 71%, and the rate of posttreatment hemorrhage was only 2.2%. Because only 4 patients received less than 20 Gy, these authors could not comment on the efficacy of lower prescription doses. In our series, however, our highest doses (18–20 Gy) still only resulted in a 3-year angiographic obliteration rate of 52%. Of note, the rate of hemorrhage for this higher dose group was only 3%, comparable to that reported by Dinca et al. Although AVM obliteration is clearly protective against posttreatment hemorrhage,<sup>20</sup> these data suggest that SRS of at least 18 Gy might pro-

**TABLE 3: Post-stereotactic radiosurgery complications**

Complication	No. of Patients (%)		
	Received <18 Gy (n = 43)	Received 18–20 Gy (n = 37)	All
any	27 (63)	11 (30)	38 (48)
hemorrhage	15 (35)	1 (3)	16 (20)
not associated w/ hemorrhage			
seizure	10 (23)	6 (16)	16 (20)
headache	11 (26)	6 (16)	17 (21)
temporary neurological deficit	1 (2)	0	1 (2)
permanent neurological deficit	0	0	0
nausea/vomiting	1 (2)	1 (3)	2 (3)
memory disturbance	0	1 (3)	1 (2)
multiple	9 (21)	4 (11)	13 (16)

## Radiosurgery for pediatric AVMs



**Fig. 4.** Pre-SRS and post-SRS functional status for children with brain AVMs, based on mRS scores. Functional status was measured before SRS and at the time of the last follow-up visit for 32 patients from the 2000–2010 cohort (mean 2.9 years, median 2.4 years, range 2.5 months–7.9 years). Functional status was good (mRS Score 0–2) for 78% of patients at the time of the last follow-up visit and was improved or unchanged from pretreatment status for 66%.

vide protection from posttreatment hemorrhage even if only a partial response is obtained. Given our low rate of obliteration among patients who received less than 18 Gy (35%), however, lower doses do not seem to offer similar protection.

With regard to other post-SRS complications, we included not only neurological deficits but also symptoms of brain edema (headache, nausea/vomiting) and new or worsening seizures (Table 3). We identified no permanent neurological deficits that were not associated with posttreatment hemorrhage and found only 1 patient in whom temporary posttreatment neurological deficits developed. The most common posttreatment complications not associated with hemorrhage were headaches and seizures, experienced by 21% and 20% of patients, respectively. For 5 patients, posttreatment headaches were managed with decadron, which was also used (in addition to increasing antiepileptic medications) in 1 patient after worsening of seizures. Overall, our prescription dose effectively minimized posttreatment neurological deficits related directly to SRS. However, this benefit was negated by lower rates of obliteration and higher rates of posttreatment hemorrhage.

Few studies of SRS for AVMs in children have reported changes in functional status based on mRS scores, a well-established measure of neurological function.<sup>6</sup> A given patient's functional outcome after SRS for an AVM is dependent on that patient's pretreatment functional status, any adverse events that occur after treatment (either directly treatment-related or otherwise), and that patient's ability to recover from any insults at the time of presentation and/or posttreatment adverse events. Thus, mRS scores provide a general sense of the entire treatment and recovery process. This measure also distinguishes between patients with no symptoms or functional disabilities (mRS Score 0) and those with mild symptoms that do

not impair function (mRS Score 1). More than half of the patients in our series with “worsened” functional status at last follow-up visit actually had what would be considered a “good” mRS score (1 or 2). Subtle changes in symptoms can result from overt motor or sensory deficits as well as other potential SRS-associated adverse effects, such as seizures, headache, nausea/vomiting, or cognitive deficits. Although 5 of the 11 patients in this series with worsened functional status experienced posttreatment hemorrhages, the remainder experienced headaches, seizures, or both, and all had mRS scores of 1 or 2 at the time of last follow-up visit. Of course, even more subtle neurological symptoms, such as cognitive deficits, are often difficult to detect without detailed neuropsychological examination. Yeon et al.<sup>30</sup> specifically evaluated patients' school performance and determined that performance declined after treatment for 44% of AVM patients who underwent SRS. Such findings emphasize the need for neuropsychological evaluations in future studies of SRS in the pediatric population.

### Conclusions

SRS is a useful tool in the management of brain AVMs in children, but the safety profile and necessary SRS parameters still require elucidation. In this study, a low marginal dose minimized overt neurological deficits directly associated with SRS but also resulted in lower rates of obliteration and higher rates of posttreatment hemorrhage. On the basis of this experience, we recommend marginal doses of at least 18 Gy to improve obliteration rates and reduce the risk for posttreatment hemorrhage. Comparison of our results with those of prior studies that used higher prescription doses ( $\geq 20$  Gy), however, suggests that even better angiographic results and reasonable



TABLE 4: Summary of studies of SRS for children with brain AVMs\*

Authors & Year	No of Cases	SMG (%)	SRS Device	SRS Parameters			Outcomes		
				Marginal Dose (Gy)	Target Vol (cm <sup>3</sup> )	Complete Obliteration/Time to Radiographic FU	Posttreatment Hemorrhage (%) / Time to Clinical FU	Other Reported Complications	
present study	80	II (13), III (56), IV (23), V (9)	GK	med 17.5	med 3.1	34 %/3 yrs	20%/med 2.4 yrs	20% new or worsened seizures, 21% HA, 2% permanent neuro deficit, 3% N/V, 2% memory disturbance, 16% multiple complications	
Skjøth-Rasmussen et al., 2012	6‡	V (17), III (83)	NR	NR	NR	67%/NR	none/NR	33% (1 neuro deficit, 1 long-term cognitive deficits)	
Kano et al., 2012	135	I (2.2), II (25), III (43), IV (13), V (0), VI (17)	GK	med 20.0	med 2.5	45%/3 yrs, 72%/10 yrs	6%/med 41 mos	2 permanent neuro deficits, 6 transient symptoms	
Darsaut et al., 2011	25†§	I–III (48), IV–V (52)		mean 21.2	mean 27	20%/NR	NR/NR	NR	
Yeon et al., 2011	39	I–II (28), III (49), IV–V (26)	GK	med 20.0	NR	44% after initial SRS/mean 23 mos	8%/NR	31% T2 signal change; 4 temporary HA, 2 neuro deterioration, 1 new-onset seizure; 44% declining school performance (due to memory deficits)	
Yen et al., 2010	186	I (12), II (30), III (47), IV (11), V (0.5)	GK	mean 20.7	mean 2.3	50% after initial SRS/NR	9%/mean 98 mos	4% HA, 2.2% temporary neuro deficits, 1% permanent neuro deficit, 1% meningiomas, 3% post-SRS cysts	
Mirza et al., 2010	6	II (33), III (67)	LINAC	either 24.0 or 25.0 (all patients)	<3	100%/NR	none/med 52 mos	2 focal neuro deficits, 1 cognitive deficit	
Buis et al., 2008	22	I (27), II (41), III (23), IV (9)	LINAC	med 19.0	med 1.8	45%/2 yrs, 64%/3 yrs	5%/mean 3.4 yrs	1 persistent neuro deficit; 32% T2 changes on MRI, 4.5% cyst formation	
Pan et al., 2008	105	I (6), II (22), III (47), IV (19), V (6), VI (1)	GK	mean at least 20.0		65%/2 yrs	4%/med 25 mos	3 temporary neuro deficits, 5 permanent neuro deficits	
Reyns et al., 2007	100	I (10), II (34), III (22), IV (5), V (0), VI (29)	LINAC	mean 23.0		65% after initial SRS/med 26 mos	2%/NR	6 permanent neuro deficits, 2 epilepsy	
Zadeh et al., 2007	40	I (15), II (35), III (35), IV (15)		15%–67% IDL (23 patients), 20.0%–90% IDL (12 patients), & 22.0%–90% IDL (1 patient)		67%/3 yrs	none/NR	4 permanent neuro deficits, 1 seizure	
Zabel-du Bois et al., 2006	22	I (4), II (32), III (56), IV (4), V (4)	LINAC	med 18.0		54%/3yrs, 65%/4 yrs	23%/NR	1 thalamic infarct due to steal phenomenon; 1 symptomatic focal edema	
Cohen-Gadol & Pollock, 2006	38	I–II (29), III (50), IV–V (21)	GK	med 20.0	med 3.4	66%/3 yrs	3%/NR	1 temporary neuro deficit	
Fuss et al., 2005	7	NR	IMRS	med 18.0	med 13.8	29%/med 32 mos	none/med 32 mos	2 w/ acute nausea/vomiting after treatment	

(continued)

TABLE 4: Summary of studies of SRS for children with brain AVMs\* (continued)

Authors & Year	No. of Cases	SMG (%)	SRS Device	SRS Parameters			Outcomes		
				Marginal Dose (Gy)	Target Vol (cm <sup>3</sup> )	Complete Obliteration/Time to Radiographic FU	Posttreatment Hemorrhage (%)/Time to Clinical FU	Other Reported Complications	
Nicolato et al., 2005	63†	I–III (92), IV (8)	GK	mean 21.6	mean 3.8	72%/3 yrs, 77%/4 yrs	none/med 33 mos	1 transient & 1 permanent neuro deficit	
Maity et al., 2004	17	NR	LINAC	med 19.0	med 6.9	53%/med 21 mos	none/med 30 mos	3 permanent, 1 temporary neuro deficits	
Nataf et al., 2003	57	I (11), II (35), III (40), IV (14)	LINAC	med 25.0	med 3.5	61%/NR (mean time to obliteration 34 mos)	8.2%/med 34 mos	none	
Shin et al., 2002	100	I (8), II (36), III (42), IV (10), V (0), VI (4)	GK	med 20.0	med 1.8	84%/3 yrs, 89%/4 yrs, & 95%/5 yrs	4%/med 71 mos	2 permanent, 2 transient neuro deficits	
Levy et al., 2000	53	I (2), II (23), III (36), IV (9), V (0), VI (30)	GK	med 20.0	med 1.7	74%/med 36 mos	8%/mean 2.9 yrs	1 permanent neuro deficit	
Hoh et al., 2000	15‡	NR	BPPB	med 16.0	med 4.5	75%/3 yrs**	7%/NR	none	
Tanaka et al., 1996	23	II (22), III (74), IV (4)	GK	mean 20.5	mean 4.8	74%/1y, 95/2 yrs	none/NR	none	
Yamamoto et al., 1992	9	II (33), III (67)	GK	mean 23.0	mean 2	67%/range 1–5 yrs	none/NR	none	
Loeffler et al., 1990	10	NR	LINAC	med 17.5	NR	56%/1 yr	none/NR	none	
Altschuler et al., 1989	18	III (50), VI (50)	GK	17.5–25.0	NR	43%/1 yr	none/range 7–19 mos	1 transient neuro deficit	
Levy et al., 1989	40	NR	BPPB	mean 27.0	mean 11.2	78%/2 yrs	5%/NR	8% neuro deficit	

\* BPPB = Bragg peak proton beam therapy; FU = follow-up; GK = Gamma Knife; HA, headache; IDL = isodose line; IMRS = intensity modulated radiosurgery; med = median; neuro = neurological; NR = not reported; N/V = nausea/vomiting; SMG = Spetzler-Martin grade.

† For patients with complete follow-up imaging data as defined by each study.

‡ Patients were part of a larger series of patients with AVM.

§ Limited to patients who underwent SRS as initial treatment.

¶ Reported only patients ≤ 16 yr of age.

\*\* Excludes 1 patient who underwent surgery after SRS.

complication rates can be obtained when higher doses are used. In addition, aggressive follow-up and consideration of salvage SRS should be implemented for these patients. With multiple treatment options for brain AVMs in children, an understanding of the risks and benefits of SRS is critical for optimizing patient outcomes. For further clarification of the potential risks of SRS, prospective studies incorporating detailed neurological and cognitive assessments are needed.

#### Acknowledgment

We thank Annette M. Molinaro, Ph.D., for her assistance with statistical analysis.

#### Disclosure

The authors report no conflict of interest concerning the materials or methods used in this study or the findings specified in this paper.

This research was funded in part by the National Institutes of Health (grant no. R01 NS034949 to W.L.Y. and grant no. P01 NS044155 to Center for Cerebrovascular Research).

Author contributions to the study and manuscript preparation include the following. Conception and design: Gupta, Potts, Fullerton. Acquisition of data: Potts, Sheth, Louie, Smyth, Sneed, Young, Hettis. Analysis and interpretation of data: Gupta, Potts, Sheth, Smyth, Sneed, Fullerton. Drafting the article: Potts. Critically revising the article: all authors. Reviewed submitted version of manuscript: all authors. Approved the final version of the manuscript on behalf of all authors: Gupta. Statistical analysis: Potts. Study supervision: Gupta.

#### References

- Altschuler EM, Lunsford LD, Coffey RJ, Bissonette DJ, Flickinger JC: Gamma knife radiosurgery for intracranial arteriovenous malformations in childhood and adolescence. **Pediatr Neurosci** **15**:53–61, 1989
- Buis DR, Dirven CMF, Lagerwaard FJ, Mandl ES, Lycklama á Nijeholt GJ, Eshghi DS, et al: Radiosurgery of brain arteriovenous malformations in children. **J Neurol** **255**:551–560, 2008
- Cohen-Gadol AA, Pollock BE: Radiosurgery for arteriovenous malformations in children. **J Neurosurg** **104 (6 Suppl)**: 388–391, 2006
- Darsaut TE, Guzman R, Marcellus ML, Edwards MS, Tian L, Do HM, et al: Management of pediatric intracranial arteriovenous malformations: experience with multimodality therapy. **Neurosurgery** **69**:540–556, 2011
- Dinca EB, de Lacy P, Yianni J, Rowe J, Radatz MWR, Preotiu-Pietro D, et al: Gamma knife surgery for pediatric arteriovenous malformations: a 25-year retrospective study. Clinical article. **J Neurosurg Pediatr** **10**:445–450, 2012
- Feliciano CE, Rodríguez-Mercado R: Evaluation of pediatric patients with vascular malformations managed with endovascular and radiosurgical techniques using a modified Rankin Disability Scale. **P R Health Sci J** **27**:27–33, 2008
- Fogh S, Ma L, Gupta N, Sahgal A, Nakamura JL, Barani I, et al: High-precision volume-staged Gamma Knife surgery and equivalent hypofractionation dose schedules for treating large arteriovenous malformations. Clinical article. **J Neurosurg** **117 Suppl**:115–119, 2012
- Fuss M, Salter BJ, Caron JL, Vollmer DG, Herman TS: Intensity-modulated radiosurgery for childhood arteriovenous malformations. **Acta Neurochir (Wien)** **147**:1141–50, 2005
- Hoh BL, Ogilvy CS, Butler WE, Loeffler JS, Putman CM, Chapman PH: Multimodality treatment of nongalenic arteriovenous malformations in pediatric patients. **Neurosurgery** **47**:346–358, 2000
- Kano H, Kondziolka D, Flickinger JC, Yang HC, Flannery TJ, Awan NR, et al: Stereotactic radiosurgery for arteriovenous malformations, part 2: management of pediatric patients. Clinical article. **J Neurosurg Pediatr** **9**:1–10, 2012
- Levy EI, Niranjan A, Thompson TP, Scarrow AM, Kondziolka D, Flickinger JC, et al: Radiosurgery for childhood intracranial arteriovenous malformations. **Neurosurgery** **47**:834–842, 2000
- Levy RP, Fabrikant JI, Frankel KA, Phillips MH, Lyman JT: Stereotactic heavy-charged-particle Bragg peak radiosurgery for the treatment of intracranial arteriovenous malformations in childhood and adolescence. **Neurosurgery** **24**:841–852, 1989
- Loeffler JS, Rossitch E Jr, Siddon R, Moore MR, Rockoff MA, Alexander E III: Role of stereotactic radiosurgery with a linear accelerator in treatment of intracranial arteriovenous malformations and tumors in children. **Pediatrics** **85**:774–782, 1990
- Maity A, Shu HKG, Tan JE, Ruffer J, Sutton LN, Tochner Z, et al: Treatment of pediatric intracranial arteriovenous malformations with linear-accelerator-based stereotactic radiosurgery: the University of Pennsylvania experience. **Pediatr Neurosurg** **40**:207–214, 2004
- Mirza B, Mønsted A, Harding J, Ohlhues L, Roed H, Juhler M: Stereotactic radiotherapy and radiosurgery in pediatric patients: analysis of indications and outcome. **Childs Nerv Syst** **26**:1785–1793, 2010
- Nataf F, Schlienger M, Lefkopoulos D, Merienne L, Ghossoub M, Foulquier JN, et al: Radiosurgery of cerebral arteriovenous malformations in children: a series of 57 cases. **Int J Radiat Oncol Biol Phys** **57**:184–195, 2003
- Niazi TN, Klimo P Jr, Anderson RCE, Raffel C: Diagnosis and management of arteriovenous malformations in children. **Neurosurg Clin N Am** **21**:443–456, 2010
- Nicolato A, Foroni R, Crocco A, Zampieri PG, Alessandrini F, Bricolo A, et al: Gamma knife radiosurgery in the management of arteriovenous malformations of the Basal Ganglia region of the brain. **Minim Invasive Neurosurg** **45**:211–223, 2002
- Nicolato A, Foroni R, Seghedoni A, Martines V, Lupidi F, Zampieri P, et al: Leksell gamma knife radiosurgery for cerebral arteriovenous malformations in pediatric patients. **Childs Nerv Syst** **21**:301–308, 2005
- Ogilvy CS, Stieg PE, Awad I, Brown RD Jr, Kondziolka D, Rosenwasser R, et al: AHA Scientific Statement: Recommendations for the management of intracranial arteriovenous malformations: a statement for healthcare professionals from a special writing group of the Stroke Council, American Stroke Association. **Stroke** **32**:1458–1471, 2001
- Pan DHC, Kuo YH, Guo WY, Chung WY, Wu HM, Liu KD, et al: Gamma Knife surgery for cerebral arteriovenous malformations in children: a 13-year experience. **J Neurosurg Pediatr** **1**:296–304, 2008
- Pollock BE, Flickinger JC: Modification of the radiosurgery-based arteriovenous malformation grading system. **Neurosurgery** **63**:239–243, 2008
- Reyns N, Blond S, Gauvrit JY, Touzet G, Coche B, Pruvo JP, et al: Role of radiosurgery in the management of cerebral arteriovenous malformations in the pediatric age group: data from a 100-patient series. **Neurosurgery** **60**:268–276, 2007
- Shin M, Kawamoto S, Kurita H, Tago M, Sasaki T, Morita A, et al: Retrospective analysis of a 10-year experience of stereotactic radio surgery for arteriovenous malformations in children and adolescents. **J Neurosurg** **97**:779–784, 2002
- Skjøth-Rasmussen J, Obbekjær T, Birkeland P, Hauerberg J, Juhler M: Multimodality treatment approach in children with cerebral arteriovenous malformation—a survey in the Danish population. **Childs Nerv Syst** **28**:587–592, 2012
- Smyth MD, Sneed PK, Ciricillo SF, Edwards MS, Wara WM,

## Radiosurgery for pediatric AVMs

- Larson DA, et al: Stereotactic radiosurgery for pediatric intracranial arteriovenous malformations: the University of California at San Francisco experience. **J Neurosurg** **97**:48–55, 2002
27. Tanaka T, Kobayashi T, Kida Y, Oyama H, Niwa M: Comparison between adult and pediatric arteriovenous malformations treated by Gamma Knife radiosurgery. **Stereotact Funct Neurosurg** **66 (Suppl 1)**:288–295, 1996
28. Yamamoto M, Jimbo M, Ide M, Tanaka N, Lindquist C, Steiner L: Long-term follow-up of radiosurgically treated arteriovenous malformations in children: report of nine cases. **Surg Neurol** **38**:95–100, 1992
29. Yen CP, Monteith SJ, Nguyen JH, Rainey J, Schlesinger DJ, Sheehan JP: Gamma Knife surgery for arteriovenous malformations in children. Clinical article. **J Neurosurg Pediatr** **6**:426–434, 2010
30. Yeon JY, Shin HJ, Kim JS, Hong SC, Lee JI: Clinico-radiological outcomes following gamma knife radiosurgery for pediatric arteriovenous malformations. **Childs Nerv Syst** **27**:1109–1119, 2011
31. Zabel-du Bois A, Milker-Zabel S, Huber P, Schlegel W, Debus J: Pediatric cerebral arteriovenous malformations: the role of stereotactic linac-based radiosurgery. **Int J Radiat Oncol Biol Phys** **65**:1206–1211, 2006
32. Zadeh G, Andrade-Souza YM, Tsao MN, Scora D, Armstrong D, Humphreys R, et al: Pediatric arteriovenous malformation: University of Toronto experience using stereotactic radiosurgery. **Childs Nerv Syst** **23**:195–199, 2007

---

Manuscript submitted July 24, 2013.

Accepted March 13, 2014.

Portions of this work were presented in electronic poster format at the Joint AANS/CNS Cerebrovascular Section Annual Meeting, New Orleans, LA, January 30–31, 2012.

Please include this information when citing this paper: published online April 25, 2014; DOI: 10.3171/2014.3.PEDS13381.

*Address correspondence to:* Nalin Gupta, M.D., Ph.D., 505 Parnassus Ave., M-779, San Francisco, CA 94143-0112. email: GuptaN@neurosurg.ucsf.edu.