

UC Irvine

UC Irvine Previously Published Works

Title

Novel valosin-containing protein mutations associated with multisystem proteinopathy.

Permalink

<https://escholarship.org/uc/item/4wq370n6>

Journal

Neuromuscular disorders : NMD, 28(6)

ISSN

0960-8966

Authors

Al-Tahan, Sejad
Al-Obeidi, Ebaa
Yoshioka, Hiroshi
[et al.](#)

Publication Date

2018-06-01

DOI

10.1016/j.nmd.2018.04.007

Copyright Information

This work is made available under the terms of a Creative Commons Attribution License, available at <https://creativecommons.org/licenses/by/4.0/>

Peer reviewed

Novel valosin-containing protein mutations associated with multisystem proteinopathy

Sejad Al-Tahan^a, Ebaa Al-Obeidi^a, Hiroshi Yoshioka^b, Anita Lakatos^a, Lan Weiss^a, Marjorie Grafe^c, Johanna Palmio^d, Matt Wicklund^e, Yadollah Harati^f, Molly Omizo^g, Bjarne Udd^{d,h,i}, Virginia Kimonis^{a,*}

^a Division of Genetics and Genomic Medicine, Department of Pediatrics, University of California, Irvine, CA

^b Department of Radiological Sciences, University of California, Irvine, CA

^c Department of Pathology, Oregon Health and Science University, Portland, OR

^d Neuromuscular Research Center, Tampere University and University Hospital, Neurology, Tampere, Finland

^e Department of Neurology, University of Colorado School of Medicine, Aurora, CO

^f Department of Neurology, Baylor College of Medicine, Houston, TX

^g Deschutes Osteoporosis Center, Bend, OR

^h Folkhälsan Institute of Genetics and the Department of Medical Genetics, Haartman Institute, University of Helsinki, Helsinki, Finland

ⁱ Neurology Department, Vasa Central Hospital, Vasa, Finland

Received 17 January 2018; received in revised form 28 March 2018; accepted 10 April 2018

Abstract

Over fifty missense mutations in the gene coding for valosin-containing protein (VCP) are associated with a unique autosomal dominant adult-onset progressive disease associated with combinations of proximo-distal inclusion body myopathy (IBM), Paget's disease of bone (PDB), frontotemporal dementia (FTD), and amyotrophic lateral sclerosis (ALS). We report the clinical, histological, and molecular findings in four new patients/families carrying novel VCP mutations: c.474 G > A (p.M158I); c.478 G > C (p.A160P); c.383G > C (p.G128A); and c.382G > T (p.G128C). Clinical features included myopathy, PDB, ALS and Parkinson's disease though frontotemporal dementia was not an associated feature in these families. One of the patients was noted to have severe manifestations of PDB and was suspected of having neoplasia. There were wide inter- and intra-familial variations making genotype-phenotype correlations difficult between the novel mutations and frequency or age of onset of IBM, PDB, FTD, ALS and Parkinson's disease. Increasing awareness of the full spectrum of clinical presentations will improve diagnosis of VCP-related diseases and thus proactively manage or prevent associated clinical features such as PDB.

© 2018 Published by Elsevier B.V.

Keywords: VCP; p97; Inclusion body myopathy; Paget's disease of bone; Parkinson's disease; Novel VCP mutations

1. Introduction

Inclusion body myopathy associated with Paget's disease of bone and frontotemporal dementia (IBMPFD) or multisystem proteinopathy is an adult-onset progressive, autosomal dominant inherited, ultimately lethal disease caused by heterozygous missense mutations in valosin-containing protein (VCP) [1,2]. The disease involves degeneration of three main organ systems: muscle, bone, and brain. As awareness increases, we are realizing that VCP disease is not as rare as previously considered.

1.1. Pathology of IBMPFD

Inclusion body myopathy is characterized by progressive weakness and atrophy of skeletal muscles of pelvic and shoulder girdle muscles [3,4], though distal myopathy has been reported [5]. Characteristic histological findings include cytoplasmic rimmed vacuoles containing some of the proteins that aggregate in the brains of patients with neurodegenerative diseases: tau, amyloid, and TDP-43 (TAR DNA binding protein 43) [6]. Ultimately, patients die from respiratory failure, cardiomyopathy and cardiac failure [2,7].

VCP disease has also been associated with a spectrum of other diseases including amyotrophic lateral sclerosis (ALS) [8], hereditary spastic paraplegia [9], and Charcot-Marie-Tooth Type 2 disease [10]. Other common disorders that have a clinical overlap with VCP disease include facioscapulohumeral

* Corresponding author. Division of Genetics and Genomic Medicine, Department of Pediatrics, University of California, Irvine, California.

E-mail address: vkimonis@uci.edu (V. Kimonis).

muscular dystrophy (FSHD), Limb-girdle muscular dystrophy (LGMD), scapulo-peroneal muscular dystrophy (SPMD), sporadic inclusion body myositis (sIBM), myofibrillar myopathies, and distal myopathy/oculopharyngeal muscular dystrophy [4].

Paget's disease of bone (PDB) is a unique skeletal disease caused by an imbalance between overactive osteoclast and osteoblast functions. The result is a gain in bone mass, but the new bone is disorganized, weak, and prone to fractures. Typical radiological findings of PDB include coarse trabeculation, cortical thickening and spotty sclerosis. Clinical features include bone pain, bone enlargement, fractures, hearing loss due to defective bone remodeling in the middle and inner ear, and arthritis. Rare complications include kidney stones, osteosarcoma and high-output heart failure due to the formation of arteriovenous shunts in bone [11].

Frontotemporal dementia (FTD) is typically diagnosed in people 45–64 years old [12], however in VCP disease it can be associated with an earlier age of onset. Degeneration and atrophy of the frontal and temporal lobes of the brain result in changes in personality and progressive loss of language. Brain histology in patients with IBMPFD affected by FTD is characterized by gliosis, spongiosis, and neuronal intranuclear inclusions [13]. TDP-43 aggregates are commonly associated with VCP-associated FTD as well as in amyotrophic lateral sclerosis (ALS) [6,14,15]. TDP-43 is a DNA/RNA-binding protein involved in various cellular processes including RNA transcription and splicing [16–18]. We have previously shown that the presence of one or two APOE4 alleles is associated with an increased risk of developing FTD in patients with VCP mutations [19].

1.2. Mutations of VCP

VCP has four domains: an N-terminal ubiquitin binding domain, two ATPase domains (D1 and D2), and a C-terminal region [20]. Valosin is a 25 amino acid peptide named after its N-terminal valine and C-terminal tyrosine, and was originally isolated from porcine gut [21]. That peptide sequence is present in valosin-containing protein, which is a highly abundant ATPase found in all cells where it interacts with various adaptor proteins to carry out many essential cellular processes. Among them are endoplasmic reticulum-associated degradation [22] and formation [23], transcription factor processing [24], nuclear envelope reconstruction [25], membrane fusion [26], post mitotic golgi reassembly [27], spindle disassembly [28], and cell cycle control [29]. Several of these activities are associated with the ubiquitin-proteasome system in which VCP helps deliver ubiquitylated substrates to the 26S proteasome for degradation [30]. VCP's role in protein degradation and autophagy is implicated in the pathogenesis of IBMPFD, and may account for the protein aggregations/cytoplasmic inclusions observed in muscle, bone, and neuronal tissue [1,30]. Currently, over 50 mutations have been identified in VCP disease (Fig. 7A) [31–36]. Since our previous report of phenotype-genotype correlations [2], several other reports have expanded the phenotypic spectrum associated with VCP mutations to include Charcot-Marie-Tooth type 2

disease (CMT2) [10,37], Parkinson's disease [17], and anal incontinence [38]. In this report, we describe the clinical features in four patients/families with multisystem proteinopathy associated with novel VCP gene mutations.

2. Case report

Informed consent was obtained for this study as approved by University of California, Irvine Institutional Review Board. Medical records of individuals were reviewed for medical complications, progress of disease, and studies of lab values, radiology, electromyograms, nerve conduction studies, and muscle biopsies. Clinical features of individuals from the unrelated families are summarized in Table 1.

2.1. Family 1 (c.474 G > A VCP; p.M158I)

The proband (IV:1) (Fig. 1A) is a 44-year-old male who initially developed progressive fatigue, low back pain, and bilateral hip pain in his late 20's to early 30's. He sought medical care at age 39 years when he was unable to walk more than a few minutes without resting. He was evaluated and tested for facioscapulohumeral muscular dystrophy (FSHD) however molecular testing for a deletion on chromosome 4q35 was negative. At age 42 years he started using a walker, and two years later started using a power chair. Co-morbidities included hypertension, type 2 diabetes mellitus, obstructive sleep apnea, and urinary and fecal incontinence. On physical exam, upper extremity strength testing revealed asymmetric periscapular weakness worse on the right, and Medical Research Council (MRC) scale 4/5 of the external rotator, biceps and triceps bilaterally, with normal grip strength. Lower extremity strength testing revealed ability to toe walk but not heel walk, bilateral dorsiflexor weakness right 4/5 and MRC 4 + /5 in hip and knee flexion and extension. Physical exam also revealed mild sensory loss over distribution of the left lateral femoral cutaneous nerve and absent to reduced deep tendon reflexes in the different muscle groups. He was able to repeat and name objects and follow complex commands without difficulty, had memory intact for recent and remote events, and had fluent speech. His frontal behavioral inventory (FBI) was not suggestive of FTD. Electromyogram testing of the left dorsal interossei, extensor carpi radialis, bicep, tibialis anterior, vastus medialis, and rectus femoris, showed short duration, low amplitude motor unit potentials with an early recruitment pattern in selected muscles, and electrophysiologic evidence of a myopathic process with normal nerve conduction testing. Echocardiogram did not reveal cardiomyopathy. Muscle biopsy of the right deltoid at 39 years revealed atrophy of myofibers without evidence of inflammation or rimmed vacuoles. Histochemistry revealed unremarkable stains for trichrome, NADH, SDH, ATPase (pH 9.4 and 4.5), cytochrome oxidase, PAS, Oil red O and acid and alkaline phosphatase. Immunohistochemistry interestingly revealed that dystrophin C was completely absent and dystrophin N was multifocally absent, however all other stains including spectrin, sarcoglycans, merosin, caveolin, dysferlin, emerin, Collagen IV, VI, and Laminin β 1 were unremarkable. EM did not reveal any

Table 1
Clinical and laboratory data for affected individuals.

Case	Age (years)	Sex	PDB	Myopathy	Age of Onset, PDB (years)	Age of Onset, Myopathy (years)	ALP (IU/L)	CK (IU/L)	EMG & NCS	FH of Parkinson's	FH of ALS	Muscle Biopsy
Family I, patient II:1 (p.M158I)	45	M	+	+	39	39	243	216	Neurogenic & myogenic features	–	+	Atrophy without rimmed vacuoles
Family II, patient III:1 (p.A160P)	65	M	+	+	52	45	230	591	Myogenic	+	–	Size variability without rimmed vacuoles
Family III, patient III:1 (p.G128A)	57	M	+	+	50	40	223	464	Myogenic	+	+	Size variability, few rimmed vacuoles, and inclusion bodies
Family IV, patient II:1 (p.G128C)	55	M	–	+	–	35	74	350	Myogenic	–	–	Dystrophic changes with few rimmed vacuoles
Mean (range)	55.5	4 M	75%	100%	47.0	39.8	192.5	405.3	100% myogenic; 25% neurogenic	50%	50%	–

PDB Paget's disease of bone, ALP alkaline phosphatase (44–147 IU/L), CPK total creatinine phosphokinase (NL 22 to 198 U/L), EMG electromyography, NCS nerve conduction study, FH family history, ALS amyotrophic lateral sclerosis.

subsarcolemmal deposits, no vacuolation and myofibrillar apparatus and vasculature appeared unremarkable. Tissue was poorly preserved for additional detailed analysis.

Plain radiograph of the spine was done for loss of height. Cervical spine radiograph revealed compression deformity of C6 with approximately 80% loss of height. There was also

evidence of a prior healed severe compression fracture of L2. Because of concern for bone neoplasm a computed tomography (CT) was obtained. Cervical CT revealed a burst fracture of C6 vertebral body (Fig. 2A), and osteolytic infiltrates involving the lateral masses, and spinous processes. Cortical retropulsion compromised the cervical spinal canal. Lumbar CT (Fig. 2C)

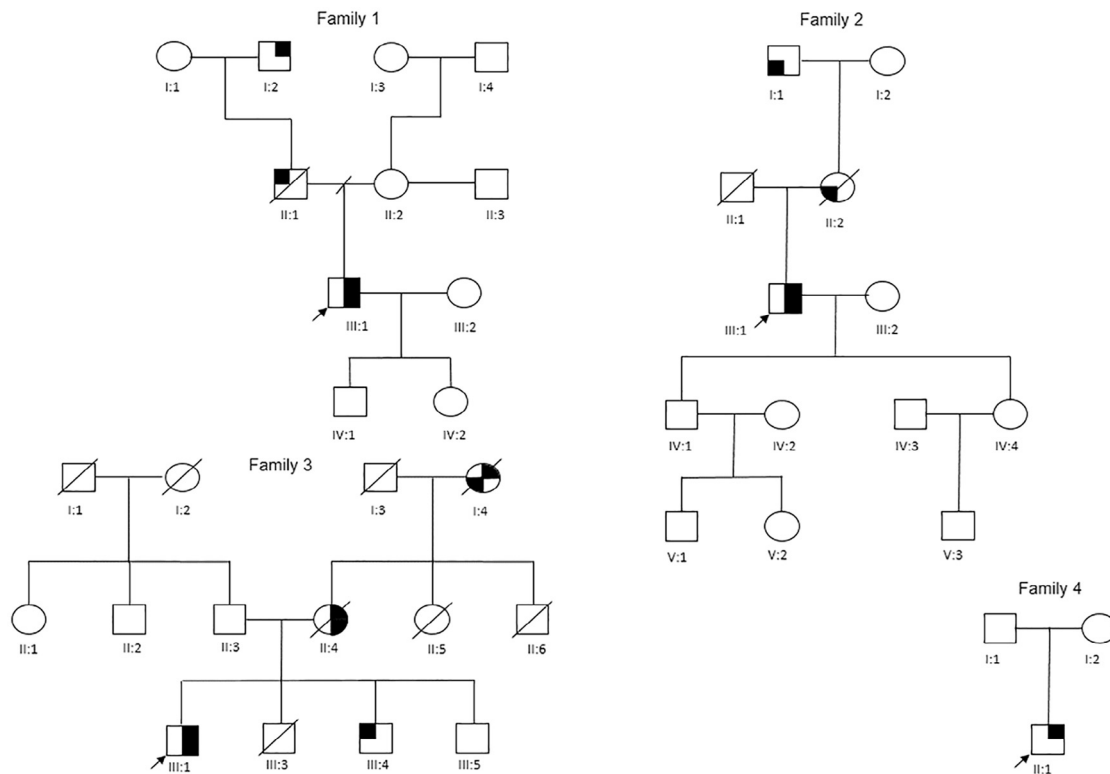


Fig. 1. Pedigree of families 1–4. Arrow indicates proband. The filled upper right quadrant indicates myopathy, filled right lower quadrant indicates Paget's disease of bone, filled upper left indicates amyotrophic lateral sclerosis, and filled lower left indicates Parkinson's disease.

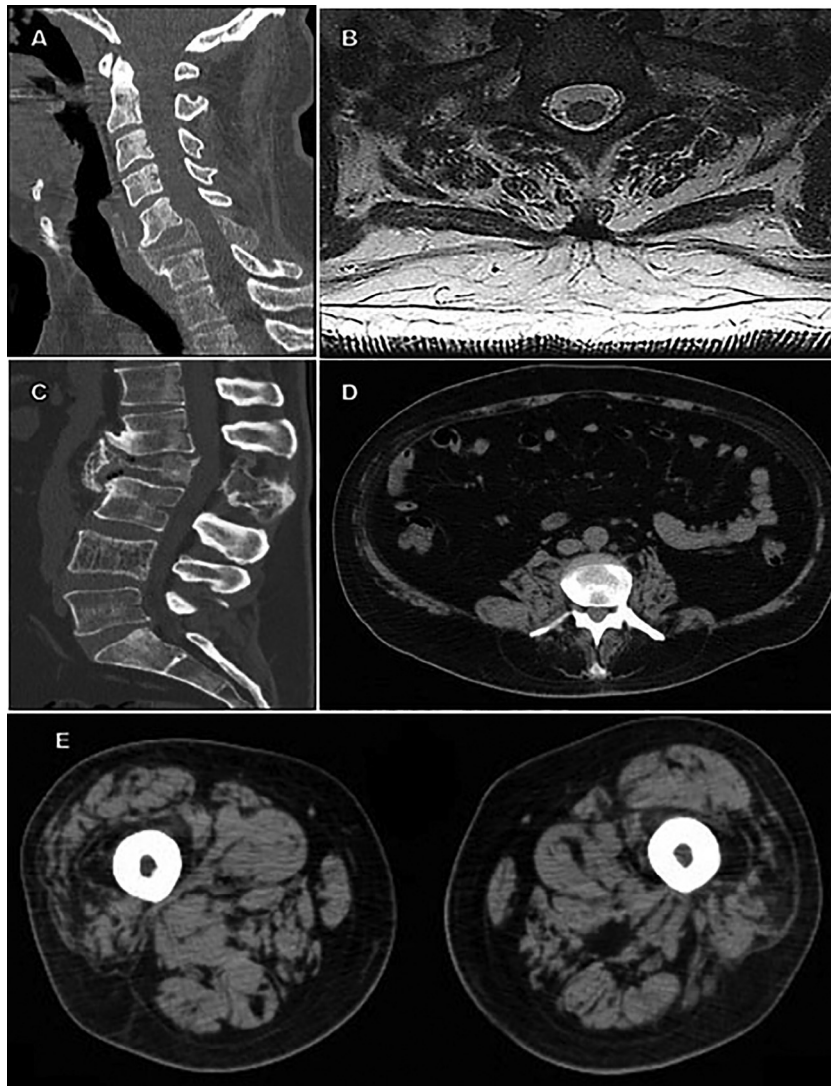


Fig. 2. Imaging studies of the proband (Individual III:1) of family 1. (A) Computed tomography (CT) of cervical spine revealed a compression deformity and fracture of C6 with approximately 80% loss of height. (B) Cervical magnetic resonance imaging (MRI) revealed atrophy of the lower cervical paraspinal muscles. (C) Lumbar CT revealed a pathological fracture of the L2 vertebral body with approximately 80%–90% loss of height. (D) Severe atrophy of the lumbar paraspinal muscles and (E) moderate atrophy of thigh muscle groups was noted.

revealed a pathological fracture of the L2 vertebral body with approximately 80%–90% loss of height. There was mild retropulsion compromising the lumbar spinal canal at the L2 vertebral body level. Trabecular thickening of the L4 vertebral body with mild loss in height was noted. There was also diffuse coarsening, mixed sclerotic and lytic changes in the right iliac bone considered to be Paget's disease versus malignancy.

MRI confirmed the CT finding showing severe C6–C7 foraminal stenosis with mass effect observed on the spinal cord and both exiting nerves of the foramina and additionally revealed atrophy of the lower cervical muscles (Fig. 2B). Severe atrophy of the lumbar paraspinal muscles (Fig. 2D) and thigh muscle groups was noted (Fig. 2E). A PET scan was completed to stage suspected lymphoma. Imaging revealed multiple areas of mild to moderate increased metabolic activity within bony structures including C6, T4, L2, and L3 vertebral bodies and multifocal areas of abnormality within the pelvis. These areas

demonstrated areas of prominent bony trabecular thickening with patchy areas of both sclerosis and lucency.

Bone biopsy for suspected malignancy of L2 showed irregular bony trabeculae with prominent osteoclastic and osteoblastic activity with areas of new bone formation. There was no evidence of a neoplastic process and these results were considered most suggestive of Paget's disease associated with an elevated alkaline phosphatase.

Genetic testing for VCP was done because of the combination of PDB and myopathy. He was found to have a novel c.474 G > A VCP mutation, resulting in a change of the conserved methionine to isoleucine at amino acid position 158 (p.M158I) (Fig. 7).

His family history was significant for his grandfather (I:2) and father (II:1) dying of ALS at an unknown age, both of whom were suspected to carry the VCP gene mutation. There were no other relatives reported who manifested features of the

familial disease. The ethnic background included mixed Dutch, Italian, Portuguese, and English.

2.2. Family 2 (c.478 G > C; p.A160P)

The proband is a 66-year-old male (III:1) (Fig. 1B) who was diagnosed with limb-girdle muscular dystrophy in his mid-forties. He experienced loss of core muscle strength, difficulty lifting his arms above his head, using the stairs, getting out of a chair, and moving in bed. He has required a power chair since age 63 years. He reports shortness of breath when climbing stairs and has mild obstructive sleep apnea. He previously smoked 1 pack per day for 28 years. Physical examination was significant for camptomelia and scapular winging. Strength testing was significant for MRC right 4 + /5 shoulder abductor, 5–/5 elbow extensor, 4 + /5 hip flexion, 5–/5 ankle dorsiflexion, and left 4 + /5 shoulder abductor, 5–/5 elbow extensor, 4 + /5 hip flexors, and ankle dorsiflexion 5–/5. Reflex testing of the triceps and patella were 1/4 bilaterally and his ankle jerk reflex was absent bilaterally. Electromyography testing was completed at age 50 years testing the right tibialis anterior, vastus medialis, vastus lateralis, tensor fascia lata, iliopsoas, lumbar paraspinal muscles, deltoid, and left vastus lateralis and tibialis anterior. There was additional nerve conduction testing of the right and left peroneal and tibial nerves and sensory nerve testing of the right and left sural nerves. Testing revealed myopathic changes without neurogenic changes. His FBI exam nor routine clinical exam was not suggestive of FTD. He also developed a pulmonary embolus at age 50 years arising from a deep vein thrombus in his leg. He developed pain in his hips and lower back at age 52 years. Bone scan revealed hot spots in multiple bones including T9, L3 spine, right scapula, bilateral femurs, and left humerus suggestive of PDB. He has been treated with alendronate sodium and more recently he has been treated with residronate successfully.

Muscle biopsy at age 57 years from his left quadriceps revealed mild myofiber size variability without evidence of inflammation or rimmed vacuoles. ATPase preparations at pH 4.3, 4.6, and 9.5 demonstrated a predominance of type II myofibers. NADH-TR staining revealed evidence of disruption of the intermyofibrillar network in the form of scattered target-like fibers suggestive of a primary neurogenic process. There was no evidence of increase in neutral lipid stores on Oil Red O stained preparations. Routine immunohistochemistry staining was unremarkable. Echocardiogram revealed mitral valve prolapse, left atrial enlargement, but no cardiomyopathy. Other medical problems included type 2 diabetes mellitus, macular degeneration, asthma, COPD, hypothyroidism, allergic rhinitis, colon polyps, and vitamin D and B12 deficiencies – common co-morbidities in the general population.

On reviewing the family history (Fig. 1B), his mother (II:2) had camptomelia related to Parkinson's disease. His maternal grandfather (I:1) also had Parkinson's in his late forties, both suspected to have VCP disease. There was no other pertinent family history. The ethnic background is Austro-Hungarian.

In view of his clinical spectrum of myopathy and PDB, genetic testing for VCP at age 64 years led to a diagnosis of VCP disease. He was identified with a novel c.478 G > C mutation

which resulted in a protein change in the conserved alanine to proline at position 160 (p.A160P) in the VCP gene (Fig. 7).

2.3. Family 3 (c.383G > C; p.G128A)

The proband (III:1) (Fig. 1C) a 57-year-old male reported difficulty raising his hands over his head since childhood. He recalls that at age 16 years he broke his clavicle in a motorcycle accident because he did not have enough strength in his arms and shoulders to turn his bike and avoid being hit by a car. He developed noticeable proximal lower extremity weakness and difficulty climbing stairs beginning at age 40 years. Muscle cramps, muscle twitching, numbness in feet and constant back pain were also reported. On physical examination he had difficulty walking on his toes and was noted to have atrophy of shoulder girdle muscles and bilateral scapular winging. Routine clinical exam revealed an MRC scale of 4+ of the deltoids, triceps and iliopsoas, 5– of the biceps, and 5/5 of the other muscle groups. Tendon reflexes was 2 + /4. He was alert and oriented in time and place and routine testing including FBI testing was not suggestive of FTD. Laboratory abnormalities include an elevated CPK, liver enzymes (ALT and AST) and an elevated ALP (Table 1).

EMG showed neurogenic and myopathic changes in several muscles of his right upper and lower extremities. Muscle biopsy at age 52 years also showed features of denervation–reinnervation and inclusion body myopathy. Histology revealed marked variation in fiber size and shape with many angular fibers in groups and scattered, several fibers with rimmed vacuoles, few fibers with multiple intracytoplasmic eosinophilic inclusions, and no abnormalities on routine staining (Fig. 3), except for a few fibers that were devoid of cytochrome oxidase staining. In particular there were no rubbed out fibers or significantly increased amount of COX negative or SDH positive fibers. Lumbosacral spine radiographs at 53 years

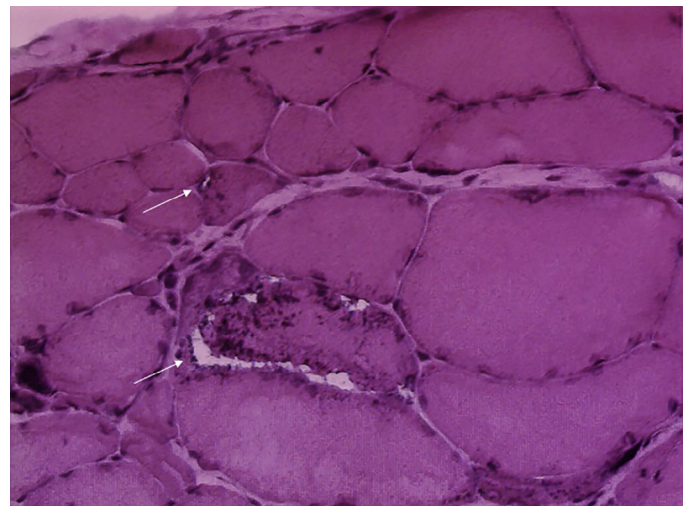


Fig. 3. Muscle biopsy of proband (individual III:1) family 2 from left quadriceps at age of 62 years. Hematoxylin and eosin (H&E) stains showed marked variation in fiber size and shape with many angular fibers, some rimmed vacuoles (arrows), few fibers with multiple intracytoplasmic eosinophilic inclusions, and minimal inflammation.

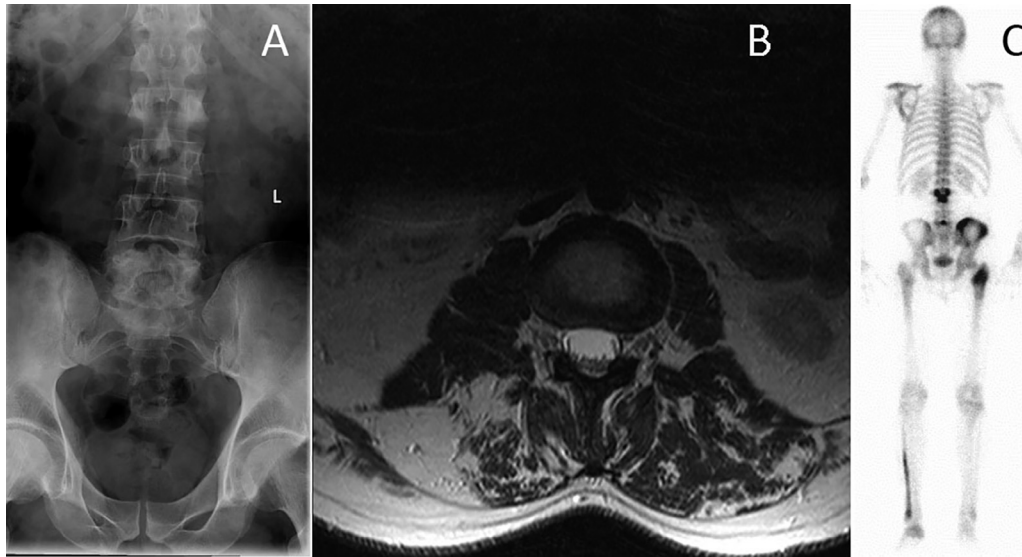


Fig. 4. Radiology of proband (individual III:1) from family 3. (A) Lumbar X-ray reveals Paget disease of L2 and L5. (B) MRI of the lumbar spine revealed fatty infiltration of the posterior paraspinal muscles. (C) Bone scan at age 49 years reveals hot spots suggestive of Paget disease of bone in skull, left scapular, L2, L5, the right ilium, the proximal right proximal femur, the left fibula, and left foot.

revealed sclerosis involving the posterior elements of L2 and L5 (Fig. 4A). X-ray of the tibia and fibula show a mild abnormality in the left fibula consistent with PDB. Skull X-ray showed patchy lytic areas in the calvarium bilaterally mostly involving the vertex but some noted to be present anteriorly. Pelvic X-ray view reveals coarse trabecular pattern and abnormal cortical thickening of the right ilium and right proximal femur. MRI of the cervical, thoracic and lumbar spine revealed degenerative changes and, importantly, fatty infiltration of the paraspinal muscle (Fig. 4B). Bone scan at age 49 years revealed elevated tracer activity in skull, left scapular, L2, L5, the right anterior ilium, the proximal right femur, the left fibula, and left foot consistent with his diagnosis of PDB (Fig. 4C).

Other clinical conditions included fatty infiltration of the liver, hypothyroidism, B12 deficiency and a torn anterior cruciate ligament. Thyroid scan revealed left thyroid nodule.

On review of his family history, his mother (II:4) had PDB and muscle weakness, loss of muscle mass, trouble speaking and swallowing suggestive of ALS and passed away at age 67 years. His maternal grandmother (I:4) had muscle weakness beginning at age 20 years, was diagnosed with PD at age 30 years and died at age 54 years. He has three brothers, one of whom age 48 years has been diagnosed with ALS, all these relatives were suspected of having VCP disease. The ethnic background is mixed Caucasian.

VCP myopathy was suspected because of his clinical features of muscle weakness, muscle biopsy findings of rimmed vacuoles, and PDB. Genetic testing revealed a c.383G > C mutation which resulted in a change of a conserved glycine at position 128 to alanine (p.G128A).

2.4. Family 4 (c.382G > T; p.G128C)

The proband (II:1) (Fig. 1D) is a 55-year-old male of Finnish ancestry whose first symptoms were ankle weakness occurring

at age 35 years. Within 2–3 years, proximal lower limb weakness was evident, with falls, and difficulty climbing stairs. He subsequently developed proximal upper limb weakness from age 40 years progressing to wheelchair use at the age of 50 years. On examinations at the age of 55 years he had extensive muscular atrophy of the proximal muscles with marked scapular winging and distal weakness resulting in testing for FSHD which was negative. Proximal muscle strength was at an MRC scale of 1–2/5 in all muscle groups except for elbow extension (4/5) and hip adduction (3–4/5). No facial weakness was noted and routine clinical exam including FBI exam was not suggestive of FTD. CK was mildly elevated at 350 IU/L, EMG was clearly myopathic. A biopsy of the anterior tibial muscle at the age of 38 years showed dystrophic changes with rimmed vacuoles and a few cytoplasmic bodies. Vacuolated fibers showed sarcoplasmic aggregates without myonuclear aggregates with SMI-31, TDP-43 and p62 antibodies (Fig. 5).

Muscle MRI (Fig. 6) showed extensive dystrophic fatty replacement with minimal sparing of the rectus femoris. The patient did not have features of FTD or PDB.

Review of family history was negative and parents lived to an advanced age without evident bone or brain disease, however were not available for DNA segregation studies.

Genetic testing via Sanger sequencing revealed a novel c.382G > T VCP mutation causing a change of a conserved glycine at position 128 to cysteine (p.G128C) thus confirming the diagnosis of VCP myopathy.

Table 1 summarizes the clinical features of the affected individuals in the four families with novel mutations. Of note, most individuals were diagnosed because of the coexistence of the two most common features: myopathy ± rimmed vacuoles and/or PDB, though family 4 did not have associated PDB but was diagnosed because of the muscle biopsy findings. Three of the four families had a family history of ALS and/or Parkinson's disease.

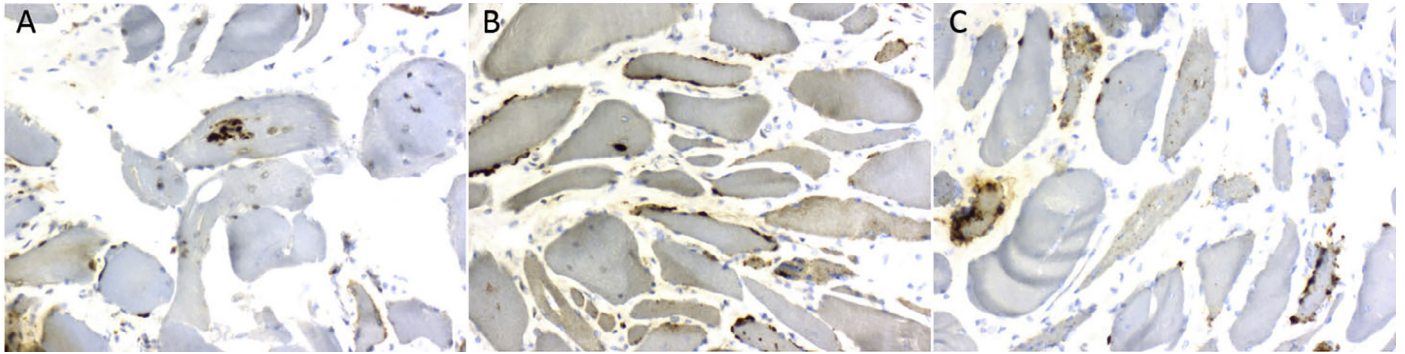


Fig. 5. Muscle biopsy from tibialis anterior muscle from patient 4 at the age of 38 years. Dystrophic features including atrophic fibers, excess of fat and fibrosis as well as numerous rimmed vacuoles. Vacuolated fibers showed aggregates with (A) SMI-31, (B) TDP-43 and (C) p62 antibodies.

In addition, we performed an *in silico* analysis to evaluate the impact of these mutations on protein function as the result of a single codon change. We used several prediction tools due to reported differences in tool performance with variable outcomes [39,40]. Table 2 summarizes the variable mutation prediction for the four novel mutations identified in the families [41–45]. Despite the inconsistencies of *in silico* prediction, all of these mutations were associated with a distinct disease phenotype segregating the families, and therefore considered causative disease mutations rather than simple polymorphisms.

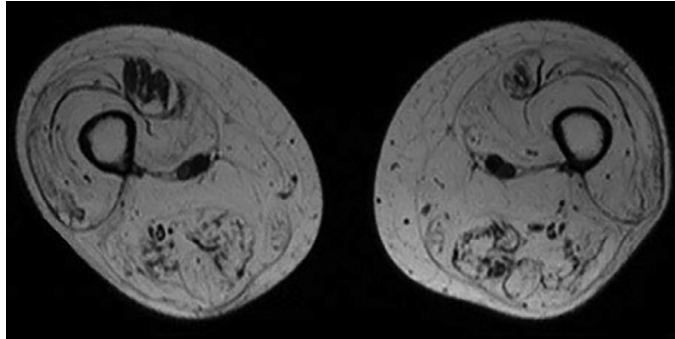


Fig. 6. Radiology of patient (individual II:1) from family 4. MRI T1 imaging of the patient shows significant fatty replacement of all thigh muscles.

3. Discussion

Herein we report patients with four novel mutations to expand the genotypic spectrum of VCP disease most commonly characterized by not only progressive limb-girdle IBM, PDB, FTD, but also ALS and Parkinson's disease.

Two of the novel mutations c.383G > C, and c.382G > T, affecting p.G128 located on exon 4, appear to be a hot spot locus. The remaining two mutations, c.474 G > A, p.M158I and c.478G > C, A160P are located in exon 5 which is involved in ubiquitin and cofactor binding. The p.Ala160 residue is conserved among VCP proteins from human to fish, and substitutions of nearby amino acids (e.g., p.Arg155His, p.Gly157Arg, and p.Arg159His) are reported to be pathogenic and causative for this disorder [1,46,47].

Both of these exons are part of the N-terminal domain (NTD) (Fig. 7). Proper function of the VCP protein has been thought to rest in the balanced binding to its various cofactors [48] which the NTD is likely involved in Schubert and Buchberger and Yeung et al's studies [49,50]. A recent study found that mutations of the NTD attenuate small ubiquitin-like modifier (SUMOylation) of VCP which weaken hexamerization during stress [51]. Several residues within the NTD, specifically R155, R159, and R191 are implicated in significant interactions with downstream residues in the D1 domain [52]. Indeed, the D1 domain's primary responsibility

Table 2
Prediction of likely impact of novel variants.

	Family 1	Family 2	Family 3	Family 4
Point Mutation	c.474G > A	c.478G > C	c.383G > C	c.382G > T
Chr:Pos	9:35065350	9:35065346	9:35066734	9:35066734
AA subs	M158I	A160P	G128A	G128C
UMD score	72	84	75	93
UMD Prediction	Prob. Pathogenic	Pathogenic	Pathogenic	Pathogenic
PolyPhen2 Score	0.887	0.001	1	1
PolyPhen2 Prediction	Possibly damaging	Benign	Probably damaging	Probably damaging
SIFT Score	0.37	0.44	0.02	0.01
SIFT Prediction	Tolerated	Tolerated	Damaging	Damaging
Provean Score	-2.98	-0.949	-5.015	-7.644
Provean Prediction	Deleterious	Neutral	Deleterious	Deleterious
Mutation Taster Score	10	27	60	159
Mutation Taster Prediction	Disease Causing	Disease Causing	Disease Causing	Disease Causing

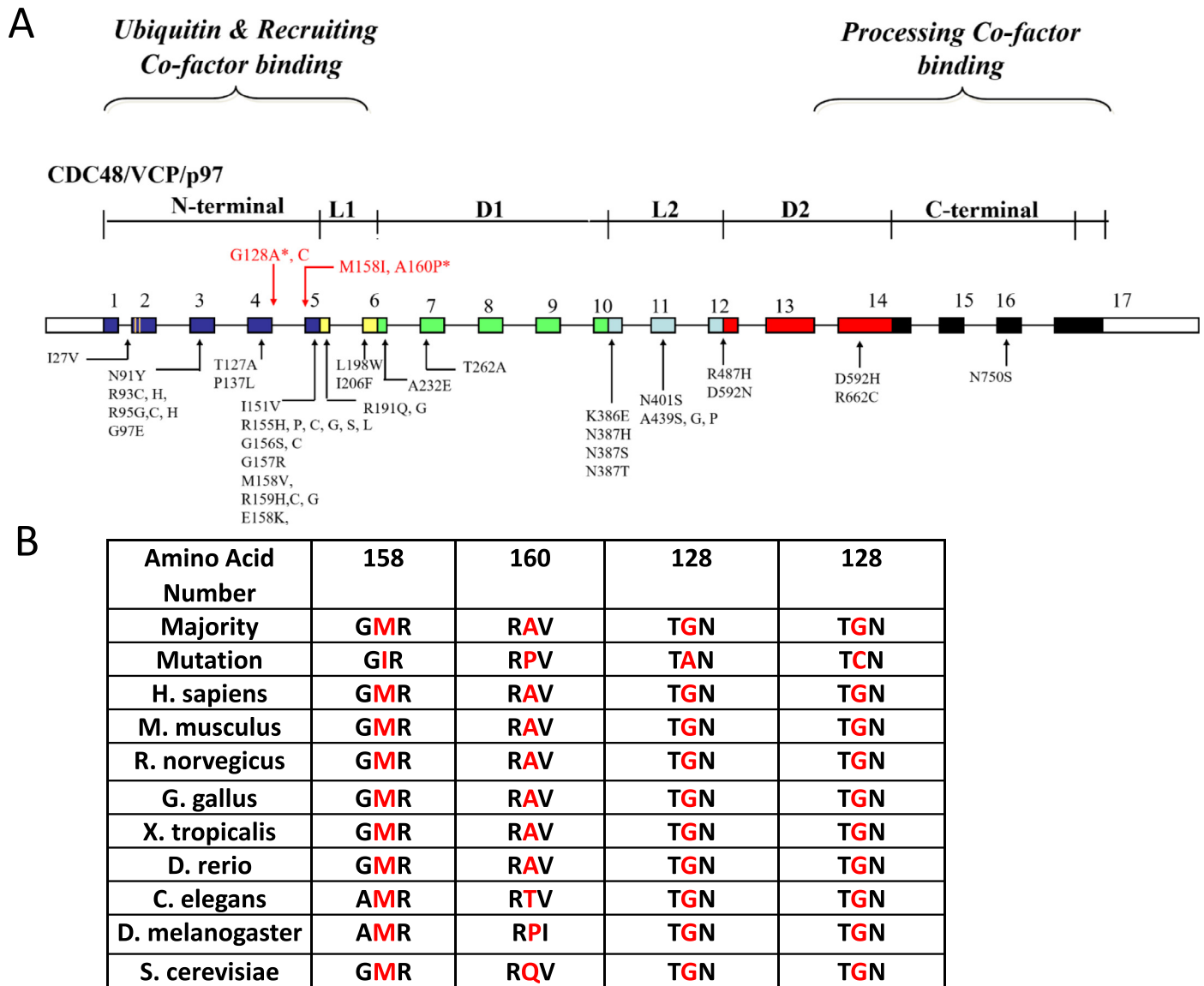


Fig. 7. Known and novel mutations in VCP in individuals. (A) Functional domains and mutations of VCP. Arrows indicate the locations of mutations relative to the exon-intron structure, where the exons are numbered 1–17. The relative positions of the N-terminal domain (CDC48, navy), flexible linker (L1, yellow), first AAA-ATPase domain (D1, green), linker region (L2, light blue), second AAA ATPase domain (D2, red) and C-terminal domain (black) are indicated, and the 5' and 3' untranslated regions are shown in white. Novel mutations are highlighted in red and mutations associated with Parkinson's are indicated by an asterisk (B) Species conservation of amino acid residues mutated in IBMPFD, with mutant residue position highlighted in red.

appears to be hexamerization [53] though the mobility of this domain is also essential for ATP hydrolysis [20]. Although mutated VCP has not been shown to alter gross hexamer formation [54], a possible effect of mutation to the NTD is to attenuate stability of the protein during stress with or without altering affinity to its cofactors. Most symptomatic VCP mutations occur near the NTD highlighting the essential function of this domain (Fig. 7).

Muscle weakness among individuals studied in this report varied from a definite pattern of limb-girdle weakness with mixed distal and proximal limb involvement. EMG results were myopathic in three families with one family showing a mixed myopathic and neurogenic pattern although our patients did not exhibit features of ALS. Previous studies describe 31.2% of

patients having pure myopathic changes while 13.7% having mixed myopathic-neuropathic changes on their EMGs [2]. Pure neurogenic changes may occur with a frequency of 30% [55]. All four individuals in the report had mildly elevated CPK levels as was previously reported by Mehta et al (2013) (CPK level 165.2 ± 149.6 IU/l range IU/L, normal range 22–198 IU/L) [2].

Muscle biopsy results typically included nuclear clumps, angulated fibers, and rimmed vacuoles without amyloid fibrils [56]. The most characteristic finding of rimmed vacuoles was only present in two of the four patients in this report highlighting the phenotypic variability of this disease.

Among our patients three of the families had PDB as a major feature presenting at an average age of 47 years. The most

striking feature was the advanced manifestations of PDB in one patient resulting in collapse of the C6 and L2 vertebral bodies and an extensive workup for a neoplasm because of the lack of awareness of the association of PDB with myopathy. Early treatment could have prevented the severe complications of PDB. Compression fractures in PDB tend to occur with higher frequencies in the lumbar spine [57] with L4/5 as the most commonly affected lumbar vertebrae [58]. Cervical spine involvement is less commonly found. The only presenting symptoms associated with PDB in Families 2 and 3 was bone pain. All three with PDB had elevated alkaline phosphatase (ALP) (average 192.5 IU/L (normal 44–147 IU/L) a simple test permitting early diagnosis and optimal treatment of PDB in VCP disease [4]. Twenty-two percent of patients with PDB are asymptomatic when diagnosed [59], highlighting the benefit of regular screening for PDB with blood ALP and bone scans. Early diagnosis and treatment with long acting bisphosphonates may prevent the severe complications of undetected or untreated PDB such as reduced height, pathologic fractures, and bone deformities [2]. Farpour et al (2012) studied radiological features of PDB in 17 patients with clinical manifestations of the VCP mutation and found evidence of PDB in 10 individuals; skeletal survey included thickening of the calvarium, sclerosis and enlargement of the lumbar vertebrae, pelvis, femurs, and humeri and only one individual had a slightly thickened cervical C5 vertebral body [60]. The severe compression deformity of C6 with approximately 80% loss of height and severe compression fracture of L2 seen in Case 1 and involvement of the fibula and foot in Case 3 are unique in association with VCP disease [60].

Unlike previous reports, none of our patients developed FTD which may be related to their particular genotypes. FTD is reported to affect a third of patients with VCP disease and is typically seen at a mean age of 57 years, thus some of the patients may not be old enough to manifest it [4].

There are now several case reports of patients with VCP disease with Parkinson's disease [5,17,61,62]. Lewy bodies are the pathological hallmark of Parkinson's disease and VCP protein is a known component of the Lewy bodies [63]. Forman et al (2006) [13] described a patient with IBMPFD having Lewy bodies on neuropathological examination though the patient exhibited no signs or symptoms of Parkinson's disease or dementia. The prior case reports and the pathological finding suggest that Parkinson's disease should now be considered as a feature of VCP disease. VCP disease and Parkinson's disease share significant involvement of mitochondrial autophagy, or mitophagy, in their common pathogenesis. Mitophagy is an essential part of cellular quality control, failure of which has been shown to elevate levels of reactive oxygen species, therefore elevating cellular stress levels [64]. VCP interacts with PINK1 and parkin, which are key mitophagy proteins important in the clearance of damaged mitochondria [65–69]. Mutations in these two genes are involved in the etiology of Parkinson's disease in vivo [69].

Urinary and fecal incontinence were reported in the proband in family 1. Fecal incontinence has been reported in association with VCP myopathy in other families secondary to autonomic

dysfunction, therefore these features are considered part of the spectrum of the phenotype associated with VCP disease [38,70].

Although the disease is rare, the enormous intra- and interfamilial variations commonly result in misdiagnosis of many patients with VCP disease as exemplified in the case reports of our cohort. The enormous variation was also highlighted in a recent study portraying a Brazilian family with three first degree members each expressing a unique symptom including myopathy, ALS, and FTD [32]. VCP disease should always be considered in families with members of the families affected by one or more components of the disease: Limb-girdle muscular dystrophy, FSHD, IBM, PDB, FTD, ALS, Parkinson's disease and Alzheimer's disease. Our study furthers the genotypic spectrum of the disease, allowing clinicians to diagnose the disease in patients with the same mutations but varying manifestations. Future studies of VCP disease will identify the underlying mechanism for the wide phenotypic variation and its relationship with related neurological disorders.

Targeted therapies are being developed for several neuromuscular/neurodegenerative disorders. Better understanding of the mechanism will also permit targeted drug therapy for VCP disease. Recently Zhang et al (2017) reported their studies in a drosophila model and indicated that VCP negatively regulates mitofusin, and disease mutations act as hyperactive alleles. They showed that VCP inhibitors NMS-873 and ML240 corrected the mitofusin downregulation, mitochondrial fusion defect, muscle damage and cell death in *Drosophila* and patient fibroblasts [68], and are a promising new treatment for patients. It is therefore important to diagnose patients early in order to prevent complications such as PDB, and permit them to obtain maximal benefit from future targeted therapies.

Acknowledgments

The authors thank the patients, their health care providers, collaborators, and researchers for their generous contribution to this work. We also thank the National Institute of Health (AR AR050236 R01 and R56 to VK), the Institute of Clinical and Translational Science (ICTS), and the University of California for funding and support for the study.

References

- [1] Watts GD, Wymer J, Kovach MJ, Mehta SG, Mumm S, Darvish D, et al. Inclusion body myopathy associated with Paget disease of bone and frontotemporal dementia is caused by mutant valosin-containing protein. *Nat Genet* 2004;36:377–81.
- [2] Mehta SG, Khare M, Ramani R, Watts GD, Simon M, Osann KE, et al. Genotype-phenotype studies of VCP-associated inclusion body myopathy with Paget disease of bone and/or frontotemporal dementia. *Clin Genet* 2013;83:422–31.
- [3] Kimonis VE, Kovach MJ, Waggoner B, Leal S, Salam A, Rimer L, et al. Clinical and molecular studies in a unique family with autosomal dominant limb-girdle muscular dystrophy and Paget disease of bone. *Genet Med* 2000;2:232–41.
- [4] Kimonis VE, Mehta SG, Fulchiero EC, Thomasova D, Pasquali M, Boycott K, et al. Clinical studies in familial VCP myopathy associated with Paget disease of bone and frontotemporal dementia. *Am J Med Genet A* 2008;146A:745–57.

- [5] Palmio J, Sandell S, Suominen T, Penttila S, Raheem O, Hackman P, et al. Distinct distal myopathy phenotype caused by VCP gene mutation in a Finnish family. *Neuromuscul Disord* 2011;21:551–5.
- [6] Weihl CC, Temiz P, Miller SE, Watts G, Smith C, Forman M, et al. TDP-43 accumulation in inclusion body myopathy muscle suggests a common pathogenic mechanism with frontotemporal dementia. *J Neurol Neurosurg Psychiatry* 2008;79:1186–9.
- [7] Nalbandian A, Donkervoort S, Dec E, Badadani M, Katheria V, Rana P, et al. The multiple faces of valosin-containing protein-associated diseases: inclusion body myopathy with Paget's disease of bone, frontotemporal dementia, and amyotrophic lateral sclerosis. *J Mol Neurosci* 2011;45:522–31.
- [8] Johnson JO, Mandrioli J, Benatar M, Abramzon Y, Van Deerlin VM, Trojanowski JQ, et al. Exome sequencing reveals VCP mutations as a cause of familial ALS. *Neuron* 2010;68:857–64.
- [9] van de Warrenburg BP, Schouten MI, de Bot ST, Vermeer S, Meijer R, Pennings M, et al. Clinical exome sequencing for cerebellar ataxia and spastic paraplegia uncovers novel gene-disease associations and unanticipated rare disorders. *Eur J Hum Genet* 2016.
- [10] Gonzalez MA, Feely SM, Speziani F, Strickland AV, Danzi M, Bacon C, et al. A novel mutation in VCP causes Charcot-Marie-Tooth Type 2 disease. *Brain* 2014;137:2897–902.
- [11] Singer F. Paget's Disease of Bone. *Endotext* 2016 [cited 2016 06/29]; Available from <http://www.ncbi.nlm.nih.gov/books/NBK279033/>.
- [12] Bang J, Spina S, Miller BL. Frontotemporal dementia. *Lancet* 2015;386:1672–82.
- [13] Forman MS, Mackenzie IR, Cairns NJ, Swanson E, Boyer PJ, Drachman DA, et al. Novel ubiquitin neuropathology in frontotemporal dementia with valosin-containing protein gene mutations. *J Neuropathol Exp Neurol* 2006;65:571–81.
- [14] Cairns NJ, Neumann M, Bigio EH, Holm IE, Troost D, Hatanpaa KJ, et al. TDP-43 in familial and sporadic frontotemporal lobar degeneration with ubiquitin inclusions. *Am J Pathol* 2007;171:227–40.
- [15] Neumann M, Mackenzie IR, Cairns NJ, Boyer PJ, Markesbery WR, Smith CD, et al. TDP-43 in the ubiquitin pathology of frontotemporal dementia with VCP gene mutations. *J Neuropathol Exp Neurol* 2007;66:152–7.
- [16] Buratti E, Baralle FE. Multiple roles of TDP-43 in gene expression, splicing regulation, and human disease. *Front Biosci* 2008;13:867–78.
- [17] Spina S, Van Laar AD, Murrell JR, Hamilton RL, Kofler JK, Epperson F, et al. Phenotypic variability in three families with valosin-containing protein mutation. *Eur J Neurol* 2013;20:251–8.
- [18] Lagier-Tourenne C, Polymenidou M, Cleveland DW. TDP-43 and FUS/TLS: emerging roles in RNA processing and neurodegeneration. *Hum Mol Genet* 2010;19:R46–64.
- [19] Mehta SG, Watts GD, Adamson JL, Hutton M, Umberger G, Xiong S, et al. APOE is a potential modifier gene in an autosomal dominant form of frontotemporal dementia (IBMPFD). *Genet Med* 2007;9:9–13.
- [20] Niwa H, Ewens CA, Tsang C, Yeung HO, Zhang X, Freemont PS. The role of the N-domain in the ATPase activity of the mammalian AAA ATPase p97/VCP. *J Biol Chem* 2012;287:8561–70.
- [21] Schmidt WE, Mutt V, Carlquist M, Kratzin H, Conlon JM, Creutzfeldt W. Valosin: isolation and characterization of a novel peptide from porcine intestine. *FEBS Lett* 1985;191:264–8.
- [22] Rabinovich E, Kerem A, Frohlich KU, Diamant N, Bar-Nun S. AAA-ATPase p97/Cdc48p, a cytosolic chaperone required for endoplasmic reticulum-associated protein degradation. *Mol Cell Biol* 2002;22:626–34.
- [23] Shih YT, Hsueh YP. VCP and ATL1 regulate endoplasmic reticulum and protein synthesis for dendritic spine formation. *Nat Commun* 2016;7:11020.
- [24] Rape M, Hoppe T, Gorr I, Kalocay M, Richly H, Jentsch S. Mobilization of processed, membrane-tethered SPT23 transcription factor by CDC48(UFD1/NPL4), a ubiquitin-selective chaperone. *Cell* 2001;107:667–77.
- [25] Hetzer M, Meyer HH, Walther TC, Bilbao-Cortes D, Warren G, Mattaj IW. Distinct AAA-ATPase p97 complexes function in discrete steps of nuclear assembly. *Nat Cell Biol* 2001;3:1086–91.
- [26] Uchiyama K, Kondo H. p97/p47-Mediated biogenesis of Golgi and ER. *J Biochem* 2005;137:115–19.
- [27] Rabouille C, Kondo H, Newman R, Hui N, Freemont P, Warren G. Syntaxin 5 is a common component of the NSF- and p97-mediated reassembly pathways of Golgi cisternae from mitotic Golgi fragments in vitro. *Cell* 1998;92:603–10.
- [28] Cao K, Nakajima R, Meyer HH, Zheng Y. The AAA-ATPase Cdc48/p97 regulates spindle disassembly at the end of mitosis. *Cell* 2003;115:355–67.
- [29] Frohlich KU, Fries HW, Rudiger M, Erdmann R, Botstein D, Mecke D. Yeast cell cycle protein CDC48p shows full-length homology to the mammalian protein VCP and is a member of a protein family involved in secretion, peroxisome formation, and gene expression. *J Cell Biol* 1991;114:443–53.
- [30] Meyer H, Weihl CC. The VCP/p97 system at a glance: connecting cellular function to disease pathogenesis. *J Cell Sci* 2014;127:3877–83.
- [31] Evangelista T, Weihl CC, Kimonis V, Lochmuller H. Consortium VCPrd. 215th ENMC International Workshop VCP-related multi-system proteinopathy (IBMPFD) 13–15 November 2015, Heemskerk, The Netherlands. *Neuromuscul Disord* 2016;26:535–47.
- [32] Abrahao A, Abath Neto O, Kok F, Zanoteli E, Santos B, Pinto WB, et al. One family, one gene and three phenotypes: A novel VCP (valosin-containing protein) mutation associated with myopathy with rimmed vacuoles, amyotrophic lateral sclerosis and frontotemporal dementia. *J Neurol Sci* 2016;368:352–8.
- [33] Shi Z, Liu S, Xiang L, Wang Y, Liu M, Liu S, et al. Frontotemporal dementia-related gene mutations in clinical dementia patients from a Chinese population. *J Hum Genet* 2016;61:1003–8.
- [34] Lee H, Deignan JL, Dorrani N, Strom SP, Kantarci S, Quintero-Rivera F, et al. Clinical exome sequencing for genetic identification of rare Mendelian disorders. *JAMA* 2014;312:1880–7.
- [35] Abramzon Y, Johnson JO, Scholz SW, Taylor JP, Brunetti M, Calvo A, et al. Valosin-containing protein (VCP) mutations in sporadic amyotrophic lateral sclerosis. *Neurobiol Aging* 2012;33:2231.e1–6.
- [36] Kwok CT, Wang HY, Morris AG, Smith B, Shaw C, de Belleruche J. VCP mutations are not a major cause of familial amyotrophic lateral sclerosis in the UK. *J Neurol Sci* 2015;349:209–13.
- [37] Jerath NU, Crockett CD, Moore SA, Shy ME, Weihl CC, Chou TF, et al. Rare Manifestation of a c.290 C>T, p.Gly97Glu VCP Mutation. *Case Rep Genet* 2015;2015:239167.
- [38] Miller TD, Jackson AP, Barresi R, Smart CM, Eugenicos M, Summers D, et al. Inclusion body myopathy with Paget disease and frontotemporal dementia (IBMPFD): clinical features including sphincter disturbance in a large pedigree. *J Neurol Neurosurg Psychiatry* 2009;80:583–4.
- [39] Flanagan SE, Patch AM, Ellard S. Using SIFT and PolyPhen to predict loss-of-function and gain-of-function mutations. *Genet Test Mol Biomarkers* 2010;14:533–7.
- [40] Dong C, Wei P, Jian X, Gibbs R, Boerwinkle E, Wang K, et al. Comparison and integration of deleteriousness prediction methods for nonsynonymous SNVs in whole exome sequencing studies. *Hum Mol Genet* 2015;24:2125–37.
- [41] Schwarz JM, Cooper DN, Schuelke M, Seelow D. MutationTaster2: mutation prediction for the deep-sequencing age. *Nat Methods* 2014;11:361–2.
- [42] Salgado D, Desvignes JP, Rai G, Blanchard A, Miltgen M, Pinard A, et al. UMD-Predictor: A High-Throughput Sequencing Compliant System for Pathogenicity Prediction of any Human cDNA Substitution. *Hum Mutat* 2016;37:439–46.
- [43] Kumar P, Henikoff S, Ng PC. Predicting the effects of coding non-synonymous variants on protein function using the SIFT algorithm. *Nat Protoc* 2009;4:1073–81.
- [44] Choi Y, Sims GE, Murphy S, Miller JR, Chan AP. Predicting the functional effect of amino acid substitutions and indels. *PLoS ONE* 2012;7:e46688.
- [45] Adzhubei IA, Schmidt S, Peshkin L, Ramensky VE, Gerasimova A, Bork P, et al. A method and server for predicting damaging missense mutations. *Nat Methods* 2010;7:248–9.

- [46] Stojkovic T, Hammouda el H, Richard P, Lopez de Munain A, Ruiz-Martinez J, Camano P, et al. Clinical outcome in 19 French and Spanish patients with valosin-containing protein myopathy associated with Paget's disease of bone and frontotemporal dementia. *Neuromuscul Disord* 2009;19:316–23.
- [47] Haubenberger D, Bittner RE, Rauch-Shorny S, Zimprich F, Mannhalter C, Wagner L, et al. Inclusion body myopathy and Paget disease is linked to a novel mutation in the VCP gene. *Neurology* 2005;65:1304–5.
- [48] Fernandez-Saiz V, Buchberger A. Imbalances in p97 co-factor interactions in human proteinopathy. *EMBO Rep* 2010;11:479–85.
- [49] Schuberth C, Buchberger A. UBX domain proteins: major regulators of the AAA ATPase Cdc48/p97. *Cell Mol Life Sci* 2008;65:2360–71.
- [50] Yeung HO, Kloppsteck P, Niwa H, Isaacson RL, Matthews S, Zhang X, et al. Insights into adaptor binding to the AAA protein p97. *Biochem Soc Trans* 2008;36:62–7.
- [51] Wang T, Xu W, Qin M, Yang Y, Bao P, Shen F, et al. Pathogenic Mutations in the Valosin-containing Protein/p97(VCP) N-domain Inhibit the SUMOylation of VCP and Lead to Impaired Stress Response. *J Biol Chem* 2016;291:14373–84.
- [52] Watts GD, Thomasova D, Ramdeen SK, Fulchiero EC, Mehta SG, Drachman DA, et al. Novel VCP mutations in inclusion body myopathy associated with Paget disease of bone and frontotemporal dementia. *Clin Genet* 2007;72:420–6.
- [53] Wang Q, Song C, Li CC. Hexamerization of p97-VCP is promoted by ATP binding to the D1 domain and required for ATPase and biological activities. *Biochem Biophys Res Commun* 2003;300:253–60.
- [54] Halawani D, LeBlanc AC, Rouiller I, Michnick SW, Servant MJ, Latterich M. Hereditary inclusion body myopathy-linked p97/VCP mutations in the NH2 domain and the D1 ring modulate p97/VCP ATPase activity and D2 ring conformation. *Mol Cell Biol* 2009;29:4484–94.
- [55] Benatar M, Wu J, Fernandez C, Weihl CC, Katzen H, Steele J, et al. Motor neuron involvement in multisystem proteinopathy: implications for ALS. *Neurology* 2013;80:1874–80.
- [56] Guyant-Marechal L, Laquerriere A, Duyckaerts C, Dumanchin C, Bou J, Dugny F, et al. Valosin-containing protein gene mutations: clinical and neuropathologic features. *Neurology* 2006;67:644–51.
- [57] Boutin RD, Spitz DJ, Newman JS, Lenchik L, Steinbach LS. Complications in Paget disease at MR imaging. *Radiology* 1998;209:641–51.
- [58] Lalam RK, Cassar-Pullicino VN, Winn N. Paget Disease of Bone. *Semin Musculoskelet Radiol* 2016;20:287–99.
- [59] Tan A, Ralston SH. Clinical presentation of Paget's disease: evaluation of a contemporary cohort and systematic review. *Calcif Tissue Int* 2014;95:385–92.
- [60] Farpour F, Tehranzadeh J, Donkervoort S, Smith C, Martin B, Vanjara P, et al. Radiological features of Paget disease of bone associated with VCP myopathy. *Skeletal Radiol* 2012;41:329–37.
- [61] Chan N, Le C, Shieh P, Mozaffar T, Khare M, Bronstein J, et al. Valosin-containing protein mutation and Parkinson's disease. *Parkinsonism Relat Disord* 2012;18:107–9.
- [62] Pirici D, Vandenberghe R, Rademakers R, Dermaut B, Cruts M, Vennekens K, et al. Characterization of ubiquitinated intraneuronal inclusions in a novel Belgian frontotemporal lobar degeneration family. *J Neuropathol Exp Neurol* 2006;65:289–301.
- [63] Mizuno Y, Hori S, Kakizuka A, Okamoto K. Vacuole-creating protein in neurodegenerative diseases in humans. *Neurosci Lett* 2003;343:77–80.
- [64] Kurihara Y, Kanki T, Aoki Y, Hirota Y, Saigusa T, Uchiumi T, et al. Mitophagy plays an essential role in reducing mitochondrial production of reactive oxygen species and mutation of mitochondrial DNA by maintaining mitochondrial quantity and quality in yeast. *J Biol Chem* 2012;287:3265–72.
- [65] Tanaka A, Cleland MM, Xu S, Narendra DP, Suen DF, Karbowski M, et al. Proteasome and p97 mediate mitophagy and degradation of mitofusins induced by Parkin. *J Cell Biol* 2010;191:1367–80.
- [66] Kim NC, Tresse E, Kolaitis RM, Molliex A, Thomas RE, Alami NH, et al. VCP is essential for mitochondrial quality control by PINK1/Parkin and this function is impaired by VCP mutations. *Neuron* 2013;78:65–80.
- [67] Chen Y, Dorn GW 2nd. PINK1-phosphorylated mitofusin 2 is a Parkin receptor for culling damaged mitochondria. *Science* 2013;340:471–5.
- [68] Zhang T, Mishra P, Hay BA, Chan D, Guo M. Valosin-containing protein (VCP/p97) inhibitors relieve Mitofusin-dependent mitochondrial defects due to VCP disease mutants. *Elife* 2017;6.
- [69] Pickrell AM, Youle RJ. The roles of PINK1, parkin, and mitochondrial fidelity in Parkinson's disease. *Neuron* 2015;85:257–73.
- [70] Figueroa-Bonaparte S, Hudson J, Barresi R, Polvikoski T, Williams T, Topf A, et al. Mutational spectrum and phenotypic variability of VCP-related neurological disease in the UK. *J Neurol Neurosurg Psychiatry* 2016;87:680–1.