

Foreign Body Granulomas after All Injectable Dermal Fillers: Part 2. Treatment Options

Foot

Gottfried Lemperle, M.D.,
Ph.D.
Nelly Gauthier-Hazan, M.D.
San Diego, Calif.; and Paris, France

Summary: Foreign body granulomas occur at certain rates with all injectable dermal fillers. They have to be distinguished from early implant nodules, which usually appear 2 to 4 weeks after injection. In general, foreign body granulomas appear after a latent period of several months at all injected sites at the same time. If diagnosed early and treated correctly, they can be diminished within a few weeks. The treatment of choice of this hyperactive granulation tissue is the intralesional injection of corticosteroid crystals (triamcinolone, betamethasone, or prednisolone), which may be repeated in 4-week cycles until the right dose is found. To lower the risk of skin atrophy, corticosteroids can be combined with antimetabolic drugs such as 5-fluorouracil and pulsed lasers. Because foreign body granulomas grow fingerlike into the surrounding tissue, surgical excision should be the last option. Surgery or drainage is indicated to treat normal lumps and cystic foreign body granulomas with little tissue ingrowth. In most patients, a foreign body granuloma is a single event during a lifetime, often triggered by a systemic bacterial infection. (*Plast. Reconstr. Surg.* 123: 1, 2009.)

An increasing number of various injectable dermal filler substances are being used for the treatment of wrinkles, acne scars, and facial lipodystrophy. They have been developed because injection of earlier substances, such as paraffin and silicone oil, was followed by a high incidence of late granuloma formation.¹ In addition, the effects of collagen and hyaluronic acids, considered the accepted standard, do not last longer than 6 months before they are resorbed. Paraffin oil used some 100 years ago led to paraffinomas,² and injection of low-viscosity silicone oil of 350 centistoke caused late siliconomas in selected patients³⁻⁵ in the 1970s. In the early 1980s, bovine collagen (Zyderm and its cross-linked form Zyplast)⁶ appeared to be safe but caused granulomas in selected patients as well.⁷

In the early 1990s, the first particulate injectables, Bioplastique⁸ and Arteplast,⁹ were introduced in Europe. These substances, however, caused foreign body granulomas at unacceptably high rates—the first because of the irregular shape of its silicone particles,¹⁰ the latter due to a high amount of small phagocytosable polymethylmethacrylate particles among the smooth and

even microspheres.¹¹ Unfortunately, polymethylmethacrylate products with a high percentage of impurities are widely injected in Brazil.^{12,13} Today, ArteFill is a third-generation polymethylmethacrylate-based filler that has substantial improvements, including microspheres, which have enhanced uniformity and consistency, compared with the second-generation polymethylmethacrylate-based product, Artecoll.

At the end of the 1990s, Dermalive, a suspension of slowly resorbable acrylic (hydroxyethylmethacrylate) particles from ground intraocular lenses,¹⁴ and New-Fill/Sculptra, faster resorbed microspheres from polylactic acid, entered the European market.¹⁵ A few years later, the first reports of late granuloma formation appeared.¹⁶ Restylane, a hyaluronic acid derived from *Streptococcus equi*,¹⁷ was introduced in 1998, and some patients reacted with the formation of late granulomas.^{18,19}

Radiesse (formerly Radiance), consisting of microspheres composed of calcium-hydroxylapa-

From the Division of Plastic Surgery, University of California, San Diego, and private practice.

Received for publication August 24, 2007; accepted December 5, 2007.

Copyright ©2009 by the American Society of Plastic Surgeons

DOI: 10.1097/PRS.0b013e3181858f4f

Disclosure: *Gottfried Lemperle, M.D., Ph.D., is not affiliated with nor an agent nor a representative of Artes Medical, Inc., which is the manufacturer of ArteFill. Dr. Lemperle is a shareholder of Artes Medical, Inc. Nelly Gauthier-Hazan, M.D., has no financial interest in any of the products mentioned in this article.*

tite and suspended in methyl-cellulose,²⁰ is a filler substance introduced in the United States in 2002 for off-label use in wrinkles and lip augmentation; it received U.S. Food and Drug Administration approval for the treatment of nasolabial folds and human immunodeficiency virus–associated lipodystrophy in 2006. So far, Radiesse appears to cause the lowest rate of foreign body granulomas among all filler substances.¹

Finally, polyacrylamide gel was the Russian answer^{21,22} to the American silicone gel for soft-tissue augmentation in the 1980s and 1990s. Today, different formulations of polyacrylamide are produced by at least five manufacturers since Interfall Ltd., in Kiev, Ukraine, lost its European patent protection of Formacryl²² and Interfall in 1995. Aquamid²³ and Bio-Alcamid^{24,25} are the products most widely used in Europe today, besides Interfall² and Amazing Gel in China.

Recently, resorbable microspheres from dextran²⁷ suspended in hyaluronic acid were introduced in Europe as dermal fillers under the trade names Reviderm intra and Matridex. They are used as urinary bulking agents to treat incontinence. Matridex is currently in clinical trials in the United States. Both stimulate heavy granulation tissue^{27,28} but have not been used long enough to provide sufficient insight into potential late complications. Dextran granuloma, however, has been described in rats²⁶ and has caused urinary obstruction in humans.^{29,30}

FOREIGN BODY GRANULOMAS AFTER DIFFERENT FILLERS

There are three different clinical and histological types of foreign body granulomas.¹ Biological substances, such as collagen and hyaluronic acids, may cause *cystic granulomas*, which may eventually result in a sterile abscess. They occur between 2 and 12 months after injection and last without treatment for 2 to 12 months before spontaneous absorption. Permanent injectable fluids, such as silicone and polyacrylamide, may cause *edematous granulomas*, with swelling and surrounding inflammation. Particulate injectables, such as Artecoll, Dermalive, and Sculptra, may cause *sclerosing granulomas*, which occur between 6 and 24 months after injection and will remain for several years if not treated. Of course, there is a continuum among the three types, and certain granulomas sometimes are a blend of two types.

Silicone

The spontaneous disappearance of silicone foreign body granulomas after a 3-year follow-up

period has been observed.^{31,32} If the reaction is limited to firm nodules, corticosteroid injections into the cellular tissue surrounding the silicone implant should be the first treatment choice. Complete remission of silicone foreign body granulomas in two patients has been obtained with a systemic antibiotic (minocycline 100 mg) given twice a day, orally.³³

“Liposuction” or puncturing and squeezing of larger silicone fluid implants can be tried, but surgical excisions should be avoided, as removal will seldom be complete due to the silicone’s fingerlike insinuation into the tissue. Total excision and flap coverage⁴ should be reserved as a last option in patients with extreme infiltration and inflammation of the skin on the nose or breast.

Bovine Collagen

Moscona et al.⁷ described a woman who developed severe sclerosing foreign body granulomas at all injection sites 2.5 years after implantation of Zyderm I collagen into her nasolabial folds, glabellar frown lines, and a few areas around the lips. High doses of oral prednisolone, up to 60 mg/day, resulted in a marked diminution of the swelling, but the foreign body granulomas rapidly recurred when the treatment was stopped. Further treatment with intralesional triamcinolone injections resulted in almost complete regression for a period of 4 to 6 weeks, after which the foreign body granulomas recurred. In the latter case, no doses were reported, but we assume that they did not exceed 40 mg per session. Slight improvement was noted over the following years with low daily doses of 5 and 10 mg of Dexacort.

Hyaluronic Acids

Late foreign body granulomas developed 2 to 11 months after injection of hyaluronic acids and lasted 2 to 10 months without treatment.^{34,35} Some were treated with intralesional triamcinolone,^{17,33} but most resolved without treatment within 1 year. We are aware of four sclerosing but rather soft Restylane granulomas with late onsets of up to 3.5 years after injection. Systemic or local antibiotics are ineffective, but puncturing and squeezing out the whitish gel will speed up their resolution.^{17,36} Surgical excision³⁷ of this cellular reaction should certainly be the last solution.

Polymethyl-Methacrylate Microspheres

Because of the extensive fibrous network associated with polymethyl-methacrylate–related granulomas, intralesional corticosteroid injec-

AQ: 1

AQ: 2

AQ: 3

tions are considered the best treatment.¹¹ We saw an Arteplast granuloma develop as late as 10 years after injection; it responded well to high doses of local steroids and pulsed light therapy (Fig. 1). A few cases of resistance to this treatment, probably due to insufficient initial doses of steroids, have been reported. If widened capillaries remain, they can be treated using different types of light therapy. Excision should be the very last option (as with all granulomas) because of the insinuations of the foreign body granulomas into the surrounding tissue. After sieving and washing, the second-generation Artecoll caused a significantly lower number of foreign body granulomas compared with polymethyl-methacrylate products with a high content of small particles.^{1,13}

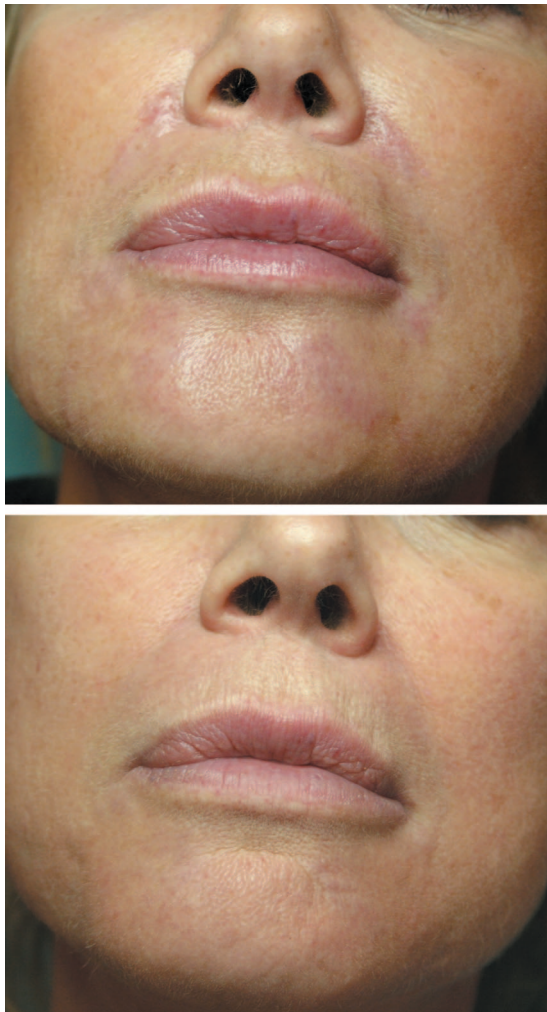

Fig. 1. (Above) Sclerosing granuloma (Arteplast) 10 years after injection, 2 weeks after severe bronchitis, and 3 days after onset. (Below) Complete resolution 10 days after intralesional injection of 160 mg of methylprednisolone and four sessions of intense pulsed light.

Poly-lactic Acid Microspheres

Powder of poly-lactic acid beads suspended in cellulose (New-Fill/Sculptra) was first used successfully in human immunodeficiency virus patients with facial lipodystrophy in France and England. In the beginning, it was diluted 1:3 with saline and caused a high percentage of palpable but not visible small subcutaneous nodules. The presently recommended suspension of one part powder with five parts of saline has significantly reduced the occurrence of lumps. They still become visible after injections into lower eyelids,³⁸ when New-Fill or Sculptra suspensions are not implanted strictly epiperiosteally.³⁹

Poly-Hydroxyethyl-Methacrylate Particles

A relative high rate of foreign body granulomas occur 4 months to 3 years after Dermalive^{40,41} implantation; the granulomas are best treated with intralesional triamcinolone injections (Fig. 2). Because hypersensitivity reactions and foreign body granulomas occur much less frequently in subcutaneous tissue, DermaDeep will cause less visible side effects, as does Bioplastique,^{8,10} when it is implanted epiperiosteally compared with subdermally. We saw a 63-year-old patient who suddenly developed a generalized granulomatosis annulare of about 60 red flat infiltrates up to 3 cm in diameter on the face, trunk, and extremities 1 year after perioral Dermalive injections. They did not react to local triamcinolone and 5-fluorouracil injections but to 7 mg of betamethasone (Diprosone) administered intralesionally a total of five times in one session. No rheumatism was observed, but some recurrences are currently being treated with Allopurinol⁴⁰ and Diprosone. Another patient developed localized sclerosing edematous foreign body granulomas at all injection sites in the face and is still being treated with systemic steroids and surgery.

Obviously, granuloma formation is a single event triggered by an infectious, traumatic, or pharmacological stimulus.¹ If it is treated early and with sufficiently high doses of corticosteroids or other agents that inhibit cellular activities,⁴³ it does not recur.

THE TREATMENT OF GRANULOMAS AND IMPLANT NODULES

Intralesional Injections of Steroids

Foreign body granulomas consist mainly of a cellular multiplication with little therapeutic effect. Even for the resorbable fillers, most particulate or artificial material cannot be broken down

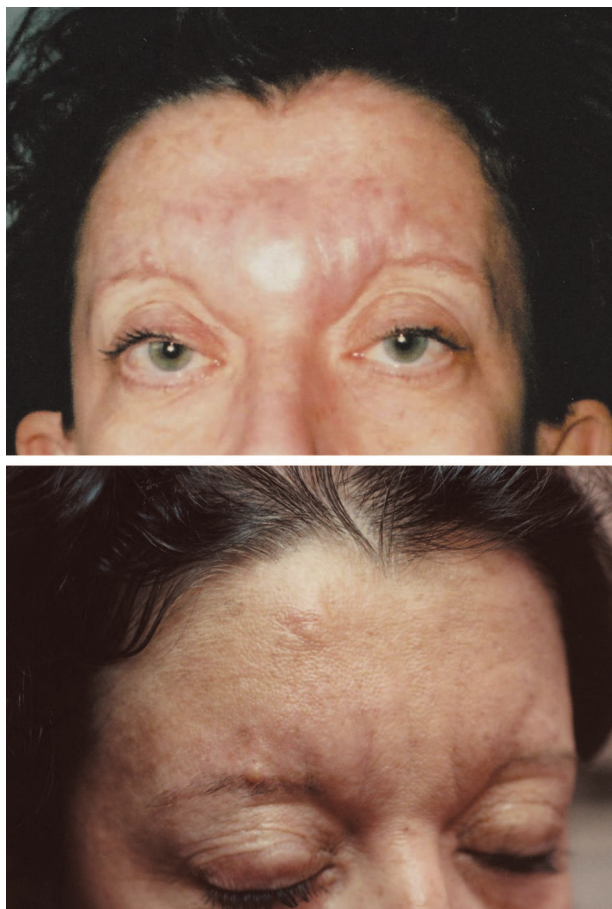

Fig. 2. (Above) Sclerosing granuloma (Dermalive) 2 years after injection and 3 months after onset. (Below) Total resolution after treatment with intralesional methylprednisolone at 80 mg. At recurrence 9 months later, methylprednisolone at 80 mg and 30 mg, as well as betamethasone at 5 mg and three sessions of intense pulsed light, was applied. There has been no recurrence in the past 3 years.

faster by granuloma formation. A granuloma is more of a frustrated reaction, like the fusion of macrophages into giant cells, which are in no way more effective. The goal in the treatment of foreign body granulomas must be to stop the invasion of cells and increased secretion of interstitial substances without leaving a scar. Triamcinolone decreases both cellular proliferation and invasion and collagen production by dermal fibroblasts. Alteration of cytokine levels (e.g., an increased production of transforming growth factor beta-1 by dermal fibroblasts) may mediate these effects.⁴⁴ In the rat model, dexamethasone drastically interfered with both the synthesis and the degradation of type I and III collagen and significantly decreased fibril collagen content.⁴⁵ This explains the impaired wound healing and occasional skin atrophy caused by corticosteroids.^{46,47}

Therefore, the treatment of choice is the strictly intralesional injection of triamcinolone (Kenalog, Volon A)^{48,49} at 40 mg or betamethasone (Diprosone)¹¹ or methylprednisolone (Depo-Medrol; Pharmacia & Upjohn, Bridgewater, N.J.) as soon as possible (Table 1). The latter two drugs can be used undiluted, but triamcinolone should be diluted 1:1 with lidocaine. Intralesional triamcinolone is approved by the Food and Drug Administration for the treatment of keloids, hypertrophic scars, and granuloma annulare, but it is not approved to treat foreign body granulomas even though it has been the treatment of choice since the early 1960s.^{48,49} The initial dose has to be sufficiently high (Fig. 2), although this risks skin depressions, to avoid frequent recurrences. The fact that foreign body granulomas treated with sufficiently high doses of corticosteroids seldom recur cannot be explained at this time. Therefore, radical surgical removal of foreign body granulomas³⁷ is never indicated in the first place.

On the other hand, nodules and foreign body granulomas with little capsule formation and little tissue ingrowth, such as cystic foreign body granulomas injection of after collagen^{7,50} or hyaluronic acid^{51,52} or packed nodules of Radiesse, Dermalive, silicone, and polyacrylamides,⁵³ will not react to intralesionally injected corticosteroids or antimetabolic drugs at all.⁵⁴ Surgical removal of cysts and nodules, especially from the lips, is probably the method of choice for these cases. Lambros⁵⁵ reports an anecdotal case of a woman with lumps in her tear troughs 1 week after injections of a hyaluronic acid filler; the lumps disappeared immediately after intralesional injections of hyaluronidase. This possibility of depolymerization of hyaluronic acid should be kept in mind for the treatment of early nodules but not foreign body granulomas.

All implant nodules with a high percentage of connective tissue content (Artecoll, Bioplastique, New-Fill/Sculptra, Reviderm intra, Matridex) and genuine foreign body granulomas of these prod-

Table 1. Proven Treatments of Granulomas

Proven Treatment
• Triamcinolone (Kenalog, Volon-A) 20–40 mg intralesionally ^{11,50,53,58}
• Triamcinolone (1 mg/ml) + 5-fluorouracil (50 mg/ml) intralesionally ^{39,59,64}
• Prednisolone (Depo-Medrol) 20–40 mg undiluted (N.G.-H.)
• Betamethasone (Diprosone) 5–7 mg intralesionally ^{11,39}
• 1:3 Betamethasone (Diprosone) 3.5 mg + 1:3 5-fluorouracil (1.6 ml) + 1:3 lidocaine intralesionally ⁴³

ucts react well to intralesional crystalline corticosteroids. The same volume reduction can be expected if nodules are accidentally dislocated by muscle movement, if too much implant material is injected, or if hypertrophic scarring occurs because of an injection being too superficial. Local steroids inhibit fibroblast activity and collagen deposition,⁵⁶ macrophage activity and giant cell formation, swelling, itching, and pain. Because particulate implants consist of approximately 80 percent of the patient's own granulation or fibrous tissue, it can be diminished as with a hypertrophic scar to half of its volume by a variety of growth depressants and antimitotic agents.⁵⁷

A 1:1 mixture of lidocaine and triamcinolone at 40 mg (Kenalog or Volon-A), methylprednisolone (Depo-Medrol) at up to 40 mg [and even 80 mg (Fig. 1)], or betamethasone (Diprosone) at up to 5 mg can be injected safely through a 1-ml insulin syringe with Luer lock and a 30-gauge needle. It must be injected strictly into the nodule held between two fingers while the needle is guided back and forth; strong resistance to the needle should be felt. Because corticosteroids injected into the surrounding tissue may cause temporary skin atrophy, one should stop injecting as soon as the resistance of the nodule lessens, and start again from a different angle. Because of their high cellular content, granulomas are much easier to inject than nodules.

A combination of triamcinolone injections with cryotherapy has been advocated.⁵⁸ Also, a combination of intralesional steroid with pulsed light treatment (Flash-lamp) (Figs. 1 and 2, *below*) of the area has proven effective,⁵⁹ especially on the blue discoloration of the skin over foreign body granulomas (Table 2). Because every patient reacts differently to corticosteroids, one should eventually increase the dose to up to 40 mg of triamcinolone (Fig. 3) or 7 mg of betamethasone in nonresponders. Two to five sessions at 3-week intervals may be necessary. If this therapy is begun early and aggressively (Fig. 2), surgical excision will not be an issue.

Another combination of triamcinolone with interferon- α 2b has been applied successfully in keloids^{59,60} by injecting triamcinolone every 2 weeks and interferon twice a week. This combination may be worth considering for patients with foreign body granulomas who have a history of failed corticosteroid injections.

Many physicians are reluctant to use local corticosteroids. These agents can cause skin atrophy in 20 to 30 percent of patients, independent of dose; the patient should be fully aware of this side

Table 2. Anecdotal Treatments of Granulomas

Anecdotal Treatment
• Triamcinolone intralesionally + cryotherapy ⁵⁸
• Bleomycin (1.5 IU/ml) intralesionally ^{57,66}
• 5-Fluorouracil intralesionally ^{59,64}
• Prednisone (1 mg/kg/day) orally ³⁴
• Prednisone (60 mg/day) orally + ibuprofen (1800 mg/day)
• Cortivazol (3.75 mg/1.5 ml) intralesionally (N.G.-H.)
• Minocycline (2 × 100 mg/day) orally ^{33,68}
• Minocycline (2 × 250 mg/day) + prednisolone (4 mg/day) ¹⁷
• Cyclosporine (5 mg/kg/day) orally ⁷⁰
• Allopurinol (200–600 mg/day) ⁴²
• Colchicine ⁶⁹
• Isotretinoin (0.5 mg/kg/day) ⁴³
• Imiquimod (Aldara) cream 5% ⁶¹
• Tacrolimus cream 0.5% ⁷¹
• Hyaluronidase ^{55,76}
• Laser at 532 nm and 1064 nm ^{29,73}
• Intralesional steroids + intense pulse light (N.G.-H)

effect. If one is not under time pressure, one could offer a local steroid test by injecting undiluted crystals as a little bleb in the subcutaneous fat of the neck below the hairline and waiting 8 weeks. One can also find the right dose by increasing it each time, preventing possible atrophy with a lower starting dose.⁶¹

If there is no improvement after 2 to 4 weeks, the dose should be doubled. In some African and Asian children with huge keloids, we have injected up to 160 mg of triamcinolone intralesionally every 4 weeks over a period of 6 months until the lesion remained flat. We cannot recall any visible systemic effect in these children. It is probable betamethasone (Fig. 4) and methylprednisolone cause less skin atrophy than triamcinolone. Should skin atrophy occur,⁶² temporary filling with collagen or hyaluronic acid will level the indentation until natural recovery occurs within 3 to 12 months.¹¹

Antimitotic Agents

The risk of cortisone skin atrophy might be reduced by the injection of antimitotic agents such as 5-fluorouracil, which is mixed with 1:3 Diprosone and 1:3 lidocaine 2% without epinephrine and injected intralesionally every 3 weeks, if necessary.^{53,63,64} The anti-inflammatory action of this mixture is astonishing: the painful tension and redness, which are sometimes associated with foreign body granulomas, subside immediately, growth stops, and the foreign body granulomas diminish within a few weeks. Betamethasone (Diprosone) is supposed to have a less damaging

T2

F3

F4

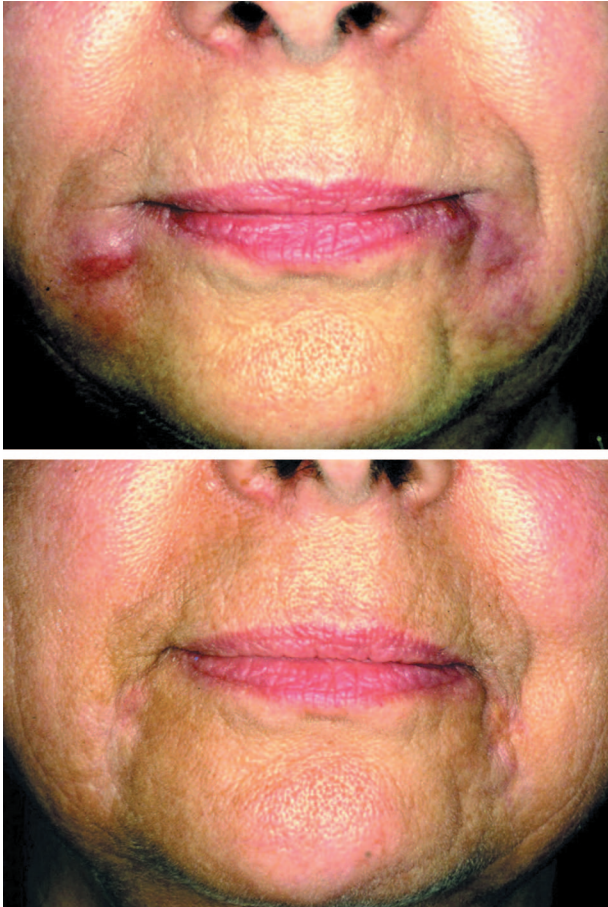


Fig. 3. (Above) Typical bluish discoloration of sclerosing granulomas (Arteplast) in both marionette lines 1 year after implantation. (Below) Total dissolution 4 weeks after a single injection of 40 mg of triamcinolone.

effect on the surrounding tissue than triamcinolone and methylprednisolone.

The pure mixture of intralesional 5-fluorouracil (here 1.6 ml of a 500 mg/10 ml 5-fluorouracil solution) with 0.4 ml of betamethasone (7 mg/ml) decreases cell proliferation and invasion and releases collagenase activity within the granuloma.³⁸ From their 9-year experience in treating hypertrophic scars, Fitzpatrick and Manuskiatti⁶³ and Narins et al.⁶⁵ recommend pure 5-fluorouracil (50 mg/cc) intralesionally or mixed with 1 mg/cc of Kenalog. Frequent initial injections administered one to three times per week were more efficacious than higher single doses. Besides inhibiting tumor growth, cytostatics also inhibit collagen synthesis and are effective in the treatment of keloids and hypertrophic scars. Bleomycin (1.5 IU/ml) has been injected intralesionally into keloids and hypertrophic scars and should work successfully in granulomas as well.^{57,66}

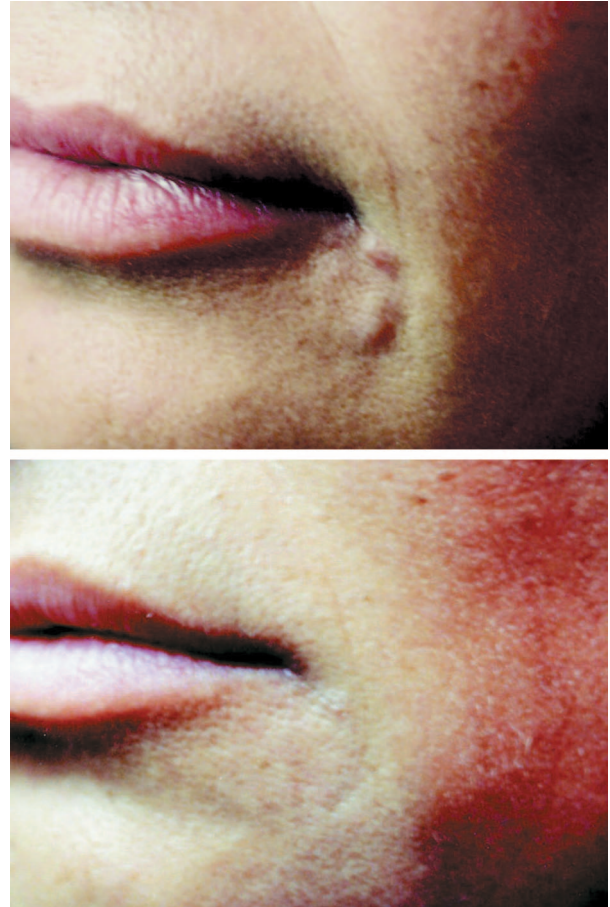

Fig. 4. (Above) Sclerosing granulomas (New-Fill) in both marionette lines developed 18 months after injections. These granulomas grow to a small size only, probably due to the small amount of polylactic acid injected, but they can remain for years if left untreated. (Below) Appearance after effective treatment with three injections of 5 mg of undiluted betamethasone intralesionally.

Systemic Corticosteroids and Alternative Drugs

In general, the resolution of granulomas and nodules by corticosteroids is a matter of dosage, compliance, guidance, and patience on both sides. Some lumps will be reduced satisfactorily after one shot (Fig. 3), and some need three to six injections over a period of 3 to 6 months (Fig. 4). Some may recur and need touch-up treatment with triamcinolone, some react preferably to betamethasone, and some may react to cytostatics alone. Systemic doses must be much higher than those used for local intralesional injection. A starting dose of 30 mg/day of prednisone had to be increased to 60 mg/day because of recurrence,⁶¹ and ibuprofen (1800 mg/day) was added for a successful treatment of 16 weeks. The patient remained asymptomatic at 2 years.

The antibiotic minocycline (100 mg twice daily) has been given systemically⁶⁸ in diffuse silicone granulomas developing 8 and 5 years after injection. Prednisone treatment (1 mg/kg/day) had to be interrupted because of glucose intolerance.³⁷ The authors relate its antigranulomatous properties to minocycline's immune-modulating effect.

Reisberger et al.⁴² successfully treated a patient with Arteplast granulomas on the forehead with Allopurinol, an effective treatment for gout using 200 to 600 mg/day administered over a period of 24 weeks. The same effect could be obtained with colchicine⁶⁹ and the retinoic acid isotretinoin (Accutane) and doxycycline.⁴¹

AQ: 6
AQ: 7
AQ: 8
Baumann and Kerdel⁷⁰ successfully treated a patient with acute allergy to bovine collagen, who did not respond to oral and intramuscular steroids (prednisone at 40 mg over 3 days and additional 9 mg of Celestone intramuscularly), with cyclosporine (5 mg/kg/day = 175 mg pro twice daily). After 2 weeks, the reaction subsided. They also reported the successful treatment of a silicone foreign body granuloma of the lips with an immunomodulatory cream [imiquimod 5% (Aldara)] that is known to increase levels of interferon alpha. The release of cytokines, interferon, and tumor necrosis factor enhances antiproliferative properties and collagenase activity. The swollen lips improved dramatically after 2 weeks of topical treatment, and the twice-daily treatment could be stopped after 2 months of consecutive treatment.

Tacrolimus cream appears to be effective in treating granuloma annulare and solved the local symptoms of collagen allergy as well.⁷¹ Tacrolimus has a mechanism of action similar to that of cyclosporine: both inhibit T-cell activation, interferon, and the release of preformed mediators from mast cells and basophils.

Many patients, however, have experienced spontaneous improvement of their condition over time.⁷² Therefore, at least five patients should be treated with every new regimen before it can be recommended as an effective therapy of foreign body granulomas (Table 2).

Laser Treatment of Telangiectasia

Small noninflammatory granulomas have responded well to long-pulsed 532-nm lasers; larger inflammatory granulomas have shown some favorable responses to 1064-nm long-pulsed lasers.^{59,73} The bluish discoloration of some superficial sclerosing foreign body granulomas can be treated effectively by "flashing" with intense pulsed light

in the same range (e.g., that of the targeting blood vessels) (Fig. 2). Four to five sessions not only block the neovascularization but appear to soften and decrease the volume of the underlying granuloma, probably by reducing its blood supply from above.

No Surgical Excisions!

Plastic surgeons tend to excise all lumps in places where they do not belong,^{37,74} whereas dermatologists, in general, try corticoid creams first. Both approaches are contraindicated in foreign body granulomas. Surgical excision of genuine granulomas will be incomplete because of their invasiveness and nonconfined borders with the surrounding tissue. Attempts to excise and extricate injected fluids such as silicone and acrylamide¹⁹ meet with dire results, causing fistulas, abscesses, continuous granulation tissue, and marked deformities, even if bacteriological cultures have proven negative.⁷⁵ In addition, surgical excisions^{37,74} may leave scars in the face but not in the lips.

Some hard nodules in the soft tissue of the lips, however, may not react well and are disturbing to the patient. In these rare cases, surgical excision, always approached from the inside, will be the best treatment. In general, foreign body nodules can be removed in the manner of a small atheroma by blunt dissection, due to the presence of the fibrous capsule that develops after 3 to 6 months. If excision of displaced material becomes necessary in a facial fold, the scar can be well hidden in the fold, especially in elderly patients.

Surgery is absolutely contraindicated in the vermilion because of the implant's proximity to the thin dermis of the vermilion border ("white roll") and because of the possibility of uncontrolled scarring. If indentations or irregularities occur after surgery, they can be treated with superficial touch-ups of absorbable filler substances, such as collagen or hyaluronic acid, as well as with additional corticoid injections, if necessary.

Similarly, radical excision of implants or foreign body granulomas from enlarged lips should be avoided under all circumstances. We are aware of three cases of radical excision of implants after lip augmentation, one in Frankfurt in 1998, one in Stockholm in 2004, and one in Regensburg in 2005. In all three patients, the orbicularis oris muscle was compressed by the implants for years and did not recover at all, as is well known from fat and breast tissue after removal of a silicone implant. Instead, stepwise horizontal volume reduction with the help of a 16-gauge trocar and simultaneous steroid injections should be tried.

AQ: 9

Whether injections of hyaluronidase^{55,76} work in Restylane foreign body granulomas is doubtful, but it is possible in early stages in combination with triamcinolone. The effect of injected collagenolytic agents (collagenase) into collagen nodules has not been reported yet.

CONCLUSIONS

Foreign body granulomas can be treated effectively with intralesional injections of corticosteroids. Prerequisite is a correct diagnosis, which takes into account whether there is enough cellular ingrowth to react to the inhibiting effect of corticosteroids and antimitotic drugs. In general, early nodules are compressed implants and do not react to invasion or proliferation-inhibiting medication. The same is true for foreign body granulomas after the injection of gels such as silicone and polyacrylamide, and for cystic foreign body granulomas after injection of collagen or hyaluronic acids; these granulomas have to be drained first. In sclerosing foreign body granulomas, however, determining the right intralesional dose may be difficult and may delay the final outcome. Systemic steroids are indicated in all edematous foreign body granulomas in which intralesional steroids are difficult to apply. Otherwise, systemic steroids take effect much too late and require an unnecessarily long treatment period, with all the accompanying psychological problems. Creams, in general, are absorbed too superficially and do not reach the subdermally located foreign body granulomas.

Gottfried Lemperle, M.D., Ph.D.

Division of Plastic Surgery
University of California, San Diego
302 Prospect Street
La Jolla, Calif. 92037
glempeler@aol.com

REFERENCES

AQ: 10

- Lemperle G, Gauthier-Hazan N, Wolters M, Eisemann-Klein M, Zimmermann U, Duffy DM. Foreign body granulomas after all injectable dermal fillers: Part I. Possible causes. *Plast Reconstr Surg*. 2008;123:xxxx.
- Khoo Boo-Chai MB. Paraffinoma. *Plast Reconstr Surg*. 1965;36:101.
- Duffy DM. Liquid silicone for soft tissue augmentation: Histological, clinical, and molecular perspectives. *Dermatol Surg*. 2007;31:1530.
- Maas CS, Papel ID, Greene D, et al. Complications of injectable synthetic polymers in facial augmentation. *Dermatol Surg*. 1997;23:871.
- Ficarra G, Mosqueda-Taylor A, Carlos R. Silicone granuloma of the facial tissue: A report of seven cases. *Oral Surg Oral Med Oral Pathol* 2002;94:65.
- Knapp TR, Kaplan EN, Daniels JR. Injectable collagen for soft-tissue augmentation. *Plast Reconstr Surg*. 1977;60:398.
- Moscona RR, Bergman R, Friedman-Birnbaum R. An unusual late reaction to Zyderm I injections: A challenge for treatment. *Plast Reconstr Surg*. 1993;92:331.
- Ersek RA. More on Bioplastique. *Aesthet Plast Surg*. 2000;24:461.
- Lemperle G, Pietz R, Lemperle M. First clinical experiences with Arteplast (polymethyl-methacrylate microspheres) injected beneath wrinkles and dermal defects. In: Hinderer UT, ed. *Plastic Surgery 1992*, Vol. II. Amsterdam: Elsevier Science Publishers B.V.; 1992:539-541.
- Lemperle G, Holmes R, Larson FG. Reply on Dr. Kessel's Commentary. *Aesthet Plast Surg*. 2000;24:74.
- Lemperle G, Romano JJ, Busso M. Soft tissue augmentation with Artecoll: 10-year history, indications, techniques, and complications. *Dermatol Surg*. 2003;29:573.
- Borges Fortes F, Lemperle G, Charrier U. Electron microscopy and human histology of different dermal fillers containing PMMA.
- Salles AG, Lotierzo PH, Gemperli R, et al. Complications after polymethylmethacrylate injections: Report of 32 cases. *Plast Reconstr Surg*. 2008;121:1811.
- Bergeret-Galley C, Latouche X, Illouz Y-G. The value of a new filler material in corrective and cosmetic surgery: DermaLive and DermaDeep. *Aesthet Plast Surg*. 2001;25:249.
- Laglenne S. Un nouveau produit de comblement des rides, entièrement resorbable. *Dermatologie* 2000;54:30.
- Lombardi T, Samson J, Plantier F, et al. Orofacial granuloma after injection of cosmetic fillers: Histopathologic and clinical study of 11 cases. *J Oral Pathol Med*. 2004;33:115.
- Lupton JR, Alster TS. Cutaneous hypersensitivity reaction to injectable hyaluronic acid gel. *Dermatol Surg*. 2000;26:135.
- Shafir R, Amir A, Gur E. Long-term complications of facial injections with Restylane (injectable hyaluronic acid). *Plast Reconstr Surg*. 2000;106:1215.
- Alijotas-Reig J, Garcia-Gimenez V. Delayed immune-mediated adverse effects related to hyaluronic acid and acrylic hydrogel dermal fillers: Clinical findings, long-term follow-up and review of the literature. *J Eur Acad Dermatol Venereol*. 2008;22:150.
- Jansen DA, Graivier MH. Evaluation of a calcium hydroxylapatite-based implant (Radiesse) for facial soft-tissue augmentation. *Plast Reconstr Surg*. 2006;118(3 Suppl):22S.
- Christensen LH, Breiting VB, Aasted A, et al. Long-term effects of polyacrylamide hydrogel on human breast tissue. *Plast Reconstr Surg*. 2003;111:1883.
- Mazzoleni F, Dominici C, Lotti T, et al. Formacryl®: Un nuovo biopolimero al servizio della medicina "piu un endoprotesi che un filler." *Dermatologia* 2000;1:13.
- De Cassia Novaes W, Berg A. Experience with a new non-biodegradable hydrogel (Aquamid): A pilot study. *Aesthet Plast Surg*. 2003;27:376.
- Casavantes LC, Izabel JM. Estabilidad, tolerancia y seguridad de polialquilimida gel (BioAlcamid™), endoprotesis inyectable para la corrección de defectos mayores en tejidos blandos. *Dermatologia CMQ*. 2004;2:98.
- Karim RB, Hage JJ, van Rozelaar L, Lange CAH, Raaijmakers J. Complications of polyalkylimide 4% injections (Bio-Alcamid™): A report of 18 cases. *J Plast Reconstr Aesthet Surg*. 2006;59:1409.
- Cheng N-X, Wang Y-L, Zhang X-M, et al. Complications of breast augmentation with injected hydrophilic polyacrylamide gel. *Aesthet Plast Surg*. 2002;26:375.
- Lemperle G, Morhenn VB, Charrier U. Human histology and persistence of various injectable filler substances for soft tissue augmentation. *Aesthet Plast Surg*. 2003;27:354.

AQ: 11

28. Alkan M, Ciftci AO, Talim B, Senocak ME, Caglar M, Buyukpamukcu N. Histological response to injected dextranomer-based implant in a rat model. *Pediatr Surg Int*. 2007;23:183.
29. Bedir S, Kilciler M, Oezgoek Y, Devenci G, Erduran D. Long-term complication due to dextranomer based implant: Granuloma causing urinary obstruction. *J Urol*. 2004;172:247.
30. Castillo-Vico MT, Checa-Vizcaino MA, Paya-Panades A, Rueda-Garcia C, Carreras-Collado R. Periurethral granuloma following injection with dextranomer/hyaluronic acid copolymer for stress urinary incontinence. *Int Urogynecol J Pelvic Floor Dysfunct* 2007;18:95.
31. Bigata X, Ribera M, Bielsa I, et al. Adverse granulomatous reaction after cosmetic dermal silicone injection. *Dermatol Surg*. 2001;27:198.
32. Duffy DM. Tissue injectable liquid silicone: New perspectives. In: Klein AW, ed. *Tissue Augmentation in Clinical Practice: Procedures and Techniques*. 2nd ed. New York: Taylor & Francis; 2005:159.
33. Senet P, Bachelez H, Ollivaud L, et al. Minocycline for the treatment of cutaneous silicone granulomas. *Br J Dermatol*. 1999;140:985.
34. Ghislanzoni M, Bianchi F, Barbareschi M, Alessi E. Cutaneous granulomatous reaction to injectable hyaluronic acid gel. *Br J Dermatol*. 2006;154:755.
35. André P. Evaluation of the safety of a non-animal stabilized hyaluronic acid (NASHA, Q-Medical, Sweden) in European countries: A retrospective study from 1997 to 2001. *J Eur Acad Dermatol Venerol*. 2004;18:422.
36. Distante F, Bandiere, Bellini R, et al. Studio multicentrico italiano sull'efficacia e la tollerabilità dell'acido ialuronico di origine non animale (Restylane) nel trattamento degli inestetismi del volto. *Gio Ital Dermatol Venerol*. 2001;136:293.
37. Hoenig JF, Brink U, Korabiowska M. Severe granulomatous allergic tissue reaction after hyaluronic acid injection in the treatment of facial lines and its surgical correction. *J Craniofac Surg*. 2003;14:197.
38. Apikian M, Roberts S, Goodman GJ. Adverse reactions to polylactic acid injections in the periorbital area. *J Cosmet Dermatol*. 2007;6:95.
39. Lemperle G, Rullan PP, Gauthier-Hazan N. Avoiding and treating dermal filler complications. *Plast Reconstr Surg*. 2006; 118 (Suppl. 3S):92S.
40. Vargas-Machuca I, Gonzalez-Guerra E, Angulo J, del Carmen Farina M, Martin L, Requena L. Facial granulomas secondary to Dermalive microimplants: Report of a case with histopathologic differential diagnosis among the granulomas secondary to different injectable permanent filler materials. *Am J Dermatopathol*. 2006;28:173.
41. Angus JE, Affleck AG, Leach IH, Millard LG. Two cases of delayed granulomatous reactions to the cosmetic filler Dermalive[®], a hyaluronic acid and acrylic hydrogel. *Br J Dermatol*. 2006;155:1077.
42. Reisberger E-M, Landthaler M, Wiest L, et al. Foreign body granulomas caused by polymethylmethacrylate microspheres. *Arch Dermatol*. 2003;139:17.
43. Lloret P, Espana A, Leache A, et al. Successful treatment of granulomatous reactions secondary to injection of esthetic implants. *Dermatol Surg*. 2005;31:486.
44. Carroll LA, Hanasono MM, Mikulec AA, et al. Triamcinolone stimulates bFGF production and inhibits TGF- β 1 production by human dermal fibroblasts. *Dermatol Surg*. 2002;28:704.
45. Oishi Y, Fu ZW, Ohnuki Y, et al. Molecular basis of the alteration in skin collagen metabolism in response to in vivo dexamethasone treatment: Effects on the synthesis of collagen type I and III, collagenase, and tissue inhibitors of metalloproteinases. *Br J Dermatol*. 2002;147:859.
46. Schoepe S, Schaecke H, May E, Asadullah K. Glucocorticoid therapy-induced skin atrophy. *Exp Dermatol*. 2006;15:406.
47. Fardet L, Flahault A, Kettaneh A, et al. Corticosteroid-induced clinical adverse events: Frequency, risk factors and patient's opinion. *Br J Dermatol*. 2007;157:142.
48. Cramer JE. Intra-lesional injection of triamcinolone. *Australas J Dermatol*. 1964;13:140.
49. Myers E, Shea CR, Krausz T, Petronic-Rosic V. Eosinophilic granuloma of the skin: Response to intralesional corticosteroid injection. *J Drugs Dermatol*. 2007;6:329.
50. Overholt MA, Tschen JA, Font RL. Granulomatous reaction to collagen implant: Light and electron microscopic observations. *Cutis* 1993;51:95.
51. Morton AH, Shannon P, Chen A, et al. Increased frequency of acute local reaction to intra-articular Hylan G-F 20 (Synvisc) in patients receiving more than one course of treatment. *J Bone Joint Surg (Am.)* 2003;85:2050.
52. Zardawi IM. Granulomatous inflammation after Hylan G-F 20 visco supplementation of the knee. *J Bone Joint Surg (Am.)* 2003;85:2484.
53. DeBree R, Middelweerd MJ, van der Waal I. Severe granulomatous inflammatory response induced by injection of polyacrylamide gel into facial tissue. *Arch Facial Plast Surg*. 2004;6:204.
54. Apikian M, Goodman G. Intralesional 5-fluorouracil in the treatment of keloid scars. *Australas J Dermatol*. 2004;45:140.
55. Lambros V. The use of hyaluronidase to reverse the effects of hyaluronic acid filler. *Plast Reconstr Surg*. 2004;114:277.
56. Nuutinen P, Autio P, Hurskainen T, et al. Glucocorticoid action on skin collagen: Overview on clinical significance and consequences. *J Eur Acad Dermatol Venerol*. 2001;15:361.
57. Espana A, Solana T, Quintanilla E. Bleomycin in the treatment of keloids and hypertrophic scars by multiple needle punctures. *Dermatol Surg*. 2001;27:23.
58. Yosipovitch G, Widjanti SM, Goon A, et al. A comparison of the combined effect of cryotherapy and corticosteroid injections versus corticosteroids and cryotherapy alone on keloids: A controlled study. *J Dermatol Treat*. 2001;12:87.
59. Asilian A, Darougheh A, Shariati F. New combination of triamcinolone, 5-fluorouracil, and pulsed-dye laser for treatment of keloid and hypertrophic scars. *Dermatol Surg*. 2006; 32:907.
60. Lee JH, Kim SE, Lee A-Y. Effects of interferon- α 2b on keloid treatment with triamcinolone acetonide intralesional injection. *Int J Dermatol*. 2008;47:183.
61. Carruthers A, Carruthers JDA. Polymethylmethacrylate microspheres/collagen as a tissue augmenting agent: Personal experience over 5 years. *Dermatol Surg*. 2005;31:1561.
62. Fisher D. Adverse effects of topical corticosteroid use. *West J Med*. 1995;162:123.
63. Fitzpatrick RE, Manuskiatti W. Laser, steroid, and 5-FU therapy appear comparable for keloid scars. *Arch Dermatol*. 2002; 138:1149.
64. Conejo-Mir JS, Guirado SS, Munoz MA. Adverse granulomatous reaction to Artecoll treated by intralesional 5-fluorouracil and triamcinolone injections. *Dermatol Surg*. 2006; 32:1079.
65. Narins RS, Brandt F, Leyden J, et al. Randomized, double-blind, multicenter comparison of the efficacy and tolerability of Restylane versus Zyplast for the correction of nasolabial folds. *Dermatol Surg*. 2003;29:588.

AQ: 12

66. Saray Y, Guelec T. Treatment of keloids and hypertrophic scars with dermojet injections of bleomycin: A preliminary study. *Int J Dermatol*. 2005;44:777.
67. Garcia-Domingo MI, Alijtas-Reig J, Cistero-Bahima A, et al. Disseminated and recurrent sarcoid-like granulomatous panniculitis due to bovine collagen injection. *J Invest Allergol Clin Immunol*. 2000;10:107.
68. Sanchez Garcia V, Sanz Trelles A. Superficial granulomatous pyoderma: Successful treatment with minocycline. *J Eur Acad Dermatol Venerol*. 2006;20:1134.
69. Aivaliotis M, Kontochristopoulos G, Hatzilou E, Aroni K, Zakopoulou N. Successful cholicine administration in facial granulomas caused by cosmetic implants: Report of a case. *J Dermatol Treatment* 2007;18:112.
70. Baumann LS, Kerdel F. The treatment of bovine collagen allergy with cyclosporin. *Dermatol Surg*. 1999;25:247.
71. Jain S, Stephens CJM. Successful treatment of disseminated granulomas annulare with topical tacrolimus. *Br J Dermatol*. 2004;150:1042.
72. Gelfer A, Carruthers A, Carruthers J, Jang F, Bernstein SC. The natural history of polymethylmethacrylate microspheres granulomas. *Dermatol Surg*. 2007;33:614.
73. Bouzani N, Davis SC, Nouri K. Laser treatment of keloids and hypertrophic scars. *Int J Dermatol*. 2007;46:80.
74. Wolfram D, Tzankov A, Piza-Katzer H. Surgery for foreign body reactions due to injectable fillers. *Dermatology* 2006; 213:300.
75. El-Shafey El-SI. Complications from repeated injection or puncture of polyacrylamide gel implant sites: Case reports. *Aesthetic Plast Surg*. 2008;32:162.
76. Soparkar CN, Patrinely JR, Tschen J. Erasing Restylane. *Ophthalm Plast Reconstr Surg*. 2004;20:317.

AUTHOR QUERIES

AUTHOR PLEASE ANSWER ALL QUERIES

1

AQ1: AUTHOR—Please confirm that ref. 2 is the reference number wanted for Interfall.

AQ2: AUTHOR—Is ref. 1 meant here, or is it the beginning of a list of three items?

AQ3: AUTHOR—Please supply the name and city/state location of the maker of Dexacort, or use the generic drug name.

AQ4: AUTHOR—Please supply the name and city/state location of the maker of Diprosone, or delete the brand name and use just the generic drug name. Please do the same for Allopurinol in the next sentence.

AQ5: AUTHOR—Please supply the name and city/state locations of the makers of Kenalog and Volon A, or delete the brand names and use just the generic drug names.

AQ6: AUTHOR—Please supply the name and city/state location of the maker of Celestone.

AQ7: AUTHOR—Please expand “pro” in “175 mg pro twice daily.”

AQ8: AUTHOR—Please supply the name and city/state location of the maker of Aldara.

AQ9: AUTHOR—Is “16-gauge trocar” meant for “16G trocar”?

AQ10: AUTHOR—Ref. 1: Please supply folio (cm²⁹ in this issue).

AQ11: AUTHOR—Please complete ref. 12.

AQ12: AUTHOR—Please supply third author’s initial in ref. 34.