

UC Davis

UC Davis Previously Published Works

Title

Degenerative Cervical Myelopathy: A Practical Approach to Diagnosis

Permalink

<https://escholarship.org/uc/item/5085n3bg>

Journal

Global Spine Journal, 12(8)

ISSN

2192-5682

Authors

Tetreault, Lindsay
Kalsi-Ryan, Sukhvinder
Davies, Benjamin
[et al.](#)

Publication Date


2022-10-01





DOI

10.1177/21925682211072847

Peer reviewed

Degenerative Cervical Myelopathy: A Practical Approach to Diagnosis

Global Spine Journal
2022, Vol. 12(8) 1881–1893
© The Author(s) 2022
Article reuse guidelines:
sagepub.com/journals-permissions
DOI: 10.1177/21925682211072847
journals.sagepub.com/home/gsj


Lindsay Tetreault, MD, PhD¹, Sukhvinder Kalsi-Ryan, BScPT, MSc, PhD^{2,3}, Benjamin Davies, MRCS, BSc, MPhil, MBChB(Hons)⁴ , Laura Nanna-Lohkamp, MD, MSc^{5,6} , Philip Garwood, MB, BCh, BAO (Hons)⁷, Allan R. Martin, MD, PhD, FRCSC⁸, Jefferson R. Wilson, MD, PhD, FRCSC⁵ , James S. Harrop, MD, MSHQS, FACS⁹, James D. Guest, MD, PhD, FACS¹⁰, Brian K. Kwon, MD, PhD, FRCSC¹¹, James Milligan, MD¹², Alberto Martinez Arizala, MD, FAAN¹⁰, Mark R. Kotter, MD, PhD⁴, and Michael G. Fehlings, MD, PhD^{5,6} 

Abstract

Study Design: Narrative Review.

Objectives: The objective of this review is to provide a stepwise approach to the assessment of patients with potential symptoms of degenerative cervical myelopathy (DCM).

Methods: N/A

Results: DCM is an overarching term used to describe progressive compression of the cervical spinal cord by age-related changes to the spinal axis. These alterations to normal anatomy narrow the spinal canal, reduce the space available for the spinal cord, and may ultimately compress the ascending and descending neural tracts. Patients with DCM present with a wide range of symptoms that can significantly impact quality of life, including bilateral hand numbness and paresthesia, gait impairment, motor weakness of the upper and lower extremities, and bladder and bowel dysfunction. Unfortunately, DCM is often misdiagnosed, resulting in delayed assessment and management by the appropriate specialist. The proper evaluation of a patient with suspected DCM includes obtaining a detailed patient history, conducting a comprehensive neurological examination, and ordering appropriate tests to rule in or out other diagnoses.

Conclusion: This review summarizes a stepwise approach to the diagnosis of patients with DCM.

¹Division of Neurology, Graduate Medical Education, New York University Langone, New York, NY, USA

²Toronto Rehabilitation Institute, University Health Network, Toronto, ON, Canada

³Department of Physical Therapy, University of Toronto, Toronto, ON, Canada

⁴Department of Academic Neurosurgery, University of Cambridge, Cambridge, UK

⁵Division of Neurosurgery, Department of Surgery, University of Toronto, Toronto, ON, Canada

⁶Division of Neurosurgery, Spinal Program, Toronto Western Hospital, University Health Network, Toronto, ON, Canada

⁷Internal Medicine Resident, Department of Medicine, University of Toronto, Toronto, ON, Canada

⁸Spine Neurosurgery, University of California Davis, Davis, CA, USA

⁹Departments of Neurological and Orthopedic Surgery, Thomas Jefferson University, Philadelphia, PA, USA

¹⁰The Miami Project to Cure Paralysis, University of Miami, Miami, FL, USA

¹¹Department, of Orthopaedics, University of British Columbia, Vancouver, BC, Canada

¹²Department of Family Medicine, McMaster University, Hamilton, ON, Canada

Corresponding Author:

Michael G. Fehlings, MD, PhD, FRCSC, FACS, Division of Neurosurgery and Spinal Program, Department of Surgery, University of Toronto, Krembil Neuroscience Centre, Toronto Western Hospital, 399 Bathurst Street, Suite 4WW-449, Toronto, ON M5T 2S8, Canada.

Email: michael.fehlings@uhn.ca



Creative Commons Non Commercial No Derivs CC BY-NC-ND: This article is distributed under the terms of the Creative Commons Attribution-NonCommercial-NoDerivs 4.0 License (<https://creativecommons.org/licenses/by-nc-nd/4.0/>) which permits non-commercial use, reproduction and distribution of the work as published without adaptation or alteration, without further permission provided the original work is attributed as specified on the SAGE and Open Access pages (<https://us.sagepub.com/en-us/nam/open-access-at-sage>).

Keywords

degenerative cervical myelopathy, cervical spondylotic myelopathy, ossification of the posterior longitudinal ligament, diagnosis

Introduction

Degenerative cervical myelopathy (DCM) is an overarching term used to describe progressive compression of the cervical spinal cord by age-related changes to the spinal axis.¹ These changes include facet arthropathy, spondylosis, and disc degeneration; subluxation of the vertebral bodies; and hypertrophy, ossification, or calcification of the supporting ligaments.² These alterations to the normal anatomy narrow the spinal canal, reduce the space available for the spinal cord, and may ultimately compress the ascending and descending neural tracts.³ In addition to static spinal cord compression, hypermobility and instability of the spinal column may cause chronic, repetitive injury to the neural elements. Injury to the spinal cord, whether through static or dynamic mechanisms, initiates a series of pathological events, including vascular changes, neuroinflammation, disruption of the brain–spinal cord barrier, and apoptosis.^{4,5} These cellular events subsequently result in demyelination, neuronal loss, and astrogliosis.

In a systematic review of the literature, Boogaarts and Bartels⁶ (2013) were unable to identify studies discussing the incidence or prevalence of DCM. They did, however, estimate that 1.6 per 100,000 individuals in their area were operated on for symptomatic cervical spondylotic myelopathy. Similarly, in a study by Kokubun et al⁷ (1996), the annual rate of surgical intervention for individuals with DCM was 5.7 per 100,000 residents in a northeastern region of Japan (estimated population 2.6 million). Finally, Nouri et al³ (2015) estimated the incidence and prevalence of DCM to be at least 41 and 605 per million, respectively, in North America. Although the exact incidence and prevalence of DCM are unknown, it is anticipated that, with an aging population, clinicians worldwide will be expected to manage an increasing number of patients with degenerative spine disease.⁸ As a result, there needs to be an improved understanding of the diagnosis, assessment, and monitoring of this condition.

DCM is often misdiagnosed, resulting in delayed assessment and management by the appropriate specialist. In a systematic review by Karadimas et al⁹ (2013), moderate evidence suggested that approximately 20 to 62% of patients with DCM exhibit clinical deterioration by 3 to 6 years if not managed surgically. Given the potential for disease progression, a diagnosis must be made promptly and patients should be referred in a timely fashion to an appropriate specialist. In a study by Behrbalk et al¹⁰ (2013), the mean time to diagnosis of DCM was 2.2±2.3 years (range 1.7 months to 8.9 years) after the first physician visit. Furthermore, patients, on average, attended 5.2±3.6 physician visits with DCM-related complaints before obtaining a diagnosis. DCM was commonly mistaken for carpal tunnel syndrome and cervical radiculopathy without neurological deficit. Finally, a study by Radcliff et al¹¹ (2016) identified a higher incidence of

undiagnosed cervical myelopathy among patients with hip fractures compared to a control population.

The objectives of this review are to provide a stepwise approach to the assessment of patients with potential symptoms of DCM.

Assessment of Patients With Potential Symptoms of DCM

A proper assessment of a patient with suspected DCM includes obtaining a detailed patient history, conducting a comprehensive neurological examination, and ordering appropriate tests to rule in or out other diagnoses. This section will summarize a stepwise approach to the evaluation of patients with potential symptoms of DCM.

Obtain a Detailed Patient History

It is estimated that 70 to 90% of medical diagnoses can be made by history alone.¹² Important principles for taking a medical history include to (i) ask a combination of open-ended and specific questions; (ii) provide adequate time for a patient to respond; (iii) actively listen and ask for clarification when necessary; and (iv) avoid medical jargon.¹² Table 1 summarizes important open-ended and specific questions that should be asked to a patient with suspected DCM.

According to a systematic review by Kim et al¹³ (2013), there are several diagnoses that can mimic DCM, including amyotrophic lateral sclerosis (ALS), peripheral nerve entrapment, and vitamin B12 deficiency. Furthermore, any process that compresses or damages the neural tracts within the spinal cord can also present like DCM. These differential diagnoses can be divided into compressive and non-compressive myelopathies and can often be distinguished based on medical history (Table 2).

Perform a Comprehensive Physical Examination

A physical examination that assesses motor and sensory function, coordination, reflexes, and tone is required to identify and localize problems of the nervous system. A complete neurological examination also consists of assessment of the cranial nerves and mental status; however, these components are not relevant to the evaluation of suspected DCM and will not be discussed in this article. They must be considered in cases where other potential diagnoses should be excluded.

DCM presents as bilateral motor and/or sensory deficits in the upper and lower extremities without facial involvement. Furthermore, patients with DCM have a combination of lower and upper motor neuron signs. Lower motor neuron signs can be localized to a particular level as they are caused by

Table 1. A Summary of Important Open-Ended and Specific Questions to Ask a Patient with Suspected Degenerative Cervical Myelopathy.**Open-ended questions**

- What brings you in today?
- When did your symptoms start? When was the first time you noticed your symptoms, even in a milder form than they are today?
- Have your symptoms gotten worse over time?
- Was there anything in particular you were doing when your symptoms started?
- Have you tried anything to relieve your symptoms? Has anything improved your symptoms?
- What makes your symptoms worse?
- Is there a particular time of day when your symptoms are worse?
- How do your symptoms affect your quality of life and activities of daily living?

Myelopathy-specific questions*A. Upper extremity symptoms*

- Do you have numbness or tingling in your arms or hands?
- Have you noticed any weakness in your hands?
- Do you often drop things like your phone or your pen?
- Do you have difficulties tying up buttons or your shoelaces?
- Have you noticed a change in your handwriting?
- Do you have difficulties opening jars or bottles?

B. Lower extremity symptoms

- Do you have numbness or tingling in your legs or feet?
- Do you feel unsteady when walking?
- Have you ever lost your balance? Have you ever fallen? Is your balance worse in the dark?
- Do you need to use the handrail when walking up and down the stairs?
- Has anyone mentioned to you that you are walking differently?

C. Bladder and bowel symptoms and sexual function

- Have you ever had a hard time urinating despite having the need to?
- Do you ever get a strong urge to urinate with little warning?
- Have you ever lost control of your bladder?
- Have you ever lost control of your bowel?
- Do you ever experience difficulties with sexual performance? Have you taken any medications to enhance your sexual performance?

D. Pain

- Do you have any pain in your neck, shoulders, or arms? If yes, can you describe the pain? Does the pain radiate anywhere? Is the pain constant or does it come and go? What makes the pain worse? What makes the pain better? Is the pain worse when lying down, sitting, or standing?
- If you put your chin to your chest, do you have the sensation that there is an electrical shock moving down your spine or into your arms?

Specific questions that may point to an alternative diagnosis

- Do you suffer from headaches?
- Have you noticed any changes in your vision (eg, blurred vision, sensitivity to light, or changes in color perception)?
- Do you have trouble swallowing?
- Has anyone mentioned to you that your voice has changed?
- Do you have any tingling or numbness in your face?
- Do you have difficulty hearing or ringing in your ears?
- Have you noticed any changes in your memory?
- Have you ever lost consciousness?
- Have you ever had a seizure?

compression of specific nerve roots as they leave the spinal canal. In contrast, upper motor neuron signs are elicited below the level of the lesion. [Table 3](#) summarizes important components of the physical examination for DCM and outlines the differences between upper and lower motor neuron signs. [Figure 1](#) provides an overview of the clinical pathway to the diagnosis of DCM.

Acquire Imaging of the Cervical Spinal Axis and Cord

If DCM is suspected from a patient's history and physical examination, the next best step is to acquire imaging of the cervical spinal axis and cord ([Figure 2](#)).

Plain Radiographs

Plain radiographs are generally the initial imaging modality for evaluating a patient with suspected DCM.¹ Although radiographs cannot visualize the spinal cord, they provide versatile two-dimensional views of the spinal axis that can depict various sources of pathology.¹⁴ For example, lateral radiographs are useful for evaluating spinal alignment and disc spaces. The swimmer's view can be obtained if C7 to T1 cannot be visualized on a normal lateral image.¹⁵ Anterior–posterior radiographs are useful for identifying uncovertebral joint spurs and assessing the vertebral bodies, intervertebral spaces, and pedicles. Finally, right and left oblique views

Table 2. Distinguishing Differential Diagnoses of Degenerative Cervical Myelopathy through Medical History.

Type of myelopathy	Differential diagnosis	Important clues in the medical history
Compressive myelopathies	Trauma	<ul style="list-style-type: none"> •Sudden onset of neurological symptoms following a traumatic event
	Spinal dural arteriovenous malformation	<ul style="list-style-type: none"> •Difficult to distinguish on history alone
	Epidural hematoma	<ul style="list-style-type: none"> •Recent history of a procedure that involves a spinal dural puncture •Medical history of thrombocytopenia or bleeding disorders •Current use of anti-platelets or anticoagulants •Presents as severe localized pain followed by loss of sensory, motor, and autonomic function
	Neoplasms, including meningioma, epidural metastasis, schwannoma, astrocytoma, ependymoma, and hemangioblastoma	<ul style="list-style-type: none"> •Known primary tumor •May have non-specific, constitutional symptoms such as fatigue, weight loss, and malaise
	Spinal epidural abscess	<ul style="list-style-type: none"> •Difficult to distinguish on history alone •Recent spinal surgery or another invasive spinal procedure •Medical history of diabetes, HIV, or alcoholism •May have fever
	Syringomyelia	<ul style="list-style-type: none"> •Medical history of a Chiari malformation •May also be post-infectious, post-inflammatory, or post-traumatic •May have loss of sensitivity to pain and temperature in neck, shoulders, forearms, or hands •May have headache, facial numbness, or thoracic kyphoscoliosis •May have an occipital headache, cranial nerve palsies, severe neck pain, or cerebellar symptoms
Non-compressive myelopathies	Chiari malformations	<ul style="list-style-type: none"> •May have an occipital headache, cranial nerve palsies, severe neck pain, or cerebellar symptoms
	Spinal cord infarction	<ul style="list-style-type: none"> •Recent surgery involving the aorta •Recent episode of severe hypotension or cardiac arrest •Medical history of atherosclerosis, hypercoagulable disorders, vasculitis, or embolism
	Nutritional deficiencies (vitamin B12 or vitamin E)	<ul style="list-style-type: none"> •Medical history of gastric malabsorption syndromes (eg, Crohn's disease, pernicious anemia, cholestatic hepatobiliary disease, pancreatic insufficiency, and short-bowel syndrome), abetalipoproteinemia, or tapeworm infection •Personal history of veganism or reduced vitamin intake •Additional symptoms vary depending on specific nutritional deficiency
	Copper deficiency	<ul style="list-style-type: none"> •Recent history of gastrointestinal surgery or excessive zinc ingestion
	Infectious myelitis (HIV, HTLV-I, Lyme disease, tertiary syphilis, and schistosomiasis)	<ul style="list-style-type: none"> •History of recent viral infection •Recent travel history •May have fever, headache, or meningism •Additional symptoms vary depending on type of infection
	Transverse myelitis	<ul style="list-style-type: none"> •Medical history of multiple sclerosis, neuromyelitis optica, systemic lupus erythematosus, mixed connective tissue disease, Sjogren's syndrome, scleroderma, antiphospholipid syndrome, or rheumatoid arthritis •Symptoms often develop rapidly over several hours •May have other systemic symptoms
	Neurosarcoidosis	<ul style="list-style-type: none"> •Symptoms often depend on whether the brain, spinal cord, or cranial nerves are affected •May also present with symptoms similar to diabetes insipidus, hypopituitarism, optic neuritis, and meningitis
	Radiation-induced myelopathy Metabolic and toxic myelopathies	<ul style="list-style-type: none"> •History of radiation therapy 2 to 12 months ago •History of cloiquinol use or substance abuse (eg, heroin and nitrous oxide) •Recent immigration from a third world country

Table 3. Relevant Components of the Neurological Examination in Patients with Suspected Degenerative Cervical Myelopathy.

	Description	Upper motor neuron signs in degenerative cervical myelopathy	Lower motor neuron signs in degenerative cervical myelopathy
Motor exam			
Inspection	Inspect several muscle groups for wasting, fasciculations, tremors, or any other involuntary movements. Observe posture and spinal alignment	None	Fasciculations or atrophy of muscles in the upper extremities. Myelopathic hand
Assessment of muscle tone	Ask the patient to relax, passively move each limb at multiple joints, and feel for any resistance to movement	Increased tone below the level of spinal cord compression. Lower limb spasticity	Reduced tone of the muscles supplied by the compressed nerve root
Functional testing	Check for pronator drift by asking a patient to hold up both of their arms with forearms in supination and close their eyes for 30 seconds. A positive test is one in which the forearm pronates with or without a downward shift. Check rapid finger tapping	Positive pronator drift. Slowed finger tapping	N/A
Evaluate the strength of individual muscle groups	Assess the strength of a muscle group that corresponds with each nerve root. Evaluate for any differences in strength between the right and left side. Strength is rated from 0 to 5. 0/5: No contraction 1/5: Muscle flicker, but no movement 2/5: Movement possible, but not against gravity 3/5: Movement possible against gravity, but not against resistance by the examiner 4/5: Movement possible against some resistance by examiner 5/5: Normal strength	Pyramidal distribution of weakness; weakness in the extensors of the upper extremities and flexors of the lower extremities	Reduced strength in the muscles supplied by the compressed nerve root
Assess the reflexes	Assess each deep tendon reflex using a reflex hammer and compare with the contralateral side to detect any asymmetries. 0: Absent reflex 1+: Trace or seen only with reinforcement 2+: Normal 3+: Brisk 4+: Non-sustained clonus 5+: Sustained clonus	Hyperreflexia of deep tendon reflexes or clonus. Spreading of reflexes to other muscles not directly being tested. Crossed adduction of the opposite leg when the medial aspect of the knee is tapped. Flexion and adduction of the thumb when flicking the middle fingernail downward (<i>Hoffmann's sign</i>). Hyperactive finger flexion when eliciting the brachioradialis reflex (<i>Inverted supinator sign</i>). Hyperreflexive shoulder adduction and internal rotation when stimulating the pectoralis tendon. Hyperreflexive knee extension when stimulating the suprapatellar tendon of the quadriceps. Upgoing plantar responses	Hyporeflexia or absent reflexes. Downgoing plantar responses
Assess coordination	Evaluate a patient's ability to accurately perform the finger-to-nose and heel to shin tests	A patient may not be able to perform these tests accurately due to weakness in the upper or lower extremities	

(continued)

Table 3. (continued)

	Description	Upper motor neuron signs in degenerative cervical myelopathy	Lower motor neuron signs in degenerative cervical myelopathy
Observe gait	Assess a patient's walking	Broad-based unstable gait. Spastic gait. Positive Romberg's sign. Impaired tandem gait	
Sensory exam			
Evaluate sensation	Evaluate a patient's response to pinprick, temperature, light touch, vibration and proprioception to assess the integrity of the spinothalamic tracts, dorsal columns, and peripheral sensory nerves	N/A	N/A

display the neural foramina as well as uncovertebral and facet joints.

Radiographs provide useful information on bone quality, cervical alignment, and can identify osteophytes, spondylosis as well as ossification of the posterior longitudinal ligament.¹⁴ Spinal alignment is best evaluated under load-bearing conditions (eg, while sitting or standing), which cannot be achieved in traditional computed tomography or magnetic resonance imaging (MRI) scanners.¹⁴ Specific measurements of cervical alignment include cervical lordosis, sagittal plane translation, and horizontal gaze. Cervical lordosis is assessed by computing the C1 or C2 to C7 Cobb angle; this is done by measuring the angle between two lines parallel to the C1 or C2 and the C7 inferior plate.¹⁶ According to Batzdorf and Batzdorf, a patient with ideal cervical alignment will have no portion of the C3 to C6 vertebra cross a line drawn from the posteroinferior aspect of the C2 vertebral body to the posteroinferior aspect of the C7 vertebral body.¹⁶ Sagittal plane translation is evaluated by computing the distance between the C2 or C7 plumb line and the posterior superior corner of the sacrum.¹⁶ Regional cervical sagittal alignment is often computed by drawing a plumb line from the center of C2 to the posterior superior aspect of C7. Horizontal gaze is also a useful measure of cervical lordosis and is assessed by the chin-brow vertical angle.¹⁷ This angle is measured between a vertical line from the forehead and a line drawn between the eyebrow and chin. Finally, T1 slope is the angle between a line along the superior endplate of T1 and a horizontal reference line.¹⁶ Long cassette or three-foot standing radiographs may also be used to assess global spinal alignment as pathology below the cervical region often impacts cervical alignment.¹⁸

Radiographic views in flexion and extension postures can help depict spondylolisthesis as well as cervical instability and be used to calculate sagittal range of motion.¹⁴ This information is essential for surgical planning, can influence the surgical approach, and help decide whether fixation is necessary. Finally, post-operative radiographs are useful for assessing fusion status and the position of bone grafts, pedicle

screws, cages, and plates.¹⁴ Postoperative films can also be compared to preoperative images to evaluate correction of cervical alignment and issues with instability.

Computed Tomography

Computed Tomography (CT) provides three-dimensional images of the spinal axis and can help detect bony abnormalities and ossification of ligamentous structures. Unfortunately, in CT images, there is usually little contrast between the cervical spinal cord and subarachnoid space, preventing visualization of intradural processes, intramedullary lesions, and cord compression. CT scans, however, can be used to classify the type of OPLL, determine the extent of the ossification, and assess bone quality.¹⁹ They are also used to measure screw trajectories if instrumentation is required, navigate intraoperatively, and assess the location of metallic hardware such as pedicle screws and plates.¹⁴ CT is the imaging modality of choice in patients who cannot undergo MRI due to ocular metallic foreign bodies, pacemakers, stimulators, embedded wires, aneurysm clips, nitroglycerin patches, or severe claustrophobia.²⁰ Finally, although not routine practice, CT angiography can visualize anomalies of the vertebral arteries and identify cases with a higher risk of injury.²¹

Magnetic Resonance Imaging

MRI is the preferred modality for assessing patients with DCM as it provides high resolution, multiplanar images of the neural, soft-tissue, and bony structures.²² Furthermore, MRI can clearly depict the extent of spinal canal stenosis and the presence of cord compression, intramedullary signal changes, and bony constriction of the neural foramina.²³ Finally, MRI is useful to exclude other disease processes of the cervical spine that may clinically present like DCM, such as neoplastic infiltration, demyelinating plaques, and syringomyelia.

Several tools can be used to qualify and quantify the extent of degenerative changes, the degree of canal stenosis and cord compression, and the presence of intramedullary signal

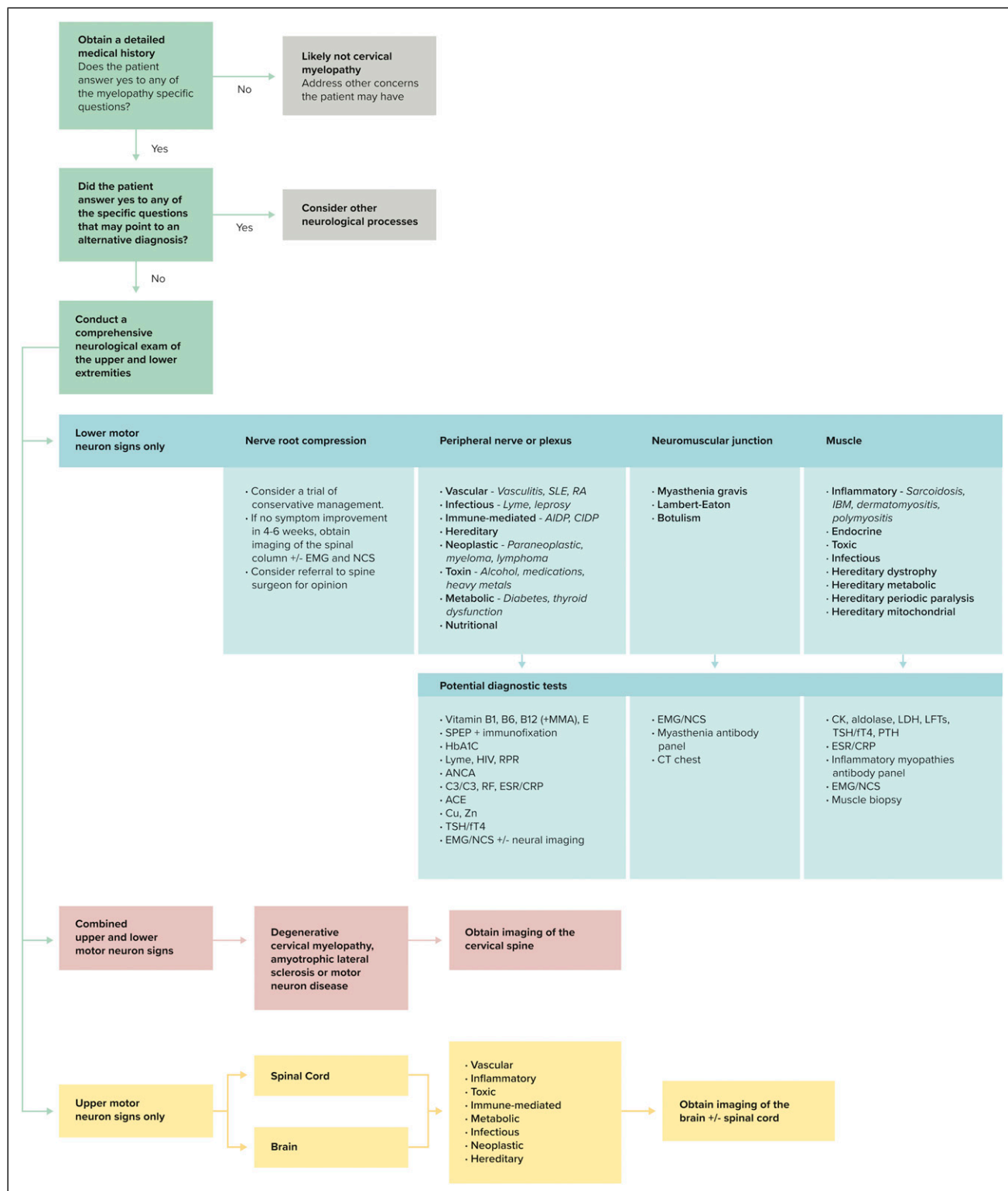


Figure 1. An approach to the diagnosis of degenerative cervical myelopathy. EMG, electromyography; NCS, nerve conduction studies; SLE, systemic lupus erythematosus; AIDP, acute inflammatory demyelinating polyneuropathy; CIDP, chronic inflammatory demyelinating polyneuropathy; IBM, inclusion body myositis; SPEP, serum protein electrophoresis; HIV, human immunodeficiency virus; RPR, rapid plasma reagin; ANCA, antineutrophil cytoplasmic antibody; C3/C4, complement 3/4; RF, rheumatoid arthritis; ESR, erythrocyte sedimentation rate; CRP, C-reactive protein; ACE, angiotensin-converting enzyme; Cu, copper; Zn, zinc; TSH, thyroid stimulating hormone; ft4, free T4; CT, computed tomography; CK, creatinine kinase; LDH, lactate dehydrogenase; LFTs, liver function tests; PTH, parathyroid hormone.

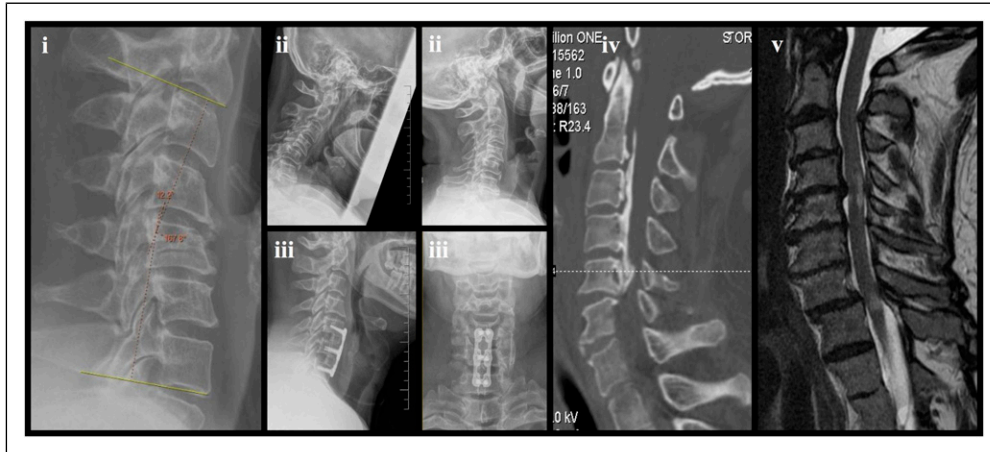


Figure 2. The role of various imaging modalities in the diagnosis and management of degenerative cervical myelopathy. (i) Lateral radiograph for the assessment of cervical alignment; (ii) flexion-extension radiographs for evaluation of spondylolisthesis and cervical instability; (iii) post-operative radiographs for assessment of fusion status and the position of instrumentation; (iv) computed tomography scans for the detection of bony abnormalities and ossification of the posterior longitudinal ligament; and (v) magnetic resonance imaging for the evaluation of the extent of spinal canal stenosis, degree of cord compression, and presence of intramedullary signal change.

change on MRI.²⁴ These classification systems and mathematical equations are summarized in Table 4.

Advanced Imaging Techniques

Although conventional MRI has revolutionized the ability to visualize the neural elements, it still has its limitations. Specifically, certain MRI findings often do not correlate with a patient's clinical presentation or disease severity. Several advanced imaging techniques are available that quantify physical properties of neural tissues and better detect injury to the axons and myelin of the white matter tracts.¹⁴ These include diffusion tensor imaging (DTI), magnetization transfer (MT), myelin water fraction (MWF), and MR spectroscopy. Metrics derived from these modalities are more sensitive at detecting subclinical tissue injury and myelopathy progression than conventional MRI and may be more accurate at predicting surgical outcomes.

Electrophysiology

Electrophysiological tests are not routinely used to diagnose patients with DCM.¹ However, they can assess the functional involvement of the spinal cord and help bridge the gap between MRI findings and a patient's clinical picture. Furthermore, neurophysiological tests are valuable for excluding other mimicking diagnoses, identifying the presence of concomitant radiculopathy, and monitoring disease progression.²⁵

Electromyography (EMG) is the study of the electrical activity of muscles and is used to evaluate the integrity of the motor unit. EMG assesses insertional activity, spontaneous activity of the muscle at rest, the motor unit action potential (MUAP) during minimal voluntary contraction, and the recruitment of motor units during increasing voluntary contraction. Increased electrical activity following insertion of an

electrode into a muscle is abnormal and is commonly seen in denervation, myotonia, and inflammatory conditions.²⁶ In contrast, a decrease in insertional activity may reflect atrophic and/or fibrotic muscle. In terms of spontaneous activity at rest, fibrillations and positive sharp waves occur in cases of denervation, typically 10 to 14 days after acute nerve injury.²⁶ Fasciculations can be a normal finding but can also be seen in motor neuron disease, radiculopathies, entrapment neuropathies, and metabolic disorders.²⁶ Myokymia or bursts of MUAPs can occur normally in the orbicularis oculi or oris muscles but may also be present in radiculopathies, radiation plexopathies, and anterior horn cell syndromes.²⁷ Voluntary activity can be used to distinguish acute and chronic patterns of denervation as well as neuropathies from myopathies.²⁶ Individuals with complete denervation will have no MUAP, whereas those with chronic denervation will have increased MUAP amplitude. This increased amplitude is because re-innervation following nerve damage results in an increased number of muscle fibers controlled by a single motor unit.²⁶ Myopathic MUAPs, in contrast, have decreased amplitude which helps distinguish myopathic from neuropathic processes. Finally, a pattern of reduced recruitment is observed in neuropathic disease. In contrast, the force generated by individual motor units is reduced in myopathic disease; a greater number of units must therefore be recruited in order to produce a certain level of force.

EMG studies can be used to identify changes in muscle recruitment and activation in patients with DCM (Table 5). Since EMG directly measures the activity of specific muscles, it may be a useful tool for monitoring disease progression, assessing recovery after surgery, and evaluating motor improvement following a trial of rehabilitation. A study by Haddas et al²⁸ (2019) compared EMG data from patients with signs, symptoms, and imaging evidence of DCM to healthy controls aged 50 to 70 years. Based on their results, patients with DCM had a

Table 4. A Summary of Classification Systems Used to Qualify and Quantify the Extent of Degenerative Changes on Magnetic Resonance Imaging in Patients with Degenerative Cervical Myelopathy.

Feature of degenerative cervical myelopathy	Description and classification on magnetic resonance imaging	Comments	
Disc degeneration	Miyazaki et al (2008): (25)	This grading system considers the signal intensity and structure of the nucleus pulposus, the delineation between the nucleus pulposus and the annulus fibrosus, and the disc height	
	Grade I: Hyperintense nucleus SI; homogenous, white nuclear structure; clear distinction of nucleus and annulus; normal disc height		
	Grade II: Hyperintense nucleus SI; inhomogeneous with horizontal band, white nuclear structure; clear distinction of nucleus and annulus; normal disc height		
	Grade III: Intermediate nucleus SI; inhomogeneous, gray to black nuclear structure; unclear distinction of nucleus and annulus; normal to decreased disc height		
	Grade IV: Intermediate nucleus SI; inhomogeneous, gray to black nuclear structure; unclear distinction of nucleus and annulus; normal to decreased disc height		
	Grade V: Hypointense nucleus SI; inhomogeneous, gray to black nuclear structure; lost distinction of nucleus and annulus; normal to decreased disc height		
	Grade VI: Hypointense nucleus SI; inhomogeneous, gray to black nuclear structure; lost distinction of nucleus and annulus; collapsed disk		
	Suzuki et al (2017):(26)		High signal intensity is defined as similar intensity as CSF and/or bone marrow. Decreased intensity is defined as lower intensity than bone marrow
	Grade 0, no degeneration: Normal disc height; hyperintense and homogenous nucleus; clear distinction of nucleus and annulus; no disc bulge/herniation		
	Grade 1, mild degeneration: Normal disc height; hyperintense and inhomogenous nucleus or decrease of SI; clear or unclear distinction of nucleus and annulus; no disc bulge or herniation		
Grade 2, moderate degeneration: Normal to slight decrease in disc height; decrease of nucleus SI; unclear distinction between nucleus and annulus; positive disc bulge or herniation			
Grade 3, severe degeneration: Decreased disc height; decreased nuclear SI; unclear distinction between nucleus and annulus; positive disc bulge or herniation			
Jacobs et al (2016):(27)	Spinal alignment is best evaluated under load-bearing conditions (eg, while sitting or standing), which cannot be achieved in traditional magnetic resonance imaging scanners. Spinal alignment is best evaluated on lateral radiographs		
Grade 0: Normal height compared to C2–3, with or without a cleft in the nucleus pulposus			
Grade 1: Dark disc, with normal height			
Grade 2: Collapsed disc, little or no osteophytes			
Grade 3: Collapsed disc, many osteophytes			
Sagittal alignment	N/A	Spinal alignment is best evaluated on lateral radiographs	
Spondylolisthesis	N/A	Spondylolisthesis is best evaluated on flexion and extension radiographs. Meyerding classification grades the degree of vertebral displacement as follows: (28) I: <25% displacement II: ≥25%, <50% displacement III: ≥50%, <75% displacement IV: ≥75%, <100% displacement V: ≥100% displacement	

(continued)

Table 4. (continued)

Feature of degenerative cervical myelopathy	Description and classification on magnetic resonance imaging	Comments
Vertebral body changes	Modic et al (1988): (29) Type I: Low signal on T1, high signal on T2 Type II: High signal on T1, isointense to high signal on T2 Type III: Low signal on T1, low signal on T2	Type I: Inflammatory changes and bone marrow edema Type II: local fatty replacement of bone marrow due to ischemia Type III: Reactive subchondral bony sclerosis
Spinal canal stenosis	Degree of spinal canal stenosis (30) 0: Normal width of the spinal canal, no signs of anterior or posterior subarachnoid space narrowing 1: Partial obliteration of anterior or posterior subarachnoid space or both 2: Complete obliteration of anterior or posterior subarachnoid space or both 3: Anterior or posterior cord impingement or both Occupying ratio: Sagittal diameter of the spinal cord divided by sagittal diameter of the neural tube (31) Anterior-posterior diameter of the canal at the level of interest $MCC = (1 - Di/(Da + Db)/2) \times 100\%$ (32)	Qualitative assessment of spinal canal stenosis on sagittal imaging Quantitative assessment of spinal canal stenosis on sagittal imaging. Di is the anteroposterior canal diameter at the level of maximum compression. Da and Db are the anteroposterior diameters of the non-compressed levels from above and below the level of maximum compression
Spinal cord compression	Degree of spinal cord compression: (33) 0: No thecal sac compression 1: Minimal degree of subarachnoid space compression 2: Mild spinal cord compression 3: Severe compression or cord atrophy Partial vs circumferential compression at the site of greatest compression (34) Ratio between the anteroposterior diameter of the compressed segment to the anteroposterior diameter of the non-compressed segment (35) Compression ratio: Ratio between the anteroposterior diameter and the transverse diameter (35) $MSCC = (1 - di/(da + db)/2) \times 100\%$ (32)	Qualitative assessment of spinal cord compression on sagittal images Qualitative assessment of spinal cord compression on axial images Quantitative assessment of spinal cord compression on sagittal images Quantitative assessment of spinal cord compression on axial images. Cord compression typically results in a reduction of the anteroposterior diameter and an increase in the lateral diameter Quantitative assessment of spinal cord compression on sagittal images. di is the anteroposterior spinal cord diameter at the level of maximum compression. da and db are the anteroposterior diameters of non-compressed levels from above and below the level of maximum compression
Signal changes	Number of levels compressed Hyperintensity on T2WI (24) Type 1: Faint, fuzzy, indistinct borders Type 2: Intense, well-defined borders Hypointensity on T1WI (24)	N/A Nonspecific; may indicate either reversible or non-reversible histological damage. Edema, Wallerian degeneration, demyelination, ischemia, gliosis Similar to hypointensity on T1WI Irreversible histological damage. Necrosis, myelomalacia, cavitation, spongiform changes in the grey matter

SI, signal intensity; CSF, cerebrospinal fluid; MCC, maximum canal compromise; MSCC, maximum spinal cord compression; T2WI, type 2-weighted images; T1WI, type 1-weighted images.

Table 5. A Summary of Important Electromyographic Findings in Patients with Degenerative Cervical Myelopathy.

Component of electromyography	Definition	Clinical relevance
Insertional activity		
Increased	Continued burst firing of action potentials after needle movement has stopped	Seen in denervation, myotonia, and inflammatory conditions
Decreased	Decreased activity following insertion of an electrode into a muscle	Seen in atrophic or fibrotic muscle
Spontaneous activity		
Fibrillation potentials	Action potentials of single muscle fibers that fire spontaneously in the absence of innervation	Seen in muscles that have lost their innervation, are regenerating, or have never been innervated
Fasciculation potentials	Spontaneous single motor unit discharges generated anywhere along the motor unit	May be normal but can also be seen in neuromuscular disorders, radiculopathies, axonal peripheral neuropathies, and anterior horn cell disorders
Complex repetitive discharges	Action potentials of a group of muscle fibers that discharge spontaneously and in near synchrony in a regular, repetitive manner	Nonspecific finding but can be seen in chronic, longstanding neurogenic or myopathic disorders
Myotonic discharges	Action potentials of single muscle fibers that fire spontaneously and are prolonged after external excitation	Reflects abnormality of the membrane of a muscle fiber. Seen in myotonic dystrophy, myotonia congenita, hyperkalemic periodic paralysis, and polymyositis
Myokymic discharges	Action potentials that fire spontaneously and in a repetitive burst pattern	Seen in radiation-induced nerve injury, chronic compressive neuropathies, polyradiculopathies, and anterior horn cell disorders
Neuromyotonic discharges	Bursts of action potentials that originate in motor axons and fire at high frequencies	Seen in disorders of peripheral nerve hyperexcitability
Cramp potentials	Involuntary, repetitive firing of action potentials at a high frequency in a large area of muscle	Seen in chronic neurogenic disorders, metabolic or electrolyte disorders, or peripheral nerve hyperexcitability
Minimal voluntary activity		
None	No motor unit action potentials	Seen in acute denervation
Increased	Increased amplitude of motor unit action potentials	Seen in chronic denervation with reinnervation
Decreased	Decreased amplitude of motor unit action potentials	Seen in myopathic processes
Recruitment pattern		
Increased	Increasing effort results in increased motor unit firing rate and increased motor unit activation	Seen in myopathic process
Decreased	Increasing effort results in more rapid firing in a reduced number of motor units	Seen in neuropathic process

significantly longer time to peak EMG in the multifidus, erector spinae, semi-tendinosus, tibialis anterior, and deltoid muscles compared to controls. However, the time to onset of muscle contraction and the peak EMG values were similar between cohorts. These findings indicate that patients with DCM are slower at fully recruiting muscles for a particular movement compared to healthy controls. This study also reported prolonged activation of the biceps femoris muscles in patients with DCM, indicating that the proximal muscles likely compensate for a lack of power generation in the distal muscles. Similarly, Malone et al²⁹ (2013) reported a significantly longer coactivation time between the rectus femoris and bicep femoris muscles in patients with DCM, confirming that the proximal muscles act to stabilize the lower leg. Furthermore, the normalized amplitude of the inactive phase of these proximal muscles was higher in patients with DCM compared to controls. This finding indicates that individuals with myelopathy are unable to scale down the output of these muscles when their activation is not required. Finally,

patients with DCM may also require prolonged activation of the tibialis anterior muscle in order to increase the stability of the ankle during stance due to impaired proprioception. Peak EMG is also higher in the medial deltoid muscles, indicating that patients may use their upper extremities in a compensatory manner in an attempt to improve balance.

Nerve conduction studies are performed to quantify the motor and sensory velocities of peripheral nerves. Two electrodes are first placed at two different points along a peripheral nerve. Conduction velocities are then computed by dividing the time from the onset of stimulus to the recorded response by the distance between the two electrodes.³⁰ Nerve conduction studies are typically normal in patients with DCM and compressive radiculopathies but are often slowed in peripheral nerve entrapment, peripheral neuropathies, and brachial plexopathies.³¹ As such, nerve conduction studies may be useful in distinguishing DCM from common mimickers, especially carpal tunnel syndrome.

Somatosensory evoked potentials (SEPs) can identify injury anywhere along the dorsal column-medial lemniscal pathway.³² This pathway is initiated by stimulating the large myelinated afferent fibers in a peripheral nerve. These nerves carry information about proprioception, vibration, and fine touch into the dorsal root ganglion where the cell bodies are located. The axons then travel ipsilaterally through the dorsal columns and synapse on second order neurons in the dorsal column nuclei in the medulla oblongata. Axons of the second sensory neuron desiccate as internal arcuate fibers and form the medial lemniscus which ascends to the thalamus. A third and final sensory neuron travels from the thalamus to the somatosensory cortex. The spinal potential N13 reflects the activity of the dorsal horn neurons that receive their inputs from the afferent sensory fibers.³¹ The loss of spinal N13 is found in patients with DCM and is considered a reliable diagnostic tool. Specifically, in a study by Restuccia et al³³ (1992), abnormalities in the N13 potential were found in 95% of radial, 90% of medial, and 54% of ulnar nerve SEPs in 11 patients with image-evidence of DCM.

Motor-evoked potentials (MEPs) can detect injury to the descending motor pathways following transcranial magnetic stimulation of the motor cortex. In patients with DCM, MEPs can help localize the levels of motor dysfunction and detect subclinical involvement of central motor pathways. Furthermore, MEPs can help distinguish DCM from ALS. Specifically, patients with DCM tend to have slower central motor conduction times in myelomeres distal to the level of spinal cord compression, whereas patients with ALS can have normal conduction times in caudal myelomeres.³¹ SEPs and MEPs may also be useful in predicting disease development in individuals with image evidence of spinal cord compression or canal stenosis but no symptoms of myelopathy. Specifically, according to Bednarik et al³⁴ (2008), nonmyelopathic patients with evidence of spondylosis or disc compression of the cervical spinal cord were more likely to develop myelopathy if they had abnormal MEPs and SEPs. Finally, SEPs and MEPs can be used to quantify sensory and motor improvements following surgery and are useful for detecting neurological injury intraoperatively.³⁵

Acknowledgments

MGF would like to acknowledge support from the Gerry and Tootsie Halbert Chair in Neural Repair and Regeneration.


Declaration of Conflicting Interests

The author(s) declared no potential conflicts of interest with respect to the research, authorship, and/or publication of this article.


Funding

The author(s) received no financial support for the research, authorship, and/or publication of this article.

ORCID iDs

Benjamin Davies, MRCS, BSc, MPhil, MBChB(Hons)  <https://orcid.org/0000-0003-0591-5069>

Laura Nanna-Lohkamp, MD, MSc  <https://orcid.org/0000-0001-8027-0569>

Jefferson R. Wilson, MD, PhD, FRCSC  <https://orcid.org/0000-0001-5965-0305>

Michael G. Fehlings, MD, PhD  <https://orcid.org/0000-0002-5722-6364>

References

1. Tetreault L, Goldstein CL, Arnold P, et al. Degenerative cervical myelopathy. *Neurosurgery*. 2015;77(suppl 4):S51-S67. doi:10.1227/NEU.0000000000000951.
2. Yamaguchi S, Mitsuhara T, Abiko M, Takeda M, Kurisu K. Epidemiology and overview of the clinical spectrum of degenerative cervical myelopathy. *Neurosurg Clin*. 2018;29:1-12. doi:10.1016/j.nec.2017.09.001.
3. Nouri A, Tetreault L, Singh A, Karadimas SK, Fehlings MG. Degenerative cervical myelopathy. *Spine*. 2015;40:E675-E693. doi:10.1097/BRS.0000000000000913.
4. Akter F, Kotter M. Pathobiology of degenerative cervical myelopathy. *Neurosurg Clin*. 2018;29:13-19. doi:10.1016/j.nec.2017.09.015.
5. Kalsi-Ryan S, Karadimas SK, Fehlings MG. Cervical spondylotic myelopathy. *Neuroscientist*. 2013;19:409-421. doi:10.1177/1073858412467377.
6. Boogaarts HD, Bartels RHMA. Prevalence of cervical spondylotic myelopathy. *Eur Spine J*. 2015;24(suppl 2):139-141. doi:10.1007/s00586-013-2781-x.
7. Kokubun S, Sato T, Ishii Y, Tanaka Y. Cervical myelopathy in the Japanese. *Clin Orthop Relat Res*. 1996;323:129-138. doi:10.1097/00003086-199602000-00018.
8. Fehlings MG, Tetreault L, Nater A, et al. The aging of the global population. *Neurosurgery*. 2015;77(suppl 4):S1-S5. doi:10.1227/NEU.0000000000000953.
9. Karadimas SK, Erwin WM, Ely CG, Dettori JR, Fehlings MG. Pathophysiology and natural history of cervical spondylotic myelopathy. *Spine*. 2013;38:S21-S36. doi:10.1097/BRS.0b013e3182a7f2c3.
10. Behrbalk E, Salame K, Regev GJ, Keynan O, Boszczyk B, Lidar Z. Delayed diagnosis of cervical spondylotic myelopathy by primary care physicians. *Neurosurg Focus*. 2013;35:E1. doi:10.3171/2013.3.FOCUS1374.
11. Radcliff KE, Curry EP, Trimba R, et al. High incidence of undiagnosed cervical myelopathy in patients with hip fracture compared with controls. *J Orthop Trauma*. 2016;30:189-193. doi:10.1097/BOT.0000000000000485.
12. Muhrer JC. The importance of the history and physical in diagnosis. *Nurse Pract Am J Prim Health Care*. 2014;39:30-35. quiz 36. doi:10.1097/01.NPR.0000444648.20444.e6.
13. Kim HJ, Tetreault LA, Massicotte EM, et al. Differential diagnosis for cervical spondylotic myelopathy. *Spine*. 2013 1976; 38:S78-S88. doi:10.1097/BRS.0b013e3182a7eb06.

14. Martin AR, Tadokoro N, Tetreault L, et al. Imaging evaluation of degenerative cervical myelopathy. *Neurosurg Clin*. 2018;29:33-45. doi:10.1016/j.nec.2017.09.003.
15. Toksoy A, Bektas F, Eken C, Ceken K, Cete Y. Value of the swimming position and arm traction in visualizing the cervicothoracic junction over the standard lateral cervical X-ray. *Int J Emerg Med*. 2010;3:85-90. doi:10.1007/s12245-010-0159-y.
16. Ames CP, Blondel B, Scheer JK, et al. Cervical radiographical alignment. *Spine*. 2013 1976;38:S149-S160. doi:10.1097/BRS.0b013e3182a7f449.
17. Patel PD, Arutyunyan G, Plusch K Jr AV Jr, Vaccaro AR. A review of cervical spine alignment in the normal and degenerative spine. *Journal of Spine Surgery*. 2020;6:106-123. doi:10.21037/jss.2020.01.10.
18. Ramchandran S, Smith JS, Ailon T, Klineberg E, Shaffrey C, Lafage V, et al. Assessment of impact of long-cassette standing x-rays on surgical planning for cervical pathology. *Neurosurgery*. 2016;78:717-724. doi:10.1227/NEU.0000000000001128.
19. Tetreault L, Nakashima H, Kato S, et al. A systematic review of classification systems for cervical ossification of the posterior longitudinal ligament. *Global Spine J*. 2019;9:85-103. doi:10.1177/2192568217720421.
20. Houser OW, Onofrio BM, Miller GM, Folger WN, Smith PL. Cervical spondylotic stenosis and myelopathy: evaluation with computed tomographic myelography. *Mayo Clin Proc*. 1994;69:557-563. doi:10.1016/s0025-6196(12)62248-4.
21. Goldberg AL, Kershah SM. Advances in imaging of vertebral and spinal cord injury. *The Journal of Spinal Cord Medicine*. 2010;33:105-116. doi:10.1080/10790268.2010.11689685.
22. Nagata K, Kiyonaga K, Ohashi T, Sagara M, Miyazaki S, Inoue A. Clinical value of magnetic resonance imaging for cervical myelopathy. *Spine*. 1990 1976;15:1088-1096. doi:10.1097/00007632-199011010-00002.
23. Sun Q, Hu H, Zhang Y, et al. Do intramedullary spinal cord changes in signal intensity on MRI affect surgical opportunity and approach for cervical myelopathy due to ossification of the posterior longitudinal ligament? *Eur Spine J*. 2011;20:1466-1473. doi:10.1007/s00586-011-1813-7.
24. Nouri A, Martin AR, Mikulis D, Fehlings MG. Magnetic resonance imaging assessment of degenerative cervical myelopathy: a review of structural changes and measurement techniques. *Neurosurg Focus*. 2016;40:E5. doi:10.3171/2016.3.FOCUS1667.
25. Tracy JA, Bartleson JD. Cervical spondylotic myelopathy. *Neurol*. 2010;16:176-187. doi:10.1097/NRL.0b013e3181da3a29.
26. Horowitz S. *Overview of Electromyography*; 2011.
27. Gutmann L. AAEM minimonograph #37: facial and limb myokymia. *Muscle Nerve*. 1991;14:1043-1049. doi:10.1002/mus.880141102.
28. Haddas R, Cox J, Belanger T, Ju KL, Derman PB. Characterizing gait abnormalities in patients with cervical spondylotic myelopathy: a neuromuscular analysis. *Spine J*. 2019;19:1803-1808. doi:10.1016/j.spinee.2019.06.005.
29. Malone A, Meldrum D, Gleeson J, Bolger C. Electromyographic characteristics of gait impairment in cervical spondylotic myelopathy. *Eur Spine J*. 2013;22:2538-2544. doi:10.1007/s00586-013-2928-9.
30. Mallik A, Weir AI. Nerve conduction studies: essentials and pitfalls in practice. *J Neurol Neurosurg Psychiatr*. 2005;76(suppl 2):ii23-ii31. doi:10.1136/jnnp.2005.069138.
31. Nardone R, Höller Y, Brigo F, et al. The contribution of neurophysiology in the diagnosis and management of cervical spondylotic myelopathy: a review. *Spinal Cord*. 2016;54:756-766. doi:10.1038/sc.2016.82.
32. Passmore SR, Murphy B, Lee TD. The origin, and application of somatosensory evoked potentials as a neurophysiological technique to investigate neuroplasticity. *J Can Chiropr Assoc*. 2014;58:170-183.
33. Restuccia D, Lazzaro VD, Valeriani M, Tonali P, Manguiere F. Segmental dysfunction of the cervical cord revealed by abnormalities of the spinal N13 potential in cervical spondylotic myelopathy. *Neurol Now*. 1992;42:1054. doi:10.1212/wnl.42.5.1054.
34. Bednarik J, Kadanka Z, Dusek L, et al. Presymptomatic spondylotic cervical myelopathy: an updated predictive model. *Eur Spine J*. 2008;17:421-431. doi:10.1007/s00586-008-0585-1.
35. Park J-H, Hyun SJ. Intraoperative neurophysiological monitoring in spinal surgery. *World Journal of Clinical Cases*. 2015;3:765-773. doi:10.12998/wjcc.v3.i9.765.