

# UC Davis

## Dermatology Online Journal

### Title

Granuloma inguinale in a 51-year-old man

### Permalink

<https://escholarship.org/uc/item/52k0c4hj>

### Journal

Dermatology Online Journal, 22(4)

### Authors

Ornelas, Jennifer  
Kiuru, Maija  
Konia, Thomas  
[et al.](#)

### Publication Date

2016

### DOI

10.5070/D3224030657

### Copyright Information

Copyright 2016 by the author(s). This work is made available under the terms of a Creative Commons Attribution-NonCommercial-NoDerivatives License, available at <https://creativecommons.org/licenses/by-nc-nd/4.0/>

Peer reviewed

## Case presentation

### Granuloma inguinale in a 51-year-old man

Jennifer Ornelas BA<sup>1</sup>, Maija Kiuru MD<sup>2</sup>, Thomas Konia MD<sup>2</sup>, Larissa Larsen MD<sup>2</sup>

Dermatology Online Journal 22 (4): 10

<sup>1</sup>School of Medicine, UC Davis, Sacramento, CA

<sup>2</sup>Department of Dermatology, UC Davis, Sacramento, CA

## Correspondence:

Larissa Larsen, MD  
3301 C Street, Suite 1400  
Sacramento, CA 95816  
Phone: 916-703-5145  
Email: lnlarsen@ucdavis.edu

---

## Abstract

Granuloma inguinale, or Donovanosis, is a rare, sexually transmitted ulcerative disease primarily affecting the genital area. In this report, we present a case of a 50-year-old man that was diagnosed with granuloma inguinale after a 2-month history of a penile ulcer. Histological analysis demonstrated the presence of *Donovan bodies within macrophages*, confirming the diagnosis. He was subsequently treated with trimethoprim/sulfamethoxazole with improvement in the ulcer. This case serves as a reminder to clinicians that although granuloma inguinale is rarely encountered in the US, it should still be suspected in patients with non-healing penile ulcers.

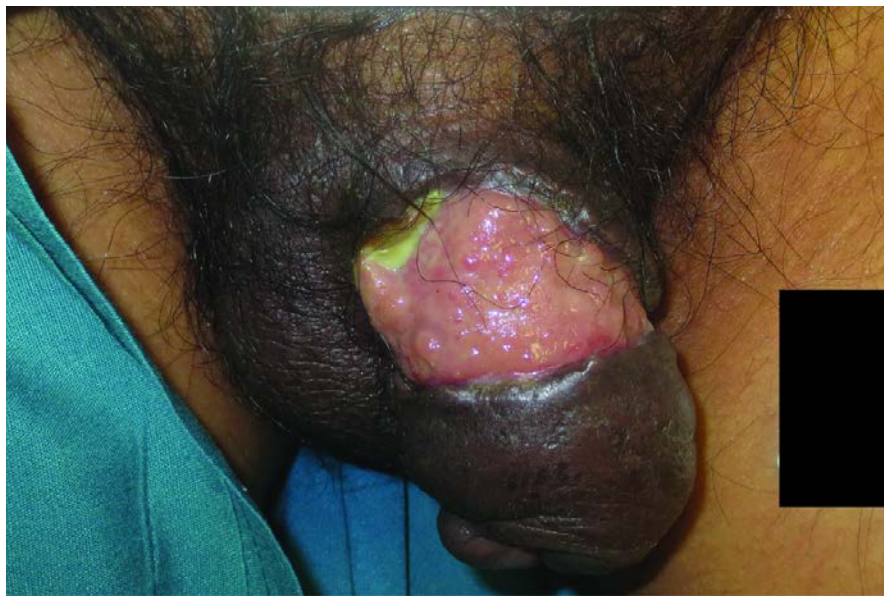**Keywords:** Granuloma inguinale, Donovanosis, *Klebsiella granulomatis*, sexually transmitted infection, penile ulcer

## Introduction

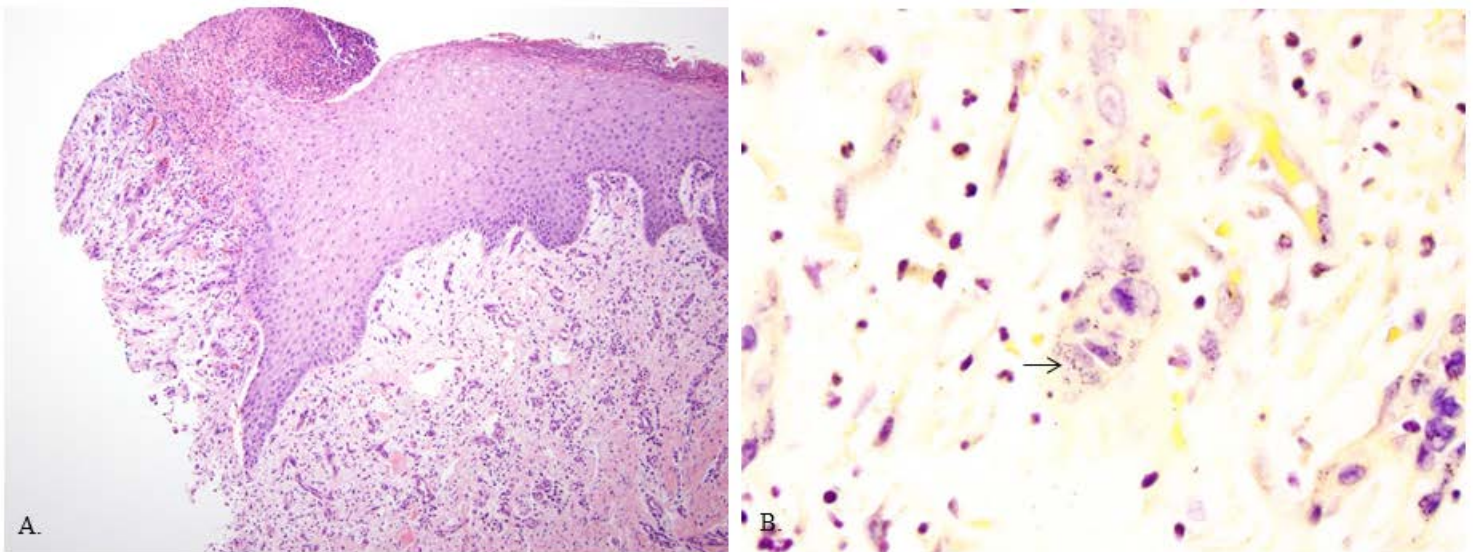
Granuloma inguinale, also known as Donovanosis, is a rare sexually transmitted ulcerative disease that causes painless ulcers in the genital and peri-genital areas. Although it is typically found in tropical and subtropical climates [1-3], a small number of cases have been reported in the US and Canada [4-6]. Granuloma inguinale can be treated with antibiotic therapy thus avoiding spread to other individuals and long-term complications [2, 3, 7-10].

## Case synopsis:

A 50-year-old man presented with a two-month history of a rash on his penis. He had initially been provided nystatin powder for a suspected candidal infection prior to presentation in our clinic. However, his rash progressed and he was subsequently admitted to a community hospital. He received treatment with clindamycin and ciprofloxacin, as well as other unknown intravenous antibiotics for suspected cellulitis. The eruption progressed into an ulcer and he was discharged from the hospital after 9 days when his ulcer stopped progressing in size. He was suspected to have penile cancer, as he was not responsive to antibiotic treatment. He had no history of fever, chills, or sexually transmitted infections.



**Figure 1.** Circumferential full thickness ulcer on the shaft of the penis. Significant edema of the surrounding area extending from the penile tip to the testicles.



**Figure 2.** A) Low magnification view of skin biopsy B) High magnification view of skin biopsy. Arrow pointing to intrahistiocytic gram-negative rods, or Donovan bodies. Consistent with *Klebsiella granulomatis*.

Physical exam revealed a circumferential full thickness ulcer on the shaft of the penis with significant edema and associated pain of the surrounding tissue extending from the penile tip to the testicles (Figure 1). No inguinal lymphadenopathy was noted. Histological examination of a skin biopsy revealed multiple intrahistiocytic gram-negative rods consistent with Donovan bodies seen in *Klebsiella granulomatis* infections (Figure 2).

The patient was diagnosed with granuloma inguinale and subsequently treated with trimethoprim/sulfamethoxazole 160/800 mg twice daily for 3 weeks. During treatment it was recommended that he abstain from intercourse until the ulcer was completely healed. In California, Center for Disease Control and Prevention (CDC) reporting is not mandated for this disease, so he was asked to inform sexual partners. The patient's ulcer was completely healed at a follow-up appointment 6 weeks later.

## Discussion

As mentioned above, granuloma inguinale is typically found in tropical and subtropical climates, including Australia, Brazil, India, Indonesia, Papua New Guinea, and South Africa [1-3]. However, multiple cases have been reported in the Caribbean, Central America, French Guiana, and Peru [3]; a small number of cases have been reported in the US and Canada [4-6]. Although one study conducted in India did find an incidence of 1.53% amongst all STD cases presenting in a 22-month period, it is difficult to estimate the true prevalence of granuloma inguinale given its low incidence and difficult clinical diagnosis [11, 12].

Granuloma inguinale is commonly thought to be spread via sexual contact, yet has a low rate of transmission to sexual partners [1, 3]. It is also thought to possibly spread through fecal contamination and autoinoculation as *Klebsiella granulomatis* has been isolated from fecal samples from individuals with granuloma inguinale [1, 13]. Moreover, cases have been reported in which the infection passed to infants during vaginal delivery, often affecting the ear structures of newborns [14], though no congenital infections have been reported [3].

Granuloma inguinale is caused by infection with *Klebsiella granulomatis*, a gram-negative, non-motile, pleomorphic bacteria. Although *K. granulomatis* may be encapsulated in its mature form, it can be un-encapsulated and demonstrate a safety pin appearance in its immature form [1]. After initial inoculation, the incubation period may last from days to weeks, with an average duration of approximately 50 days [1, 3].

Initially, a single papule or multiple papules or nodules appear in the genital area. They then progress and grow into a painless ulcer that can affect adjacent tissue through self-inoculation, but rarely involve the lymph nodes [1-3]. In men, commonly affected areas include the balano-preputial region, as seen in the patient presented here, as well as the coronal sulcus area, and the anus [3]. Women are commonly affected in the labia minora, vaginal fucula, and cervix [3]. Primary extragenital lesions are rare; most extragenital lesions are the results of spread from an initial genital lesion [1, 3]. Infection can lead to complications, including phimosis, as well as urethral, vaginal, and anal stenosis. Moreover, it can mimic cervical and ovarian carcinoma and spread to cause cervical lymphadenopathy, osteomyelitis, and septic arthritis [8-10].

Diagnosis is made via physical exam and histological analysis. Biopsies or tissue smears can be stained using Giemsa, Wright, silver, or gram stains and demonstrate the presence of characteristic inclusion bodies, or Donovan bodies [1, 3]. During silver staining a fraction of silver is deposited in a section after reduction by the slide and another portion is deposited by reduction of the developer [15]. Consequently, silver staining can be used to visualize the capsules of encapsulated bacteria, such as the mature form of *K. granulomatis* [16]. However, as silver stains are also capable of staining lipopolysaccharides, they can be used to visualize the outer layer of the cell wall of gram negative bacteria [17, 18]. Giemsa or Giemsa-Wright stains contain dyes that stain acidic structures of the cell blue and basic structures orange to pink [17]. As a result, *K. granulomatis* is stained a blue-purple color allowing for its visualization [19, 20].

As *K. granulomatis* is difficult to culture, a culture is not necessary for diagnosis [2, 7]. A polymerase chain reaction colorimetric assay has been developed for the detection of the disease, but a diagnosis is often still made with histological analysis [3, 21].

The World Health Organization recommends first line therapy of doxycycline 100 mg taken orally twice daily or azithromycin 1g taken orally once weekly or 1 g taken on the first day followed by 500 mg daily for 3 weeks, or until all lesions have completely healed [3, 7]. Alternatively, the CDC recommends azithromycin alone as first line therapy [2]. Other treatment options include ciprofloxacin 750 mg twice daily, erythromycin 500 mg four times daily, or trimethoprim/sulfamethoxazole 800 mg/160mg twice daily, all for 3 weeks or until complete healing of all lesions [1-3, 7]. If no improvement is seen following the first few days of treatment, an aminoglycoside may be added, such as gentamycin 1 mg/kg, given every eight hours via intramuscular or intravenous injection [1-3]. However, in complicated cases antibiotic treatment alone may not be sufficient and surgical intervention may be necessary [1-3].

Following initiation of treatment, patients should be followed to ensure that all symptoms resolve. Patients should also undergo testing for other sexually transmitted infections, including human immunodeficiency virus, gonorrhea, and syphilis, because *K. granulomatis* can coexist with other pathogens responsible for sexually transmitted infections [2]. This is especially important because co-infection with human immunodeficiency virus can lead to a complicated disease course and may need longer antibiotic treatment [1, 3].

The U.S. Centers for Disease Control and Prevention (CDC) is a federal agency under the Department of the Health and Human Services. The CDC is responsible for coordinating interstate and international responses to communicable diseases and public health dilemmas. However, the decision of which individual sexually transmitted infections must be reported to the CDC is under individual state jurisdiction. As the patient mentioned in this case report was diagnosed in the state of California, which does not require reporting of cases of granuloma inguinale, informing and testing of his sexual partners was not mandated.

## Conclusion

Granuloma inguinale, or Donovanosis, is a rare sexually transmitted ulcerative disease that is uncommonly found in the US. Herein we presented the case of a 51-year-old man who was diagnosed with granuloma inguinale following a two-month history of a non-healing penile ulcer. Although it is rare in the US, granuloma inguinale should be included in the differential diagnosis for non-healing painless genital ulcers presenting without lymphadenopathy.

## References

1. Basta-Juzbasic, A. and R. Ceovic, *Chancroid, lymphogranuloma venereum, granuloma inguinale, genital herpes simplex infection, and molluscum contagiosum*. Clin Dermatol, 2014. 32(2): p. 290-8. [PMID:24559566]
2. Velho, P.E., E.M. Souza, and W. Belda Junior, *Donovanosis*. Braz J Infect Dis, 2008. 12(6): p. 521-5. [PMID: 19287842]
3. Markle, W., T. Conti, and M. Kad, *Sexually transmitted diseases*. Prim Care, 2013. 40(3): p. 557-87. [PMID: 23958358]
4. Golfo, E.B. and L.M. Galindo, *Diagnosis of an unusual abdominal presentation of granuloma inguinale by fine needle aspiration cytology*. Acta Cytol, 1990. 34(4): p. 570-2. [PMID: 2375227]
5. Hacker, P., Fisher, B.K., Dekoven, J., and Shier, R.M., *Granuloma inguinale: three cases diagnosed in Toronto, Canada*. Int J Dermatol, 1992. 31(10): p. 696-9. [PMID: 1399195]
6. Rashid, R.M., S.A. Janjua, and A. Khachemoune, *Granuloma inguinale: a case report*. Dermatol Online J, 2006. 12(7): p. 14. [PMID: 17459300]
7. *Guidelines for the Management of Sexually Transmitted Infections*. 2001, World Health Organization.
8. Barroso, L.F. and B. Wispelwey, *Donovanosis presenting as a pelvic mass mimicking ovarian cancer*. South Med J, 2009. 102(1): p. 104-5. [PMID: 19077787]
9. Fletcher, H.M., Rattray, C.A., Hanchard, B., Vaughan, K., West, W.M., *Disseminated donovanosis (granuloma inguinale) with osteomyelitis of both wrists*. West Indian Med J, 2002. 51(3): p. 194-6. [PMID: 12501553]
10. Taneja, S., Jena, A., Tangri, R., Sekhon, R., *Case report. MR appearance of cervical donovanosis mimicking carcinoma of the cervix*. Br J Radiol, 2008. 81(966): p. e170-2. [PMID: 18487384]
11. Morrone, A., Toma, K., Franco, G., and Latini, O., *Donovanosis in developed countries: neglected or misdiagnosed disease?* Int J STD AIDS, 2003. 14(4): p. 288-9. [PMID: 12716504]
12. Veeranna, S. and T.Y. Raghu, *A clinical and investigational study of donovanosis*. Indian J Dermatol Venereol Leprol, 2003. 69(2): p. 159-62. [PMID: 17642866]
13. Goldberg, J., *Studies on granuloma inguinale. V. Isolation of a bacterium resembling Donovanias granulomatis from the faeces of a patient with granuloma inguinale*. Br J Vener Dis, 1962. 38: p. 99-102. [PMID: 13899699]
14. Govender, D., K. Naidoo, and R. Chetty, *Granuloma inguinale (donovanosis): an unusual cause of otitis media and mastoiditis in children*. Am J Clin Pathol, 1997. 108(5): p. 510-4. [PMID: 9353089]
15. Samuel, E.P., *The mechanism of silver staining*. J Anat, 1953. 87(3): p. 278-87. [PMID: 13069383].
16. Gerstley, L., 3rd and H.E. Morton, *The demonstration of bacterial capsules by Fontana's staining procedure*. J Bacteriol, 1954. 67(1): p. 125-6. [PMID: 13117825].
17. Murray, P., Rosenthal, KS, and Pfaller, MA, *Medical Microbiology*. 7 ed. 2013: Elsevier Health Sciences.
18. Tsai, C.M. and C.E. Frasch, *A sensitive silver stain for detecting lipopolysaccharides in polyacrylamide gels*. Anal Biochem, 1982. 119(1): p. 115-9. [PID: 6176137].
19. Davis, C.M. and C. Collins, *Granuloma inguinale: an ultrastructural study of Calymmatobacterium granulomatis*. J Invest Dermatol, 1969. 53(5): p. 315-21. [PMID: 5347410]
20. O'Farrell, N., et al., *A rapid stain for the diagnosis of granuloma inguinale*. Genitourin Med, 1990. 66(3): p. 200-1. [PMID: 1695193]
21. Carter, J.S. and D.J. Kemp, *A colorimetric detection system for Calymmatobacterium granulomatis*. Sex Transm Infect, 2000. 76(2): p. 134-6. [PMID: 10858717]