

# UCLA

## UCLA Previously Published Works

### Title

Posterior mediastinal capillary hemangioma misdiagnosed as neurofibromas: a rare case report and review of the literature

### Permalink

<https://escholarship.org/uc/item/52r8b8kr>

### Journal

Rare Tumors, 7(1)

### ISSN

2036-3605

### Authors

Zeyaian, Bijam  
Soleimani, Neda  
Geramizadeh, Bita

### Publication Date

2015-02-18

### DOI

10.4081/rt.2015.5639

Peer reviewed

## Posterior mediastinal capillary hemangioma misdiagnosed as neurofibromas: a rare case report and review of the literature

Bijam Zeyaian,<sup>1</sup> Neda Soleimani,<sup>2</sup>  
Bitam Geramizadeh<sup>2,3</sup>

<sup>1</sup>Department of Surgery, <sup>2</sup>Department of Pathology, <sup>3</sup>Transplant Research Center, Shiraz University of Medical Sciences, Iran

### Abstract

Capillary hemangioma is a common benign tumor which can occur everywhere in the whole body, however its occurrence in posterior mediastinum is extremely rare, and to the best of our knowledge less than 20 cases have been reported in the English literature so far. Here in we report a 65-year-old lady who presented with prolonged cough and diagnosed to have a posterior mediastinal mass. Before operation, according to the site of tumor, it has been diagnosed as neurofibroma. It is very important to consider hemangioma before operation to reduce surgical complications, and it should be in the differential diagnosis of posterior mediastinal masses.

### Introduction

Mediastinal hemangioma is a rare lesion, and less than 0.5% of the mediastinal masses are hemangioma.<sup>1</sup> Most of these reported mediastinal hemangiomas have been in anterior part and of cavernous type.<sup>2</sup>

Herein we report an extremely rare case of posterior mediastinal mass that has been operated with the primary impression of neurofibroma and was diagnosed as capillary hemangioma after pathologic examination of the resected mass.

### Case Report

A 65-year old female, case of diabetes mellitus and hypertension, referred with chief complaint of productive cough for one year.

Physical examination and routine blood tests were unremarkable. No positive previous history has been noted, *i.e.* there has been no history of surgery or previous mass or tumor.

Plain chest-X-ray radiography showed a well defined round opacity in right side of mediastinum (Figure 1A). Spiral chest computed tomography with contrast showed a 5×5 cm mass in close contact to posterior chest wall and vertebra with peripheral enhancement and mild pleural effusion. Pressure effect on right main bronchus and mild displacement of esophagus was also present (Figure 1B).

Tru-cut biopsy was unsuccessful and no adequate tissue was yielded for definite diagnosis. It showed some mature adipose tissue and a few spindle-shaped cells and vessels. With the preliminary diagnosis of neurogenic tumor (neurofibroma) thoracotomy and complete excision was done for the patient and the mass sent for pathology.

Histopathology revealed that the mass consisted of small vessels of capillary caliber in vague lobular configuration with no atypia and low mitotic figures. There has been no hemorrhage and thrombosis (Figure 1C).

Diagnosis of capillary hemangioma was made. Now after 6 months, she is doing well and completely free of symptoms.

Correspondence: Bitam Geramizadeh, Department of Pathology, Transplant Research Center, Shiraz University of Medical Sciences, Shiraz, Iran.  
Tel./Fax: +98.711.6473238.  
E-mail: geramib@sums.ac.ir

Key words: mediastinum, capillary hemangioma.

Contributions: the authors contributed equally.

Conflict of interests: the authors declare no potential conflict of interests.

Received for publication: 18 September 2014.

Revision received: 19 December 2014.

Accepted for publication: 19 December 2014.

This work is licensed under a Creative Commons Attribution NonCommercial 3.0 License (CC BY-NC 3.0).

©Copyright B. Zeyaian et al., 2015  
Licensee PAGEPress, Italy  
Rare Tumors 2015; 7:5639  
doi:10.4081/rt.2015.5639

### Discussion

Mediastinal masses span a wide histopathological spectrum. They are divided into anterior, middle and posterior compartments. Anterior mediastinal tumors account for 50% of all mediastinal masses, including thymoma, teratoma, thyroid lesions and lymphoma. Masses of the middle mediastinum are typically congenital cysts while those arising in the posterior mediastinum are often neurogenic tumors.<sup>3</sup>

The first case of mediastinal hemangioma has been reported in 1914 by Shannon.<sup>4</sup> After that, more than 100 cases of mediastinal hemangioma have been reported in the

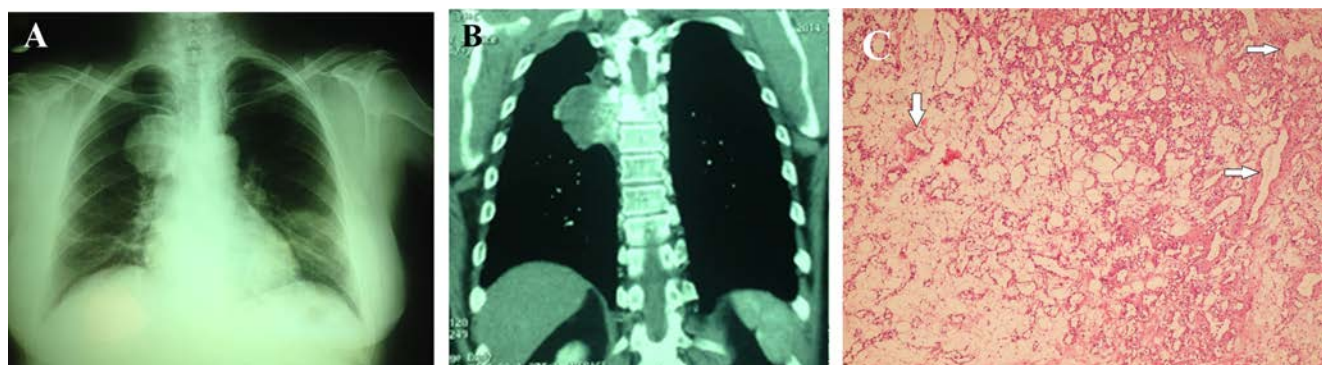


Figure 1. A) Chest X-ray shows a mediastinal mass. B) Computed tomography scan shows a large mass lesion measuring 5×5 cm in posterior segment of mediastinum. C) Sections from posterior mediastinal mass show vascular channels lined by normal endothelial cells (Hematoxylin & Eosin, 250×).

English literature.<sup>5</sup>

Almost all of the previously reported cases have been cavernous type in anterior mediastinum and to the best of our knowledge less than 20 cases of posterior mediastinal hemangioma have been reported in the English literature so far. Between these posterior mediastinal hemangiomas only 6 cases have been capillary type hemangioma.<sup>1,3,4</sup>

Most of the reported posterior mediastinal hemangiomas have been in female patients, in adults, but rare cases of pediatric patients have been reported.<sup>6</sup> Our patient has been a 65-year old lady who presented with prolonged cough, also, the most common presenting symptom in the previous cases has been pulmonary symptoms such as cough, and chest pain.<sup>7</sup>

The most challenging point in posterior mediastinal capillary hemangioma has been preoperative diagnosis, none of the previous cases had preliminary diagnosis of hemangioma and almost all of the cases have been operated with the preoperative diagnosis of neurogenic tumor such as neurofibroma.<sup>8-10</sup>

Calcification, and phlebolits are diagnostic signs in mediastinal hemangiomas, however these findings have been reported in less than 20% of the cases.<sup>10</sup>

Radiologically mediastinal hemangioma shows homogenous signal intensity which is very similar to neurogenic tumors such as paraganglioma and pheochromocytoma.<sup>10</sup> In MRI (magnetic resonance imaging) differences in signal intensity on T-1 and T-2 weighted images can be helpful and also

markedly high intensity on fat suppression T-2 weighted image might be a characteristic finding.<sup>5</sup> Our patient has been operated with preliminary diagnosis of neurofibroma, mostly because of posterior mediastinal location of the mass.

## Conclusions

The purpose of surgery in most of previous cases has been both diagnosis and treatment.<sup>8</sup> Endovascular embolization is also another option for removing mediastinal hemangioma, which can also reduce blood loss during surgery,<sup>7</sup> however, it is often difficult to diagnose mediastinal hemangioma before surgery.<sup>10</sup>

**Table 1. Characteristics of posterior mediastinal hemangioma reported so far.**

Author	Age	Sex	Place	Size, cm	Radiologic diagnosis	Pathology	Treatment	Follow up
Yun <i>et al.</i> <sup>2</sup>	58 y	F	Back pain	6	-	Cavernous hemangioma	Thoracotomy + complete excision	No recurrence after 17 months
Yoshino <i>et al.</i> <sup>5</sup>	54 y	F	Asymptomatic	2.7	Suspicious to neurogenic tumor	Cavernous hemangioma	Thoracoscopic thoracotomy	-
Herman <i>et al.</i> <sup>1</sup>	7 m	F	Work up for CHD	-	Neuroblastoma	Capillary hemangioma	Only biopsy	-
Herman <i>et al.</i> <sup>1</sup>	8 w	?	Cyanosis apnea	-	-	Capillary hemangioma	Thoracotomy, partial resection, alfa interferon, short course, steroid	-
Karamalou <i>et al.</i> <sup>6</sup>	57 y	F	Epigastric pain dyspnea	12.8	-	Cavernous hemangioma	Thoracotomy, complete excision	-
Taori <i>et al.</i> <sup>7</sup>	25 y	M	Back pain	9	-	Cavernous hemangioma	Thoracotomy, complete excision	Uneventful
Kubokura <sup>8</sup>	58 y	M	Dyspnea, dysphagia, back pain	8	-	Cystic hemangioma	Thoracotomy, cystectomy	Excellent
Maeda <i>et al.</i> <sup>9</sup>	67 y	M	Asymptomatic	-	Neurogenic tumor	Hemangioma	Thoracotomy, complete excision	No recurrence after 18 months
Sabharwal <i>et al.</i> <sup>12</sup>	4 m	F	Work up for TOF	2	Suspicious to neuroblastoma	Hemangioma	Thoracotomy, complete excision	Well
Sabharwal <i>et al.</i> <sup>12</sup>	6 m	F	Work up for CHF	Multiple	Suspicious to neuroblastoma	Hemangioma	Thoracotomy complete excision	-
Ridene <i>et al.</i> <sup>10</sup>	58 y	F	Incidental finding	5	Neurinoma	Capillary hemangioma	Thoracotomy complete excision	-
Ridene <i>et al.</i> <sup>10</sup>	66 y	M	Paresthesis of superior extremity	6	-	Mixed hemangioma	Thoracotomy complete excision	-
Ridene <i>et al.</i> <sup>10</sup>	16 y	?	Asymptomatic	5	-	Cavernous hemangioma	Video assisted technique for complete excision	No recurrence after 3 years
Moran <i>et al.</i> <sup>11</sup>	48 y	F	cough	3	-	Capillary hemangioma	Thoracotomy complete excision	Alive and well after 3 months
Moran <i>et al.</i> <sup>11</sup>	1 m	F	Rectal bleeding + facial telangectasia	?	-	Capillary hemangioma	Autopsy finding	Expired
Moran <i>et al.</i> <sup>11</sup>	37 y	M	Asymptomatic	9	-	Cavernous hemangioma	Thoracotomy complete excision	Alive and well after 4 years
Moran <i>et al.</i> <sup>11</sup>	35 y	F	Neck pain	7	-	Cavernous hemangioma	Thoracotomy complete excision	-
Current case	65 y	F	Productive cough	5	Neurogenic tumor	Capillary hemangioma	Thoracotomy complete excision	-

y, years; m, months; w, weeks; M, male; F, female; CHD, coronary heart disease; TOF, tetralogy of Fallot.

Histologically, most of the capillary hemangiomas in the mediastinum have been lobulated, separated by thin fibrovascular septae. The tumor cells have been bland looking with no atypia, and low or no mitosis.<sup>11</sup>

Prognosis of capillary hemangioma after resection is excellent. There has been no recurrence in long follow up.<sup>12</sup>

Table 1 shows the characteristics of posterior mediastinal hemangioma reported so far.

As a conclusion, hemangioma and vascular tumors can occur anywhere in the body, so it should also be in the differential diagnosis of posterior mediastinal masses, because it can cause surgical complications such as bleeding during operation.

## References

1. Herman TE, McAlister WH, Dehner LP. Posterior mediastinal capillary hemangioma with extradural extension resembling neuroblastoma. *Pediatr Radiol* 1999;29:517-9.
2. Yun T, Suzuki H, Tagawa T, et al. Cavernous hemangioma of posterior mediastinum with bony invasion. *Gen Thorac Cardiovasc Surg* 2014 [Epub ahead of print].
3. Juanpere S, Canete N, Ortuno P, et al. A diagnostic approach to the mediastinal masses. *Insights Imaging* 2013;4:29-52.
4. Shanon T. Histologically nonmalignant hemangioma with numerous metastasis. *J Pathol* 1914;19:139-54.
5. Yoshino N, Okada D, Ujiie H, et al. Venous hemangioma of the posterior mediastinum. *Ann Thiraz Cardiovasc Surg* 2012;18:247-50.
6. Karamlou T, Kinder K, Tieu B, et al. Mediastinal hemangioma arising in setting of partial anomalous pulmonary venous drainage to azygous vein in a 57-year-old woman. *Ann Vasc Surg* 2011;25:e13-7.
7. Taori KB, Mitra KR, Mohite AR, et al. A case report and review of literature: posterior mediastinal haemangioma. *Indian J Radiol Imaging* 2002;12:83-5.
8. Kubokura H, Okamoto J, Hoshina H, et al. Mediastinal cystic hemangioma presenting as bilateral bloody pleural effusion: a case report. *J Nippon Med Sch* 2012;79:381-4.
9. Maeda S, Takahashi S, Koike K, Sato M. Preferred surgical approach for dumbbell-shaped tumors in posterior mediastinum. *Ann Thorac Cardiovasc Surg* 2011;17:394-6.
10. Ridene I, Abassi A, Baccouche I, et al. Posterior mediastinal hemangioma mimicking neurogenic tumor: report of two cases. *Eur J Radiol Extra* 2010;75:e55-8.
11. Moran CA, Suster S. Mediastinal hemangioma: a study of 18 cases with emphasis on the spectrum of morphologic features. *Hum Pathol* 1995;26:416-20.
12. Sabharwal GK, Strouse PJ. Posterior mediastinal hemangioma. *Pediatr Radiol* 2005;35:1239-66.