UC Davis
UC Davis Previously Published Works

Title
Management options of colonoscopic splenic injury.

Permalink
https://escholarship.org/uc/item/52w152rk

Journal
JSLS Journal of the Society of Laparoscopic & Robotic Surgeons, 10(2)

ISSN
1086-8089

Authors
Shatz, David V
Rivas, Luis A
Doherty, James C

Publication Date
2006

Copyright Information
This work is made available under the terms of a Creative Commons Attribution-NonCommercial-NoDerivatives License, available at https://creativecommons.org/licenses/by-nc-nd/4.0/

Peer reviewed

eScholarship.org Powered by the California Digital Library
University of California

CASE REPORT JSLS

Management Options of Colonoscopic Splenic Injury

David V. Shatz, MD, Luis A. Rivas, MD, James C. Doherty, MD

ABSTRACT

Injury to the spleen during routine colonoscopy is an extremely rare injury. Diagnosis and management of the injury has evolved with technological advances and experience gained in the management of splenic injuries sustained in trauma. Of the 37 reported cases of colonoscopic splenic injury, 12 had a history of prior surgery or a disease process suggesting the presence of adhesions. Only 6 had noted difficulty during the procedure, and 31 patients experienced pain, shock, or hemoglobin drop as the indication of splenic injury. Since 1989, 21/24 (87.5%) patients have been diagnosed initially using computed tomography or ultrasonography. Overall, only 27.8% have retained their spleens. None have experienced as long a delay as our patient, nor have any had an attempt at percutaneous control of the injury. This report presents an unusual case of a rare complication of colonoscopy and the unsuccessful use of one nonoperative technique, and reviews the experience reported in the world literature, including current day management options.

Key Words: Spleen, Splenic injury, Splenic rupture, Complications of colonoscopy.

University of Miami School of Medicine, Department of Surgery, Division of Trauma, Burns, and Surgical Critical Care, Miami, Florida, USA (Dr Shatz).

University of Miami School of Medicine, Department of Radiology, Division of Trauma and Emergency Radiology, Miami, Florida, USA (Dr Rivas).

James C. Doherty, MD, Advocate Christ Medical Center, Oak Lawn, Illinois, USA (Dr Doherty).

Address reprint requests to: David V. Shatz, MD, University of Miami School of Medicine, Department of Surgery, Division of Trauma, Burns, and Surgical Critical Care, PO Box 016960 (D-40), Miami, FL 33101, USA. Telephone: 305 585 1194, Fax: 305 326 7065, E-mail: Dshatz@miami.edu

© 2006 by *JSLS, Journal of the Society of Laparoendoscopic Surgeons.* Published by the Society of Laparoendoscopic Surgeons, Inc.

INTRODUCTION

Endoscopic evaluation of the gastrointestinal tract offers both diagnostic and therapeutic options and has become the preferred procedure for the evaluation of gastrointestinal disorders. Though low, endoscopy carries a known risk, including perforation and hemorrhage. A particularly rare complication of colonoscopy is injury to the spleen. Presented here are an illustrative example and a review of the world literature, with a focus on diagnostic and management options.

CASE REPORT

A healthy, 75-year-old woman underwent screening colonoscopy at an outside facility and developed left upper quadrant abdominal pain over the ensuing days. A CT scan revealed a splenic "cyst," and observational management was elected. Over the next several months, the patient underwent serial CT scan examinations of her abdomen, which demonstrated a slowly but progressively enlarging splenic cyst. Though bearable, the patient was in chronic pain. Approximately 4 months after the inciting colonoscopy, the patient was referred to our facility for management. A 10x7-cm thin-walled splenic fluid collection was seen on CT **(Figure 1)**, abutting the abdominal wall and displacing the spleen medially. A fluid/fluid level could be seen within the collection, consistent with hematocrit effect (blood cells separating from plasma and settling over time). The collection was percutaneously drained with an 8 French multi-holed catheter for 400cc of brown fluid, consistent with old blood. Postprocedure CT confirmed complete collapse of the collection **(Figure 2)** and the catheter was removed. Six days after the collection was drained, the patient presented with a return of her abdominal pain and was found on follow-up CT to have a recurrent 6x4-cm subcapsular splenic collection with a small hematocrit level, presumably from ongoing small hemorrhages. With the rapid reformation of the collection, it was felt that repeat drainage would not be curative. Therefore, the patient was immunized with pneumococcal and HiB vaccines and taken for elective splenectomy 2 days later. Though laparoscopic splenectomy was considered, open resection was chosen given the patient's age and likelihood of significant inflamma-

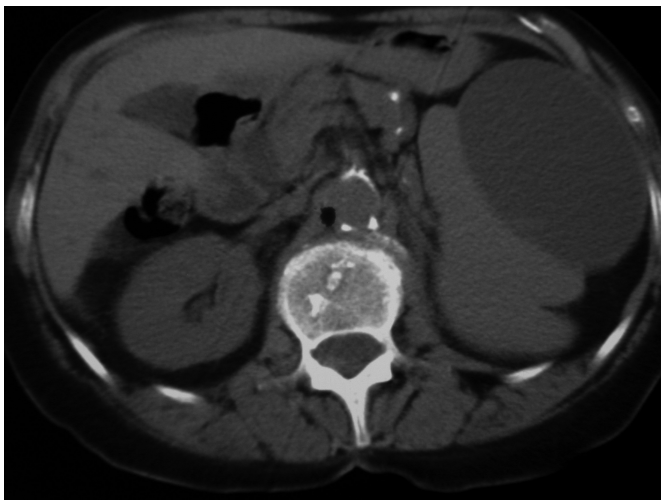

Figure 1. Presenting computed tomographic scan of patient with large undrained hemorrhagic splenic cyst abutting the left lateral abdominal wall.

Figure 2. Complete collapse of hemorrhagic splenic cyst following computed tomography-guided percutaneous drainage. Drainage catheter is visible lateral to the spleen.

tory changes. At laparotomy, she was noted to have a very mobile splenic flexure with an underdeveloped splenocolic ligament. The colon was otherwise completely normal. Inflammatory adhesions were found in the area of the spleen, and an 8x5-cm white cyst, slightly larger than the spleen itself, was found posterolateral to the spleen **(Figures 3 and 4)**. The spleen and accompanying cyst were removed after dissection of the surrounding adhesions. Postoperatively, the patient did remarkably well and was discharged home 3 days later.

Figure 3. Pathologic specimen of intact spleen and associated hemorrhagic cyst.

DISCUSSION

Though barium enema has long been the gold standard for identification of colonic lesions, colonoscopy affords the ability to not only identify a lesion, but to provide tissue for pathologic examination and is often the definitive procedure for polyps. Hence, colonoscopy is considered the accepted screening examination in all people over 50 years of age, and younger if a familial history of colon cancer is present.

Though overall very safe, colonoscopy is not entirely without risk. The 2 most common complications are hemorrhage following polypectomy (range, 1.8% to 2.5%) and perforation (range, 0.34% to 2.14%).[1] An extremely rare complication is injury to the spleen. The injury was first reported in 1974, with 2 patients sustaining hemorrhage, one of which resulted in splenectomy.[2] Since the first report, an additional 36 cases have been reported in the world literature, including the current case.[1–33] The average age of the patients is 64.9 years (range, 33 to 90),

Figure 4. Pathologic specimen of divided spleen and associated hemorrhagic cyst.

reflecting the age for which colonoscopy is routinely indicated, with a preponderance of females (66.7%).

Levine[19] proposed 2 theories for the probable cause of splenic injury during colonoscopy. Difficult intubation of the colon may impart direct injury to the spleen during passage through the splenic flexure. Dense adhesions between the colon and spleen from previous surgery or disease may result in tearing of the splenic capsule as the colonoscope is passed through the colon. Telmos[31] and others[28] later added technical maneuvers to the list of risk factors, including slide-by, the alpha maneuver, straightening of the sigmoid loop, and externally applied abdominal pressure. In the available literature, only 6 patients were reported to have had some difficulty with intubation of the colon, while 21 specifically mentioned a lack of difficulty. Reports from the remaining 10 cases made no mention of ease or difficulty of the procedure. Twelve of the 37 reported patients had undergone previous surgery or had a disease process that may have enabled adhesion formation (Crohn's disease and pancreatitis). Eighteen had no predisposition to adhesion formation, and 8 reports lacked any information regarding risk factors. Interestingly, of the 12 patients with possible adhesions, 10 had no intubation difficulties.

Most patients with colonoscopic splenic injury present relatively soon after injury with signs or symptoms suggestive of a problem. The range in the reported literature extends from within 2 hours to as long as 10 days. Fourteen of the 32 patients with available information presented with symptoms within 12 hours of colonoscopy. The remaining 18 patients presented over the following days.

The vast majority of patients with information available presented with symptoms of pain (28/32). Approximately half of these same patients also presented with evidence of hemorrhage or shock, or both (18/32). With the exception of 1 patient successfully managed nonoperatively,[3] the only reports that did not include pain as a presenting symptom were also those in which the patients died, suggesting the patients were too moribund to complain of pain.

The diagnosis and management of these colonoscopy-related splenic injuries has to some degree reflected the available technology and is similar to the management of traumatic splenic injuries. Although most injuries were diagnosed, or at least confirmed, at laparotomy in the era before 1987, 21 of the 24 cases since 1989 have been diagnosed with noninvasive methods, such as computed tomography or ultrasonography. Before the report of Federle[34] in 1983, diagnosis of splenic injury sustained in trauma was indirect and was prompted by a positive diagnostic peritoneal lavage (DPL) leading to laparotomy. With the proven utility of CT in blunt abdominal trauma, only hemodynamically unstable patients now undergo DPL, and even that has been largely replaced by the focused abdominal sonography for trauma (FAST) examination.[35] A similar trend is noted with colonoscopic splenic injury.

The recognition over 100 years ago of the spleen's role in immunoprotection against encapsulated organisms, such as *streptococcus pneumoniae, haemophilus influenzae,* and *neisseria meningitidis* was largely ignored until the 1950s when a swing in the management of splenic injuries began the era of splenic salvage. Besides splenorrhaphy, splenic salvage maneuvers now include nonoperative management of splenic injuries and splenic artery embolization of pseudoaneurysms.[36] In the trauma literature, nonoperative management of lower grade injuries (Grades I–III)[37] has a success rate ranging from 95.2% to 80.4%, respectively.[38] Though none of the injuries induced at colonoscopy were graded in the available reports, these are presumably not the pulverized high-grade injuries seen in trauma, and probably fall into the grade I thru III category. However, overall only 27.8% of patients with a splenic injury by colonoscopy have retained their spleens. Before 1988, the splenectomy rate was 100%. Since that time, that rate has dropped to 61.5%, still higher than that predicted from the trauma literature.

Finally, our patient presented with a condition not previ-

ously reported in the colonoscopy literature. The formation of a secondary cyst is rare and is characterized by the lack of a cellular lining as seen in a primary cyst. Secondary cysts are typical of a hemorrhagic, inflammatory, or degenerative origin.[39] Successful percutaneous drainage under ultrasound guidance has been reported for splenic cysts secondary to blunt abdominal trauma,[40] but not for those related to colonoscopy. Our attempt at percutaneous drainage was similarly intended to prevent splenectomy, but unfortunately was unsuccessful. With only limited experience, this technique, however, should remain in the armamentarium for the treatment of these injuries.

CONCLUSION

In the history of splenic injury by colonoscopy, the experience of the first decade was laparotomy and splenectomy in all patients. Though CT scanning has proven successful in diagnosing the injury, relatively few patients have escaped the experience with an intact spleen.

Nonoperative management and splenic artery embolization have been used with significant success in the trauma setting, but used only sparingly with colonoscopic injuries. These options should be given serious consideration in these patients. Though our attempt at percutaneous control of the secondary cyst formed as a result of a colonoscopic splenic injury was unsuccessful, we believe this could nevertheless represent an alternative to splenectomy in future patients.

References:

1. Shaker IS, Deckleman C. Delayed presentation of splenic rupture after colonoscopy. *J Emerg Med.* 1999;17:455–457.

2. Wherry DC, Zehner H. Colonoscopy—Fiberoptic endoscopic approach to the colon and polypectomy. *Med Ann DC.* 1974;43:189–192.

3. Adamek RJ, Wegener M, Schmidt-Heinevetter G, Ricken D, Jergas M. Milzruptur nach koloskopie: eine ungewOhnliche komplikation. *Z Gastroenterol.* 1992;30:139–141.

4. Ahmed A, Eller P, Schiffman FJ. Splenic rupture: an unusual complication of colonoscopy. *Am J Gastroenterol.* 1997;92:1201–1204.

5. Bergamaschi R, Arnaud J. Splenic rupture from colonoscopy (letter). *Surg Endosc.* 1997;11:1133.

6. Bier JY, Ferzli G, Tremolieres F, Gerbal JL. Rupture splenique provoquee par la coloscopie. *Gastroenterol Clin Biol.* 1989;13:224–225.

7. Castelli M. Splenic rupture: an unusual late complication of colonoscopy. *CMAJ.* 1986;134:916–917.

8. Cohen JL, Forde KA. Intraoperative colonoscopy. *Ann Surg.* 1988;207:231–233.

9. Colarian J, Alousi M, Calzada R. Splenic trauma during colonoscopy. *Endoscopy.* 1991;23:48–49.

10. Coughlin F, Aanning HL. Delayed presentation of splenic rupture following colonoscopy. *South Dakota J Med.* 1997;50:325–326.

11. Doctor NM, Monteleone F, Zarmakoupis C, Khalife M. Splenic injury as a complication of colonoscopy and polypectomy. *Dis Colon Rectum.* 1987;30:967–968.

12. Dodds LJ, Hensman C. Splenic trauma following colonoscopy. *Aust NZ J Surg.* 1993;63:905–906.

13. Ellis WE, Harrison JM, Williams RS. Rupture of spleen at colonoscopy. *Br Med J.* 1979;1:307–308.

14. Espinal EA, Hoak T, Porter JA, Slezak FA. Splenic rupture from colonoscopy. *Surg Endosc.* 1997;11:71–73.

15. Gores PF, Simso LA. Splenic injury during colonoscopy. *Arch Surg.* 1989;124:1342.

16. Hamzi L, Soyer P, Boudlaf M, et al. Rupture splenique apres coloscopie: a propos d'un cas inhabituel survenant sur une rate initialement saine. *J Radiol.* 2003;84:320–322.

17. Heath B, Rogers A, Taylor A, Lavergne J. Splenic rupture: an unusual complication of colonoscopy. *AJG.* 1994;9:449–450.

18. Kloer M, Schmidt-Wilcke HA, Schulz U. Milzruptur als koloskopiefolge. *Dtsch Med Wochenschr.* 1984;109:1782–1783.

19. Levine E, Wetzel LH. Splenic trauma during colonoscopy. *AJR.* 1987;149:939–940.

20. Melsom DS, Cawthorn SJ. Splenic injury following routine colonoscopy. *Hasp Med.* 1997;60:65.

21. Merchant AA, Cheng EH. Delayed splenic rupture after colonoscopy. *Am J Gastroenterol.* 1990;85:906–907.

22. Moses RE, Leskowitz SC. Splenic rupture after colonoscopy. *J Clin Gastroenterol.* 1997;24:257–258.

23. Ong E, Bohmler U, Wurbs D. Splenic injury as a complication of endoscopy: two case

reports and a literature review. *Endoscopy.* 1991;23:302–304.

24. Reissman P, Durst AL. Splenic hematoma, a rare complication of colonoscopy. *Surg Endosc.* 1998;12:154–155.

25. Reynolds FS, Moss LK, Majeski JA, Lamar C. Splenic rupture following colonoscopy. *Gastrointest Endosc.* 1986;32:307–308.

26. Rockey DC, Weber JR, Wright TL, Wall SD. Splenic injury following colonoscopy. *Gastrointest Endosc.* 1990;36:306–309.

27. Smith LE. Fiberoptic colonoscopy: Complications of colonoscopy and polypectomy. *Dis Colon Rectum*. 1976;19:407–412.

28. Stein DF, Myaing M, Guillaume C. Splenic rupture after colonoscopy treated by splenic artery embolization. *Gastrointest Endosc*. 2002;55:946–948.

29. Sugar I, Ledniczky G, Odnrejka P, Vajda V, Pozsonyi T, Prohaszka Z. Koionoszkopia ritka szovodmenye: a lepruptura. *Magyar Scheszet*. 2000;53:73–75.

30. Taylor FC, Frankl HD, Riemer KD. Late presentation of splenic trauma after routine colonoscopy. *Am J Gastroenterol*. 1989;84:442–443.

31. Telmos AJ, Mittal AJ. Splenic rupture following colonoscopy. *JAMA*. 1977;237:2718.

32. Tuso P, McElligot J, Marignani P. Splenic rupture at colonoscopy. *J Clin Gastroenterol*. 1987;9:559–562.

33. Viamonte M, Wulkan M, Irani H. Splenic trauma as a complication of colonoscopy. *Surg Laparosc Endosc*. 1992;2:154–157.

34. Federle MP. CT of abdominal trauma. *Crit Rev Diagn Imaging*. 1983;19:257–316.

35. American College of Surgeons. Abdominal Trauma. In: *Advanced Trauma Life Support for Doctors*. Chicago, IL: American College of Surgeons; 1997;157–175.

36. Elliott JA, Millward SF, Kribs SW. Use of computed tomographic scanning and embolization to improve the nonoperative management of splenic trauma: critically appraised topic. *Can Assoc Radiol*. 2003;J 54:183–184.

37. Moore EE, Cogbill TH, Jurkovich GJ, Shackford SR, Malangoni MA, Champion HR. Organ injury scaling: Spleen and liver (1994 revision). *J Trauma*. 1995;38:323–324.

38. Peitzman AB, Heil B, Rivera L, et al. Blunt splenic injury in adults: Multi-institutional study of the Eastern Association for the Surgery of Trauma. *J Trauma*. 2000;49:177–189.

39. Labruzzo C, Haritopoulos KN, El Tayar AR, Hakim NS. Post-traumatic cyst of the spleen: a case report and review of the literature. *Int Surg*. 2002;87:152–156.

40. Ravera M, Cocozza E. Post traumatic pseudocyst of the spleen: case report on a conservative management through percutaneous drainage. *G Chir*. 1999;20:471–473.