

# UC Irvine

## UC Irvine Previously Published Works

### Title

Hyperpigmented plaques and nodules in a young man

### Permalink

<https://escholarship.org/uc/item/52z0q9pg>

### Authors

Sattler, Samantha  
Kraus, Christina N  
Lee, Bonnie  
[et al.](#)

### Publication Date

2021-12-01

### DOI

10.1016/j.jdcr.2021.11.008

### Copyright Information

This work is made available under the terms of a Creative Commons Attribution License, available at <https://creativecommons.org/licenses/by/4.0/>

Peer reviewed

## Hyperpigmented plaques and nodules in a young man



Samantha Sattler, BA,<sup>a</sup> Christina N. Kraus, MD, FAAD,<sup>b</sup> Bonnie Lee, MD, FAAD,<sup>b</sup> and  
Janellen Smith, MD, FAAD<sup>b</sup>  
*Albany, New York and Irvine, California*

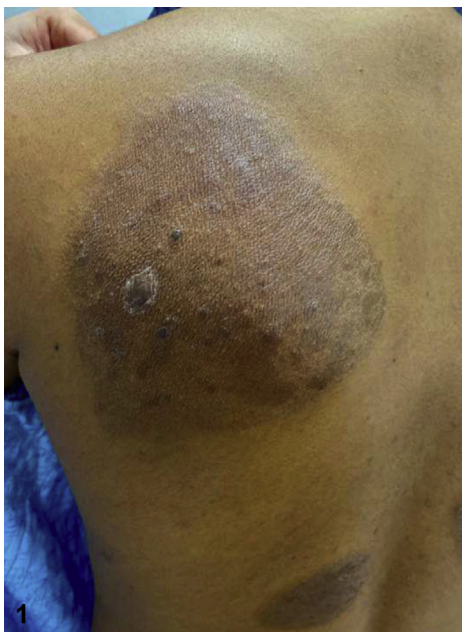

Figure 1. By Samantha Sattler, BA; Christina N Kraus, MD, FAAD; Bonnie Lee, MD, FAAD; Janellen Smith, MD, FAAD.

From Albany Medical College<sup>a</sup>, and Department of Dermatology,  
University of California Irvine.<sup>b</sup>

Funding: None.

IRB approval status: Not applicable.

Correspondence to: Samantha Sattler, BA, Albany Medical College,  
49 New Scotland Avenue, Albany, NY 12208. E-mail: [sattles@amc.edu](mailto:sattles@amc.edu).

JAAD Case Reports 2021;18:106-8.

2352-5126

© 2021 by the American Academy of Dermatology, Inc. Published  
by Elsevier, Inc. This is an open access article under the CC BY-  
NC-ND license ([http://creativecommons.org/licenses/by-nc-nd/  
4.0/](http://creativecommons.org/licenses/by-nc-nd/4.0/)).

<https://doi.org/10.1016/j.jdcr.2021.11.008>

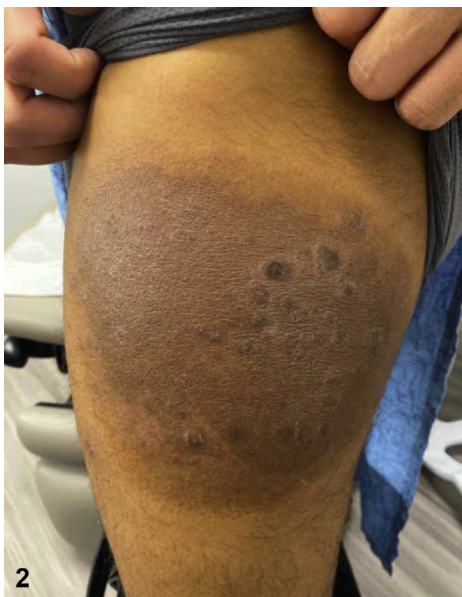

Figure 2. By Samantha Sattler, BA; Christina N Kraus, MD, FAAD; Bonnie Lee, MD, FAAD; Janellen Smith, MD, FAAD.

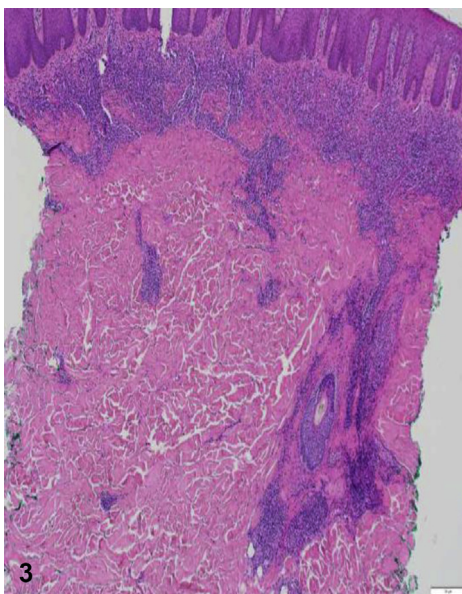


Figure 3. By Samantha Sattler, BA; Christina N Kraus, MD, FAAD; Bonnie Lee, MD, FAAD; Janellen Smith, MD, FAAD.

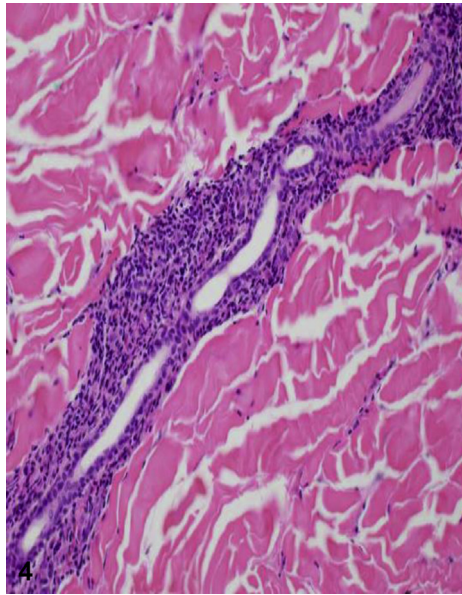


Figure 4. By Samantha Sattler, BA; Christina N Kraus, MD, FAAD; Bonnie Lee, MD, FAAD; Janellen Smith, MD, FAAD.

### CASE PRESENTATION

A man in his 20s presented with progressive pruritic hyperpigmented plaques that he had since age 16 years. Previous treatments included topical and systemic steroids and narrowband UVB. He denied fevers, chills, lymphadenopathy, weight loss, and night sweats. On examination he had large, round hyperpigmented plaques studded with small, darker papules and nodules involving the trunk, legs, and buttocks (Figs 1 and 2). Punch biopsy revealed a dense superficial and deep lymphocytic infiltrate with prominent perieccrine distribution (Figs 3 and 4). Immunostaining demonstrated loss of CD7 and elevated CD4:8 ratio (10:1).

### Question #1: What is the most likely diagnosis?

- A. Hyperpigmented mycosis fungoides
- B. Indeterminate leprosy
- C. Neutrophilic eccrine hidradenitis (NEC)
- D. Syringotropic mycosis fungoides (STMF)
- E. Tumid lupus

Click [here](#) to view disclosures, take the quiz, and claim CME credit.

Consent for the publication of recognizable photographs was provided by the authors at the time of article submission to the journal stating that all patients gave consent for their photographs to be published in print and online and with the understanding that these photographs may be publicly available.

### Conflicts of interest

The authors have no conflicts of interest to declare.