

# Solitary myofibroma of the oropharynx causing airway obstruction in an adult

Harrison W. Lin, MD; David Jung, MD, PhD; Linda N. Lee, MD; Peter M. Sadow, MD, PhD; James W. Rocco, MD, PhD

## Abstract

*Myofibromas are benign neoplasms believed to be the most common fibrous proliferation of childhood. We present an unusual case of a 44-year-old woman who developed acute airway obstruction from a myofibroma in the oropharynx and accordingly required emergent tracheotomy tube placement. Serial laser excisions to adequately remove the entire lesion while maintaining pharyngeal structure and function were performed, and the patient was successfully decannulated. To date she has remained free of signs and symptoms of recurrence. Although rare in adults, solitary myofibromas should be considered in the differential diagnosis of any subcutaneous or submucosal head and neck lesion. Moreover, clinicians treating adult and pediatric patients with known solitary or multicentric forms of myofibroma should be aware of its potential for airway obstruction. Patients found to have a pharyngeal myofibroma should be managed with airway stabilization, surgical excision with preservation of speech and swallow function, and close postoperative monitoring for recurrence.*

## Introduction

Myofibromas are histologically benign neoplasms most frequently seen in the pediatric population in both solitary and multicentric forms. They may present in different locations, although they are often found in the

oral cavity in both children and adults. These lesions are typically painless and slowly growing, and they follow an innocuous course. Myofibromas of the head and neck have not been previously described in the literature as presenting with acute airway obstruction and necessitating an emergent surgical intervention. To our knowledge, this is the first report of a solitary myofibroma of the oropharynx in an adult causing airway distress and requiring a tracheostomy.

## Case report

A 44-year-old woman presented to our institution with a 3-month history of worsening dysphagia and position-dependent dyspnea. Fiberoptic examination revealed an oropharyngeal mass that completely obstructed visualization of the distal airway. Magnetic resonance imaging (MRI) demonstrated a 3.0 × 1.7 × 1.4-cm pedunculated lesion of the right base of the tongue and epiglottis, with pronounced enhancement with contrast and hyperintensity on fat-suppression images (figure 1). The patient was urgently taken to the operating room for biopsy, followed by subtotal resection to optimize the airway and preserve function. Histopathology revealed the lesion to be a myofibroma (figure 2). After airway stabilization, the patient was scheduled for elective resection in 2 weeks and discharged home.

Having failed to return for her scheduled surgery, the patient presented again 3 months later in respiratory distress. She required tracheotomy tube placement to stabilize her airway and repeat subtotal resection because of base-of-tongue and epiglottis involvement.

A postoperative swallow study revealed normal function without aspiration. A definitive serial CO<sub>2</sub> laser excision was then performed to remove all residual disease, and the patient was successfully decannulated. At last follow-up approximately 1 year later, the patient continued to be free of disease.

From the Department of Otolaryngology–Head and Neck Surgery, University of California, Irvine (Dr. Lin); the Department of Otolaryngology, Massachusetts Eye and Ear Infirmary, Boston (Dr. Jung, Dr. Lee, and Dr. Rocco); and the Department of Pathology (Dr. Sadow) and the Department of Surgery (Dr. Rocco), Massachusetts General Hospital, Boston. The case described in this article occurred at Massachusetts Eye and Ear Infirmary.

Corresponding author: Harrison W. Lin, MD, University of California, Irvine, 101 The City Drive South, Bldg. 56, Suite 500, Orange, CA 92868. Email: harrisonlin@gmail.com

## Discussion

Myofibromas are benign neoplasms composed of contractile myoid cells and myofibroblasts; they are considered the most common fibrous proliferation of infancy and childhood.<sup>1,2</sup> Although an estimated 90% of all cases occur in the first 2 years of life,<sup>3</sup> myofibromas can arise in patients of any age and, accordingly, the condition is broadly divided into infantile (juvenile) myofibromatosis and adult myofibromatosis. This lesion can manifest as solitary or multicentric, and it is believed that solitary lesions are more common.<sup>1</sup>

Myofibromas have been reported to have a predisposition for the subcutaneous and cutaneous tissues and skeletal muscles of the head and neck—in particular the oral cavity.<sup>3,4</sup> Here we report the first case of a solitary oropharyngeal myofibroma in an adult and describe its potential for life-threatening airway compromise.

Myofibromas are generally considered to be slowly growing tumors most frequently seen on the oral tongue and buccal mucosa. When present, these tumors can be difficult to distinguish from other fibrous proliferations, including fibrosarcomas, leiomyomas, fibrous histiocytomas, and solitary fibrous tumors, among others. Reports of the histopathologic features of solitary myofibromas have varied, ranging from a strictly benign appearance to a locally aggressive mass with infiltrative growth and high rates of recurrence after excision.<sup>4</sup>

In our case, the lesion was noted to be a bland, spindle cell neoplasm with cells exhibiting elongated, cigar-shaped nuclei with normochromasia and without mitoses or necrosis. Immunohistochemistry revealed cytoplasmic positivity for smooth-muscle actin, seen in myofibroblasts, and negative staining for several keratins (positive in spindle cell carcinomas), CD34 (positive in solitary fibrous tumors), ALK1 (as seen in inflammatory myofibroblastic tumors, usually pediatric), and desmin (positive in leiomyomas). The overall findings were of a benign myofibroblastic proliferation consistent with myofibroma.

Once the diagnosis of myofibroma is established, complete excision with a conservative surgical resection has been advocated, especially if the tumor is in a functionally or cosmetically sensitive location.<sup>2</sup> In the present case, epiglottic involvement necessitated initial subtotal resection to minimize the risk of subsequent aspiration while the airway was stabilized, followed by definitive laser excision.

Myofibromas also have been reported to be successfully treated with serial subtotal resections followed by complete spontaneous regression, which is a phenom-

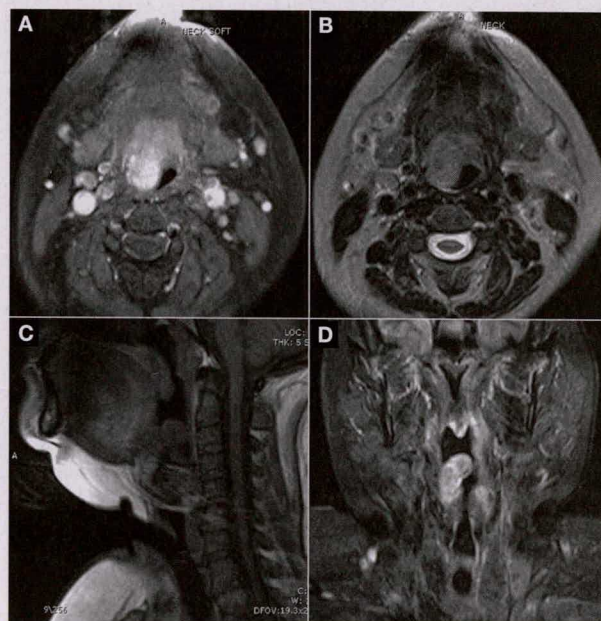


Figure 1. Axial T1-weighted postcontrast (A) and axial T2-weighted (B) MRIs of the oropharyngeal myofibroma show that it is nearly obliterating the airway. Sagittal T1-weighted precontrast (C) and coronal short T1-weighted inversion recovery (D) images are also shown.

enon thought to result from massive cellular apoptosis.<sup>5</sup> However, this did not occur in our case. With respect to other treatments, these tumors have been reported to respond to a chemotherapy regimen of dactinomycin, vincristine, and cyclophosphamide.<sup>4</sup> Our patient's case was presented at our multidisciplinary head and neck clinic, where a recommendation for surgical excision was made.

Given that rates of recurrence have been described to range from 12.5 to 31%,<sup>3,4</sup> close postoperative monitoring for tumor recurrence is paramount, especially if tumor bulk may contribute to airway narrowing or symptoms resembling those of obstructive sleep apnea. Notably, a solitary myofibroma in a 4-month-old boy previously tracheostomized at the time of birth for subglottic stenosis was found to extend from the floor of the mouth to the thoracic inlet and encircle the trachea.<sup>6</sup> In that case, the bulk of the tumor completely obliterated the pharyngeal airway. Moreover, a previously reported case of tongue-base myofibroma exhibited unusually aggressive clinical behavior.<sup>4</sup> This lesion, first noted in an 8-month-old child, required 7 surgical excisions over a period of 10 years and 9 cycles of chemotherapy to achieve disease resolution.

In conclusion, although solitary myofibromas are rare in adults and have never been reported to be obstructive, they have been described in the oral cavity of adults on

*Continued on page 417*

patient who required 4 days of oral supplementation before normalization.

One shortcoming of our study, in addition to its retrospective nature, is that intact parathyroid hormone levels had not been obtained in the hypocalcemic patients. The availability of these measurements would have allowed us to refine our assessment.

In conclusion, our findings suggest that minimally invasive thyroidectomy poses no additional risk with regard to the development of prolonged postoperative hypocalcemia. We did not seek to compare the minimally invasive thyroidectomy cohort with our patients who had undergone conventional open thyroidectomy because they were dissimilar groups with respect to thyroid anatomy, disease state, and the extent of resection. These differences made any such comparison of little value in terms of the goal of this study.

## References

- Rafferty M, Miller I, Timon C. Minimal incision for open thyroidectomy. *Otolaryngol Head Neck Surg* 2006;135(2):295-8.
- Perigli G, Cortesini C, Qirici E, et al. Clinical benefits of minimally invasive techniques in thyroid surgery. *World J Surg* 2008;32(1):45-50.
- Sgourakis G, Sotiropoulos GC, Neuhäuser M, et al. Comparison between minimally invasive video-assisted thyroidectomy and conventional thyroidectomy: Is there any evidence-based information? *Thyroid* 2008;18(7):721-7.
- Terris DJ, Gourin CG, Chin E. Minimally invasive thyroidectomy: Basic and advanced techniques. *Laryngoscope* 2006;116(3):350-6.
- Terris DJ, Seybt MW. Cosmesis in thyroid and parathyroid surgery: A matter of perspective [comment]. *Arch Otolaryngol Head Neck Surg* 2008;134(10):1120-1.
- Pattou F, Combemale F, Fabre S, et al. Hypocalcemia following thyroid surgery: Incidence and prediction of outcome. *World J Surg* 1998;22(7):718-24.
- Abboud B, Sargi Z, Akkam M, Sleilaty F. Risk factors for post-thyroidectomy hypocalcemia. *J Am Coll Surg* 2002;195(4):456-61.
- Asari R, Passler C, Kaczirek K, et al. Hypoparathyroidism after total thyroidectomy. *Arch Surg* 2008;143(2):132-7; discussion 138.
- Kang SW, Jeong JJ, Yun JS, et al. Gasless endoscopic thyroidectomy using trans-axillary approach; surgical outcome of 581 patients. *Endocr J* 2009;56(3):361-9.
- Terris DJ, Angelos P, Steward DL, Simental AA. Minimally invasive video-assisted thyroidectomy: A multi-institutional North American experience. *Arch Otolaryngol Head Neck Surg* 2008;134(1):81-4.
- Page C, Strunski V. Parathyroid risk in total thyroidectomy for bilateral, benign, multinodular goitre: Report of 351 surgical cases. *J Laryngol Otol* 2007;121(3):237-41.

Continued from page 412

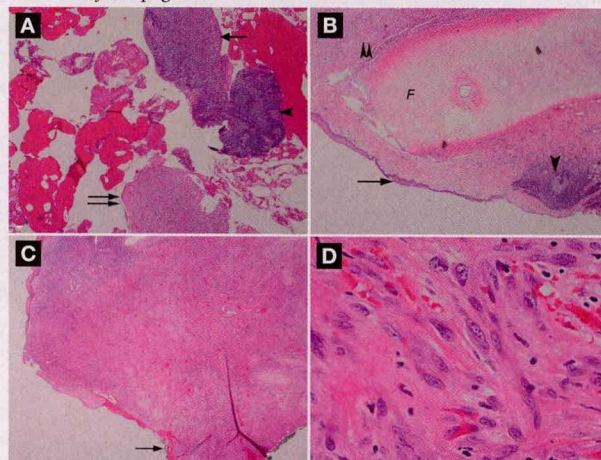


Figure 2. **A:** Histopathology reveals ulcerated squamous mucosa (arrow) with underlying lymphoid tissue (arrowhead) and fragmented spindle cell proliferation (double arrow), features consistent with myofibroma (hematoxylin and eosin, original magnification  $\times 20$ ). **B:** Squamous mucosa (arrow) is seen, with underlying fibrocartilage (F), lymphoid tissue (arrowhead), and fragmented spindle cell proliferation (double arrowhead), also consistent with myofibroma (hematoxylin and eosin, original magnification  $\times 20$ ). **C:** The myofibroma extends to the black-inked margin of the resection (arrow) (hematoxylin and eosin, original magnification  $\times 20$ ). **D:** Fascicles of bland, ovoid spindle cells are seen (hematoxylin and eosin, original magnification  $\times 600$ ).

many occasions and should be considered in the differential diagnosis of any subcutaneous or submucosal head and neck lesion.<sup>4</sup> This case should alert clinicians to the potential obstructive nature of these lesions when present in solitary or multicentric forms in both children and adults. Management principles include airway stabilization, surgical excision with preservation of speech and swallow function, and close postoperative monitoring for recurrence.

## References

- Wiswell TE, Davis J, Cunningham BE, et al. Infantile myofibromatosis: The most common fibrous tumor of infancy. *J Pediatr Surg* 1988;23(4):315-18.
- Stout AP. Juvenile fibromatoses. *Cancer* 1954;7(5):953-78.
- Vered M, Allon I, Buchner A, Dayan D. Clinico-pathologic correlations of myofibroblastic tumors of the oral cavity. II. Myofibroma and myofibromatosis of the oral soft tissues. *J Oral Pathol Med* 2007;36(5):304-14.
- Beck JC, Devaney KO, Weatherly RA, et al. Pediatric myofibromatosis of the head and neck. *Arch Otolaryngol Head Neck Surg* 1999;125(1):39-44.
- Fukasawa Y, Ishikura H, Takada A, et al. Massive apoptosis in infantile myofibromatosis. A putative mechanism of tumor regression. *Am J Pathol* 1994;144(3):480-5.
- Eze N, Pitkin L, Crowley S, et al. Solitary infantile myofibroma compromising the airway. *Int J Pediatr Otorhinolaryngol* 2004;68(12):1533-7.

Copyright of ENT: Ear, Nose & Throat Journal is the property of Vendome Group LLC and its content may not be copied or emailed to multiple sites or posted to a listserv without the copyright holder's express written permission. However, users may print, download, or email articles for individual use.