UC Irvine
UC Irvine Previously Published Works

Title
Mid-Infrared Laser Orbital Septal Tightening

Permalink
https://escholarship.org/uc/item/53d112g7

Journal
Facial Plastic Surgery & Aesthetic Medicine, 16(6)

ISSN
2689-3614

Authors
Chu, Eugene A
Li, Michael
Lazarow, Frances B
et al.

Publication Date
2014-11-01

DOI
10.1001/jamafacial.2014.671

Copyright Information
This work is made available under the terms of a Creative Commons Attribution License, availalbe at https://creativecommons.org/licenses/by/4.0/

Peer reviewed

eScholarship.org Powered by the California Digital Library
University of California

NIH Public Access
Author Manuscript
JAMA Facial Plast Surg. Author manuscript; available in PMC 2015 December 01.

Published in final edited form as:
JAMA Facial Plast Surg. 2014 December 1; 16(6): 425–431. doi:10.1001/jamafacial.2014.671.

Mid-Infrared Laser Orbital Septal Tightening:

Ex Vivo Dosimetry Study and Pilot Clinical Study

Eugene A. Chu, MD, **Michael Li, MD**, **Frances B. Lazarow, MD**, and **Brian J. F. Wong, MD, PhD**

Division of Facial Plastic and Reconstructive Surgery, Department of Otolaryngology–Head and Neck Surgery, University of California, Irvine School of Medicine, Irvine (Chu, Wong); Beckman Laser Institute, University of California, Irvine (Li, Lazarow, Wong)

Abstract

IMPORTANCE—Blepharoplasty is one of the most commonly performed facial aesthetic surgeries. While myriad techniques exist to improve the appearance of the lower eyelids, there is no clear consensus on the optimal management of the orbital septum.

OBJECTIVES—To evaluate the safety and feasibility of the use of the holmium:yttrium aluminum garnet (Ho:YAG) laser for orbital septal tightening, and to determine whether modest use of this laser would provide some degree of clinical efficacy.

DESIGN, SETTING, AND PARTICIPANTS—Direct laser irradiation of ex vivo bovine tissue was used to determine appropriate laser dosimetry using infrared thermal imaging and optical coherence tomography before conducting a pilot clinical study in 5 patients. Laser irradiation of the lower eyelid orbital septum was performed through a transconjunctival approach. Standardized preoperative and postoperative photographs were taken for each patient and evaluated by 6 unbiased aesthetic surgeons.

EXPOSURE—Use of the Ho:YAG laser for orbital septal tightening.

MAIN OUTCOME AND MEASURE—To determine appropriate laser dosimetry, infrared thermal imaging and optical coherence tomography were used to monitor temperature and tissue

Copyright 2014 American Medical Association. All rights reserved.

Corresponding Author: Brian J. F. Wong, MD, PhD, Division of Facial Plastic and Reconstructive Surgery, Department of Otolaryngology–Head and Neck Surgery, University of California, Irvine, 1002 Health Sciences Rd E, Irvine, CA 92612 (bjwong@uci.edu).

Role of the Sponsor: Newstar Laser had no role in the design and conduct of the study; collection, management, analysis, and interpretation of the data; preparation, review, or approval of the manuscript; and decision to submit the manuscript for publication.

Additional Contributions: Allison Zemek assisted in the development of the thermal analysis software and was not compensated for her assistance.

Author Contributions: Dr Wong had full access to all of the data in the study and takes responsibility for the integrity of the data and the accuracy of the data analysis.
Study concept and design: Chu, Wong.
Acquisition, analysis, or interpretation of data: Chu, Lazarow, Wong.
Drafting of the manuscript: Chu, Li, Lazarow, Wong.
Critical revision of the manuscript for important intellectual content: Chu, Wong.
Statistical analysis: Chu, Li.
Obtained funding: Wong.
Administrative, technical, or material support: All authors.
Study supervision: Wong.

NIH-PA Author Manuscript
NIH-PA Author Manuscript
NIH-PA Author Manuscript

NIH-PA Author Manuscript

NIH-PA Author Manuscript

NIH-PA Author Manuscript

shape changes of ex vivo bovine tissue that was subjected to direct laser irradiation. For the clinical study, preoperative and postoperative photographs were evaluated by 6 surgeons on a 10-point Likert scale.

RESULTS—Optical coherence tomography demonstrated that laser irradiation of bovine tissue to a temperature range of 60°C to 80°C resulted in an increase in thickness of up to 2-fold. There were no complications or adverse cosmetic outcomes in the patient study. Patient satisfaction with the results of surgery averaged 7 on a 10-point Likert scale. For 3 patients, 3 (50%) of the evaluators believed there was a mild improvement in appearance of the lower eyelids after surgery. The remaining patients were thought to have no significant changes.

CONCLUSIONS AND RELEVANCE—Transconjunctival Ho:YAG laser blepharoplasty is a safe procedure that may ameliorate mild pseudoherniation of lower eyelid orbital fat and is a first step toward the development of percutaneous techniques.

LEVEL OF EVIDENCE—4.

Blepharoplasty is the second most commonly performed aesthetic operation of the face.[1] Patients seeking facial rejuvenation frequently complain of “bags” tous laxity develops with a subsequent reduction in eyelid tone and development of orbital fat pseudoherniation against a weakened septum. There is an increasingly complex array of surgical treatments for the lower eyelids, including skin flap, skin-muscle flap, or transconjunctival blepharoplasty with either fat excision or repositioning. Adjunctive procedures, such as skin pinch excisions, chemical peels, laser resurfacing, or autologous fat transfer, are also frequently performed.[2–5] All of these procedures are aimed at addressing either the skin and orbicularis muscle or orbital fat and septum. There is no clear consensus on the optimal management of the orbital fat and septum.

Potential complications related to orbital lipectomy include a sunken appearance of the orbit, retrobulbar hemorrhage, and worsening of involutional enophthalmos.[6] The risk of developing a “hollowed out” lower eyelid can be minimized by conservatively excising fat or fat-repositioning techniques.[7] However, any technique involving manipulation of orbital fat and violation of the septum contributes to the risk of retrobulbar hemorrhage. Several authors[8–10] have performed orbital septorhaphy through suture plication techniques to ameliorate pseudoherniation of fat by strengthening the septum. In 1984, Cook et al[11] reported the use of electrocautery to tighten the septum during lower lid blepharoplasty through a subciliary approach.

Conventional electrocautery (radiofrequency, hereinafter RF) is a reliable, inexpensive, and effective tool for both tissue dissection and hemostasis. However, it can result in unintentional collateral tissue damage, prolonged edema, and postsurgical pain owing to uncontrolled heat generation. Uncontrolled heat generation is an intrinsic limitation of RF surgery, in which the distribution of heat sources in tissue mirrors the electrical field surrounding the cautery tip. The electrical field intensity leading to heat generation surrounding classic RF devices (ie, Bovie and bipolar) can extend several millimeters. Without direct visualization of tissue shrinkage due to heat generation, it is difficult to gauge the end point for septal tightening, and uncontrolled heating can occur. This is a major reason why RF devices must be used with extreme caution when inserted through the skin.

NIH-PA Author Manuscript

NIH-PA Author Manuscript

NIH-PA Author Manuscript

Obviously, this effect is exploited for positive results where volumetric heating of tissue is desired, such as in palatal and turbinate procedures. These limitations have provided the impetus for the creation of alternative cutting and coagulating modalities, such as plasma mediated instrumentation, ultrasonic scalpels, and laser devices.

The approach of Cook et al[11] to tightening the septum required wide exposure and used conventional RF devices to tighten the septum in tandem with skin excision. However, in younger patients, who may have just begun to show the early signs of aging and have isolated pseudoherniated fat without skin, muscle, or ligamentous changes, orbital septum tightening alone should, in theory, be adequate to correct fat protrusion. This would be particularly attractive if such a technique could be performed percutaneously under local anesthesia. The key to performing a minimally invasive thermally mediated orbital septal tightening procedure is identification of a treatment modality that can heat the septum while minimizing injury to orbital fat and the orbicularis oculi muscle.

While the primary objective of this study was to evaluate the safety and feasibility of the use of the holmium:yttrium aluminum garnet (Ho:YAG) laser for orbital septal tightening, we also conducted a preliminary clinical investigation to determine whether modest use of the technology would provide some degree of efficacy as well. Direct laser irradiation of ex vivo bovine tissue was used to determine appropriate laser dosimetry using infrared thermal imaging and optical coherence tomography (OCT) to monitor temperature and tissue shape change. These data were then used to perform a pilot clinical study in 5 patients to assess the safety of this technology. We believe this study is the first step in the development of a minimally invasive septal tightening blepharoplasty procedure.

Methods

This study was approved under the aegis of the University of California, Irvine's institutional review board (protocol No. 2008-6593).

Bovine Tissue Direct Irradiation

Thin bovine diaphragmatic tissue was obtained from a local packing house. Tissue with a thickness of roughly 1.0 mm was excised and stretched over the open aperture of a sealed cylindrical chamber (Figure 1). The tissue was subsequently irradiated with light from a Ho:YAG laser (λ = 2100 nm; Newstar Lasers) delivered via a 600-μm silica fiber with a cleaved tip at a distance of 1 mm. The laser can deliver light in user-defined macropulses. Each macropulse consists of a train of micropulses that are themselves delivered at variable pulse repetition rates from 5 to 15 Hz. Direct laser irradiation was performed at 1.5 W with a spot size of 1.0 mm at pulse repetition rates of 5 Hz, 8 Hz, and 12 Hz using 10 macropulses; at 2.5 W with a spot size of 3.0 mm at 5 Hz, 8 Hz, and 12 Hz using 10 macropulses; and at 3.5 W with a spot size of 3.1 mm at 5 Hz, 8 Hz, and 12 Hz using 10 macropulses. Thermal paper was used to estimate the laser spot size as described previously.[12]

Five trials at each power setting were performed. During irradiation, tissue desiccation was prevented by humidifying the chamber over which the tissue was stretched with an ultrasonic atomizer. Prior to all irradiation trials, laser pulse structure was analyzed by an

NIH-PA Author Manuscript

NIH-PA Author Manuscript

NIH-PA Author Manuscript

infrared photoreceiver to determine laser fidelity. Surface temperature during laser heating was recorded as previously described using an infrared imaging system (Inframetrics model 600, FLIR).[13] Tissue samples taken both before and after direct laser irradiation were analyzed with an OCT device (Niris, model 1300, Imalux) to determine tissue thickness change after irradiation.[14]

Study Participants

Five normal, healthy volunteers were recruited from advertisements in local newspapers, websites, the National Institutes of Health database on clinical trials, and through a university-wide e-mail requesting participants for a study involving laser-assisted blepharoplasty to reduce lower eyelid bags. Written informed consent for the study was obtained. To meet inclusion criteria, each volunteer had to be 30 years or older, had to be an appropriate candidate for elective outpatient surgery, and had to have pseudoherniation of the lower eyelid fat pads. Exclusion criteria included medical co-morbidities that made the volunteer an inappropriate candidate for blepharoplasty, previous surgery or trauma to the lower eyelid or orbit, requirement of additional procedures other than septal tightening (ie, skin excision, canthoplasty and/or canthopexy), high risk for postoperative dry-eye syndrome, and current pregnancy or lactation. Volunteers were not compensated for their participation.

All patients received a complete head and neck examination at the initial visit and standardized photographs were taken. Postoperative visits were at day 1, 1 week, 1 month, and 2 months. At each visit, careful attention was paid to any complications or evidence of eyelid malposition. At the 2-month visit, standardized photographs were again taken, and patients were asked to rate their satisfaction with the procedure on a scale of 1 to 10 (1, completely unsatisfied; 10, completely satisfied).

Surgical Technique

All procedures were performed by 2 of us (E.A.C. and B.J.F.W.) with the patient under intravenous sedation with topical and local anesthetics. Metallic corneal shields were used to protect the cornea from injury secondary to laser scatter. A meticulous transconjunctival preseptal dissection was used to expose the orbital septum, and Ho:YAG laser energy was used to irradiate the septum in a gridlike pattern, keeping the fiber tip approximately 0.5 cm from the orbital septum (Figure 2). The distance between the fiber tip and tissue surface was altered intraoperatively to adjust the irradiance at the tissue surface; noticeable shrinkage of the tissue without evidence of ablation was used as a clinical end point as observed during bovine tissue studies. Power settings ranged from 1 to 3 W with 5 to 10 pulses per second (Table 1). Spot size was approximately 2 to 3 mm as estimated using thermal paper. Laser dosimetry was adjusted in an iterative fashion. As we gained more experience and saw no untoward effects postoperatively, the total number of pulses and pulse repetition rate were increased in patients treated later in this series. The conjunctiva was then loosely reapproximated with 6-0 fast absorbing gut suture.

NIH-PA Author Manuscript

NIH-PA Author Manuscript

NIH-PA Author Manuscript

Photographs

Preoperative and postoperative photographs were standardized with regard to patient position and lighting. Frontal, profile, and three-quarter views were taken with the patient in the Frankfort plane. Five independent facial plastic surgeons and 1 oculoplastic surgeon, each with more than 5 years of practice experience, evaluated the 5 study patients comparing preoperative photographs and 2-month postoperative photographs using an online survey program (QuestionPro; Survey Analytics LLC). (We were not included as evaluators.) Evaluators were asked to assess the change in the amount of lower eyelid pseudoherniation of fat and graded the results as (1) worse than before, (2) unchanged, (3) mild improvement, (4) moderate improvement, (5) complete correction.

Data Analysis

Direct laser irradiation data were analyzed in MatLab (Math-Works). Statistical analysis of patient satisfaction scores and evaluation of preoperative and postoperative photograph scores was performed with Excel (Microsoft) on a Macintosh PC (Apple).

Results

Direct Laser Irradiation Ex Vivo Studies

Irradiance was calculated to determine dosimetry. At 1.5 W with a spot size of 1.0 mm, the irradiance was calculated to be 47.7 W/cm^2; at 2.5 W with a spot size of 3.0 mm, the irradiance was 35.4 W/cm^2; and at 3.5 W with a spot size of 3.1 mm, the irradiance was 46.4 W/cm^2. The trial data were analyzed in Matlab, and the results are plotted on temperature vs number of pulses on a set variable of 1.5 W, 2.5 W, or 3.5 W. Vertical error bars are incorporated onto the graphs to illustrate the variability between trials (Figure 3).

At 1.5 W, the number of pulses to reach the expected temperature of tissue denaturation (60°C–80°C) was 4 on all trials (Figure 3A). At 2.5 W, a total number of 5 pulses were required (Figure 3B) and at 3.5 W, 4 pulses were needed to reach the desired temperature range (Figure 3C).

The OCT imaging showed the initial bovine diaphragmatic tissue thickness to be approximately 1 mm. After laser irradiation to a temperature range of 60°C to 80°C, OCT demonstrated an increase in thickness of up to 2-fold. Figure 4 shows representative images before and after irradiation.

Ho:YAG Laser–Assisted Lower Eyelid Blepharoplasty

Five study patients were selected after interviewing and examining 73 study candidates. No patients had any clinically significant dermatochalasis or evidence of eyelid laxity. Their average age was 35 years. All participants adhered to the scheduled follow-up.

Table 2 summarizes the study patient demographics as well as their satisfaction with the appearance of their lower eyelids 2 months after surgery. Patient satisfaction with the results of the procedure averaged 7 on a 10-point Likert scale. Table 3 presents the evaluation of posttreatment results by 5 facial plastic surgeons and 1 oculoplastic surgeon. For 2 patients,

NIH-PA Author Manuscript

NIH-PA Author Manuscript

NIH-PA Author Manuscript

all 6 evaluators believed there was no difference in the amount of pseudoherniation before and after surgery. For the remainder of the study patients, 3 (50%) of the evaluators believed there was a mild improvement in appearance of the lower eyelids after surgery. There were no complications, such as significant scarring or burns, and no patients demonstrated any evidence of eyelid malposition after surgery. Figure 5 demonstrates the preoperative and 2-month postoperative photographs of a study patient.

Discussion

Lower eyelid blepharoplasty is a deceptively simple operation that has evolved over the past 50 years into a complex array of operations designed to optimally treat the senescent lower eyelid. Isolated pseudoherniation of fat is one of the earliest signs of aging in the lower eyelid and precedes the development of dermatochalasis and tarsal plate weakening. Contemporary treatment of lower eyelid pseudoherniated fat revolves around fat removal, fat repositioning, or fat transfer. There is still much controversy and division over treatment of the orbital septum—a critical structure that fails to retain the protrusion of fat in its native anatomic location in the aging lower eyelid.

The use of lasers in blepharoplasty is not a new concept. However, they are typically used as incisional or hemostatic devices aimed at replacing blades or electrocautery, with the goal of decreasing bruising or improving hemostasis.[15,16] The carbon dioxide laser is the most commonly used laser in blepharoplasty—primarily as a cutting instrument, although other lasers, such as the neodinium:YAG (Nd:YAG) and erbium: YAG (Er:YAG), have been used as well.[17] Prado et al[18] compared the use of the carbon dioxide laser to needle tip electrocautery in septal tightening in a fashion similar to that described by Cook et al.[11] For the lower eyelid, a skin-muscle flap was raised and the electrocautery was applied in a grid-like fashion on one side and the carbon dioxide laser on the contralateral side. No statistical clinical differences were observed between the 2 sides.

While the Ho:YAG laser has been successfully used in many different clinical applications, to our knowledge, there are no reports of its use in blepharoplasty. Our selection, however, of the Ho:YAG laser was not arbitrary. It is a mid-infrared laser that emits light at one of the local absorption peaks for water. Monte Carlo simulations of light transport performed in our laboratory with this laser suggest that the optical penetration depth is approximately 200 to 400 μm. This penetration depth is aptly suited to the thickness of the orbital septum, which varies by our estimates from, at most, 1 mm near the tarsal plates to perhaps less than 100 μm as one approaches the arcus marginalis. We considered other laser wavelengths as well. Visible lasers are widely available and low-cost; however, they rely on hemoglobin as the chromophore and would have less value in the septum, which is largely devoid of blood vessels. Near-infrared lasers are poorly absorbed in tissue and would result in volumetric heating of large regions of tissue without confinement of thermal injury. Carbon dioxide lasers generate light absorbed by water molecules and have a relatively shallow optical penetration depth but create a relatively large region of thermal injury compared with the Ho:YAG laser owing to long pulse durations, which are common in most clinical devices. In addition, carbon dioxide lasers do not lend them-selves readily to small-diameter fibers or

NIH-PA Author Manuscript

NIH-PA Author Manuscript

NIH-PA Author Manuscript

wave guide–driven procedures (eg, passing fiber through a needle <18 gauge). Erbium:YAG lasers share these same limitations as carbon dioxide lasers.

The Ho:YAG laser provides a means to heat a reasonably thin layer of tissue, such as the orbital septum, without significant temperature elevation of the underlying orbital fat. Irradiation of septal tissue will cause denaturation of proteins and local shrinkage of collagen fibers within the septum, theoretically causing septal tightening and decreased protrusion of pseudoherniated orbital fat. Shrinkage of these tissues can be attributed to a number of different synergistic effects, which include the denaturation of matrix macromolecules such as collagen, dehydration (transient), and longer and more chronic processes such as wound healing and scar formation. In our ex vivo model, laser irradiation led to an increase in bovine diaphragmatic tissue thickness, which we used as a proxy for increased tissue rigidity and strength. In vivo, this remains speculative, and in vivo studies are needed to confirm this. Light from the laser can be delivered using low-cost fiber-optics, and the same fibers can be embedded or positioned within small-diameter needles.

Because this study represents a translational reach effort, our focus in this preliminary investigation was to demonstrate the safety and feasibility of this technology. Our ultimate goal, however, is to develop a percutaneous technique to effect septal tightening, which may be of considerable value in the younger patient with early signs of aging. Percutaneous approaches to treat the orbital septum in order to denature and shrink its collagen network have been quite limited. Recently, the use of an Nd:YAG laser to shrink orbital fat was reported[17] with significant complications. This occurred because of a lack of recognition that the thermal energy and subsequent temperature distribution produced by a laser device depends intimately on optical absorption and scattering at the wavelength of interest, and laser pulse duration. Light from Nd:YAG and near-infrared lasers is poorly absorbed by tissue. Spatially selective heating of a specific tissue region requires an understanding of light distribution in tissue and the thermodynamic events that accompany photothermal heating.

A transconjunctival rather than percutaneous approach was chosen for these initial experiments because it allowed us to directly observe the structural change to the septum during the irradiation process. The septal tissue contracted in vivo in an identical fashion to what was observed in our laboratory experiments using bovine fascia. The dosimetry parameters identified in our preclinical studies provided an optimal starting point allowing us to safely and iteratively identify parameters for use in human participants. We monitored surface temperature and observed macroscopic changes in tissue structure and combined these with real-time OCT imaging to verify that structural changes occurred in the tissue rather than the effect being a consequence of water loss alone. The OCT data were critical because there is no specific temperature range that exists as an absolute target over which tissues undergo this change. Tissue shrinkage results from loss of tertiary structure of matrix macromolecules, and the kinetics of this reaction are dependent on both time and temperature in a nonlinear fashion. The heating rate affects the temperature at which this occurs, although our studies indicate a range of 60°C to 80°C over which these changes are observed during relatively fast laser heating. Lasers have an obvious advantage over any other heat source because the spatial extent of thermal injury can be precisely controlled[19]

NIH-PA Author Manuscript

NIH-PA Author Manuscript

NIH-PA Author Manuscript

and the widespread availability of low-cost semiconductor and rare-earth–doped fiber lasers now make this technology affordable.

The clinical results of this study are the most important outcomes because they not only provide a link between our ex vivo investigations and laser dosimetry but, more importantly, they provide evidence that the use of the Ho:YAG laser can be safely used on the lower eyelid orbital septum. Intra-operatively, we observed significant shrinkage of the orbital septum with reduction of fat protrusion. Postoperatively, over the limited follow-up time intervals in this preliminary investigation, the clinical outcomes were less compelling, with most of the 30 evaluations being unchanged. Nevertheless, 50% of the evaluators believed there was a mild improvement in appearance of the lower eyelids after surgery in 3 of the 5 study patients. This indicates that the procedure has the potential to ameliorate some of the changes that accompany the early aging processes of the lower eyelid. However, fibrosis produced by the preseptal dissection might produce tightening of the septum independent of laser heating. The subtle results and lack of complications suggests that we can increase laser dosimetry in future studies aimed specifically at achieving efficacy. In our first study participants, we were extremely conservative and loosely spaced our laser target spots to allow for significant regions of nonirradiated septal tissue to separate areas of heating. Based on the results of the first few patients in this study, we progressively increased both the number of laser irradiation pulses and the density in which these laser spots were placed.

Obviously, septal tightening procedures will not treat the deficits associated with more advanced aging of the lower eyelid, such as dermatochalasis, severe pseudoherniation of orbital fat, festoons, and lagophthalmos. Our aim was to develop a technology applicable to the patient with mild changes in the lower eyelid related to subtle fat pseudoherniation who is not yet ready to undergo more comprehensive eyelid rejuvenation with its associated longer recovery period. With the current technology, a percutaneous Ho:YAG laser–based septal tightening procedure could conceivably be performed in the office using local anesthesia. Identifying the appropriate tissue plane may be challenging, but this may be overcome with the use of ultrasonography for guidance, which is now available with low-cost devices commonly found in many medical offices. However, we believe with appropriate training, positioning the fiber in the correct tissue plane without the use of ultrasonography will be a reasonably simple task, especially for those surgeons who have expertise in fat transfer procedures or other injectable treatments.

Future research will focus on escalating the dosimetry to obtain more significant reduction of pseudoherniation of orbital fat. The transition to a percutaneous technique will require the development of specialized needles to deliver a fiber into the lower eyelid and specialized fiber tips that would allow the creation of uniform fluence rate distributions in the vicinity of the needle tip as well as reevaluation of ultrasonographic technology to aid in guiding the needle. This work is ongoing in our research laboratories.

Conclusions

Using dosimetry data obtained from a bovine model, this pilot clinical study has demonstrated that Ho:YAG laser blepharoplasty is a safe procedure that holds the potential

NIH-PA Author Manuscript

NIH-PA Author Manuscript

NIH-PA Author Manuscript

to ameliorate mild pseudoherniation of lower eyelid orbital fat. The transconjunctival approach is a first step toward the development of percutaneous techniques. Nevertheless, further refinements in laser dosimetry will be necessary to optimize results as well as a larger clinical series and longer follow-up to have a better understanding of long-term changes to the lower eyelid.

Acknowledgments

Funding/Support: This research was supported by an unrestricted research grant from Newstar Laser (Roseville, California).

References

1. Surgeons ASoP. [Accessed May 15, 2010] National plastic surgery statistics: cosmetic and reconstructive procedure trends. 2000/2007/2008. http://www.plasticsurgery.org/Documents/news-resources/statistics/2008-statistics/2008-cosmetic-reconstructive-plastic-surgery-minimally-invasive-statistics.pdf
2. Aston SJ. Skin-muscle flap lower lid blepharoplasty. Clin Plast Surg. 1988; 15(2):305–308. [PubMed: 3349743]
3. Coleman SR. Facial recontouring with lipostructure. Clin Plast Surg. 1997; 24(2):347–367. [PubMed: 9142473]
4. Hamra ST. Arcus marginalis release and orbital fat preservation in midface rejuvenation. Plast Reconstr Surg. 1995; 96(2):354–362. [PubMed: 7624408]
5. Tessier P. The conjunctival approach to the orbital floor and maxilla in congenital malformation and trauma. J Maxillofac Surg. 1973; 1(1):3–8. [PubMed: 4521446]
6. Lelli GJ Jr, Lisman RD. Blepharoplasty complications. Plast Reconstr Surg. 2010; 125(3):1007–1017. [PubMed: 20195127]
7. de la Plaza R, Arroyo JM. A new technique for the treatment of palpebral bags. Plast Reconstr Surg. 1988; 81(5):677–687. [PubMed: 3362986]
8. Huang T. Reduction of lower palpebral bulge by plicating attenuated orbital septa: a technical modification in cosmetic blepharoplasty. Plast Reconstr Surg. 2000; 105(7):2552–2558. [PubMed: 10845312]
9. Mühlbauer W, Holm C. Orbital septorhaphy for the correction of baggy upper and lower eyelids. Aesthetic Plast Surg. 2000; 24(6):418–423. [PubMed: 11246429]
10. Sensöz O, Unlü RE, Perçin A, Baran CN, Celebioglu S, Ortak T. Septo-orbitoperiostoplasty for the treatment of palpebral bags: a 10-year experience. Plast Reconstr Surg. 1998; 101(6):1657–1663. [PubMed: 9583503]
11. Cook TA, Derebery J, Harrah ER. Reconsideration of fat pad management in lower lid blepharoplasty surgery. Arch Otolaryngol. 1984; 110 (8):521–524. [PubMed: 6743099]
12. Chao KK, Cheung E, Armstrong WB, Wong BJ. The effect of optical design on micromanipulator spot size using CO2 laser irradiation. Otolaryngol Head Neck Surg. 2002; 126(6):593–597. [PubMed: 12087323]
13. Li C, Protsenko DE, Zemek A, Chae YS, Wong B. Analysis of Nd:YAG laser-mediated thermal damage in rabbit nasal septal cartilage. Lasers Surg Med. 2007; 39(5):451–457. [PubMed: 17565732]
14. Rubinstein M, Fine EL, Sepehr A, et al. Optical coherence tomography of the larynx using the Niris system. J Otolaryngol Head Neck Surg. 2010; 39(2):150–156. [PubMed: 20211101]
15. Kontoes PP, Lambrinaki N, Vlachos SP. Laser-assisted blepharoplasty and inferior lateral retinaculum plication: skin contraction versus skin traction. Aesthetic Plast Surg. 2007; 31(5):579–585. [PubMed: 17659409]
16. Rokhsar CK, Ciocon DH, Detweiler S, Fitzpatrick RE. The short pulse carbon dioxide laser versus the Colorado needle tip with electrocautery for upper and lower eyelid blepharoplasty. Lasers Surg Med. 2008; 40(2):159–164. [PubMed: 18306246]

NIH-PA Author Manuscript

NIH-PA Author Manuscript

NIH-PA Author Manuscript

17. Yu D, Biesman B, Khan JA. Bilateral eyelid dermal burn from subcutaneous diode laser lipolysis blepharoplasty. Lasers Surg Med. 2009; 41(9):609–611. [PubMed: 19827146]

18. Prado A, Andrades P, Danilla S, Castillo P, Benitez S. Nonresective shrinkage of the septum and fat compartments of the upper and lower eyelids: a comparative study with carbon dioxide laser and Colorado needle. Plast Reconstr Surg. 2006; 117(6):1725–1735. [PubMed: 16651943]

19. Jacques SL. Role of tissue optics and pulse duration on tissue effects during high-power laser irradiation. Appl Opt. 1993; 32(13):2447–2454. [PubMed: 20820404]

NIH-PA Author Manuscript
NIH-PA Author Manuscript
NIH-PA Author Manuscript

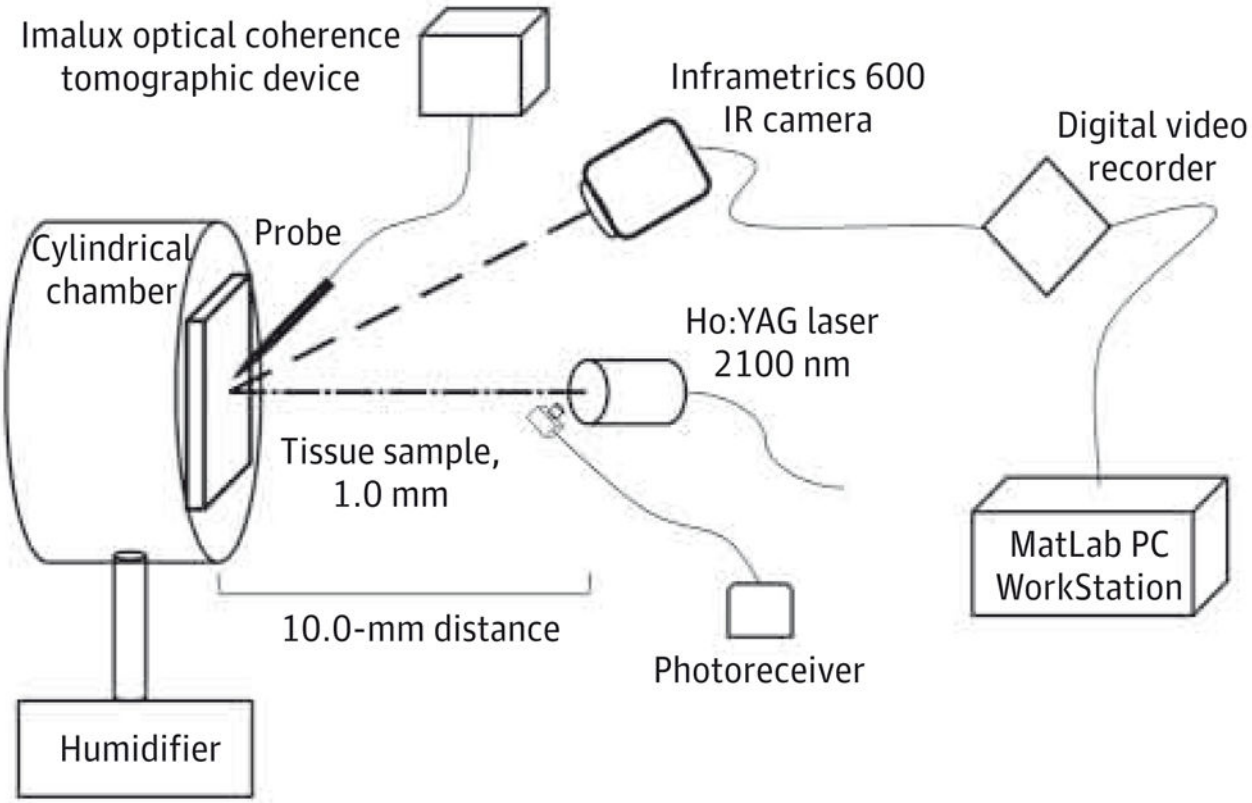

Figure 1. Schematic of Direct Laser Irradiation (IR) Setup

Schematic of setup for direct laser irradiation of ex vivo bovine tissue. Ho:YAG indicates holmium:yttrium aluminum garnet.

NIH-PA Author Manuscript

NIH-PA Author Manuscript

NIH-PA Author Manuscript

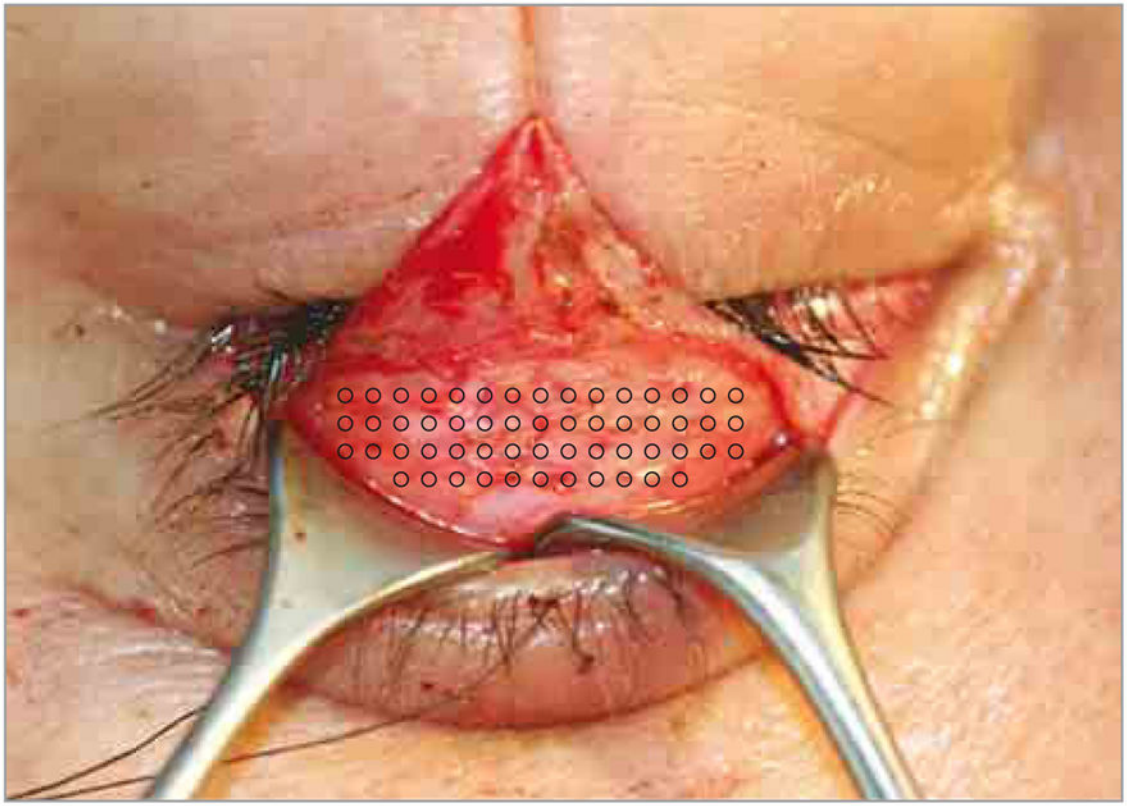

Figure 2. Intraoperative Exposure of the Orbital Septum

Intraoperative photograph demonstrating exposure of orbital septum through a transconjunctival approach. Black circles indicate the typical pattern of laser irradiation.

NIH-PA Author Manuscript

NIH-PA Author Manuscript

NIH-PA Author Manuscript

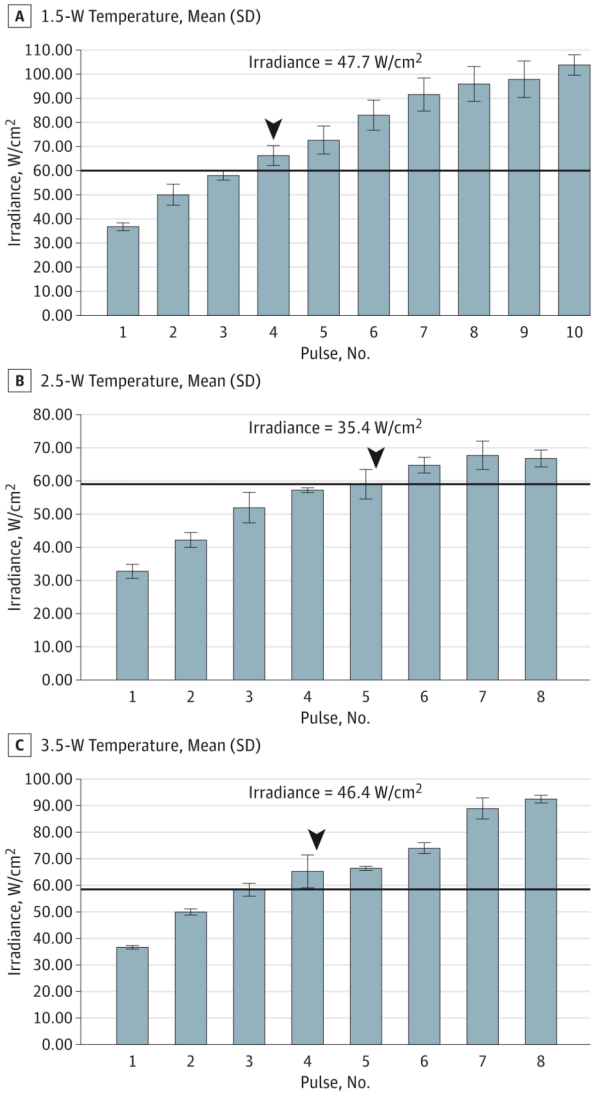

Figure 3. Number of Pulses vs Temperature

Bar graph of number of pulses vs temperature at (A) 1.5 W, (B) 2.5 W, and 3.5 W. Arrowheads denote the minimum number of pulses required to cross the critical 60°C threshold.

NIH-PA Author Manuscript

NIH-PA Author Manuscript

NIH-PA Author Manuscript



Figure 4. Optical Coherence Tomographic Images of Bovine Diaphragmatic Tissues Before and After Holmium:Yttrium Aluminum Garnet (Ho:YAG) Laser Irradiation

Optical coherence tomographic images of bovine diaphragmatic tissues (A) before and (B) after irradiation with the Ho:YAG laser to a temperature range of 60° to 80°C and a setting of 3.5 W at 8 Hz using 6 pulses.

NIH-PA Author Manuscript

NIH-PA Author Manuscript

NIH-PA Author Manuscript

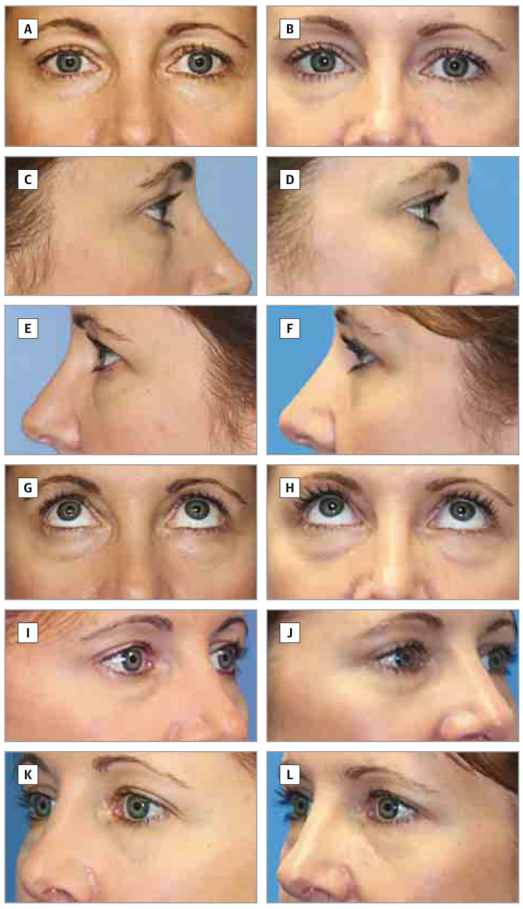

Figure 5. Preoperative and Postoperative Photographs

Preoperative (A, C, E, G, I, K) and 2-month (B, D, F, H, J, K) postoperative photographs of patient 2 after lower eyelid holmium:yttrium aluminum garnet (Ho:YAG) laser septal tightening.

NIH-PA Author Manuscript

NIH-PA Author Manuscript

NIH-PA Author Manuscript

Table 1

Ho:YAG Laser Settings

			Macropulses	
Patient No.	**Watts**	**Pulses per Second**	**Right**	**Left**
1	2	10	15	19
2	2	8	16	15
3	1	10	30	33
4	2	10	75	70
5	3	8	63	55

Abbreviation: Ho:YAG, holmium: yttrium aluminum garnet.

NIH-PA Author Manuscript

NIH-PA Author Manuscript

NIH-PA Author Manuscript

Table 2

Patient Demographics and Patient Satisfaction Scores[a]

Patient No./Sex/Age, y	Satisfaction Score
1/M/38	4
2/F/40	7
3/M/36	10
4/F/30	9
5/M/32	6

[a]Two months after surgery. Scores are on a scale of 1 to 10 (1, completely unsatisfied; 10, completely satisfied).

NIH-PA Author Manuscript

NIH-PA Author Manuscript

NIH-PA Author Manuscript

Table 3

Physician Evaluator Scores of 2-Month Postoperative Results[a]

	No. (%)			
			Improvement	
Patient No.	1 (Worse)	2 (Unchanged)	3 (Mild)	4 (Moderate)
1	0	3 (50)	3 (50)	0
2	0	2 (33)	3 (50)	1 (17)
3	0	6 (100)	0	0
4	1 (17)	2 (33)	3 (50)	0
5	0	6 (100)	0	0

[a]Five board-certified facial plastic surgeons and 1 oculoplastic surgeon served as evaluators. Scores were assigned on a 5-point (5 indicates complete correction) system, but no evaluators gave a score of 5.