

UCSF

UC San Francisco Previously Published Works

Title

Compact in vivo handheld dual SWIR transillumination/reflectance imaging system for the detection of proximal and occlusal lesions

Permalink

<https://escholarship.org/uc/item/5444j29r>

Authors

Zhu, Yihua

Simon, Jacob

Ng, Chung

et al.

Publication Date

2021-03-01

DOI

10.1117/12.2584903

Copyright Information

This work is made available under the terms of a Creative Commons Attribution-NonCommercial-NoDerivatives License, available at <https://creativecommons.org/licenses/by-nc-nd/4.0/>

Peer reviewed



Published in final edited form as:

*Proc SPIE Int Soc Opt Eng.* 2021 March ; 11627: . doi:10.1117/12.2584903.

## Compact *in vivo* handheld dual SWIR transillumination/ reflectance imaging system for the detection of proximal and occlusal lesions

Yihua Zhu, Jacob Simon, Chung Ng, Daniel Fried\*

University of California, San Francisco, San Francisco, CA 94143-0758

### Abstract

We have developed a clinical probe capable of acquiring simultaneous short wavelength infrared (SWIR) cross-polarized reflectance and occlusal transillumination images of lesions on tooth proximal and occlusal surfaces. We hypothesize that the dual SWIR reflectance and transillumination probe will improve the diagnostic accuracy of the device by reducing false positives since it is unlikely that confounding structural features or specular reflection are going to be present in both reflectance and transillumination images. In addition, the dual probe will provide complementary diagnostic information about lesion severity to help discriminate early superficial lesions on tooth surfaces from deeply penetrating lesions. The dual probe was 3D printed and equipped with a compact InGaAs camera and broadband superluminescent diode light sources that emit broadband light at 1300 nm for occlusal transillumination and 1600 nm light for cross-polarization reflectance measurements. The first clinical images acquired using this novel probe are presented.

### Keywords

SWIR imaging; caries detection; reflectance; transillumination

## 1. INTRODUCTION

Short wavelength infrared (SWIR) and near-IR (NIR) imaging methods have been under development for almost 20 years for the use in dentistry and several clinical devices are now available commercially. Due to the high transparency of enamel at these wavelengths, novel imaging configurations are feasible in which the tooth can be imaged from the occlusal surface after shining light at and below the gum line, which we call occlusal transillumination [1, 2]. Approximal lesions can be imaged by occlusal transillumination of the proximal contact points between teeth and by directing SWIR light below the crown while imaging the occlusal surface [2-4]. The latter approach is capable of imaging occlusal lesions as well with high contrast [1, 2, 5-8]. In 2010, it was demonstrated that approximal lesions that appeared on radiographs could be detected *in vivo* with SWIR imaging with similar sensitivity [2] and that occlusal transillumination could be employed clinically. This

\*. daniel.fried@ucsf.edu.

was the first step in demonstrating the clinical potential of near-IR imaging for approximal caries detection. In another clinical study [9] at wavelengths greater than 1300-nm, we measured the diagnostic performance of both SWIR transillumination and SWIR reflectance probes for detecting caries lesions in premolar teeth scheduled for extraction. The teeth were collected and sectioned and examined with polarized light microscopy and transverse microradiography which served as the gold standard. In addition, extraoral radiographs were taken of teeth and the diagnostic performance of SWIR imaging was compared with radiography. It was anticipated that SWIR methods would be more sensitive to occlusal lesions than radiographs since the radiographic sensitivity for occlusal lesions is extremely poor, however, the sensitivity was also much higher for approximal lesions than radiography, 0.53 vs 0.23. In addition, the sensitivity of each individual SWIR method was either individually equal to or higher than radiography.

Prior *in vitro* studies attempted to combine SWIR reflectance and transillumination measurements taken at SWIR wavelengths in order to estimate the depth of occlusal lesions [7, 10, 11]. Since, multispectral SWIR reflectance and transillumination experiments have demonstrated that the tooth appears darker at wavelengths coincident with increased water absorption, multispectral images can be used to produce increased contrast between sound enamel and dentin, dental decay and composite restorative materials [12-14]. Combining measurements from different SWIR imaging wavelengths and comparing them with concurrent measurements acquired by complementary imaging modalities should provide improved assessment of lesion depth and severity. The SWIR reflectance and transillumination probe should reduce false positives since it is unlikely that confounding structural features or specular reflection are going to be present in both reflectance and transillumination images. In addition, the dual probe will provide complementary diagnostic information about lesion severity to help discriminate early superficial lesions on tooth surfaces from deeply penetrating lesions.

Last year we presented the results of an *in vitro* study using a prototype dual transillumination and reflectance probe with a germanium enhanced silicon sensor that was sensitive from 400-1600 nm [15]. We later expanded that study to evaluate 120 extracted teeth and used a high resolution InGaAs camera. In addition, the diagnostic performance of radiography, the individual reflectance and transillumination images, dual images and fused images were compared using micro computed tomography (microCT) as the gold standard [16]. Reflectance imaging at 1600 nm yielded the highest diagnostic accuracy for lesions on both occlusal and proximal surfaces while radiography yielded the lowest number of false positives. In this paper, we present the first clinical images taken using the dual handpiece at 1300 and 1600 nm.

## 2. MATERIALS AND METHODS

### 2.1 Test Subjects

Test subjects aged 12-60 were imaged at the UCSF Dental Clinics as part of an NIH funded study. Imaging was performed on patients with 2-4 premolars scheduled for extraction due to orthodontic reasons with the test subjects consent, UCSF IRB #19-27656. Teeth will be

collected post extraction for histological sectioning and examination with transverse microradiography to confirm lesion presence.

## 2.2 Visible/Color Images

Color/visible intra-oral images of each tooth were acquired using a MD740 Dental Intraoral camera with disposable, single-use protective sheaths.

## 2.3 Dual SWIR probe

The dual transillumination and reflectance probe was designed in Fusion 360 from Autodesk (San Francisco, CA). The dual probe is assembled from two 3D printed components, a reflectance probe body that connects the camera and optics to the acquisition mirror and a transillumination component that attaches to the end of the body. All attachments were printed using Form 2 and Form 3 printers from Formlabs (Boston, MA). Detailed diagrams of the components are shown in reference [16]. The reflectance probe body consists of a right-angle aluminum mirror to collect light from the occlusal surface and an attachment for the reflectance fiber and polarizing beam splitter. A low-OH optical fiber of 1 mm diameter fiber is inserted into a cylindrical Teflon plug (3.2 x 40 mm). Light exiting the plug is incident on a polarizing beam splitting cube that directs polarized light towards the tooth occlusal surface. There is an air nozzle attached to the reflectance body near the mirror to prevent fogging of the mirror. The air nozzle can also be used to dry the lesion to increase lesion contrast and potentially assess lesion activity [17-19]. The transillumination attachment is designed to slide over and attach to the end of the reflectance probe body. The low-OH, 0.4 mm diameter transillumination fibers enter from the bottom of the attachment into two cylindrical Teflon plugs (3.2 x 40 mm) that deliver diffuse light out of two ports on the distal end of each extension. An image of the fully assembled probe is shown in Fig. 1.

The SWIR reflectance images were captured using a 640 x 480 pixel micro-SWIR camera (SU640CSX) measuring only 32 x 32 x 28 mm from Sensors Unlimited (Princeton, NJ). Two planoconvex antireflection coated lenses of 60 and 100 mm focal length along with an adjustable aperture were placed between the handpiece and the InGaAs camera to provide a field of view of 11 mm<sup>2</sup> at the focus plane. Light from a 1604 nm superluminescent diode (SLD), Model ESL 1620-2111 from Exalos (Schlieren, Switzerland) with an output of 17 mW and a bandwidth of 46-nm was used for reflectance. The intensity delivered to the tooth was 5-mW. A 1314-nm (BW) SLD, Model DL-CS3452A-FP 1620-2111 from Denselight (Singapore) with a peak output of 48 mW and a bandwidth of 33 nm attached to a 50/50 beamsplitter was used as the source for transillumination. The output intensity of each arm was set at 10 mw before entering the Teflon plugs. The reflectance and transillumination light sources output were controlled via two OSW12(22) MEMS fiber optic switches from Thorlabs. The camera and the optic switch were controlled in custom authored programs in LabView (Austin, TX). The two optical switches alternate between the 1300 nm light source for transillumination and the 1600 nm source for reflectance allowing near simultaneous acquisition at a rate of 30 Hz.

### 3. RESULTS AND DISCUSSION

Clinical testing of the dual probe has provided successful acquisition of high resolution transillumination and reflectance images at 30Hz frame rates providing real-time multimodal SWIR measurements. Figure 2 shows a visible and transillumination/reflectance images of a maxillary first premolar taken by the dual probe *in vivo*. Based on the reflectance and transillumination images it appears that there may be an interproximal lesion on this tooth at the position within the dashed circle. There appears to be no demineralization in the fissures on the tooth occlusal surface. The suspected lesion appears darker in transillumination since the increased scattering by the lesion attenuates the light transmitted through the tooth, while it appears lighter in reflectance due to the scattered light from the lesion. This sample, as well as all future samples in the study will be collected after extraction and histologically sectioned to confirm or deny the presence of an actual lesion. Over the next 1-2 years we plan on imaging premolars scheduled for extraction for orthodontics on 40 test subjects with 2-4 premolars scheduled for extraction producing a study with sample size of n=100-160.


### ACKNOWLEDGEMENTS

The authors would like to acknowledge the support of NIDCR/NIH grants R01-DE028295 and F30-DE027264.

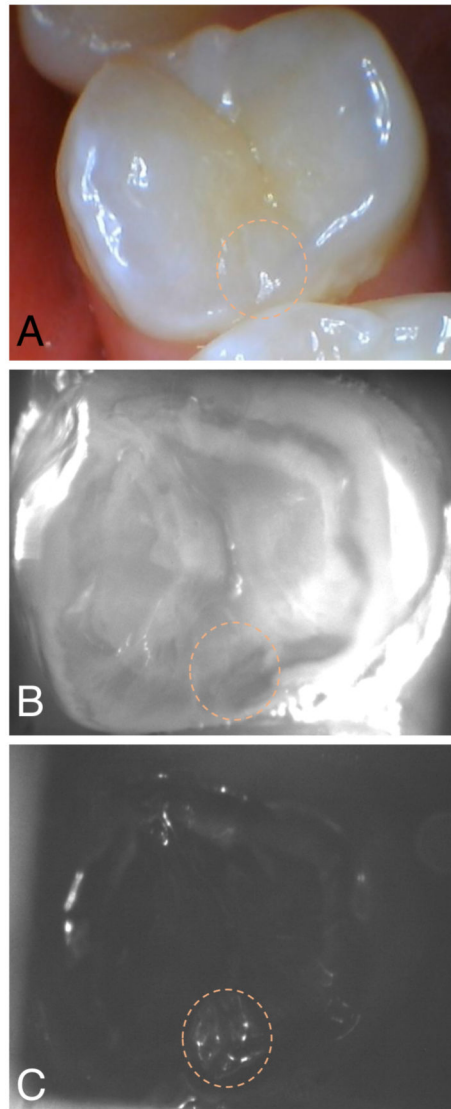
### 5. REFERENCES

- [1]. Buhler C, Ngaoheppitak P, and Fried D, "Imaging of occlusal dental caries (decay) with near-IR light at 1310-nm," *Optics Express*, 13(2), 573–82 (2005). [PubMed: 19488387]
- [2]. Staninec M, Lee C, Darling CL, and Fried D, "In vivo near-IR imaging of approximal dental decay at 1,310 nm," *Lasers Surg Med* 42(4), 292–8 (2010). [PubMed: 20432277]
- [3]. Jones G, Jones RS, and Fried D, "Transillumination of interproximal caries lesions with 830-nm light," *Lasers in Dentistry X. Proc. SPIE*, Vol. 5313 17–22 (2004).
- [4]. Jones RS, Huynh GD, Jones GC, and Fried D, "Near-IR Transillumination at 1310-nm for the Imaging of Early Dental Caries," *Optics Express*, 11(18), 2259–2265 (2003). [PubMed: 19466117]
- [5]. Fried D, Featherstone JDB, Darling CL, Jones RS, Ngaoheppitak P, and Buehler CM, "Early Caries Imaging and Monitoring with Near-IR Light," *Dental Clinics of North America - Incipient and Hidden Caries*, 49(4), 771–794 (2005).
- [6]. Hirasuna K, Fried D, and Darling CL, "Near-IR imaging of developmental defects in dental enamel," *J Biomed Opt*, 13(4), 044011:1–7 (2008). [PubMed: 19021339]
- [7]. Lee C, Lee D, Darling CL, and Fried D, "Nondestructive assessment of the severity of occlusal caries lesions with near-infrared imaging at 1310 nm," *J Biomed Opt*, 15(4), 047011 (2010). [PubMed: 20799842]
- [8]. Karlsson L, Maia AMA, Kyotoku BBC, Tranaeus S, Gomes ASL, and Margulis W, "Near-infrared transillumination of teeth: measurement of a system performance," *J Biomed Opt* 15(3), 036001–8 (2010). [PubMed: 20615003]
- [9]. Simon JC, Lucas SA, Lee RC, Staninec M, Tom H, Chan KH, Darling CL, and Fried D, "Near-IR Transillumination and Reflectance Imaging at 1300-nm and 1500-1700-nm for in vivo Caries Detection," *Lasers Surg Med*, 48(6), 828–836 (2016). [PubMed: 27389018]
- [10]. Lee C, Darling CL, and Fried D, "In vitro near-infrared imaging of occlusal dental caries using a germanium enhanced CMOS camera," *Lasers in Dentistry XVI. Vol. 7549 K:1–7* (2010).
- [11]. Simon JC, Curtis DA, Darling CL, and Fried D, "Multispectral near-infrared reflectance and transillumination imaging of occlusal carious lesions: variations in lesion contrast with lesion depth," *Lasers in Dentistry XXIV. Proc. SPIE Vol. 10473 05:1–7* (2018).

- [12]. Zakian C, Pretty I, and Ellwood R, "Near-infrared hyperspectral imaging of teeth for dental caries detection," *J Biomed Opt*, 14(6), 064047 (2009). [PubMed: 20059285]
- [13]. Tom H, Simon JC, Chan KH, Darling CL, and Fried D, "Near-infrared imaging of demineralization under sealants," *J Biomed Opt*, 19(7), 77003 (2014). [PubMed: 25036214]
- [14]. Simon JC, Lucas S, Lee R, Darling CL, Staninec M, Vanderhobli R, Pelzner R, and Fried D, "Near-infrared imaging of natural secondary caries," *Lasers in Dentistry XXI. Proc. SPIE Vol. 9306 F:1–8* (2015).
- [15]. Zhu Y, Chang N, Fried WA, Yang V, and Fried D, "A dual handheld SWIR transillumination/reflectance probe for imaging lesions on tooth occlusal and proximal surfaces," *Lasers in Dentistry XXVI. Proc. SPIE Vol. 11217 J:1–7* (2018).
- [16]. Zhu Y, Abdelaziz M, Simon J, Le O, and Fried D, "Dual Short Wavelength Infrared transillumination/reflectance mode imaging for caries detection," *J Biomed Opt* 26(4), 043004 (2021).
- [17]. Lee RC, Darling CL, and Fried D, "Assessment of remineralization via measurement of dehydration rates with thermal and near-IR reflectance imaging," *J Dent* 43, 1032–1042 (2015). [PubMed: 25862275]
- [18]. Lee RC, Darling CL, and Fried D, "Activity assessment of root caries lesions with thermal and near-infrared imaging methods," *J Biophotonics*, 10(3), 433–445 (2016). [PubMed: 27060450]
- [19]. Lee RC, Staninec M, Le O, and Fried D, "Infrared methods for assessment of the activity of natural enamel caries lesions," *IEEE J Sel Top Quant Elect*, 22(3), 6803609 (2014).



**Fig 1.**  
The dual occlusal transillumination (1300 nm) and cross polarization reflectance (1600 nm) probe.



**Fig 2.**  
A set of *in vivo* images taken by the dual probe. (A) visible, (B) occlusal transillumination and cross polarization (C) reflectance images of a suspected interproximal lesion (dashed circle).