

UC Irvine

UC Irvine Previously Published Works

Title

Intracameral Tissue Plasminogen Activator Use in a Large Series of Eyes With Valved Glaucoma Drainage Implants

Permalink

<https://escholarship.org/uc/item/5463g46b>

Journal

JAMA Ophthalmology, 120(11)

ISSN

2168-6165

Authors

Zalta, Alan H
Sweeney, Charles P
Zalta, Alyson K
[et al.](#)

Publication Date

2002-11-01

DOI

10.1001/archopht.120.11.1487

Copyright Information

This work is made available under the terms of a Creative Commons Attribution License, available at <https://creativecommons.org/licenses/by/4.0/>

Peer reviewed

Intracameral Tissue Plasminogen Activator Use in a Large Series of Eyes With Valved Glaucoma Drainage Implants

Alan H. Zalta, MD; Charles P. Sweeney, MD; Alyson K. Zalta; Adam H. Kaufman, MD

Objective: To describe the efficacy and complications of intracameral tissue plasminogen activator (tPA) in a large series of glaucomatous eyes with valved glaucoma drainage implants (GDIs).

Methods: A retrospective analysis of 620 Ahmed and Krupin aqueous shunts implanted between December 1992 and May 2001 identified 36 eyes treated with intracameral tPA for total or imminent tube obstruction by fibrin and/or blood. For a successful ocular outcome, tPA use must prevent the need for additional glaucoma surgery to replace or revise an occluded drainage implant.

Results: Intracameral tPA successfully cleared or prevented tube occlusion by fibrin/blood clots in 32 (88.9%) of 36 eyes. Multiple tPA injections were administered in

38.9% of eyes, and the mean number of injections required to achieve successful outcomes was 1.6. The mean±SD tPA dose per injection was 9.8±3.1 µg, and the mean±SD total tPA dose required to achieve successful outcomes was 15.5±9.9 µg. For injections to be successful in totally occluded tubes (n=31), the mean±SD intraocular pressure change 24 hours after tPA administration was -21.2±15.6 mm Hg. Significant complications, including severe hyphema, profound hypotony, and anterior chamber flattening, occurred after 10.9% of tPA administrations.

Conclusion: Intracameral tPA clears and prevents obstruction of valved GDIs by fibrin and/or blood clots.

Arch Ophthalmol. 2002;120:1487-1493

GLAUCOMA DRAINAGE implant (GDI) surgery is commonly complicated by hyphema and/or fibrin resulting from the sclerotomy, tube insertion, iridectomy, the rapid change in intraocular pressure (IOP), or underlying conditions. Neovascular glaucoma and the inflammatory types of glaucoma are especially prone to intraoperative or postoperative bleeding and fibrin formation due to the presence of rubeosis iridis and an altered blood-aqueous barrier. Intraocular blood and/or fibrin may obstruct the internal tube lumen, thereby compromising aqueous outflow and causing filtration failure. Complete tube obstruction usually causes severe IOP elevation, which further damages an already compromised optic nerve and visual field. Conservative measures, including oral, periocular, and topical steroids often fail to lyse these clots and restore outflow patency. Conventional surgical procedures to remove a blood or fibrin clot that is obstructing a tube lumen are invasive, require a return to the operating room, may precipitate new bleeding or fibrin formation, and have all of the attendant risks of intraocular surgery.

Tissue plasminogen activator (tPA) is a naturally occurring serine protease with clot-specific fibrinolytic activity. It is an enzyme that binds to fibrin in a thrombus, catalyzes the conversion of plasminogen to plasmin, and promotes the lysis of newly formed clots. Recombinant tPA¹ has been extensively used in the treatment of acute myocardial infarction, acute ischemic stroke, and acute massive pulmonary embolism. When administered systemically, tPA has an initial half-life of less than 5 minutes. Once bound to fibrin, tPA may have prolonged fibrinolytic activity for more than 7 hours.² During the last decade, recombinant tPA¹ has been used to dissolve intraocular blood and/or fibrin clots after a variety of eye surgeries, including vitreoretinal surgery,³⁻⁵ penetrating keratoplasty,⁶ cataract extraction,^{7,8} and glaucoma surgery.⁸⁻¹⁹ To our knowledge, tPA use after GDI surgery has been described thus far for only 7 nonvalved implants.⁸⁻¹¹

We present the largest experience to date of tPA use after GDI surgery, the only case series of tPA use in valved implants, and long-term follow-up of intracameral tPA use. Our findings—the indications for tPA use, its short-term and long-term suc-

From the Department of Ophthalmology, University of Cincinnati College of Medicine, Cincinnati, Ohio (Drs Zalta and Kaufman); Cincinnati Eye Institute, Cincinnati (Drs Zalta and Kaufman); Department of the Army, Brooke Army Medical Center, Fort Sam Houston, Tex (Dr Sweeney); and Harvard College, Cambridge, Mass (Ms Zalta).

Patient Demographics

	No. of Eyes (n = 36)
Diagnosis	
Neovascular glaucoma	19
Inflammatory glaucoma	6
Primary open-angle glaucoma	3
Traumatic/exfoliation glaucoma	3
Secondary angle-closure glaucoma	2
Primary angle-closure glaucoma	2
Congenital glaucoma	1
Sex	
Male	17
Female	19
Race	
White	13
Black	23
Age, y, mean \pm SD (range)	63 \pm 23 (6-89)
Follow-up, mo, mean \pm SD (range)	30 \pm 22 (3-82)

cess in clearing obstructed tubes or preventing tube obstruction, and the complications associated with its use—are all examined and reported here.

METHODS

The medical records of 620 eyes that received valved GDI surgery performed on the glaucoma service at the University of Cincinnati Medical Center (Cincinnati, Ohio) between December 1992 and May 2001 were reviewed and analyzed. A total of 65 Krupin Eye Valves With Disc (Hood Laboratories, Pembroke, Mass) and 555 Ahmed Glaucoma Valves (New World Medical Inc, Rancho Cucamonga, Calif) were implanted during this 8 $\frac{1}{2}$ -year interval. Of these 620 aqueous tube shunt procedures, 36 eyes of 33 patients received intracameral tPA for the treatment of total or imminent obstruction by blood and/or fibrin clots. Patients who received tPA had either elevated IOP with observable total occlusion of the tube lumen by blood and/or fibrin, or normal IOP with a large blood and/or fibrin clot partially occluding or threatening to obstruct the tube lumen. Imminent tube occlusion includes both partial obstruction, defined by large clots visibly extending into the lumen and up the tube shaft, and threatened obstruction, defined by large clots visibly positioned at or near the proximal tube opening without extending into the tube lumen. Fibrin and/or blood clots located more than 2 mm from the tube ostium were not considered threatening. The rationale to treat imminent tube occlusion with intracameral tPA was conceptually similar to that of laser iridotomy for impending iris bombe in which 360° of posterior synechiae are present and the IOP is still normal. In both cases, acute glaucoma with its attendant damage is inevitable, and treatment of a comfortable eye with a clear cornea is preferable to that of a painful eye with an edematous cornea. Patient demographics and diagnoses are presented in the **Table**.

Intracameral tPA was administered in eyes with total or imminent tube occlusion after intense intraoperative and/or postoperative steroid treatment and other conservative measures failed to prevent or diminish the fibrin and/or blood clots. All patients with a preoperative diagnosis of chronic uveitis received intravenous methylprednisolone sodium succinate, 2 mg/kg, intraoperatively. All eyes undergoing valved GDI surgery were routinely treated with 100 mg of dexamethasone injected subconjunctivally into the inferior cul-de-sac at the completion of surgery and the following topical medications beginning on postoperative day 1: 1% atropine, 1 drop every 12 hours, and

either tobramycin-dexamethasone, 1 drop 4 times per day, or a combination of prednisolone acetate and ciprofloxacin hydrochloride, each 1 drop 4 times per day. In eyes with severe postoperative fibrinoid reactions or combined fibrin-blood clots, topical prednisolone acetate was prescribed every one half to 1 hour while awake and one-half inch of topical neomycin-polymixin B sulfates-bacitracin zinc-hydrocortisone acetate ointment was instilled at bedtime. Additional conservative measures for treating eyes with total or imminent tube occlusion included 1 or more of the following measures: aqueous suppressant medications, 100 mg of dexamethasone injected subconjunctivally into the inferior cul-de-sac every 1 to 4 days, 30 to 40 mg per day of oral prednisone, and release of aqueous through the paracentesis tract 1 day prior to intracameral tPA use.

Tissue plasminogen activator was prepared by the hospital pharmacy staff from lyophilized recombinant tPA (Acti-vase, Genentech Inc, San Francisco, Calif)¹ by dilution with sterile water to an initial concentration of 100 μ g/0.1 mL. Subsequent dilution with 0.9% sodium chloride resulted in a final concentration of 6 μ g/0.1 mL or 10 μ g/0.1 mL. After preparation, aliquots of 0.3 mL were stored at -20°C or lower and then thawed at room temperature immediately before use.

Prior to tPA administration, all eyes received 3 drops of a broad-spectrum topical antibiotic, 1 drop of a 5% betadine solution, and 1 drop of a topical anesthetic. A sterile eyelid speculum was placed in the eye to prevent eyelid closure. Using sterile precautions and technique, a 30-gauge cannula attached to a tuberculin syringe was inserted into the anterior chamber through a paracentesis tract. This procedure was performed at the office slitlamp microscope in 33 eyes and at an operating room microscope in 3 eyes.

Single doses of 5 to 20 μ g of tPA were injected intracamerally, depending on the physician's assessment of the severity of fibrin and/or blood in the anterior chamber. If the IOP was significantly elevated before the procedure, aqueous humor was released externally through the paracentesis tract prior to tPA injection. This was performed by tilting the 30-gauge cannula in the paracentesis tract to allow aqueous to egress in a controlled fashion. After injection of the tPA and removal of the 30-gauge cannula, gentle pressure was applied to the paracentesis tract with a sterile cotton-tipped applicator. All paracentesis tracts were self-sealing. Three drops of a broad-spectrum topical antibiotic were instilled after each procedure. All eyes were reexamined from 15 minutes to 1 hour after the procedure to watch for any serious complications. All eyes were also examined 24 hours later to determine the success or failure of tPA administration.

Visual acuity and IOP were recorded before and 1 day after tPA use. The IOP measurements recorded immediately after tPA administration were not used because the effect of aqueous release during paracentesis could not be separated from the effect of tPA on the obstructed aqueous shunt. The indications for tPA use, surgical procedure initiating the blood and/or fibrin reaction, tPA dose, postoperative interval before tPA administration, post-tPA change of IOP, length of follow-up after tPA administration, complications associated with tPA use, vision on last follow-up examination, and success or failure of tPA administration were examined.

Because multiple tPA injections were required in some eyes, 2 criteria for success were developed to differentiate between a successful ocular outcome and a single successful tPA injection. For a single tPA injection to be successful, fibrin and/or blood must have resolved 24 hours after tPA administration. The development of complications after tPA use did not preclude the success of a single tPA injection. Furthermore, repeated tube occlusion caused by the development of new fibrin and/or blood did not negate the successful outcome of a single tPA injection. For a successful ocular outcome, tPA use must have prevented the need for additional glaucoma surgery to replace or revise an

occluded valved GDI. One or more injections of tPA may have been used to clear or prevent tube blockage by blood and/or fibrin to result in a successful ocular outcome. Data are given as mean \pm SD unless otherwise indicated.

RESULTS

Of 620 valved GDI procedures, 36 eyes were treated with 1 or more intracameral injections of tPA for complete or

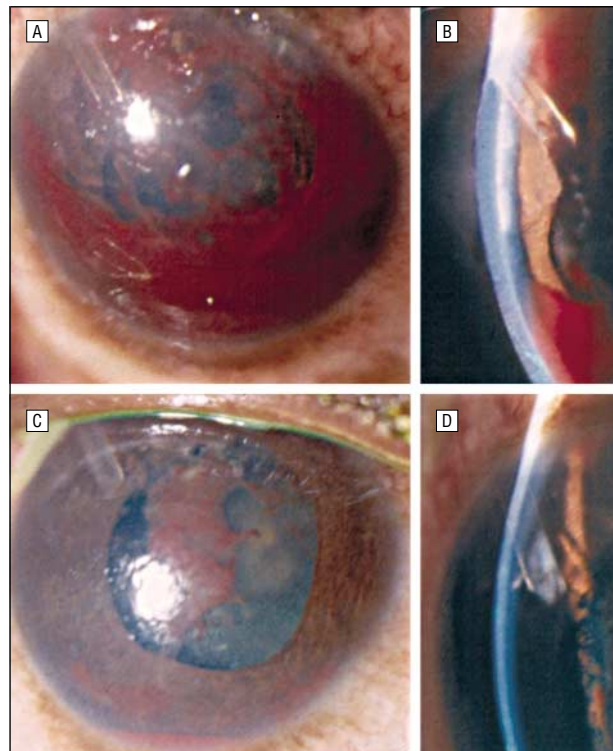


Figure 1. A and B, Krupin valve (Hood Laboratories, Pembroke, Mass) totally occluded by blood and fibrin on postoperative day 2 despite subconjunctival dexamethasone, aqueous suppressant therapy, and therapeutic aqueous release on postoperative day 1. C and D, Patent tube, 5 days later. Twenty-four hours after receiving 6 µg of intracameral tissue plasminogen activator, the intraocular pressure decreased from 45 mm Hg to 13 mm Hg.

imminent tube obstruction by fibrin and/or blood. A total of 55 tPA injections were identified and analyzed. Intracameral tPA was administered in 3 (4.6%) of 65 eyes with Krupin valves and in 33 (5.9%) of 555 eyes with Ahmed valves. The mean length of follow-up after tPA administration was 30 ± 22 months (range, 3-82 months).

All eyes with total or imminent tube occlusion were treated with 1 or more conservative measures prior to intracameral tPA administration. Thirty-one of 36 eyes received subconjunctival 100-mg injections of dexamethasone every 1 to 4 days (**Figures 1, 2, and 3**). Only 5 eyes did not receive additional subconjunctival dexamethasone, including 2 in children and 3 with blood clots. Sixteen of 36 eyes were treated with aqueous suppressant medications, including topical β adrenergic antagonists, topical α -2 adrenergic agonists, and/or carbonic anhydrase inhibitors (Figure 1). Aqueous suppressants did not alter the decision to use tPA in all 16 eyes, including 11 with total tube obstructions and 5 with imminent tube obstructions. Four patients with severe fibrinoid reactions were prescribed oral prednisone, 30 to 40 mg/d. Finally, 3 eyes had aqueous humor released externally through the paracentesis tract to lower the IOP for treatment of acute glaucoma due to total tube occlusion (Figure 1). In all 3 of these eyes, acute glaucoma recurred 24 hours later, at which time intracameral tPA was administered for persistent total tube obstruction.

Intracameral tPA was used after a variety of intraocular procedures. In 18 eyes (50%), tPA was used following valved GDI surgery alone. Thirteen eyes (36%) received tPA after valved GDI surgery, combined with either cataract extraction, scleral buckle, pars plana vitrectomy, or penetrating keratoplasty. Overall, tPA was used after valved GDI surgery performed alone or in combination with other procedures in 31 (5%) of 620 eyes. Five eyes (14%) received tPA following nonfistulizing intraocular procedures performed on eyes with pre-existing valved GDIs, including vitrectomy, cataract extraction, penetrating keratoplasty, and peripheral iridectomy.

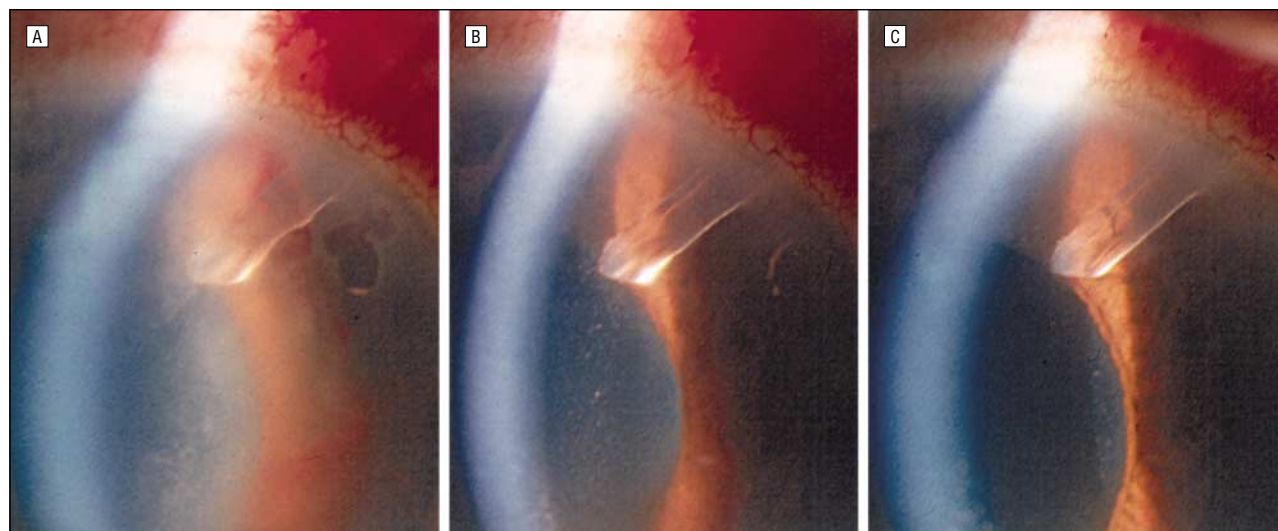


Figure 2. A, Ahmed valve (New World Medical Inc, Rancho Cucamonga, Calif) totally occluded by fibrin despite 2 failed tissue plasminogen activator (tPA) injections. B, Patent tube 1½ hours after the third intracameral administration of 10 µg of tPA. C, One day later, the tube remained patent and the intraocular pressure decreased from 40 mm Hg to 8 mm Hg. Use of tPA was complicated by mild hypotony and 15% hyphema, both of which resolved spontaneously.

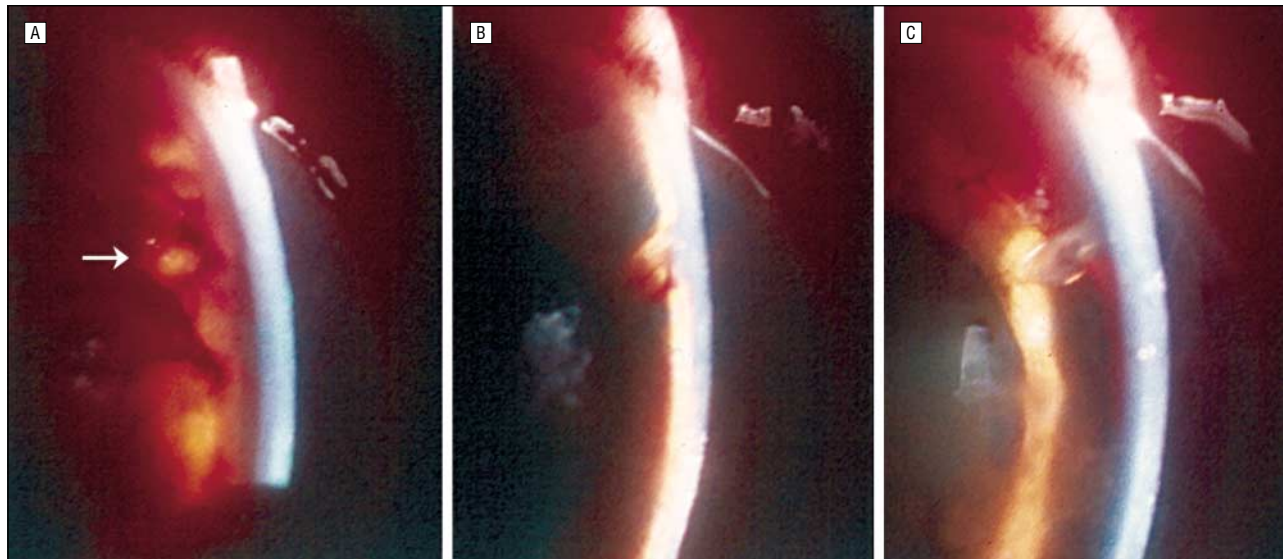


Figure 3. A, Ahmed valve (New World Medical Inc, Rancho Cucamonga, Calif) totally occluded and obscured (arrow) by a fibrin blood clot on postoperative day 2. B, One day after receiving 15 µg of intracameral tissue plasminogen activator, the tube patent, the anterior chamber flat, and the intraocular pressure (IOP) decreased from 44 mm Hg to 6 mm Hg. C, Patent tube, deep anterior chamber. The IOP was 14 mm Hg on postoperative day 4, 1 day after Healon (Pharmacia & Upjohn Co, Kalamazoo, Mich) reformation. The complicating 15% hyphema cleared spontaneously.

The mean interval from the surgical procedure that precipitated the blood and/or fibrin reaction to the first injection of tPA (n=36) was 4.3 ± 4.1 days (range, 1-18 days). The median interval to tPA administration was 2 days. The mean dose in a single tPA injection (n=55) was 9.8 ± 3.1 µg (range, 5-20 µg). For successful ocular outcomes (n=33), the mean total tPA dose was 15.5 ± 9.9 µg and the mean number of tPA injections was 1.6 ± 0.9 (range, 1-5).

Intracameral tPA was successful in clearing or preventing tube occlusion by fibrin and/or blood clots in 32 (88.9%) of 36 eyes. Of the 32 eyes with successful outcomes, 19 eyes (59.4%) received a single tPA injection (Figures 1 and 3) and 13 eyes (40.6%) received multiple tPA injections (Figure 2). Of the 4 cases that failed, the aqueous shunt implant was replaced in 3 eyes and revised in 1 eye.

Fourteen (38.9%) of the 36 eyes that received intracameral tPA required multiple administrations: 11 eyes twice, 2 eyes 3 times, and 1 eye 5 times. Eyes received multiple tPA administrations for either tube reocclusion after successful clot lysis or tPA failure. After successful initial tPA injections, the subsequent development of additional fibrin and/or blood reoccluded tubes in 9 (64.3%) of the 14 eyes. Intracameral tPA failed to break down the original fibrin and/or blood clot in 4 (28.6%) of the 14 eyes. One (7.1%) of the 14 eyes had failed tPA injections and a recurrent tube occlusion after successful clot lysis.

The analysis of tPA indications and IOP change was based on injections rather than eyes because 2 eyes required multiple injections for both total and imminent tube obstruction during their treatment. Intracameral tPA was used to treat total tube occlusion in 43 (78.2%) of 55 injections and partial or threatened tube occlusion in 12 (21.8%) of 55 injections. Tube lumens were completely occluded by fibrin in 18 cases (32.7%), blood in 6 cases (10.9%), and a mixture of blood and fibrin in 19 cases (34.5%). Of these 43 tPA injections, 31 successfully cleared the tube obstruction and restored aqueous outflow (Fig-

ures 1-3). Imminent tube occlusion occurred as the result of fibrin in 8 cases (14.5%) and a mixture of fibrin and blood in 4 cases (7.3%). All of these 12 tPA injections successfully prevented tube occlusion. Overall, intracameral tPA was successful after 43 (78.2%) of 55 injections.

The IOP decreased after 40 (72.7%) of the 55 injections and the mean total IOP reduction was 12.3 ± 15.9 mm Hg (range, -55 to 17 mm Hg). For the 43 successful tPA administrations, the IOP decreased after 35 injections (81.4%) and the mean IOP reduction was 15.3 ± 16.4 mm Hg (range, -55 to 6 mm Hg). A large IOP reduction, greater than 25 mm Hg, occurred after 15 (34.9%) of 43 successful tPA injections (Figures 1-3). For the 12 failed tPA administrations, the mean IOP reduction was 1.3 ± 7.2 mm Hg (range, -10 to 17 mm Hg). For the 43 successful tPA administrations, the mean total IOP reduction was 21.2 ± 15.6 mm Hg for 31 injections treating total tube occlusion and 0.1 ± 3.3 mm Hg for 12 injections treating imminent tube occlusion. For the 31 successful tPA administrations treating total tube occlusion, 13 injections were given in eyes receiving aqueous suppressant medications and 18 injections were given in eyes not receiving aqueous suppressant medications; the mean IOP reduction was 18.7 ± 17.9 mm Hg and 23.0 ± 14.0 mm Hg, respectively.

One day after the last tPA injection, the visual acuity was the same or improved from preadministration levels in 35 (97.2%) of 36 eyes and worse in 1 eye complicated by a 70% hyphema. At the most recent follow-up (mean, 30.1 months), the visual acuity was equal to or better than pre-tPA levels in 27 (75%) of 36 eyes and was improved by 5 or more lines of visual acuity in 9 (25%) of 36 eyes.

At the most recent follow-up, the visual acuity had deteriorated in 9 (25%) of 36 eyes. One eye with a traumatic angle recession glaucoma and prior scleral buckle for retinal detachment repair developed a mature cataract 3 years later. One pseudophakic eye with an underlying chronic iritis and a failed trabeculectomy developed bullous keratopathy 4 years after receiving 6 µg of

intracameral tPA. The other 7 eyes (19.4%) progressed to no light perception as the result of chronic retinal detachment (1 eye) and progressive end-stage proliferative retinopathy, complicating both diabetes mellitus (5 eyes) and a central retinal vein occlusion (1 eye). All 6 eyes that lost vision from complications of severe proliferative retinopathy were seen emergently by the glaucoma service and found to have acute neovascular glaucoma and poor visual function: 20/400 (1 eye), counting fingers (2 eyes), hand motions (2 eyes), and light perception (1 eye). Sight-ending complications from severe proliferative retinopathy included cyclitic membranes, tractional retinal detachment, neovascular glaucoma, and phthisis. These sight-ending complications occurred from 2 to 8 months after tPA administration in 5 eyes and from 3 to 4 years after tPA administration in 2 eyes.

Complications occurred after 12 (21.8%) of 55 intracameral tPA administrations. In these 12 cases, hyphemas, hypotony, and anterior chamber flattening were the only complications identified and occurred in varying degrees either individually or in combination. Eleven of 12 cases occurred after tPA injections for treatment of complete tube obstruction and 1 of 12 cases occurred after tPA injection to prevent tube occlusion. Hypotony alone was mild and transient after 4 injections and profound with anterior chamber flattening after 3 injections. Hyphema alone occurred after 2 injections. One of these hyphemas was mild, creating a 10% inferior layer and cleared without further intervention during the next few days. The other hyphema was severe and filled 70% of the anterior chamber. The new blood reoccluded the visible tube shaft in the anterior chamber and required surgical evacuation with aqueous shunt revision. Combined mild hypotony and mild hyphema occurred after 1 injection and resolved spontaneously (Figure 2). Combined severe hypotony and mild hyphema occurred after 2 injections (Figure 3). All cases of severe hypotony were successfully managed at the office slitlamp microscope by refilling the anterior chamber with Healon (Pharmacia & Upjohn Co, Kalamazoo, Mich) through the paracentesis tract. Overall, severe complications occurred after 6 (10.9%) of 55 tPA injections. All 12 complications occurred when tPA was injected less than 9 days postoperatively. The 6 severe complications occurred when tPA was injected less than 5 days postoperatively.

COMMENT

The formation of blood or fibrin clots in the anterior chamber after glaucoma fistulizing surgery is a well-recognized complication that compromises aqueous outflow and causes filtration failure. Recombinant tPA¹ is a clot-specific fibrinolytic enzyme that has been effectively used to lyse blood and/or fibrin clots after glaucoma surgery.⁸⁻¹⁹

To our knowledge, intracameral tPA use after GDI surgery has been previously reported for only 7 nonvalved devices,⁸⁻¹¹ and only 1 of these provided follow-up information longer than 6 months. Our retrospective analysis of intracameral tPA use in 36 eyes represents the largest experience to date of tPA use after GDI surgery and the only case series of tPA use in valved implants. Furthermore, with a mean follow-up of 2¹/₂ years, this

report provides both short-term and long-term data on the efficacy and complications of tPA use in this setting.

Five percent of 620 valved GDIs performed alone or in combination with other procedures were treated with intracameral tPA for blood and/or fibrin clots occluding or threatening to occlude the tube lumen. On our glaucoma service, the 5% incidence for this complication represents the second most common problem in the early postoperative period after valved GDI surgery. Complications of profound hypotony, including anterior chamber flattening and progressive choroidal effusions, are the most common problems following trabeculectomy and drainage implant surgery. Well-accepted practice patterns for follow-up after glaucoma surgery require frequent monitoring of the IOP and anterior chamber depth during the first postoperative week to identify this complication. This time frame is also the most critical period and carries the greatest risk for tube occlusion after valved GDI surgery. In our series, the mean postoperative time interval for tPA use was 4 days and the median postoperative time interval for tPA use was 2 days. As such, it is important to closely monitor tube lumen patency and the location of anterior chamber blood and fibrin clots during the first postoperative week.

In our series, intracameral tPA restored patency or prevented aqueous shunt tube occlusion in 32 (89%) of 36 eyes and after 12 (78%) of 55 injections. For the 31 successful tPA injections in eyes with total tube occlusion, the mean IOP reduction was 21 mm Hg. This marked IOP lowering substantiates the efficacy of intracameral tPA in restoring aqueous outflow and drainage implant function. In these eyes, tPA use prevented further optic nerve damage from severely elevated IOP and averted reoperation for IOP control. After 12 successful tPA injections for partial or threatened tube obstructions, the IOP was not significantly changed. This finding in eyes with imminent tube occlusion is consistent with the free flow of aqueous prior to tPA injection and an unchanged rate of aqueous humor production following tPA injection. Intracameral tPA failed to lyse blood and/or fibrin occluding tube lumens in only 4 cases. These eyes with uncontrolled acute glaucoma required immediate reoperation to revise or replace the obstructed drainage implants.

It is difficult to compare the success in our series with past case reports⁸⁻¹¹ because of differing drainage devices and differing criteria for defining a successful outcome. All 7 previously reported cases involved nonvalved GDIs, including Baerveldt (Iovision Inc, Irvine, Calif), Molteno (IOP Inc, Costa Mesa, Calif), and Schocket (Storz, St Louis, Mo) devices. Glaucoma drainage implants without valves are purposefully modified with temporary ligatures and/or intubation sutures to close or restrict the tube lumen and limit aqueous outflow for the first 2 to 4 weeks postoperatively. In a report of a double-plate Molteno implant,¹⁰ the 5-0 nylon intubation suture was partially retracted on postoperative day 1 for treatment of a severely elevated IOP of 53 mm Hg. On postoperative day 2, the IOP decreased to 19 mm Hg and the tube lumen became obstructed by a fibrin-blood clot. In another report,⁹ a Baerveldt tube became occluded by a fibrin clot on postoperative day 12, 4 days after removing the 4-0 nylon intubation suture. Nonvalved, ligated GDIs without venting slits should not become occluded by fibrin and/or blood in the early post-

operative period. The greatest risk for functional tube occlusion with nonvalved devices occurs soon after the tube ligature has been released, typically several weeks after surgery. In 5 of the 7 nonvalved case reports, tPA successfully cleared the tube obstruction and the IOP was acceptably controlled at the most recent follow-up without repeated glaucoma surgery or devastating complications. Our large case series confirms that intracameral tPA is a useful therapeutic adjunct to clear blood and/or fibrin clots from occluded drainage implants and to prevent the need for additional glaucoma surgery.

There are currently no established guidelines for the treatment of fibrin and/or blood clots that occlude or threaten to occlude GDIs. To complicate matters, the use of tPA with a valved implant in the early postoperative period prior to plate encapsulation is very different than its use with a nonvalved device after ligature release in the presence of a well-encapsulated plate. The variable use of conservative treatment measures, including high-dose topical and periocular steroids, aqueous suppressants, oral prednisone, and therapeutic aqueous release, did not alter the decision to use intracameral tPA for the treatment of total and imminent tube occlusion in our series. For valved drainage implants, aqueous suppressant therapy is controversial since it may obscure tPA's effect in restoring outflow patency and may cause profound hypotony once tPA has cleared the occluded drainage implant. Lundy et al⁸ used intracameral tPA in the early period after glaucoma surgery when there was evidence of decreased bleb function in the presence of significant anterior chamber or subconjunctival blood or fibrin, but provided no criteria for filtration failure, elevated IOP, or aqueous suppressant therapy. In our review, 22% of intracameral tPA injections were performed in eyes with normal IOP and imminent tube occlusion. Since trabecular outflow is usually severely compromised, clots located within 2 mm of the tube ostium will follow the only functional path of aqueous flow and migrate toward or be drawn into the tube shunt lumen. The authors believe that high-risk situations exist for imminent tube occlusion in which prophylactic intracameral tPA injection is warranted. In our series, intracameral tPA use for this indication was 100% successful at preventing complete drainage implant obstruction and its sequelae.

Tissue plasminogen activator has many useful properties for clearing obstructed aqueous shunt tubes: it has a short biologic half-life, rapidly dissolves clots within minutes to hours, and lowers a severely elevated IOP in a timely manner. Tissue plasminogen activator acts distant from the site of administration and restores aqueous outflow by breaking down the clot in the anterior chamber, tube opening, tube lumen, and tube exit on the implant plate. Although tPA can diffuse throughout the eye and GDI, it remains locally active, with minimal or no risk of systemic bleeding complications. Once tPA is bound to fibrin, fibrinolytic activity may be prolonged more than 7 hours.² As such, tPA is effective in breaking down extensive blood and/or fibrin clots in the tube, valve mechanism, implant plate exit, and subconjunctival space. Finally, compared with glaucoma reoperation, tPA is much less invasive and is less likely to incite intraocular inflammation or fibrin formation.

In our series, varying amounts of tPA were used based on the physician's assessment of the severity of the fibrin-

ous and/or hemorrhagic anterior chamber reaction. Previous investigators showed that low doses of tPA, ie, 3 µg to 12.5 µg, were effective in clearing postoperative intraocular fibrin and had less risk of complications.⁴ Our high success rate using a mean dose of 9.8 µg supports prior recommendations for using low-dose tPA to lyse intraocular blood and fibrin. However, the actual amount of tPA delivered into the anterior chamber could not be quantified because a variable amount escaped through the paracentesis tract during or immediately following the injection. Therefore, optimal dosing cannot be determined.

For the 32 eyes with successful outcomes, 19 (59%) received a single tPA injection and 13 (41%) received multiple tPA injections. When managing occluded tube shunts, more than 1 intracameral tPA injection should be anticipated. The most common cause for multiple tPA injections was the development of new fibrin or blood after successful initial tPA administrations. Recurrent tube occlusion occurred in 19 (28%) of 32 eyes. Thus, postoperative bleeding and fibrin may recur even after successful clearing by intracameral tPA.

Neovascular glaucoma (19 eyes [53%]) and inflammatory glaucoma (6 eyes [17%]) represented the 2 most common diagnoses in our series of 36 eyes. Of the 7 prior case reports of tPA use for occluded tube shunts,⁸⁻¹¹ 4 patients had neovascular glaucoma and 1 patient had inflammatory glaucoma. Patients with neovascular glaucoma are predisposed to postoperative bleeding and fibrin formation due to the presence of abnormal iris vessels and an altered blood-aqueous barrier. Patients with inflammatory glaucoma are more prone to postoperative fibrin formation alone due to an altered blood-aqueous barrier. This may explain why fibrin (49 [89%]) was a more common indication for tPA use compared with blood (29 [53%] of 55 injections) in our series. Since eyes with neovascular and inflammatory glaucoma represented 22 (70%) of 36 eyes of cases in which tPA was used, treatment to mitigate postoperative fibrin formation, ie, high-dose systemic or periocular steroids, should be considered at the time of surgery or in the early postoperative period to prevent this complication.

Intracameral tPA seemed to have no deleterious short-term or long-term effects on the visual acuity in our series. One day after tPA administration, the visual acuity was the same or improved in 35 (97%) of 36 eyes. At 2½ years, the visual acuity was the same or better than the pre-tPA level in 27 (75%) of 36 eyes and had deteriorated in 9 (25%) eyes. In the eyes that deteriorated, loss of light perception occurred months to years after tPA use and was the result of progressive, severe underlying ocular disease, ie, chronic retinal detachment and end-stage proliferative retinopathy. Since the duration of tPA's biological activity is only minutes to hours, the loss of sight was unrelated to tPA use and represented the natural course of uncontrolled end-stage disease.

Hyphema, hypotony, and anterior chamber flattening were the only complications identified and were severe after 6 (11%) of 55 tPA administrations. Persistent profound hypotony with flat anterior chambers was the most common severe complication and was successfully managed in all cases by injecting Healon into the anterior chamber through the paracentesis tract at the

slitlamp. Profound hypotony and anterior chamber flattening due to excessive outflow is known to be the most common complication after aqueous shunt surgery; as such, it is impossible to know whether tPA use was the direct or indirect cause of profound hypotony in our cases. In contrast, bleeding is the most common complication of tPA used systemically¹ for the treatment of ischemic stroke or myocardial infarction and intracamerally^{8,12} after glaucoma fistulizing surgery. In our series, 1 eye developed a severe 70% hyphema after tPA use and required surgical evacuation with aqueous tube shunt revision. Before tPA administration, a localized blood clot obstructed this tube and severely elevated the IOP. Had tPA not been used, a similar reoperation would have been required, albeit to a lesser degree. Except in this single case, the development of both hypotony and hyphema did not preclude tPA success and did not diminish the efficacy of tPA use. By comparison, a conventional surgical procedure to remove a blood or fibrin clot obstructing a tube lumen would be more time consuming and invasive.

Intuitively, intracameral tPA injections given closer to the day of surgery would be more likely to result in both hypotony and hyphema. The risk of causing hypotony by enhancing flow through the tube shunt is probably greater within the first 2 weeks after surgery, prior to fibrous encapsulation of the implant plate. Additionally, the risk of recurrent hemorrhage following clot lysis probably diminishes with increasing time from the initial surgery. Our data support a correlation between the interval from the surgical procedure to the administration of tPA and the incidence of hyphema and hypotony. All complications occurred when intracameral tPA was used less than 9 days postoperatively and all severe complications occurred when intracameral tPA was used less than 5 days postoperatively.

In our series, there were no other serious complications directly associated with intracameral tPA use. In particular, there was no systemic bleeding or other adverse systemic effects. There were also no other severe intraocular or periocular bleeding complications, including vitreous hemorrhage, suprachoroidal hemorrhage, retrolbulbar hemorrhage, and subconjunctival hemorrhage around the implant plate. Tube migration after tPA administration occurred in 2 of 4 cases reported by Lundy et al⁸ but was not observed in our patients. Rehfeldt and Hoh¹² reported a 3.2% incidence of transient corneal edema after 185 intracameral injections of tPA following glaucoma fistulizing surgery. However, a laboratory model using human donor corneas²⁰ detected no adverse effect of 25 µg of intracameral tPA on the corneal endothelium. In our series, 1 eye developed bullous keratopathy 4 years after receiving 6 µg of intracameral tPA. In view of multiple underlying risk factors for corneal decompensation, including a chronic iritis and 3 intraocular surgeries, we believe it highly unlikely that tPA was causally related to this long-term complication.

Our study is limited by its retrospective design, non-randomization of patients, and variability of tPA doses. Also, threatened tube occlusions could have been treated more intensely with high-dose systemic and periocular steroids before resorting to intracameral tPA administration. A prospective, randomized clinical study with

standard administration criteria for high- and low-dose tPA injections would help establish guidelines for tPA use, identify the optimal tPA dose, and define the risk-benefit ratio associated with high- vs low-dose tPA use.

In a retrospective review of 620 valved glaucoma drainage implants, intracameral tPA successfully cleared or prevented tube occlusion by fibrin and/or blood clots in 32 of 36 eyes. This series represents the largest experience to date of intracameral tPA use after GDI surgery and the only description of tPA use in valved devices. Significant short-term complications occurred after 11% of injections, including severe hyphema, profound hypotony, and anterior chamber flattening. No long-term complications were associated with intracameral tPA use after a mean follow-up of 2½ years.

Submitted for publication January 17, 2002; final revision received May 20, 2002; accepted June 13, 2002.

This research was supported by a Career Development Award from Research to Prevent Blindness, New York, NY (Dr Kaufman).

We have no commercial or proprietary interest in Activase or Genentech Inc.

Corresponding author and reprints: Alan H. Zalta, MD, University Medical Arts Bldg, 222 Piedmont Ave, Suite 1700, Cincinnati, OH 45219 (e-mail: zaltaah@uc.edu).

REFERENCES

1. Activase® [package insert]. Revised. San Francisco, Calif: Genentech Inc; 1999.
2. Eisenberg PR, Sherman IA, Tiefenbrunn AJ, Ludbrook PA, Sobel BE, Jaffe AS. Sustained fibrinolysis after administration of t-PA despite its short half-life in the circulation. *Thromb Haemost.* 1987;57:35-40.
3. Johnson R, Olsen K, Hernandez E. Tissue plasminogen activator treatment of postoperative intraocular fibrin. *Ophthalmology.* 1988;95:592-596.
4. Jaffe GJ, Abrams GW, Williams GA, Han DP. Tissue plasminogen activator for postvitrectomy fibrin formation. *Ophthalmology.* 1990;97:184-189.
5. Williams DF, Bennett SR, Abrams GW, et al. Low dose intraocular tissue plasminogen activator for treatment of postvitrectomy fibrin formation. *Am J Ophthalmol.* 1990;109:606-660.
6. Snyder RW, Sherman MD, Allinson RW. Intracameral tissue plasminogen activator for treatment of excessive fibrin response after penetrating keratoplasty. *Am J Ophthalmol.* 1990;109:483-484.
7. Lesser GR, Osher RH, Whipple D, Abrams GW, Cionni RJ. Treatment of anterior chamber fibrin following cataract surgery with tissue plasminogen activator. *J Cataract Refract Surg.* 1993;19:301-305.
8. Lundy DC, Sidoti P, Winarko T, Minckler D, Heuer DK. Intracameral tissue plasminogen activator after glaucoma surgery. *Ophthalmology.* 1996;103:274-282.
9. Richards DW. Intracameral tissue plasminogen activator to treat blocked glaucoma implants. *Ophthalmic Surg.* 1993;24:854-855.
10. Pastor SA, Schumann SP, Starita RJ, Fellman RL. Intracameral tissue plasminogen activator: management of a fibrin clot occluding a Molteno tube. *Ophthalmic Surg.* 1993;24:853-854.
11. Sidoti PA, Morinelli EN, Heuer DK, et al. Tissue plasminogen activator and glaucoma drainage implants. *J Glaucoma.* 1995;4:258-262.
12. Rehfeldt K, Hoh H. Therapeutic and prophylactic application of tPA into the anterior chamber of the eye. *Ophthalmology.* 1999;96:587-593.
13. Tripathi RC, Tripathi BJ, Park JK, et al. Intracameral tissue plasminogen activator for resolution of fibrin clots after glaucoma filtering procedures. *Am J Ophthalmol.* 1991;111:247-248.
14. Burnstein Y, Higginbotham EJ. Report of tissue plasminogen activator injection in a very low dose for treatment of posttrabeculectomy fibrin. *J Glaucoma.* 1998;7:361.
15. Azuara-Blanco A, Wilson RP. Intraocular and extraocular bleeding after intracameral injection of tissue plasminogen activator. *Br J Ophthalmol.* 1998;82:1345-1346.
16. Foo K, Workman D. TPA for sclerostomy occlusion. *Aust N Z J Ophthalmol.* 1996;24:391-392.
17. Lee PF, Myers KS, Hsieh MM, Wood EF, Hotaling DM. Treatment of failing glaucoma filtering cystic blebs with tissue plasminogen activator. *J Ocul Pharmacol Ther.* 1995;11:227-232.
18. Olivier MM, Kupin TH, McDermott ML, Shin DH. Intracameral tissue plasminogen activator in neovascular glaucoma. *Arch Ophthalmol.* 1993;111:586.
19. Smith MF, Doyle JW. Use of tissue plasminogen activator to revive blebs following intraocular surgery. *Arch Ophthalmol.* 2001;119:809-812.
20. McDermott ML, Edelhauser HF, Hyndiuk RA, Koenig SB. Tissue plasminogen activator and the corneal endothelium. *Am J Ophthalmol.* 1989;108:91-92.