

Lawrence Berkeley National Laboratory

LBL Publications

Title

Clinical Experience with the Multiplane Tomographic Scanner

Permalink

<https://escholarship.org/uc/item/54p703vd>

Authors

Volpe, Joseph A

McRae, James

Anger, Hal O

Publication Date

2023-09-06

**CLINICAL EXPERIENCE WITH THE
MULTIPLANE TOMOGRAPHIC SCANNER**

Joseph A. Volpe,* James McRae,† and Hal O. Anger

*Donner Laboratory of Medical Physics and Biophysics,
The Lawrence Radiation Laboratory, University of California, Berkeley, California,
and Letterman General Hospital, San Francisco, California*

DISCLAIMER

This document was prepared as an account of work sponsored by the United States Government. While this document is believed to contain correct information, neither the United States Government nor any agency thereof, nor the Regents of the University of California, nor any of their employees, makes any warranty, express or implied, or assumes any legal responsibility for the accuracy, completeness, or usefulness of any information, apparatus, product, or process disclosed, or represents that its use would not infringe privately owned rights. Reference herein to any specific commercial product, process, or service by its trade name, trademark, manufacturer, or otherwise, does not necessarily constitute or imply its endorsement, recommendation, or favoring by the United States Government or any agency thereof, or the Regents of the University of California. The views and opinions of authors expressed herein do not necessarily state or reflect those of the United States Government or any agency thereof or the Regents of the University of California.

CLINICAL EXPERIENCE WITH THE MULTIPLANE TOMOGRAPHIC SCANNER

Joseph A. Volpe,* James McRae,† and Hal O. Anger

*Donner Laboratory of Medical Physics and Biophysics,
The Lawrence Radiation Laboratory, University of California, Berkeley, California,
and Letterman General Hospital, San Francisco, California*

Conventional radioisotope scanners produce a single picture with sharpest resolution at the geometric focal plane of the collimator. Activity at other depths is blurred. For 8-in.-crystal scanners the decrease in resolution with distance from the geometric focal plane is considerable and results in poor resolution throughout most of the volume of a thick organ.

The multiplane tomographic scanner overcomes this limitation by simultaneously producing six picture readouts from one scan, each readout being sharply focused on a different plane in the subject. When one scans thick organs, the readout planes are normally focused at 1, 2, 3, 4, 5, and 6 in. from the collimator. When one scans smaller organs such as the kidney or pancreas, the readout planes may be moved closer together. Typically the first readout plane is then 2¼ in. from the collimator, the sixth is at 4¾ in., and the remaining planes are spaced between at ½-in. intervals. The principle of operation of the tomographic scanner has been described in detail elsewhere (1).

METHODS, MATERIALS, AND RESULTS

The multiplane tomographic scanner has been in clinical use since June 1968. A total of 161 patients have been studied through March 1970. All of the scans have been reviewed, and the results of these studies are presented in this report.

The pertinent technical data including scanning parameters and radiopharmaceuticals used are presented in Table 1. A tomoscan was done initially, and the total number of counts accumulated was recorded. Following this a scintiphoto with an approximately equal number of counts was obtained. In this manner the information densities of the tomoscan and scintiphoto were considered to be roughly comparable, and a valid comparison could be made. Comparison studies between the tomoscanner and the scintillation camera were done in all cases, and in some cases, rectilinear scans were done on the same patient with either a multicrystal scanner (Picker Dynapix) or a conventional 3-in.-crystal scanner (Picker Magnascanner). The scintillation camera used for these studies was constructed at Donner Laboratory and uses an 11½-in.-diam scintillator with 19 phototubes (2). Tomographic scans and scintillation camera pictures will be referred to as tomoscans and scintiphotos, respectively.

Liver. Of 52 liver patients studied, abnormalities were found in 36. The scintiphotos and tomoscans

Received May 28, 1970; revision accepted Oct. 15, 1970.

For reprints contact: Joseph A. Volpe, Box 1283, William Beaumont General Hospital, El Paso, Tex. 79920.

* Present address: See above.

† Present address: Dept. of Medicine, University of Sydney, Sydney, Australia.

TABLE 1. TECHNICAL DATA ON 161 PATIENTS STUDIED WITH MULTIPLANE TOMOGRAPHIC SCANNER

Organ	Radiocompound	Dose	Delay* (min)	Scan line spacing (in.)	Scan speed (cm/min)	Space between tomographic planes (in.)	Duration of scan per view (min)
Liver	^{99m} Tc-sulfur colloid	2 mCi	5	1/8	700	1	10
Kidney	²⁰³ Hg-chlormerodrin	100 µCi	60	1/8	300	½-¾	15
Pancreas	⁷⁵ Se-selenomethionine	200 µCi	30	1/16	300	1	30
Lung	^{99m} Tc-iron hydroxide	2 mCi	5	1/8	500	1	15
Brain	^{99m} Tc-pertechnetate	10 mCi	5	1/8	700	1	5

* Time between administration of the isotopes and start of scan.

TABLE 2. COMPARISON OF LIVER TOMOSCAN WITH SCINTIPHOTOS IN 52 PATIENTS

Referring diagnosis	Tomoscan and scintiphoto of equal clinical value		Tomoscan superior to scintiphoto		Total
	Normal study	Abnormal study	Normal study	Abnormal study	
Metastatic carcinoma	6	7	0	8	21
Hepatosplenomegaly	6	5	0	0	11
Cirrhosis	1	7	0	0	8
Normal liver	3	0	0	0	3
Liver abscess	0	3	0	0	3
Hemochromatosis	0	2	0	0	2
Subphrenic abscess	0	1	0	0	1
Hepatoma	0	0	0	1	1
Splenomegaly	0	2	0	0	2
Total	16	27	0	9	52

were judged to be comparable in 43 patients, and the tomoscans were superior in nine patients (Table 2). These nine patients had metastatic or primary cancer of the liver. In one of the nine cases, there were multiple discrete focal lesions on the tomoscan which appeared in the scintiphoto as irregular labeling of the liver (Fig. 1). The scintiphoto failed to identify the abnormalities as discrete lesions. In four patients focal lesions were seen on both the scintiphotos and tomoscans, but on the tomoscans diffuse irregular labeling of other portions of the liver suggested additional lesions. In four other cases, the

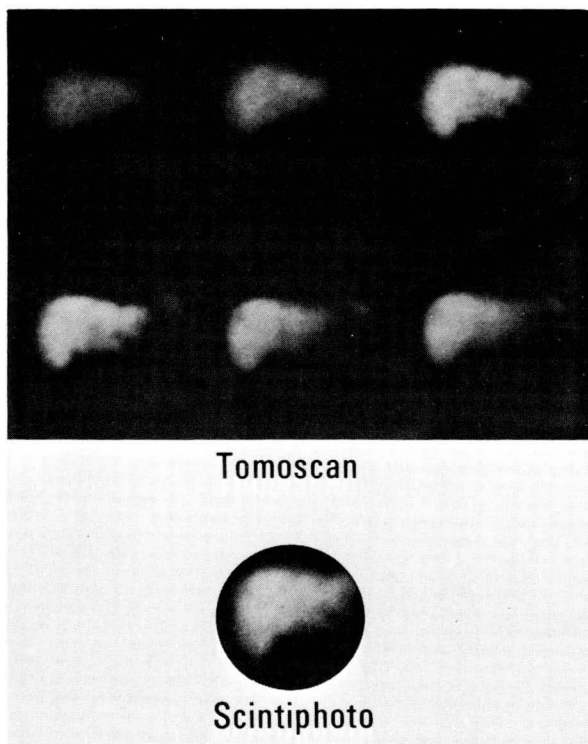


FIG. 1. Tomoscan shows multiple focal defects in liver with metastatic carcinoma. On scintiphoto, one focal defect is suggested but pattern is one of irregular uptake of colloid.

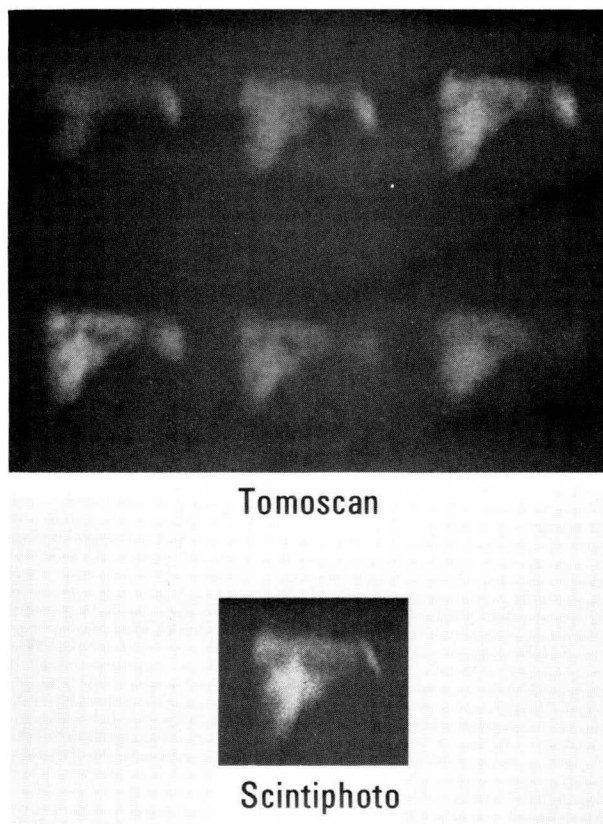


FIG. 2. Tomoscan of liver with metastatic carcinoma shows more lesions and better resolution than scintiphoto.

scintiphotos failed to resolve all of the focal defects resolved by the tomoscans (Fig. 2). In no instance did the tomoscanner fail to detect a lesion seen with the scintillation camera. Hepatomegaly and large focal defects in patients with liver abscess, tumor, subphrenic abscess, and spleen cyst were detected equally well with tomoscans and scintiphotos.

Comparative Dynapix scans were done in seven of the liver patients and were inferior to the tomoscans in two patients, both of whom had multiple

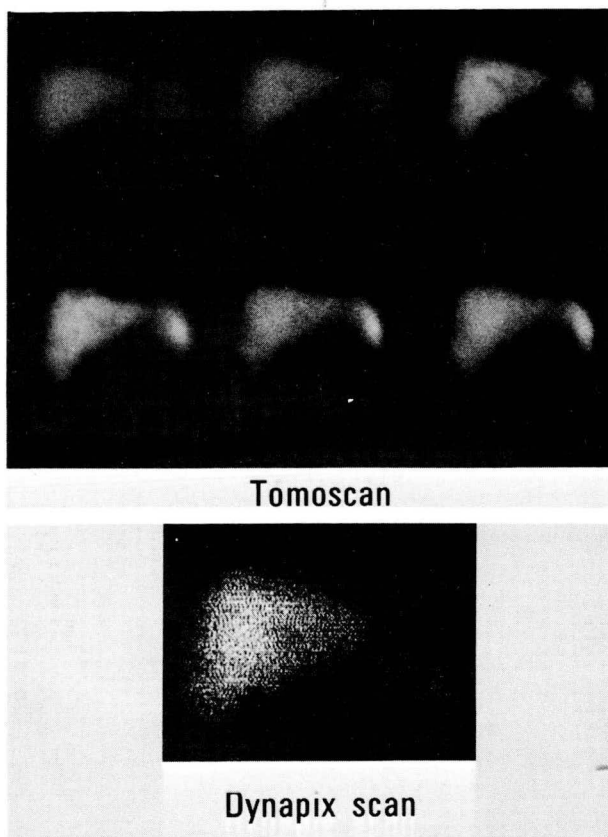


FIG. 3. Tomoscan of liver shows more lesions and better resolution than Dynapix scan.

metastases. In these two cases, the Dynapix scan failed to detect as many focal defects and did not resolve lesions as well as the tomoscan (Fig. 3). Large focal defects and cirrhosis were detected well with the Dynapix scan.

When taking anterior views of the liver, the tomoscanner, scintillation camera, and rectilinear scanners may all fail to detect posterior lesions which are clearly visible on a posterior view (3). Anterior tomoscans failed to detect posterior lesions in three cases. Even though the tomoscanner provides good

geometric resolution at depths as great as 6 in., lesions can still be missed because of poor counting-rate contrast caused by overlying active tissue. Therefore, posterior views of the liver are still necessary when using a tomoscanner.

Kidney. Of 25 kidney patients studied, abnormalities were found in 12. The tomoscans were comparable to the scintiphotos in 17 patients, and the tomoscans were superior in eight patients (Table 3). In no instance did a tomoscan fail to detect a lesion which was demonstrable on the scintiphoto. In patients with polycystic kidneys, the tomoscans re-

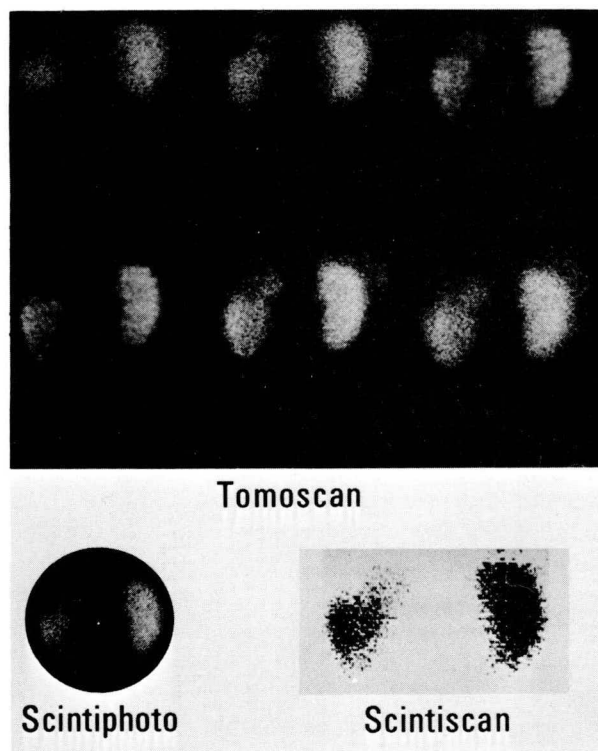


FIG. 4. Tomoscan indicates that abscess involves superior-lateral portion of left kidney. Scintiphoto does not resolve lesion as well as tomoscan. Rectilinear scan suggests mass lesion of entire superior pole.

TABLE 3. COMPARISON OF TOMOSCAN WITH SCINTIPHOTOS IN 25 PATIENTS

Referring diagnosis	Tomoscan and scintiphoto of equal clinical value		Tomoscan superior to scintiphoto		Total
	Normal study	Abnormal study	Normal study	Abnormal study	
Polycythemia	9	1	0	0	10
Polycystic kidneys	0	1	0	4	5
Renal mass	2	1	0	2	5
Hypertension	1	1	0	0	2
Hematuria	1	0	0	0	1
Renal infarct	0	0	0	1	1
Renal tuberculosis	0	0	0	1	1
Total	13	4	0	8	25

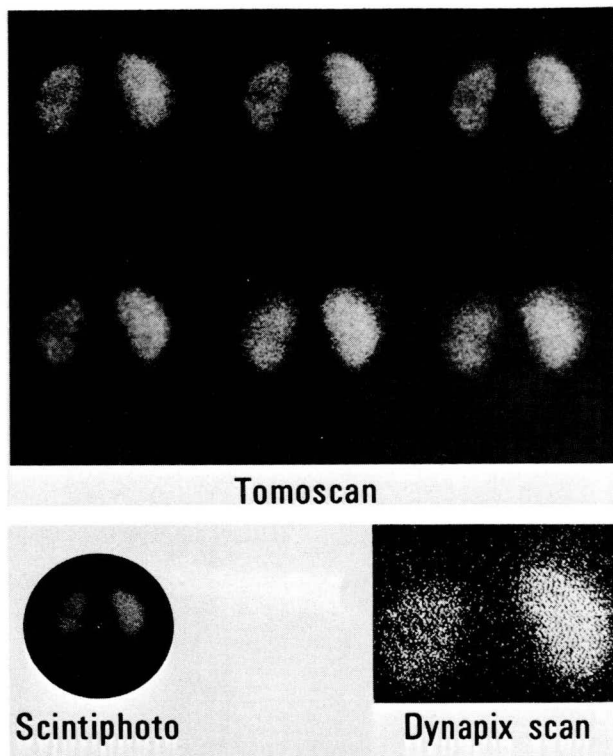


FIG. 5. Cyst is discretely resolved by tomoscan and is less distinct on scintiphoto and Dynapix scan of kidneys.

solved the cysts more discretely, and in three instances they showed lesions not detected on the scintiphotos. In a patient with renal tuberculosis, a superior pole abscess was more sharply outlined on the tomoscan (Fig. 4). In another patient with recurrent urinary tract infections and left flank pain the scintiphoto showed an ill-defined area of decreased uptake in the mid-left kidney whereas a discrete lesion was demonstrable on the tomoscan (Fig. 5). A retrograde urogram indicated this was a calyceal cyst. In a young man with multiple arterial emboli from subacute bacterial endocarditis, resultant infarcts of the left kidney were more clearly outlined by the tomoscan than by the scintiphoto, and an additional infarct in the upper pole of the right kidney was suggested by the tomoscan (Fig. 6). Defects in this patient were poorly resolved by the Dynapix scan.

Rectilinear scans were done in 11 of the 25 patients and were inferior to the tomoscan in eight. In three of these eight cases, solitary lesions were not as sharply outlined (Figs. 4 and 5) and in four patients with polycystic kidney disease the cysts were poorly shown by the rectilinear scan. In two of the latter cases one kidney was more anteriorly situated and thus out of the focal plane of the collimator, whereas in one case the cysts were not detected even though the kidney was in focus.

The kidney is a relatively small organ and lesions involving it are often small. Because of its good resolution the tomoscanner should provide additional useful information when compared to scintiphotos of the same organ, and in fact it did in eight of 25 cases. In four cases it detected lesions missed by the scintillation camera, and in four cases, lesions poorly defined by the scintiphotos were sharply outlined by the tomoscan. The importance of sharper resolution was exemplified by the patient with the calyceal cyst (Fig. 5). The scintiphotos did not show a discrete lesion whereas the tomoscan clearly resolved the potential surgical lesion.

When one scans kidneys using ^{203}Hg -chlormerodrin, the number of counts recorded by a conventional 3-in. scanner in a scan of reasonable duration is relatively small. The tomoscanner's higher sensitivity was probably responsible for the superior results in eight of the 11 patients on whom rectilinear scans were done.

Brain. Of 45 brain studies, eight were abnormal including three primary tumors, three metastatic tumors, one intracerebral cyst, and one focal defect of uncertain etiology. The lesions were well seen on tomoscans and scintiphotos in all instances, but the

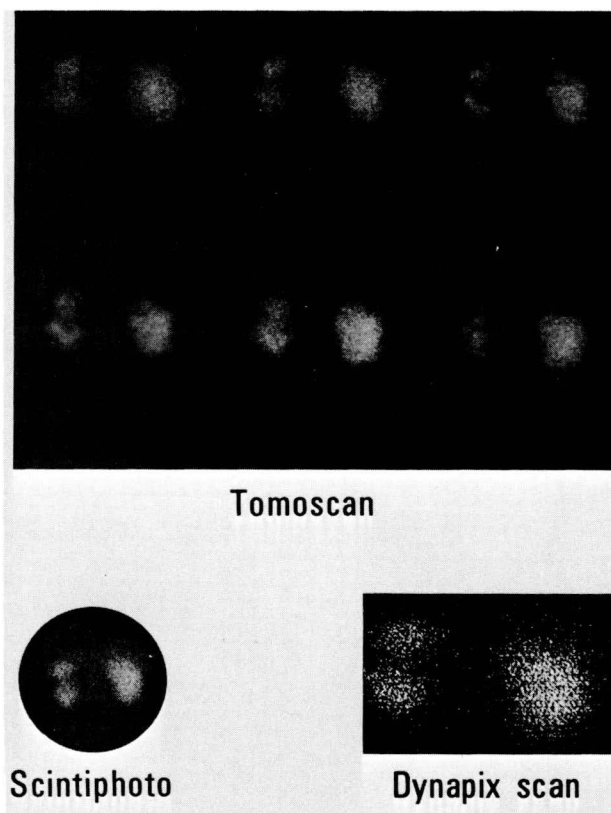


FIG. 6. Infarcts of left kidney are more clearly resolved by tomoscan than by scintiphoto. Additional infarct of upper pole of right kidney is suggested on tomoscan. Infarcts are poorly resolved by Dynapix scan.

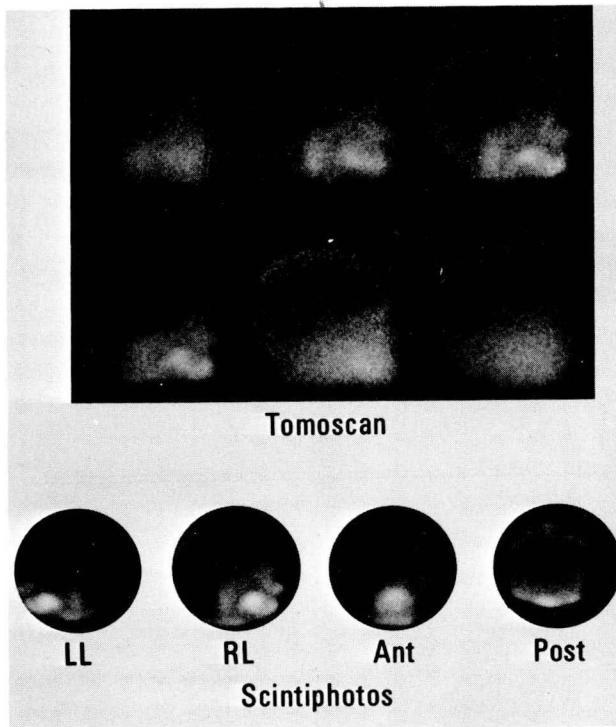


FIG. 7. On scintiphoto focal defect is obvious on right lateral view only. Depth of lesion is uncertain. Tomoscan proves that defect is within brain as it is most sharply focused on third plane, 2.75 in. from surface.

tomoscan showed the normal cross-sectional anatomy more clearly. Focal lesions in the brain could thus be more accurately localized.

For example, in one patient, the scintiphotos showed a focal area of increased concentration on the right lateral view only. The depth of the lesion was uncertain. The tomoscan proved the lesion was within the brain rather than superficial because it was sharply focused at a depth of 2.75 in. (Fig. 7). In a previously reported case, a left frontal oligodendroglioma was well localized by the tomographic scan (4). In this case, the coronal series outlined the roof of the orbits on the second and third readout planes. The tumor was clearly outlined on the fourth readout plane at a depth of 1-in. posterior to the back of the orbit. On the left lateral series, the tumor was sharply resolved on the fourth readout plane which represented a plane near the midline of the skull approximately 3 in. from the surface. Such information could be extremely useful to the neurosurgeon.

Lung. Eleven of 22 lung scans were abnormal, showing areas of decreased pulmonary perfusion. All patients were referred because of suspected pulmonary emboli. The abnormal cases in this series showed relatively large lesions. In one instance the entire left lung was not being perfused. In five there were multiple bilateral areas of decreased perfusion.

Diagnostically, the tomoscans and scintiphotos were comparable in all instances, although the resolution of the tomoscans was frequently superior.

Areas of decreased pulmonary perfusion usually are sizable, and they should be well detected with both the tomoscanner and the scintillation camera. This has been the experience to date. Because the lung is a thick organ, it is possible that, when a greater number of cases have been examined, instances will be found in which the tomoscan detects small lesions missed with the scintiphotos.

Pancreas. The pancreas was scanned without any special patient preparation. The tomoscan was started immediately after injection of selenomethionine. Using a 1/8-in. line spacing, a 15-min scan was accomplished. Starting at 30-min postinjection, a 30-min tomoscan using a 1/16-in. line spacing was done. Occasionally a third tomoscan was done. A 10-min scintiphoto followed the tomoscan and was usually started within 60–90-min postinjection.

Seventeen patients had pancreas studies and of these, the uptake of selenomethionine was good in five, fair in six, and poor in six. This is not surprising as King et al, using a conventional 3-in. crystal

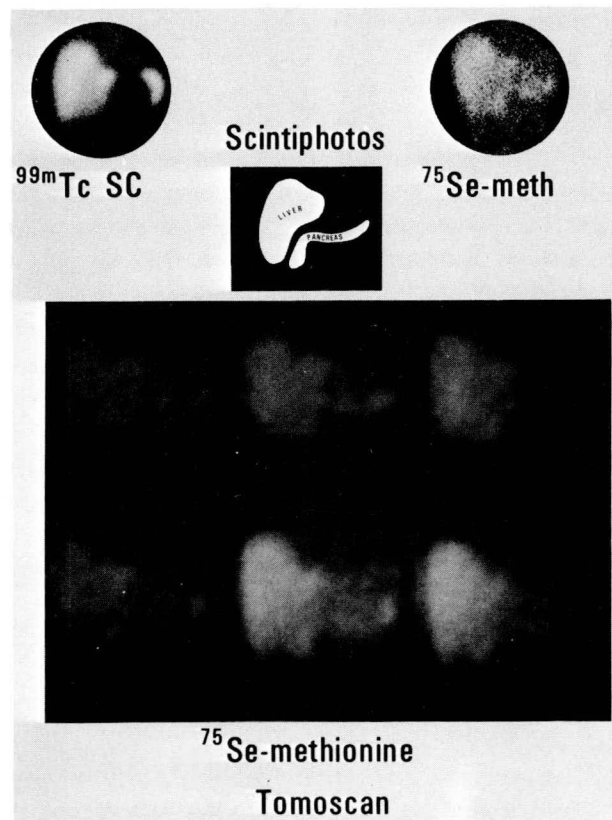


FIG. 8. ^{99m}Tc -sulfur colloid liver scintiphoto shows truncated left hepatic lobe suggesting intrinsic or extrinsic mass in this region. On ^{75}Se -selenomethionine scintiphoto, abnormality in tail of pancreas is suspected. Tail of pancreas is resolved and appears normal on tomoscan. Line drawing indicates outline of pancreas and its relationship to liver as determined by tomoscan.

scanner, obtained a good image in only nine of 33 ^{75}Se -selenomethionine pancreas scans done in patients without a history of pancreatic disease, suggesting that even the normal pancreas may fail to take up the compound (5).

Of the 12 cases with good or fair uptake, the tomoscans resolved the pancreas slightly better than the scintiphotos in six. Additional clinical information was provided by the tomoscan in one case, that of an emaciated man with unilateral proptosis and an abdominal mass, whose $^{99\text{m}}\text{Tc}$ -sulfur colloid liver scintiphoto showed a truncated left hepatic lobe (Fig. 8). The ^{75}Se -selenomethionine scintiphoto suggested a lesion originating in the tail of the pancreas. The tail was resolved on the tomoscan and appeared normal, suggesting an extrapancreatic etiology for the truncated left hepatic lobe (Fig. 8).

DISCUSSION

The difficulty inherent in the empiric approach used in this comparison of instruments must be recognized. As has been emphasized by Gottschalk (6), if one tries empirically to compare instruments that are reasonably close in function and purpose, usually thousands of cases must be studied in order to detect 100 "marginal" lesions, and this latter group must be examined to decide which of the techniques is better.

CONCLUSIONS

One hundred and sixty-one patients were studied with the multiplane tomographic scanner between June 1968 and March 1970. The tomographic scanner did not fail to detect any lesion visualized with

other instruments. When compared to the scintillation camera, the tomographic scanner provided additional useful information in nine of 52 liver scans, eight of 25 kidney scans, two of 45 brain scans, and one of 17 pancreas scans. Therefore, in 20 of 162 cases, or about 12%, the tomoscanner provided additional information. When compared to the other scanners, the percentage is somewhat higher. In liver and kidney scanning, its advantage was sharper resolution of all space-occupying lesions. This resulted in the detection of lesions missed by the scintillation camera in 13 of 77 cases, or 17%. In brain scanning it allowed more accurate localization of focal lesions by reference to the normal cross-sectional anatomy of the brain. In lung and pancreas scanning the superior resolution did not result in the detection of any additional lesions.

REFERENCES

1. ANGER HO: In *Fundamental Problems in Scanning*, Springfield, Charles C. Thomas, 1968, p. 195
2. ANGER HO: In *Instrumentation in Nuclear Medicine*, New York, Academic Press, 1967, p. 495
3. LOKEN MK, GERDING D: Visualization of filling defects in a liver phantom containing $^{99\text{m}}\text{Tc}$, ^{197}Hg , ^{131}I , or ^{198}Au using a rectilinear scanner or scintillation camera. *Amer J Roentgen* 88: 275-288, 1962
4. WEI WC, MCRAE J, ANGER HO: A case of oligodendroglioma studied with technetium-99m pertechnetate the scintillation camera and multiplane tomographic gamma-ray scanner. *J Neurosurg* 31: 474-478, 1969
5. KING ER, SHARPE A, GRUBB W, et al: Study of the morphology of the normal pancreas using ^{75}Se -methionine photoscanning. *Amer J Roentgen* 96: 657-663, 1966
6. GOTTSCHALK A: *Clinical Scintillation Scanning*. New York, Hoeber Medical Division, Harper & Row, 1969, p. 517