

# UCLA

## UCLA Previously Published Works

### Title

Shoulder instability: evaluation with MR imaging.

### Permalink

<https://escholarship.org/uc/item/5628k8m3>

### Journal

Radiology, 168(3)

### ISSN

0033-8419

### Authors

Seeger, LL  
Gold, RH  
Bassett, LW

### Publication Date

1988-09-01

### DOI

10.1148/radiology.168.3.3406398

Peer reviewed

## Shoulder Instability: Evaluation with MR Imaging<sup>1</sup>

**Instability of the glenohumeral joint is a common cause of chronic shoulder pain and disability. One or more episodes of subluxation or dislocation may result in a tear, detachment, or attenuation of the glenoid labrum, stripping of the joint capsule from the scapula, or trauma to the tendons or muscles of the rotator cuff. A series of 27 shoulders examined with magnetic resonance (MR) imaging showed changes of glenohumeral instability, which were confirmed with open or arthroscopic surgery. MR imaging was capable of displaying common types of pathologic conditions resulting from instability, including labral trauma, capsular detachment, and retraction of the subscapularis muscle. MR imaging is a valuable diagnostic tool for the evaluation of glenohumeral instability.**

**Index terms:** Shoulder, dislocation, 414.42  
• Shoulder, injuries, 414.436 • Shoulder, MR studies, 414.1214

**Radiology 1988;** 168:695-697

**B**ECAUSE the glenohumeral joint is the most mobile joint in the body, it is also the most inherently unstable (1). Since only a small portion of the humeral head is in contact with the glenoid fossa at any given time, much of the stability of the joint must come from the surrounding soft tissues. Although no consensus exists regarding precisely what structures are responsible for glenohumeral stability (2-6), it appears that the so-called capsular mechanism provides most of its support (6). This soft-tissue complex includes the glenoid labrum, synovium and capsule of the joint, the three glenohumeral ligaments, and the anterior (subscapularis) and posterior (infraspinatus and teres minor) rotator cuff tendons and muscles.

To determine the accuracy of magnetic resonance (MR) imaging in depicting the soft-tissue abnormalities associated with shoulder instability, we identified 67 shoulders with MR findings indicative of this disorder. Surgery was subsequently performed on 27 of these shoulders, allowing retrospective correlation with the MR findings.

### MATERIALS AND METHODS

All images were acquired with a 0.3-T magnet system (Fonar, Melville, NY). The planar surface coil that was used and the method of patient positioning have been previously described (7). All imaging was done in the axial plane. The field of view was 17-19.2 cm, with an imaging matrix of 256 × 256 interpolated to 512 × 512 for display. The section thickness was 3-5 mm, and sections were obtained at 5-7-mm intervals. Whenever possible, images with both relative T1 weighting (spin-echo sequence, repetition time [TR] of 300-500 msec, echo time [TE] of 28-30 msec [SE 300-500/28-30]) and with T2 weighting (SE 1,500-2,000/56-84) were obtained.

Surgical confirmation of instability was available in 27 shoulders. Only one pulse sequence was available in 13 of these: T1-weighted images were obtained in nine and T2-weighted images in four. The remaining 14 shoulders underwent both

T1- and T2-weighted imaging. To avoid possible soft-tissue changes resulting from prior invasive procedures, MR imaging was not performed less than 2 weeks after shoulder arthrography or corticosteroid injection.

For all MR images, the glenoid labrum was evaluated for contour and signal intensity, and the anterior and posterior cuff muscles were evaluated for the site of the musculotendinous junction and for atrophy. Atrophy was considered to be present only if high-signal-intensity fat within the muscle on relatively T1-weighted images was disproportionately greater than in adjacent muscles. Bankart lesions were considered present if high-signal-intensity fluid was seen either along the base of the labrum (indicating labral avulsion) or along the border of the scapula (indicating capsular stripping).

### RESULTS

Of the 67 shoulders with MR findings of glenohumeral instability, 56 were associated with a history of prior dislocation or subluxation. The remaining 11 were imaged to evaluate nonspecific shoulder pain or to rule out a rotator cuff tear and were found to have abnormalities indicative of instability.

In the 27 shoulders with surgical follow-up, there were no false-positive MR images for labral abnormality. The labrum manifested severe attenuation and indistinct borders, diffusely abnormal increased signal intensity, or a discrete band of abnormal increased signal intensity. With the latter two changes, the tear was of medium signal intensity on relatively T1-weighted images and became bright with T2 weighting. In 24 of the 27 shoulders, labral abnormalities were limited to the anterior labrum (Figs 1, 2). One shoulder had only a posterior labral abnormality, while in two shoulders both the anterior and posterior labra were abnormal, indicating multidirectional instability (Fig 3).

Bankart lesions may be osseous (fracture of the glenoid rim), "cartilaginous" (avulsion of the glenoid labrum and/or stripping of the joint capsule),

<sup>1</sup> From the Department of Radiological Sciences, UCLA School of Medicine, 10833 Le Conte Ave, Los Angeles, CA 90024. From the 1987 RSNA annual meeting. Received March 4, 1988; revision requested April 11; revision received April 29; accepted May 2. Address reprint requests to L.L.S.

© RSNA, 1988

or both. Because the glenoid labrum is predominantly fibrous and contains little cartilage, we refer to the "cartilaginous" lesion as either a labral or a capsular Bankart lesion. Surgical confirmation of a Bankart lesion in seven shoulders was corroborated by MR evidence either of labral detachment and/or capsular stripping on T2-weighted images (Fig 3, 4) or abnormal signal intensity within the subchondral bony glenoid on T1-weighted images (Fig 5). In five shoulders with only T1-weighted images, MR failed to show a capsular Bankart lesion that was later found at surgery.

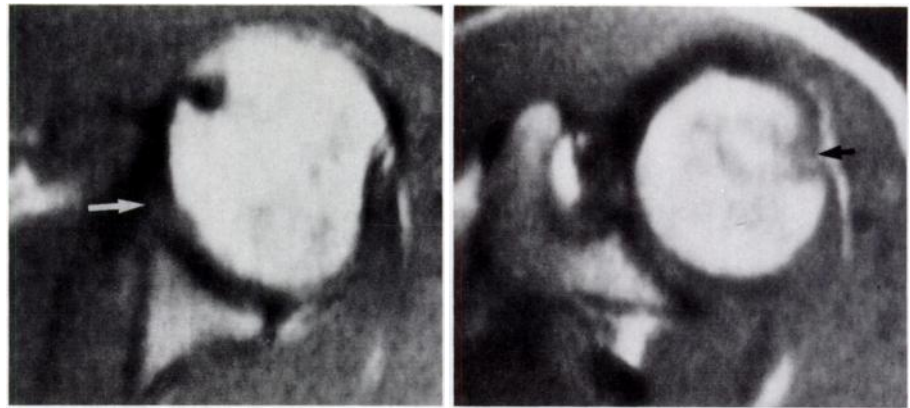
Within the group of 27 shoulders with surgical follow-up, three exhibited MR evidence of retraction of the subscapularis muscle, characterized by medial displacement of the musculotendinous junction (Fig 6). An abnormal increase in fat within the subscapularis muscle in four shoulders indicated muscle atrophy. None of the patients showed abnormalities at MR imaging of the posterior portion of the rotator cuff (infraspinatus and teres minor).

## DISCUSSION

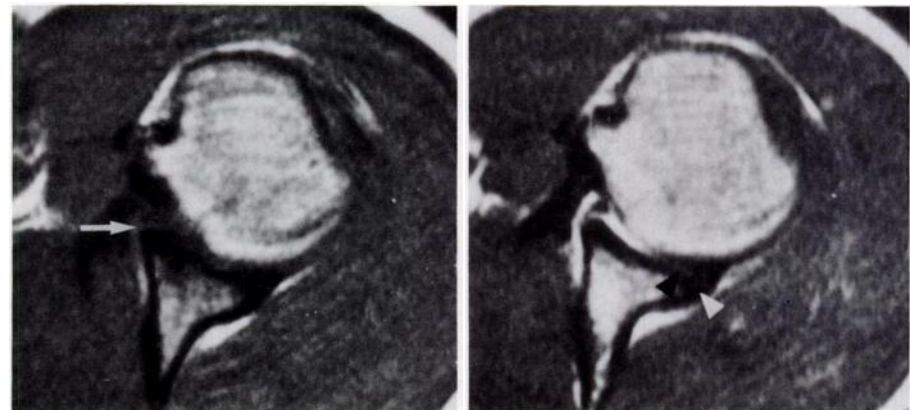
Several diagnostic problems may be encountered during the evaluation of the unstable shoulder. First, not all patients have a typical history of prior dislocation or subluxation but may instead complain of such nonspecific problems as pain, fatigue, weakness, numbness, or diminished range of motion (8,9). The differential diagnosis for these vague symptoms is extensive and includes shoulder impingement syndrome with or without rotator cuff tear, acromioclavicular joint disease, cervical disk disease, thoracic outlet syndrome, and brachial plexus injury. Second, there exists a group of patients in whom instability is multidirectional (9), that is, both anterior and posterior. If only the more common anterior lesion is repaired, these patients may subsequently experience persistent pain and disability from fixed, unidirectional posterior instability. Finally, there is a significant number of patients with complex soft-tissue lesions involving not only the glenoid labrum but also the joint capsule and/or rotator cuff (10). For these patients, simple labral debridement is inadequate to relieve symptoms and achieve stability, and a more extensive surgical procedure is indicated.

Confirmation of the MR findings was in general possible only for those patients who were referred for imaging and followed up by orthopedic surgeons at our institution.

The glenoid labrum is predominantly composed of fibrous tissue and therefore normally appears as a signal void in all pulse sequences (7). The an-



**Figure 1.** Anterior labral attenuation in a 33-year-old man with history of multiple anterior dislocations. (a) T1-weighted axial MR image (SE 500/28) shows that anterior labrum is severely attenuated and its margin is ill defined (arrow). The posterior labrum is normal. (b) More superior image from same imaging sequence shows abnormal contour of lateral margin of humeral head at level of coracoid process, indicating Hill-Sachs lesion (arrow).



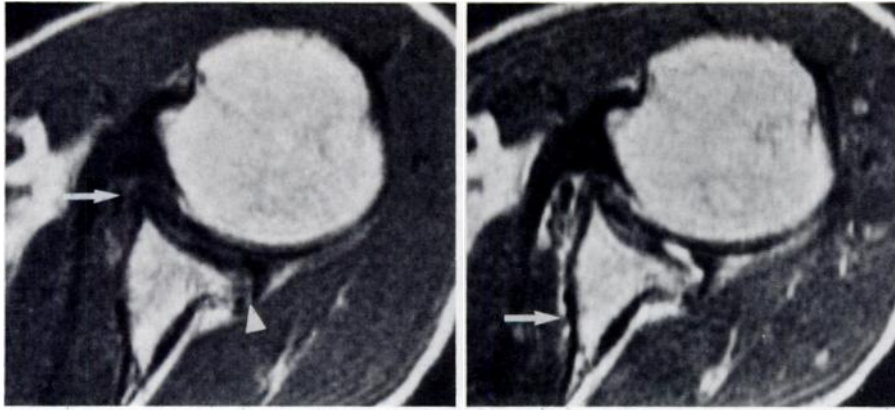
**Figure 2.** Anterior labral tear in a 20-year-old male baseball pitcher with 4-month history of anterior subluxation. (a) Axial T1-weighted image (SE 500/28) shows band of medium-intensity signal traversing anterior labrum (arrow). (b) T2-weighted image (SE 2,000/56) reveals high-signal-intensity joint fluid surrounding anterior labrum and within tear. Surgery disclosed "bucket-handle" tear anteriorly. Thin band of intermediate signal intensity adjacent to posterior labrum (black arrowhead) represents articular cartilage. More posterior rim of intermediate signal intensity (white arrowhead) is believed to represent the thin layer of cartilage tissue at the labral base. The signal is not high enough on this T2-weighted image to represent fluid due to tear. Posterior labrum was normal at surgery.

terior labrum is larger than the posterior labrum. Because the entire labrum is pliable, its shape depends on the position of the humeral head (6). With internal rotation of the humeral head, the anterior lip is sharply pointed and the posterior lip is rounded.

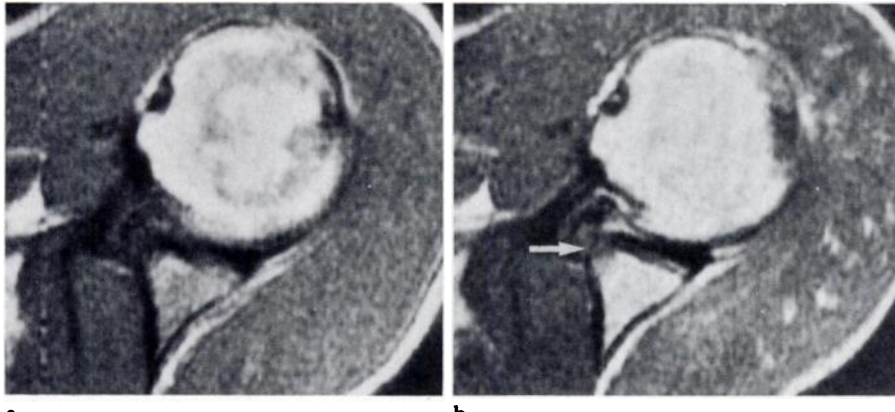
While we had no false-positive images for labral abnormality among the 27 shoulders with abnormal MR findings and surgical confirmation, the number of false-negative images, if any, is not known because follow-up was not available for most patients with normal-appearing labra on MR images. Although Kieft et al (11) were unable to detect soft-tissue abnormalities with MR imaging in two shoulders that had undergone recurrent dislocation, surgical confirmation was unavailable for either patient, and the MR appearance of the subscapularis musculotendinous unit was not discussed.

The normal subscapularis tendon appears as a homogeneous signal void from its musculotendinous junction to its attachment to the lesser tuberosity (7). On axial MR images, the musculotendinous junction should approximate the level of the bony glenoid. The muscle should produce a homogeneous medium-intensity signal, without evidence of focal, disproportionate deposits of fat. Because of its inherently high soft-tissue contrast, MR imaging is an ideal means of determining the level of the musculotendinous junction and of evaluating possible muscle atrophy.

It was unusual to find a description of the anterior or posterior rotator cuff in the surgical reports of those of our patients who underwent surgery. Therefore, although it was usually impossible to confirm our MR findings relating to these structures, we believe that they nevertheless play a signifi-



**Figure 3.** Multidirectional instability in a 42-year-old man with shoulder pain for 1 year. (a) T1-weighted axial image (SE 500/28) shows diffusely abnormal intermediate signal intensity in region of anterior labrum (arrow), as well as at base of the posterior labrum (arrowhead). (b) With T2 weighting (SE 2,000/56), high-signal-intensity fluid is seen surrounding base of anterior and posterior labra and dissecting along anterior border of scapula (arrow). Surgery disclosed anterior and posterior Bankart lesions.



**Figure 4.** Anterior labral tear with Bankart lesion in a 26-year-old racquetball player with history of recurrent anterior subluxation. (a) Axial T1-weighted image (SE 500/28) shows diffuse abnormal signal intensity in anterior labrum, with small region of abnormally low signal intensity in anterior glenoid rim. Posterior labrum is normal. (b) T2-weighted image (SE 2,000/56) reveals high-signal-intensity fluid along lateral aspect of anterior labrum and loss of normally sharp cortical separation between labrum and bony glenoid (arrow). An anterior Bankart lesion was found at surgery.

cant role in the predilection for and in the pathologic conditions resulting from glenohumeral instability, and we have therefore included the MR findings in our analysis.

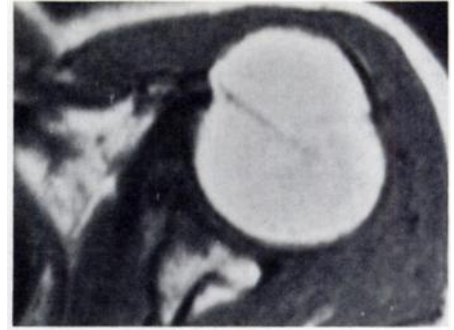Ideally, the MR evaluation of glenohumeral instability should include both T1- and T2-weighted images. T1-weighted images are needed to differentiate fatty infiltration of the rotator cuff muscles from fluid, and T2-weighted images are often required to identify the full extent of a labral tear and of capsular avulsion. In 13 of the 27 cases confirmed at surgery, only one pulse sequence was available for evaluation. This is because early in our experience, both T1- and T2-weighted imaging was not routinely employed. Even now, patients with nonspecific complaints or with symptoms indicative of impingement syndrome or rotator cuff tear require considerable imaging time for multiplanar imaging, usually pre-

cluding the performance of both T1- and T2-weighted imaging in the axial plane.

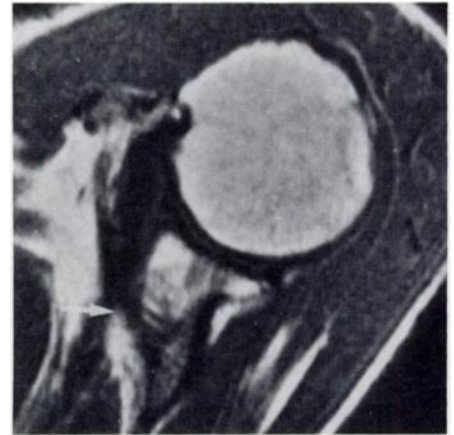
We have found MR imaging to be a valuable noninvasive method for studying the pathologic conditions associated with shoulder instability. MR imaging studies can document labral abnormalities, confirm the direction of instability, and identify those patients with multidirectional instability. MR imaging is also useful for planning surgery for patients with complex pathologic conditions for whom the simple arthroscopic debridement of labral tears may be inadequate. Further studies are needed to compare the effectiveness of MR imaging with CT arthrography for the evaluation of this common condition. ■

#### References

1. Rothman RH, Marvel JP, Happenstall RB. Recurrent anterior dislocation of the shoulder. *Orthop Clin North Am* 1975; 6:415-422.



**Figure 5.** Anterior labral tear with osseous Bankart lesion in a 65-year-old woman who complained of shoulder pain after trauma 10 days before MR imaging. Axial T1-weighted image (SE 500/28) shows diffusely abnormal signal intensity in anterior labrum and bony glenoid. Posterior labrum is normal.



**Figure 6.** Retracted subscapularis muscle in a 65-year-old man with limited range of motion and shoulder pain for 5 years. Axial T1-weighted MR image (SE 500/28) reveals retraction of subscapularis musculotendinous junction (arrow). Band of abnormal intermediate signal intensity is present in anterior labrum.

2. Townley CO. The capsular mechanism in recurrent dislocation of the shoulder. *J Bone Joint Surg [Am]* 1950; 32:370-380.
3. Brewer BJ, Wubben RC, Carrera GF. Excessive retroversion of the glenoid cavity. *J Bone Joint Surg [Am]* 1986; 68:724-731.
4. Turkel SJ, Ithaka, Panio MW, Marshall JL, Girgis FG. Stabilizing mechanisms preventing anterior dislocation of the glenohumeral joint. *J Bone Joint Surg [Am]* 1981; 63:1208-1217.
5. Pappas AM, Goss TP, Kleinman PK. Symptomatic shoulder instability due to lesions of the glenoid labrum. *Am J Sports Med* 1983; 11:279-288.
6. Mosley HF, Overgaard B. The anterior capsular mechanism in recurrent anterior dislocation of the shoulder. *J Bone Joint Surg [Am]* 1962; 44:913-927.
7. Seeger LL, Ruszkowski JT, Bassett LW, Kay SP, Kahmann RD, Ellman H. MR imaging of the normal shoulder: anatomic correlation. *AJR* 1987; 148:83-91.
8. Rowe CR, Zarins B. Recurrent transient subluxation of the shoulder. *J Bone Joint Surg [Am]* 1981; 63:863-871.
9. Neer CS II, Foster CR. Inferior capsular shift for involuntary inferior and multidirectional instability of the shoulder. *J Bone Joint Surg [Am]* 1980; 62:897-908.
10. Rowe CR, Patel D, Southmayd WW. The Bankart procedure. *J Bone Joint Surg [Am]* 1978; 60:1-16.
11. Kieft GJ, Sartoris DJ, Bloem JL, et al. Magnetic resonance imaging of glenohumeral joint disease. *Skeletal Radiol* 1987; 16:285-290.