

UC Davis

UC Davis Previously Published Works

Title

Cholangiocarcinoma obscured by a large paraesophageal hernia causing traction compression of the common hepatic duct ultimately diagnosed with percutaneous cholangioscopy.

Permalink

<https://escholarship.org/uc/item/56q4j0pg>

Journal

Videogic, 7(3)

Authors

Tejaswi, Sooraj

Louie, Justin

Jenner, Zachary

et al.

Publication Date

2022-03-01

DOI

10.1016/j.vgie.2021.12.001

Copyright Information

This work is made available under the terms of a Creative Commons Attribution-NonCommercial-NoDerivatives License, available at

<https://creativecommons.org/licenses/by-nc-nd/4.0/>

Peer reviewed



Cholangiocarcinoma obscured by a large paraesophageal hernia causing traction compression of the common hepatic duct ultimately diagnosed with percutaneous cholangioscopy

Sooraj Tejaswi, MD, MSPH,¹ Justin Louie, MD,¹ Thomas W. Loehfelm, MD, PhD,¹ Zachary B. Jenner¹
Sonia Reichert, MD,² Ananya D. Mitra, MD,¹ Sepideh Gholami, MD,¹ Rex M. Pillai, MD¹

A 75-year-old man presented to an outside hospital with a 1-month history of painless jaundice. Abdominal CT and magnetic resonance imaging with contrast showed severe intrahepatic biliary ductal dilation with an abrupt cutoff in the common bile duct at the entrance into a large type IV hiatal hernia that contained the entire stomach, proximal duodenum, and colon (Fig. 1). The proximal duodenum was being pulled into the hernia tightly, leading to compression of the common bile duct (Fig. 2). His lipase level was normal (65 U/L), and the pancreas appeared normal on cross-sectional imaging. He underwent right-sided internal/external 8.5F percutaneous biliary drain placement by interventional radiology (IR) (Fig. 3). After this, he developed necrotizing pancreatitis around the tail of the pancreas.

He presented to us shortly after discharge for further management. He had persistently elevated liver enzymes and elevated CA 19-9, despite the functioning biliary drain. This raised suspicion for an alternative diagnosis, such as cholangiocarcinoma, despite cross-sectional imaging not showing a biliary mass. Intraductal evaluation with ERCP

was deferred because of his complex anatomy and necrotizing pancreatitis. Instead, we planned percutaneous cholangioscopy in conjunction with the IR team.

It is our practice to perform this procedure with the patient under general anesthesia in the IR suite to avoid transporting an intubated patient between the endoscopy and IR suites. Patients are positioned supine. A target intrahepatic bile duct/radicle is identified under ultrasound guidance, and access is obtained with AccuStick introducer system (Boston Scientific, Natick, Mass, USA) or MAK set (Merit Medical, Jordan, Utah, USA) over a wire (Nitrex, Medtronic, Minneapolis, Minn, USA). A longitudinal approach is preferred to parallel the bile duct. A cholangiogram is then obtained, followed by guidewire passage into the duodenum and catheter advancement over the guidewire into the duodenum. This is followed by dilation of the percutaneous tract with a 12F × 30-cm sheath (Cook Medical, Bloomington, Ind, USA) and inner dilator over a 0.035-inch wire, typically a stiff wire (Amplatz wire, Boston Scientific). Once the sheath is secure, a Spyglass Discover digital catheter (Boston Scientific) is advanced through the

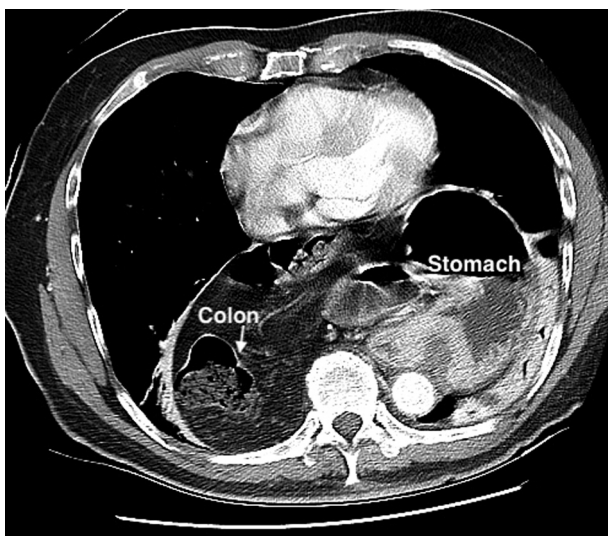


Figure 1. CT image showing a large paraesophageal hernia containing stomach and transverse colon (*white arrow*).

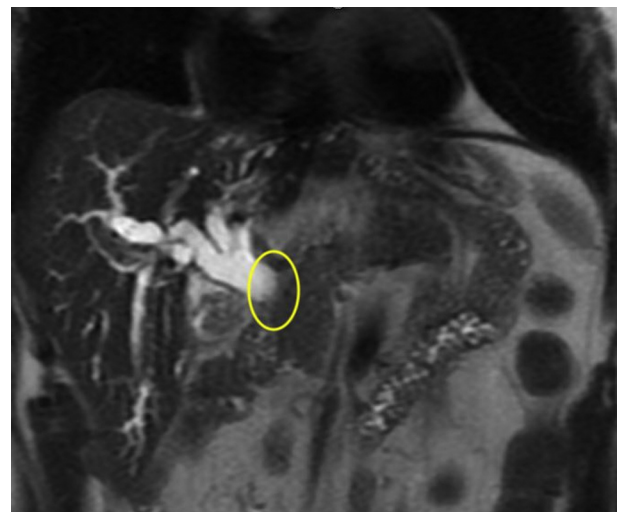


Figure 2. Magnetic resonance imaging shows severe intrahepatic biliary dilation with abrupt cut off at the common hepatic duct region (*yellow oval*).

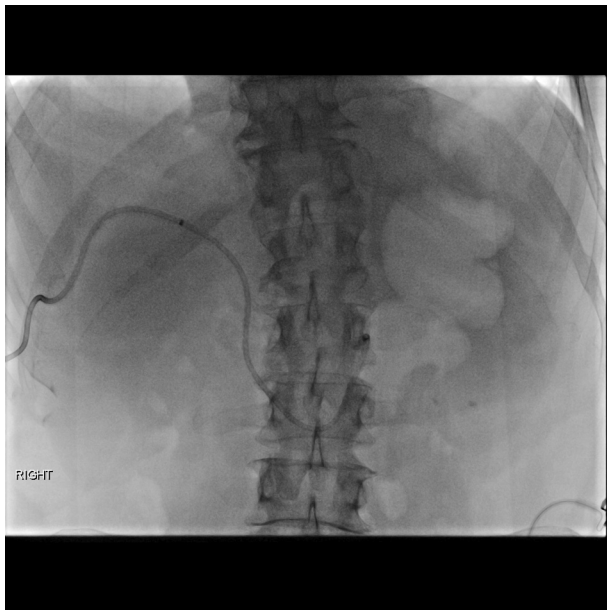


Figure 3. Fluoroscopic image showing the 8.5F internal-external biliary drain.

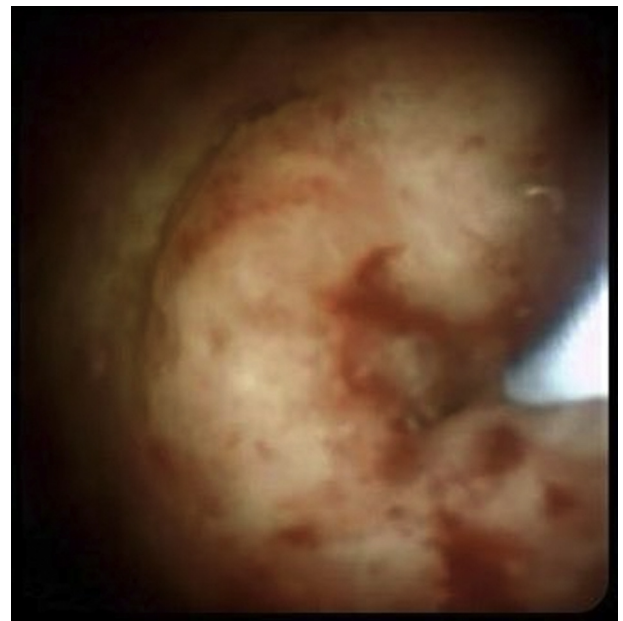


Figure 5. Percutaneous cholangioscopy showing a near-circumferential mass in the common hepatic duct.

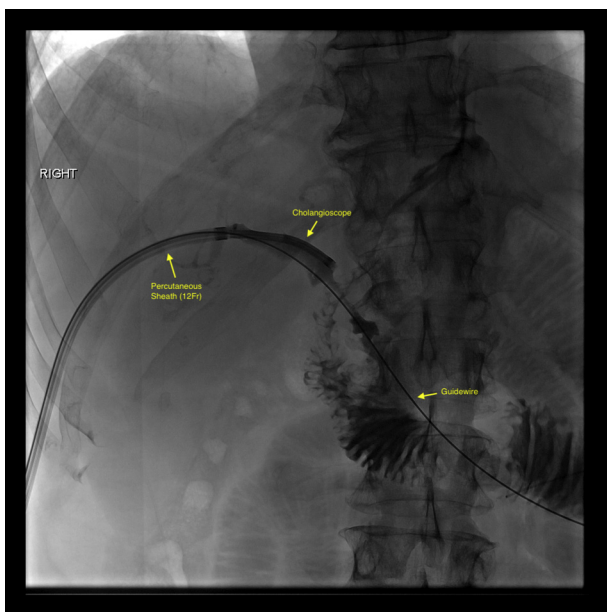


Figure 4. Fluoroscopic image showing the 12F percutaneous sheath through which the cholangioscope was inserted alongside the guidewire.

sheath. This can be done either over or alongside the guidewire (Fig. 4) (Video 1, available online at www.giejournal.org). Antibiotic prophylaxis is administered, and we typically continue antibiotics for 3 to 5 days after the procedure.

Cholangioscopy revealed a near-circumferential mass with tumor vessels in the common hepatic duct (Fig. 5) about 2 cm below the hilum. Cholangioscopy-directed biopsies revealed moderately differentiated adenocarcinoma

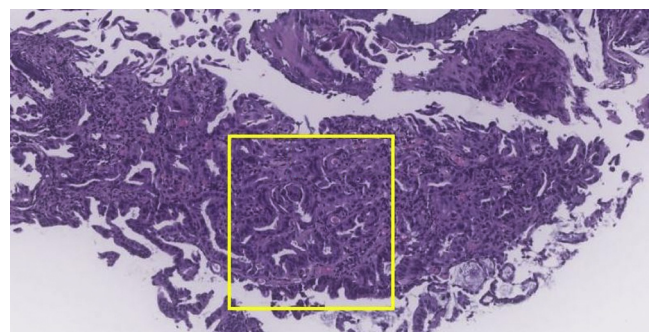


Figure 6. Hematoxylin & eosin stain (orig. mag. $\times 4$) showing submucosal glands with prominent nuclei (yellow box).

(Figs. 6, 7, and 8), leading to a diagnosis of Klatskin tumor (Bismuth-Corlette Type I). Just distal to and below this mass was a 2.5-cm high-grade biliary stricture with fibrotic-appearing mucosa due to traction from the large hiatal hernia causing extrinsic compression (Figs. 9 and 10) (Video 1). Because of persistent left-sided biliary ductal dilation after percutaneous biliary drain placement, we completed percutaneous cholangioscopy of the left intrahepatic ducts with the SpyGlass DS II access and delivery catheter (Boston Scientific) and did not see any additional abnormalities.

A 12F internal/external percutaneous biliary drain (Cook Medical) was left in place after the procedure to prevent bile leak around the puncture site and to provide biliary drainage in this patient with obstructive jaundice (Video 1). The patient tolerated oral nutrition throughout his clinical course and did not need enteral feeding.

The patient underwent neoadjuvant chemotherapy with 6 cycles of cisplatin and gemcitabine. However, during

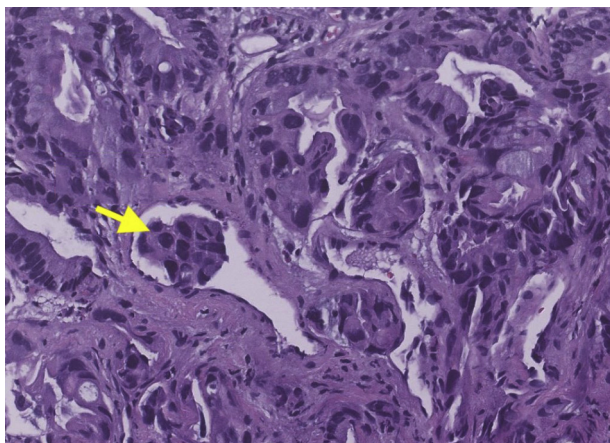


Figure 7. Histopathology (orig. mag. $\times 20$) showing submucosal glands with prominent atypical nuclei with increased nuclear-cytoplasmic ratio (yellow arrow).

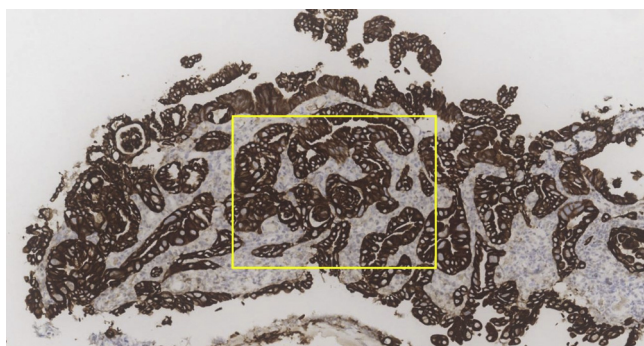


Figure 8. Immunohistochemical stain showing cyokeratin 7 staining of the submucosal glands (yellow box).

laparotomy, peritoneal spread was detected, precluding curative resection. The large hiatal hernia was reduced and gastropexy was performed.

Unfortunately, the patient developed recurrent bouts of cholangitis requiring an additional percutaneous biliary drain and ultimately chose comfort care and died.

DISCUSSION

Obstructive jaundice due to abrupt tapering of the common bile duct at the hiatus of a type IV hiatal hernia is extremely rare.¹⁻⁵ Definitive management requires surgical repair of the hiatal hernia¹ and is undertaken after decompression of the biliary obstruction. Biliary decompression is best attempted via percutaneous drainage because ERCP is less likely to be successful owing to the challenging anatomy.^{1,3-5} However, surgery may need to be performed urgently if there is concern for bowel ischemia owing to strangulation inside the hiatal hernia.⁵

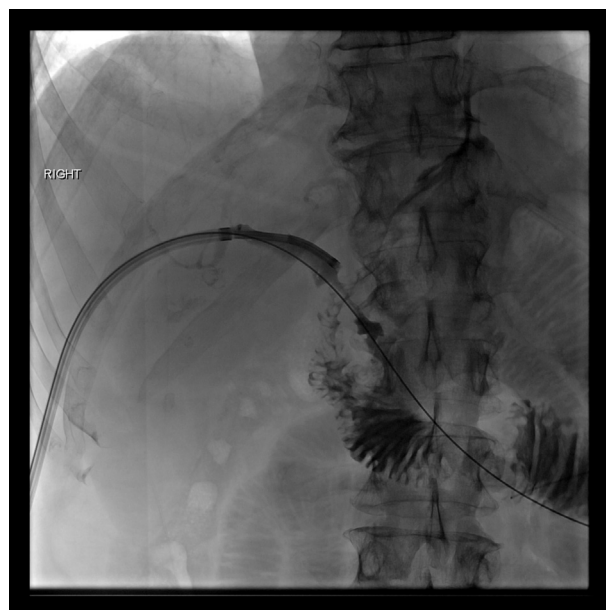


Figure 9. Cholangiogram showing the CBD stricture due to extrinsic compression owing to traction of the duodenum by the Type IV hiatal hernia.

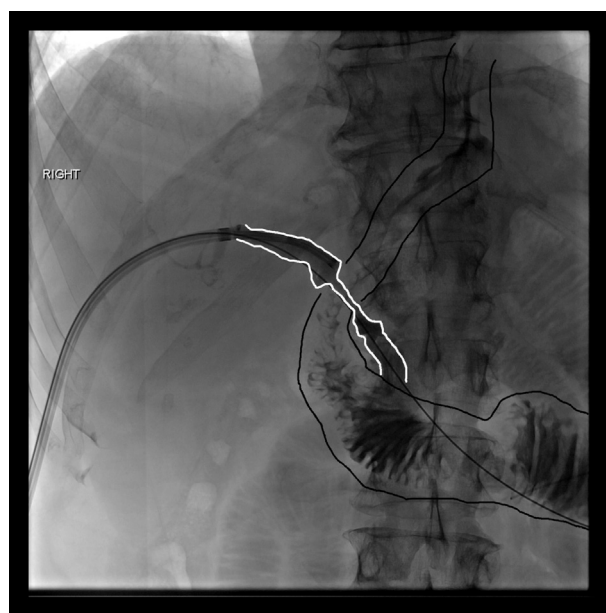


Figure 10. Annotated cholangiogram tracing the CBD stricture due to extrinsic compression owing to traction of the duodenum by the Type IV hiatal hernia.

We present the first case of a coexisting cholangiocarcinoma, complicating a very rare manifestation of type IV hiatal hernia. The lack of normalization of liver test abnormalities and the elevated CA 19-9 level despite a functioning percutaneous biliary drain raised concern for a coexisting malignancy in this case. Percutaneous cholangioscopy and cholangioscopic-directed biopsies with the novel shorter-length cholangioscope designed for

percutaneous access aided the diagnostic workup because the yield of cytology brushings for cholangiocarcinoma remain suboptimal.⁶

Our technique of percutaneous cholangioscopy is a collaborative effort between the GI and IR teams. Our method has enabled percutaneous cholangioscopy after percutaneous biliary catheter placement in a single session, in lieu of waiting for maturation of the percutaneous biliary tract.⁷ This is a valuable technique when malignancy is suspected. An expedited diagnosis is vital to improve the outcome in such cases.

We recommend maintaining the percutaneous biliary drain after cholangioscopy to allow for the tract to mature before removing the drain. This can help avoid biliary leak. We irrigate the duct with distilled water or saline solution via the digital cholangioscope to achieve a satisfactory examination, and there are no reported cases of air embolism, which may occur with the use of pediatric gastroscopes via mature tracts. Finally, antibiotic prophylaxis can help reduce the risk of postprocedure cholangitis.

As with most interventional endoscopic procedures, we strongly recommend a postprocedure phone call to promptly identify any procedure-related adverse events and manage them appropriately.

DISCLOSURE

All authors disclosed no financial relationships.

Abbreviation: IR, interventional radiology.

REFERENCES

1. Furtado RV, D'Netto TJ, Hook HC, et al. Massive hiatal hernia complicated by jaundice. *J Surg Case Rep* 2015;2015:rjv087.
2. Llana PP, Salt WB 2nd, Partyka EK. Extrahepatic biliary obstruction complicating a diaphragmatic hiatal hernia with intrathoracic gastric volvulus. *Am J Gastroenterol* 1986;81:292-4.
3. Caldeiro JC, Curcio A, Gigena VC, et al. Choledochal semi volvulus with jaundice due to hiatal hernia. Initial percutaneous management. *Acta Gastroenterol Latinoam* 2001;31:329-32.
4. Tomida H, Hayashi M, Hashimoto S. Massive hiatal hernia involving prolapse of the entire stomach and pancreas resulting in pancreatitis and bile duct dilation: a case report. *Surg Case Rep* 2020;6:11.
5. Mandaliya R, Amberker D, Breckenridge J. Biliary obstruction from paraesophageal hernia. *Clin Gastroenterol Hepatol* 2014;12:e99.
6. Yan SL, Tejaswi S. Clinical impact of digital cholangioscopy in management of indeterminate biliary strictures and complex biliary stones: a single-center study. *Ther Adv Gastrointest Endosc* 2019;12:2631774519853160.
7. Tejaswi S, Pillai RM, Grandhe S, et al. Disposable digital percutaneous cholangioscope-aided retrieval of a plastic biliary stent after failed retrieval at ERCP. *VideoGIE* 2021;6:413-5.

UC Davis School of Medicine, Sacramento, California (1), Woodland Clinic Medical Group, Woodland, California (2).

If you would like to chat with an author of this article, you may contact Dr Tejaswi at soorajt@gmail.com.

Copyright © 2022 American Society for Gastrointestinal Endoscopy. Published by Elsevier Inc. This is an open access article under the CC BY-NC-ND license (<http://creativecommons.org/licenses/by-nc-nd/4.0/>).

<https://doi.org/10.1016/j.vgie.2021.12.001>

Endoscopy

Endoscopy has a new look! Check out the redesign of the official blog of *GIE* and *VideoGIE*. Keep up with the latest news and article discussions and post your comments or questions to *VideoGIE* authors. Visit us at www.endoscopy.com.