

UC Irvine

UC Irvine Previously Published Works

Title

Infection or allergy? The multifaceted nature of vulvar dermatoses

Permalink

<https://escholarship.org/uc/item/58j696sj>

Journal

International Journal of Women's Dermatology, 1(4)

ISSN

2352-6475

Authors

Vij, Alok
Sood, Apra
Piliang, Melissa
et al.

Publication Date

2015-12-01

DOI

10.1016/j.ijwd.2015.08.005

Peer reviewed



Infection or allergy? The multifaceted nature of vulvar dermatoses☆

Alok Vij, MD ^{a,*}, Apra Sood, MD ^a, Melissa Piliang, MD ^{a,b}, Natasha Atanaskova Mesinkovska, MD, PhD ^{a,b}

^a Department of Dermatology, Cleveland Clinic Foundation, Cleveland, OH

^b Department of Dermatopathology, Cleveland Clinic Foundation, Cleveland, OH

ARTICLE INFO

Article history:

Received 1 June 2015

Received in revised form 4 August 2015

Accepted 17 August 2015

ABSTRACT

Chronic dermatitis or pruritus affecting the female genital and perianal skin can be challenging to properly diagnose and manage. The differential diagnosis generally includes allergic, inflammatory, infectious, and neoplastic conditions. We report the case of a 52-year-old woman with a 6-month history of a progressive, debilitating vulvar and perianal rash that highlights the multifaceted nature of female genital dermatoses.

© 2015 The Authors. Published by Elsevier Inc. on behalf of Women's Dermatologic Society. This is an open access article under the CC BY-NC-ND license (<http://creativecommons.org/licenses/by-nc-nd/4.0/>).

Case report

A 52-year-old woman presented to our office for a second opinion with a 6-month history of a painful and pruritic genital and perianal rash. Initially, the rash presented on her superior gluteal cleft as a painful, round, ulcerated erythematous plaque. She was evaluated at an outside dermatology clinic and prescribed treatment with a mild topical steroid; despite this treatment, her eruption expanded to include her entire gluteal cleft, perineum, vulva, and inguinal folds.

Consultations with several dermatologists and infectious disease specialists resulted in an extensive workup and numerous treatments that were unsuccessful. She first attempted stronger topical steroids with liberal emollients. Skin cultures were positive for Group B *Streptococcus*, for which she was treated with oral antibiotics, including cephalixin and ciprofloxacin, in addition to topical ketoconazole and repeated courses of oral fluconazole for presumed *Candida* vaginitis. She developed pelvic lymphadenopathy, thought to be secondary to her dermatitis on MRI evaluation.

The patient was a professional with no significant past medical history. She took no chronic medications or supplements. She was in a long-term monogamous relationship with a female partner, who was unaffected by the rash. She was premenopausal with no history of chronic skin or venereal disease.

Despite all attempts, her skin became progressively eroded and weepy, with adherent crusts that made separating the skin painful and routine hygiene difficult. Her activities of daily living suffered due to the pain, discharge, and odor; she eventually had to resort to a position working from home. Ultimately, she was prescribed several

courses of prednisone, which somewhat improved her symptoms. After her last course of prednisone, she was devastated to note not only recurrence of the rash, but also new involvement of her armpits and flexural surfaces of her arms.

When she presented to our clinic, physical examination revealed tender, erythematous, edematous plaques with desquamative sheets of scale, erosions, and ulcers of her vulva (Fig. 1a), perineal and perianal skin (Fig. 1b), inguinal folds, and gluteal cleft. There was copious mucopurulent drainage on her vulva. Scattered thin erythematous plaques were noted in her axillary vaults and antecubital fossae.

Due to the complex presentation, the following tests were performed: bacterial and fungal cultures, herpes simplex virus (HSV) viral culture and direct fluorescent antibody screen, punch biopsy of the involved axillary and perianal skin, and comprehensive patch testing.

Bacterial culture revealed Group B *Streptococcus* and *Klebsiella pneumoniae*. Fungal culture revealed *Candida glabrata*, resistant to fluconazole. Viral cultures and direct fluorescent antibody screen were positive for HSV.

Punch biopsies from the perineum and the axilla revealed spongiotic dermatitis with a brisk superficial perivascular inflammatory infiltrate of lymphocytes and numerous eosinophils, suggestive of allergic contact dermatitis (Fig. 2).

Patch testing revealed 3+ reaction to methylisothiazolinone (MI) and 1+ reaction to methylisothiazolinone-methylchlorisothiazolinone (MCI) mixture (Fig. 3). These allergens were relevant, as the patient had used several brands of wet wipes and feminine cleansers containing the offending allergens.

The patient was treated with trimethoprim-sulfamethoxazole, voriconazole, and valacyclovir, with tremendous improvement in pain and erythema within several days. Strict avoidance of products containing the allergens induced near-resolution within 2 weeks. Though she had a bout of hand dermatitis after using a soap containing MI, her vulvar rash has otherwise remained controlled without the use of topical medications at 18 months of follow-up.

☆ Conflicts of interest: The authors have no conflicts of interest to report.

* Corresponding author.

E-mail address: vija@ccf.org (A. Vij).

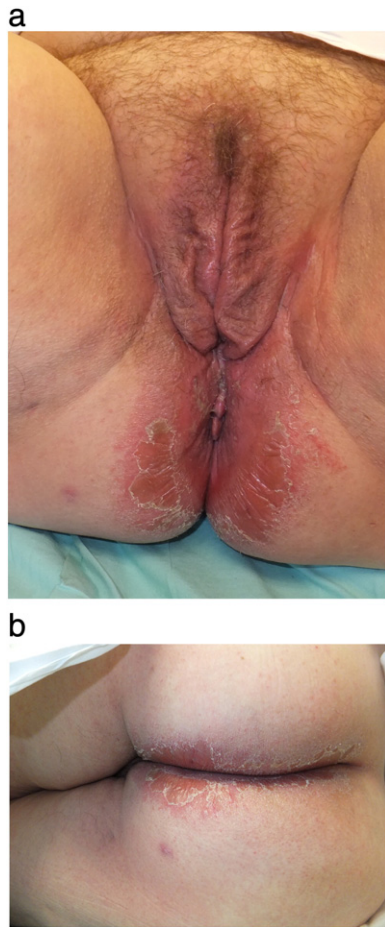


Fig. 1. (a) Erythema, edema, and sheets of desquamative scale of the vulva, inguinal folds, perianal skin, and gluteal cleft. (b) Edematous, erythematous plaques of the gluteal cleft with adherent crusts and desquamative sheets of scale.

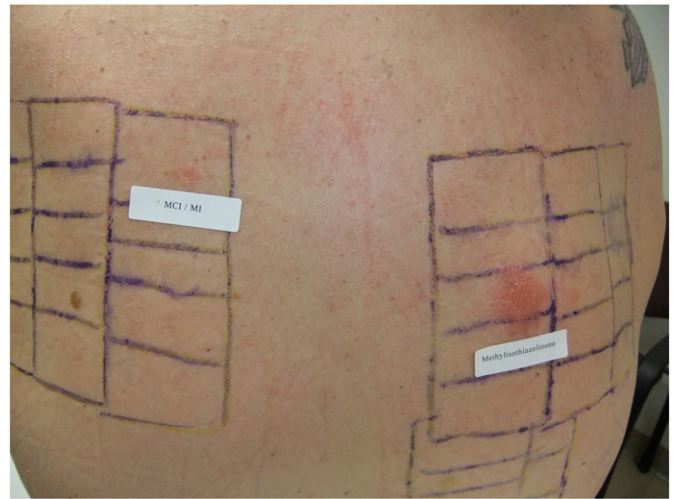


Fig. 3. Patch test results, final read at 96 hours. 3+ reaction to methylisothiazolinone; 1+ reaction to methylisothiazolinone:methylisochlorothiazolinone mixture.

Discussion

Dermatoses affecting the female genital tract can be challenging to optimally diagnose and treat. This case illustrates that several underlying pathologies may overlap to produce a complicated clinical syndrome, and separate management of each may not induce complete remission of the disease.

MI is a biocidal preservative used alone or in combination with MCI in cosmetics, wet wipes, and household products, including cleaning solutions and paint (Alwan et al., 2014). It has caused a recent epidemic of contact allergy, resulting in MI being named the American Contact Dermatitis Society's 2013 Contact Allergen of the year (Castanedo-Tardana and Zug, 2013). Contact sensitization to MI is associated with occupational dermatitis in painters and beauticians as well as anogenital or airborne allergic contact dermatitis (Uter et al., 2013), among other patterns of clinical disease. Many topical products used in female genital care, including washes, powders, wipes, and douches, contain this product.

A compromised skin barrier creates a portal of entry for cutaneous infections. Defensins are components of the innate immune system with broad antibacterial, antiviral, and antifungal activity (Jarczak et al., 2013). The cytokines that drive allergic contact dermatitis, including interleukin-4, -10, and -13, downregulate human defensins. The depletion of defensins may be linked to increased susceptibility to polymicrobial infections (Howell et al., 2006). In our patient, the compromised barrier allowed both Gram-positive and Gram-negative bacterial infection, which could only be definitively treated after culture and sensitivities were obtained.

Candida vulvovaginitis is increasing in frequency, as is fluconazole resistance among *Candida* isolates (Zhang et al., 2014). *C. glabrata* is a more virulent yeast than *Candida albicans*, associated with systemic illness (Pieralli et al., 2014), failed joint implants (Skedros et al., 2014), and intrauterine fetal loss (Ozer et al., 2013). Prior exposure to fluconazole may be a risk factor for invasive fungal disease (Zilberberg et al., 2014) and may portend a higher mortality once invasion has occurred (Colombo et al., 2014). Rigorous use of diagnostic tests to properly identify fungal organisms, coupled with the judicious use of antifungal agents, may serve to stem the rising tide of invasive fungal disease and antifungal resistance (Lestner et al., 2015), as antibiotic stewardship may be reducing bacterial resistance to antibiotics (JHuttner et al., 2014).

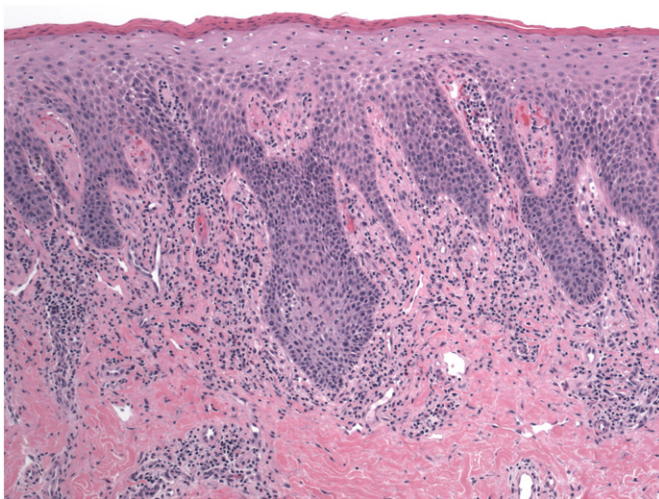


Fig. 2. Punch biopsy specimen from the gluteal cleft and the axilla revealed similar findings. Histologic sections revealed spongiotic dermatitis with a superficial- and mid-dermal perivascular infiltrate of lymphocytes and eosinophils consistent with allergic contact dermatitis. (H&E, 40×).

In addition to offering a portal of entry for bacterial and fungal infections, compromised skin barriers may increase susceptibility to viral infections. Eczema herpeticum (Kaposi varicelliform eruption) is a well-recognized phenomenon of viral superinfection of preexisting dermatoses such as atopic dermatitis (Olson et al., 2008). However, recent evidence suggests that the spectrum of clinical disease may be much broader than the classic acute, life-threatening eruption (Frish and Siegfried, 2011). With viral infections as much as with fungal infections, the judicious use of diagnostic tests is of utmost importance to avoid missing a chronic, indolent viral infection.

Additionally, the lack of history of genital or perianal herpes and sexual orientation of our patient need not obviate testing for viral infection. Initial infection with HSV may or may not induce disease; viral shedding is common prior to and after secondary recurrences, with or without an accompanying vesicular eruption (Chayavichitsilp et al., 2009). Based on epidemiological data from the most recent National Health and Nutrition Examination Study, women who have sex with women have the highest prevalence of HSV-2 infection, greater than men who have sex with men, men who do not have sex with men, and women who do not have sex with women (Xu et al., 2010a, 2010b).

Optimal management of complex anogenital dermatoses requires a step-wise approach. A careful history must be taken, with particular focus on the duration of the problem, including fluctuations in intensity and any associated symptoms: blistering, itching, burning, drainage, etc. Co-existing illnesses, such as diabetes; medications, including antibiotics; and chronic skin diseases, like psoriasis or lichen planus, can all play a role in the development or maintenance of an anogenital problems.

Also important are the use of, and response to, prescribed and nonprescribed medications during the course of the malady. Topical steroids may exacerbate infections, while anesthetic products may induce contact dermatitis; antibiotics may induce some positive change, but result in an opportunistic yeast infection. Attention should also be paid to personal hygienic practices, including the use of soaps or cleansing wipes, lotions, or sprays, as irritating or allergenic substances are commonly found in this often-overlooked component of the history.

A careful physical exam is critical to help define further testing and treatment considerations. Bacterial infections commonly present with erythema, edema, and tenderness of the involved skin; frank pus is a less likely finding. Although *Streptococcus* classically affects the perianal skin, vulvar involvement is common, as is polymicrobial involvement in compromised skin. The so-called “satellite papules” that herald *Candida* are papules of pustules at the periphery of a moist, shiny erythematous plaque often with overlying soft, caseous crust. Clues to the presence of herpes virus are grouped vesicles, erosions, or crusts on an erythematous base. The judicious use of cultures with susceptibility testing is crucial to avoid incomplete diagnosis or treatment failure.

In addition to infections, primary inflammatory skin diseases affecting the female anogenital region include psoriasis, lichen planus, lichen sclerosus et atrophicus, allergic or irritant contact dermatitis, and, rarely, atopic dermatitis. Clues to the presence of allergic contact dermatitis include well-marginated or symmetric erythematous scaly plaques.

Further testing should stem from the physical examination findings. Swab cultures for bacterial and fungal organisms should routinely be obtained. A low threshold for viral studies should be maintained, particularly in patients with disruption of the epidermis with ulcers, erosions, or blisters. Punch biopsy should also be performed if the

clinical picture is not clear or if the patient does not respond to treatment as expected.

Regardless of the clinical suspicion for contact dermatitis, fragrance-free, dye-free, and otherwise “hypoallergenic” products should be used in a patient’s personal care in addition to any prescribed treatments. This “anti-irritant” regimen should include laundry detergent, body wash or soap, and emollients. Patch testing can be a useful and occasionally necessary tool to help define the root cause of allergic contact dermatitis. Patch testing should be undertaken for patients with physical exam or histologic findings suspicious of allergic contact dermatitis. Additionally, any patient with a chronic course of dermatitis with limited or poor response to treatment should undergo patch testing.

Holistic care is required to optimally care for women with chronic genital eruptions. We report the case of a patient with a progressive, debilitating vulvovaginal and perianal eruption initiated by allergic contact dermatitis and complicated by bacterial, viral, and fungal infection. A step-wise approach to the diagnosis of anogenital dermatoses is also presented. The answer to the important question of “infection or allergy?” can be “both.”

References

- Alwan W, White I, Bannerjee P. Presumed airborne contact allergy to methylisothiazolinone causing acute severe facial dermatitis and respiratory difficulty. *Contact Dermatitis* 2014;70:316–28.
- Castaneda-Tardana M, Zug K. Methylisothiazolinone. *Dermatitis* 2013;24(1):2–6.
- Chayavichitsilp P, Buckwalter J, Krakowski A, Friedlander S. Herpes simplex. *Pediatr Rev* 2009;30(4):119–29.
- Colombo A, Guimaraes T, Sukienik T, Pasqualotto A, Andreotti R, Quieroz-Tellez F, et al. Prognostic factors and historical trends in the epidemiology of candidemia in critically ill patients: an analysis of five multicenter studies sequentially conducted over a 9-year period. *Intensive Care Med* 2014;40(10):1489–98.
- Frish S, Siegfried E. The clinical spectrum and therapeutic challenge of eczema herpeticum. *Pediatr Dermatol* 2011;28(1):46–52.
- Howell M, Boguniewicz M, Pastore S, Novak N, Bieber T, Girolomoni G, et al. Mechanism of HBD-3 deficiency in atopic dermatitis. *Clin Immunol* 2006;121(3):332–8.
- Jarczak J, Kościuczuk E, Lisowski P, Strzałkowska N, Józwik A, Horbańczuk J, et al. Defensins: natural component of human innate immunity. *Hum Immunol* 2013;74(9):1069–79.
- JHuttner B, Harbath S, Nathwani D. ESCMID Study Group for Antibiotic Policies (ESGAP). Success stories of implementation of antimicrobial stewardship: a narrative review. *Clin Microbiol Infect* 2014;20(10):954–62.
- Lestner J, Versporten A, Doerholt K, Warris A, Røilides E, Sharland M, et al. Systemic antifungal prescribing in neonates and children: outcomes from the Antibiotic Resistance and Prescribing in European Children (ARPEC) Study. *Antimicrob Agents Chemother* 2015;59(2):782–9.
- Olson J, Robles D, Kirby P, Colven R. Kaposi varicelliform eruption (eczema herpeticum). *Dermatol Online J* 2008;14(2):18.
- Ozer E, Unlu M, Ersen A, Gulekli B. Intrauterine fetal loss associated with *Candida glabrata* chorioamnionitis: report of two cases. *Turk Patoloji Derg* 2013;29(1):77–9.
- Pieralli F, Bazzini C, Vanucchi V, Mancini A, Nozzoli C. A case of *Candida glabrata* severe urinary sepsis successfully treated with micafungin. *Med Mycol Case Rep* 2014;10(5):1–3.
- Skedros J, Keenan K, Updike W, Oliver M. Failed reverse total shoulder arthroplasty caused by recurrent *Candida glabrata* infection with prior *Serratia marcescens* coinfection. *Case Rep Infect Dis* 2014;2014:142428.
- Uter W, Geier J, Bauer A, Schnuch A. Risk factors associated with methylisothiazolinone contact sensitization. *Contact Dermatitis* 2013;69:231–8.
- Xu F, Sternberg M, Markowitz L. Men who have sex with men in the United States: demographic and behavioral characteristics and prevalence of HIV and HSV-2 infection: results from National Health and Nutrition Examination Survey 2001–2006. *Sex Transm Dis* 2010;37(6):399–405.
- Xu F, Sternberg M, Markowitz L. Women who have sex with women in the United States: prevalence, sexual behavior and prevalence of herpes simplex virus type 2 infection—results from national health and nutrition examination survey 2001–2006. *Sex Transm Dis* 2010;37(7):407–13.
- Zhang J, Liu J, Liu F, Xia Y, Wang J, Liu X, et al. Vulvovaginal candidiasis: species distribution, fluconazole resistance and drug efflux pump gene overexpression. *Mycoses* 2014;57(10):584–91.
- Zilberberg M, Yu H, Chaudhari P, Emons M, Khandewal N, Shorr A. Relationship of fluconazole prophylaxis with fungal microbiology in hospitalized intra-abdominal surgery patients: a descriptive cohort study. *Crit Care* 2014;18(5):590.