

UC Davis
Dermatology Online Journal

Title

Mycobacterium marinum lymphocutaneous infection

Permalink

<https://escholarship.org/uc/item/5bb78905>

Journal

Dermatology Online Journal, 25(2)

Authors

Bouceiro-Mendes, R
Ortins-Pina, A
Fraga, A
et al.

Publication Date

2019

License

<https://creativecommons.org/licenses/by-nc-nd/4.0/> 4.0

Peer reviewed

Mycobacterium marinum lymphocutaneous infection

R Bouceiro-Mendes¹, A Ortins-Pina¹, A Fraga¹, T Marques², M Viveiros³, D Machado³, L Soares-de-Almeida^{1,4}, JP Freitas¹, P Filipe^{1,4}

Affiliations: ¹Dermatology Department, Centro Hospitalar Lisboa Norte, Hospital de Santa Maria, Lisbon, Portugal, ²Infectious Diseases Department, Centro Hospitalar Lisboa Norte, Hospital de Santa Maria, Lisbon, Portugal, ³Global Health and Tropical Medicine, GHTM, Instituto de Higiene e Medicina Tropical, IHMT, Universidade Nova de Lisboa, UNL, Lisboa, Portugal, ⁴Unit of Research in Dermatology, Institute of Molecular Medicine, Faculty of Medicine, University of Lisbon, Portugal

Corresponding Author: Address: Rita Bouceiro Mendes, Hospital de Santa Maria – Serviço de Dermatologia Piso 5, Avenida Prof. Egas Moniz, 1649-035 Lisboa, Portugal, Tel: 351 96 9928106, Email: rita.bouceiro.mendes@gmail.com

Abstract

Mycobacterium marinum is a nontuberculous mycobacterial species with worldwide distribution that lives in fresh or salt water and is responsible for infections in fish, and sometimes in humans. Human disease consists mainly of cutaneous nodules, but deep structure involvement may also occur. Diagnosis of *M. marinum* infection remains a challenge, with a considerable time delay between onset of symptoms and diagnosis. We present a 33-year-old man with no immunosuppressive history who was seen in our department with skin nodules over his hand and forearm, distributed in a sporotrichoid pattern. His hobbies included maintaining an aquarium of tropical fish. Histological examination of the patient's skin biopsy was compatible with the diagnosis of mycobacterial infection, and the Ziehl-Neelsen staining revealed acid-fast bacilli. Molecular techniques confirmed the suspicion of *M. marinum* infection. A necropsy was performed on one of the patient's fish, more specifically, a *Poecilia reticulata*, and resulted in identification of *M. marinum* from its gut. The patient was treated with clarithromycin, ethambutol, and rifampicin for 9 months, with clearance of infection.

Keywords: *Mycobacterium marinum*, skin infection, sporotrichoid pattern

Introduction

Mycobacterium marinum is a nontuberculous mycobacteria species (NTM) with worldwide

distribution that lives in fresh or salt water. It causes infections in fish and can also cause opportunistic infections in humans [1-4]. Human disease produces nodular or ulcerating skin lesions, occurring mainly over the extremities (especially fingers and bony prominences) with onset after an incubation period of two to 6 weeks [5, 6]. A sporotrichoid pattern may be seen in up to one-third of the cases owing to lymphatic spread [6]. Invasive infections such as tenosynovitis, septic arthritis, and osteomyelitis are uncommon [7]. The infection has been associated with minor trauma and subsequent exposure to contaminated water or fish and there is a high incidence in aquarists [1-3, 8]. We present a case of lymphocutaneous infection caused by *M. marinum* in which microbiological studies in one fish in contact with the patient confirmed the source of the infection, thereby confirming the link between the patient's hobby and the disease.

Case Synopsis

A previously healthy 33-year-old man was examined in our department. He described a 3-month history of skin lesions consisting of painful plaques and nodules on the right hand and forearm. He recalled a minor cut in the right third fingertip one month before the symptoms' onset; the cut had spontaneously healed in two weeks. The patient first noticed tingling of the right third finger, followed by an ulcerated nodule on the laceration site and progressive finger inflammation. More lesions developed over the right upper extremity. The

symptoms worsened markedly in the post-operative period after an emergency appendectomy owing to acute appendicitis. He had previously been diagnosed with "skin infection" and underwent therapy with multiple courses of antibiotics (dicloxacillin, ciprofloxacin, and topical fusidic acid cream) with no improvement. There was no history of immunosuppression. The patient reported to have fishkeeping as a hobby and he kept dozens of tropical fish in a 200-liter tank, which he cleaned and maintained without any hand protection.

Dermatological examination revealed inflammatory signs involving the third right finger and an ulcerated nodule of the right fingertip, with abnormal granulation tissue (**Figure 1A**). Other red-to-purplish ulcerating nodules, some suppurative, were visible on the dorsal aspect of the right forearm distributed in a sporotrichoid pattern (**Figure 1B**). Satellite lymphadenopathy was palpable over the epitroclear area. He had no fever.

In view of the clinical picture, our suspected differential diagnosis included sporotrichosis, atypical mycobacteriosis, and cutaneous tuberculosis. Given the hobby-related risk factor, *M. marinum* infection was considered likely to be involved.

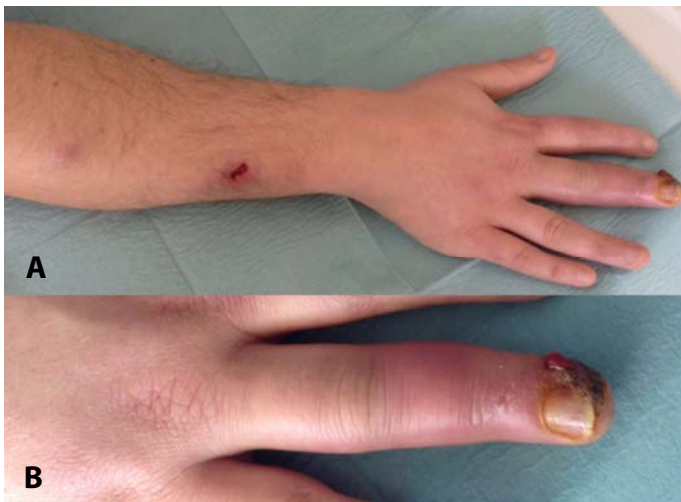

Figure 1. Clinical presentation. **A)** Inflammatory signs on the third right finger and an ulcerated nodule in fingertip are seen. **B)** Red-to-purplish ulcerating nodules on the dorsal aspect of the right forearm following a lymphocutaneous (sporotrichoid) pattern.

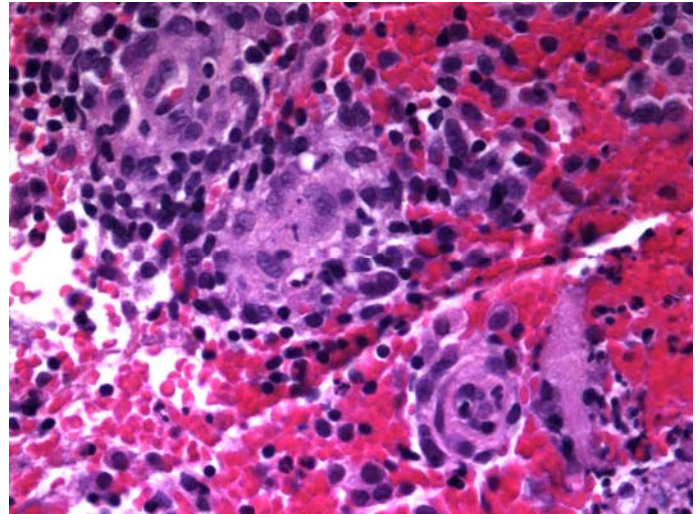


Figure 2. Histopathological features. Dermal granulomatous infiltrate with suppurative granulomas. H&E, 400x.

Routine blood test results were within normal limits. HIV, HBV, HCV, and HTLV serologies were negative. QuantiFERON-TB testing was positive but the chest X-ray did not reveal any evidence of latent or active tuberculosis. Mycological and bacteriological studies of purulent material and biopsy of one cutaneous nodule were negative, but a few acid-fast bacilli (AFB) were identified on direct examination with Ziehl-Neelsen (ZN) staining. Cultures of the exudate were negative.

Histological examination of the patient's skin biopsy revealed a dermal granulomatous inflammatory infiltrate with suppurative granulomas (**Figure 2**). PAS staining was negative and the ZN staining revealed a few AFB. Polymerase chain reaction (PCR) amplification of the highly conserved region of 16S rRNA and 439-bp *hsp65* gene performed on fresh tissue from the skin biopsy confirmed the diagnosis of *M. marinum* infection. To assess the degree of involvement of deeper structures, the patient was subjected to an X-ray and magnetic resonance imaging study of the hand, wrist, and forearm, which ruled out osteitis and tenosynovitis.

The source of the infection was confirmed by a necropsy of one of the patient's fish, more specifically a *Poecilia reticulata*, commonly known as a guppy. *M. marinum* was identified by molecular methods from the gut of the fish.

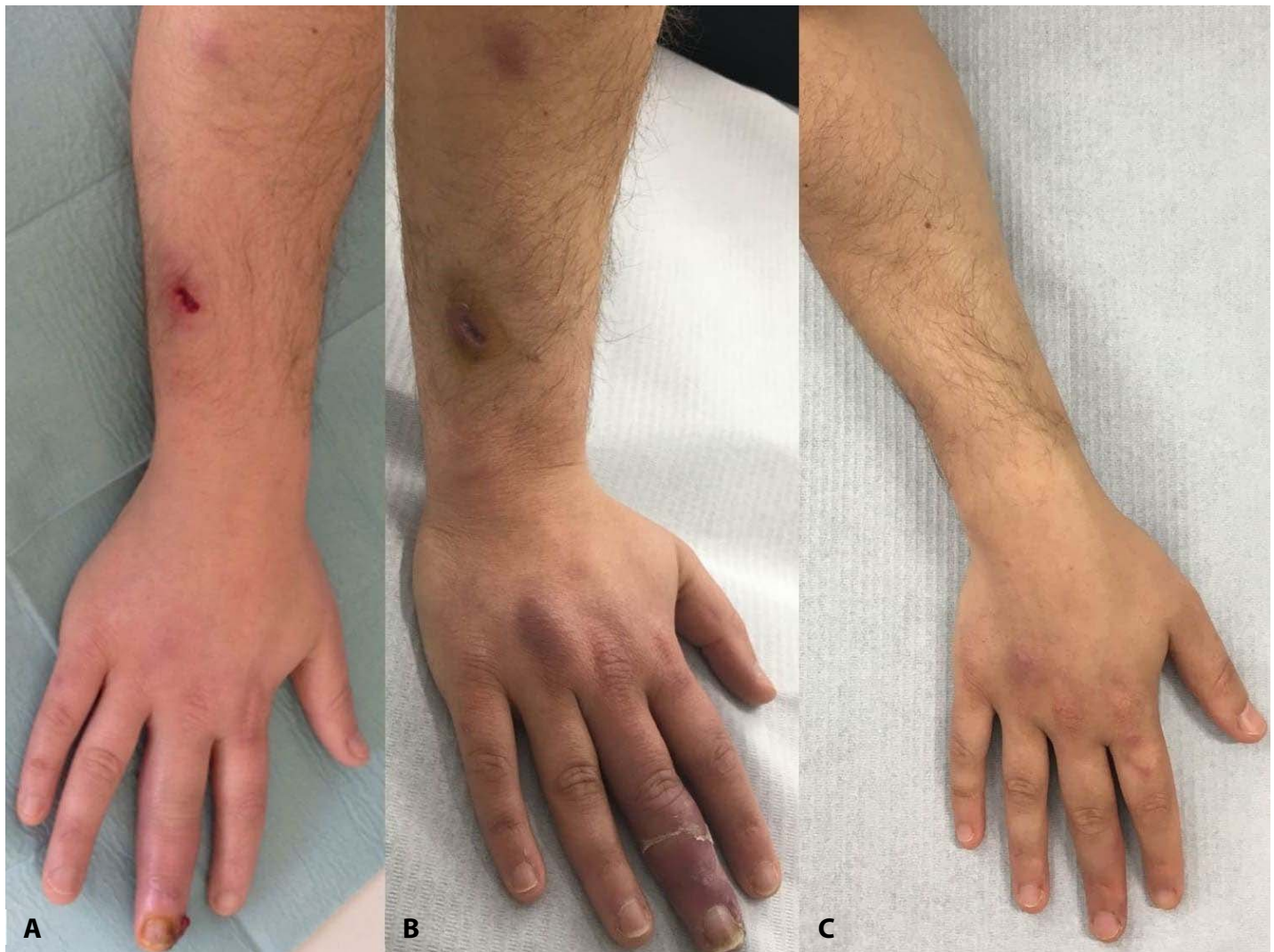

Figure 3. Clinical follow-up. **A)** Initial picture, before treatment. **B)** Two weeks after starting treatment, a significant clinical improvement is seen with clearance of the inflammatory signs. **C)** Complete resolution, by the end of the treatment course.

The patient was treated with clarithromycin, 500mg twice daily, rifampicin, 600mg once a day, and ethambutol 25mg/kg once a day (1.2g a day) orally. After two weeks of therapy we observed marked remission of the infection with clearance of the inflammatory signs (**Figure 3**). The patient completed 9 months of treatment with complete clinical resolution, no sequelae, and no adverse effects (**Figure 3**).

Case Discussion

Diagnosis of *M. marinum* infection remains a challenge, with a considerable time delay between initial onset of symptoms and diagnosis [3, 4, 7, 9, 10]. A careful medical history is critical for the correct diagnosis and it should be suspected in both

immunosuppressed and immunocompetent individuals, particularly in fishermen or aquarium enthusiasts, who present with granulomatous inflammation of the upper limb after minor trauma associated with water exposure.

Besides *M. marinum*, several other mycobacterial, bacterial, fungal, protozoal, and viral infections can present in a sporotrichoid pattern. Some neoplasms (including keratoacanthomas, squamous cell carcinomas, and lymphomas) and rarely, reactive dermatoses such as Sweet syndrome can also present with skin lesions distributed in the same manner [11]. Therefore, histological examination and microbiological culture of the skin are essential for the correct diagnosis [7, 9, 11]. PCR-ELISA can be useful to speciate the organism. QuantiFERON

testing may have been positive because protein derivatives from *M. tuberculosis* share common antigens with NTM [7, 12].

There are no specific criteria or guidelines for the treatment of skin infections caused by NTM [1, 3, 5, 10], but the 2007 recommendations of the American Thoracic Society, and the Infectious Diseases Society of America (ATS/IDSA) are universally followed [13]. The prognosis of fish tank granuloma is favorable as long as it is appropriately treated before deep soft tissue and/or bone involvement develop [13, 14]. Generally, the skin infection is curable with a combination of antimycobacterial agents, including clarithromycin, ethambutol, and/or rifampicin [4, 5]. According to the ATS/IDSA statement and recommendations, a reasonable approach is to treat with two active antibiotics for one-to-two months after resolution of symptoms. Clarithromycin and ethambutol are likely to provide the optimal balance of efficacy and tolerability for most patients, with the addition of rifampin in cases of deep structures infection [13, 14]. In our case, we decided to add rifampin since identification of the mycobacteria was not immediately available at the time of the clinical diagnosis. Susceptibility testing is not routinely recommended and should be reserved for patients who remain culture positive after several months of therapy; surgical debridement may be indicated for disease involving closed spaces of the hand and when standard therapy has failed [13].

The prevalence of *Mycobacterium spp.* in ornamental fish has been reported as high as 47% [8, 15]. This

case illustrates the need for adequate personal protective equipment, mainly for the hands of fish tank keepers.

Mycobacterial identification using PCR amplifications is an accurate and rapid technique for identification of *M. marinum* in fish [16]. The demonstration of the source of infection helps patients to understand their disease and fully acknowledge the importance of their role in active prevention. Diseased fish exhibit clinical signs [16], but there is no specific treatment and destruction of all affected stocks and disinfection of fish tanks (with ethanol, Lysol, or sodium chlorite) is absolutely required [8].

Conclusion

The diagnosis of *M. marinum* infection is difficult and it should be suspected in patients with skin infections that fail to respond to antibiotics active against streptococci and staphylococci, particularly when there is a history of water or fish exposure. DNA-specific PCR amplification is an accurate and rapid technique for identification of *M. marinum* in human tissue and fish. Our case highlights the importance of personal protective equipment, mainly gloves, in fish tank keepers to prevent these infections.

Potential conflicts of interest

The authors declare no conflicts of interests.

References

1. Bhambri S, Bhambri A, Del Rosso JQ. Atypical Mycobacterial Cutaneous Infections. *Dermatologic Clin.* 2009;27(1):63-73. [PMID: 18984369].
2. Veraldi S, Molle M, Nazzaro G. Eczema-like fish tank granuloma: A new clinical presentation of *Mycobacterium marinum* infection. *J Eur Acad Dermatol Venereol.* 2017;32(5):e200-e201. [PMID: 29194791].
3. Wu TS, Chiu CH, Yang CH, Leu HS, Huang CT, Chen YC, Wu TL, Chang PY, Su LH, Kuo AJ, Chia JH, Lu CC, Lai HC. Fish Tank Granuloma Caused by *Mycobacterium marinum*. *PLoS ONE.* 2012;7(7): e41296. [PMID: 22911774].
4. Cheung JP-Y, Fung B, Wong SS-Y, Ip W-Y. Review Article: *Mycobacterium Marinum* Infection of the Hand and Wrist. *J Orthop Surg.* 2010;18(1):98-103. [PMID: 20427845].
5. Timoney I, Lynch M, Timoney L, Feeney E, Kirby B. *Mycobacterium marinum* infection contracted from seaweed wrap in a psoriasis patient undergoing treatment with adalimumab. *Dermatol Online J.* 2017;23(8). [PMID: 29469748].
6. Sridhar J, Deo R. Marine and Other Aquatic Dermatoses. *Indian J Dermatol.* 2017;62(1):66-78. [PMID: 28216728].
7. Avneri L, Eidlitz-Markus T, Mor M, Zeharia A, Amir J, Haimi-Cohen Y. *Mycobacterium marinum*: a rare cause of chronic lymphocutaneous syndrome. *Eur J of Pediatr.* 2018;177(9):1389-1393. [PMID: 29411142].
8. Hashish E, Merwad A, Elgaml S, Amer A, Kamal H, Elsadek A, Marei A, Sitohy. M. *Mycobacterium marinum* infection in fish and man: epidemiology, pathophysiology and management: a review. *Vet Q.* 2018;38(1):35-46. [PMID: 29493404].
9. Steinbrink J, Alexis M, Angulo-Thompson D, Ramesh M, Alangaden G, Miceli M. *Mycobacterium marinum* remains an unrecognized cause of indolent skin infections. *Cutis.* 2017;100(5):331-336. [PMID: 29232419].

10. Veronese F, Zavattaro E, Farinelli P, Colombo E, Savoia P. An unusual cutaneous infection caused by *Mycobacterium marinum*. *JMM Case Rep*. 2017;4(4):e005088. [PMID: 29026615].
11. Abudu B, Cohen PR. Sporotrichoid Keratoacanthomas: Case Report and Review of Neoplasms Presenting in a Sporotrichoid Pattern. *Cureus*. 2018;10(8):e3196. [PMID: 30402364].
12. Sim E, Li J, Williams R, Pan Y, Mohamed M, Aboltins C, H Chong A. Two cases of occupationally acquired *Mycobacterium marinum* infection in Chinese restaurant workers in Melbourne, Australia. *Australas J Dermatol*. 2018;59(3):231-232. [PMID: 29076528].
13. Griffith DE, Aksamit T, Brown-Elliott BA, Catanzaro A, Daley C, Gordin F, Holland SM, Horsburgh R, Huitt G, Iademarco MF, Iseman M, Olivier K, Ruoss S, Reyn CFv, Richard J, Wallace J, Winthrop K. An Official ATS/IDSA Statement: Diagnosis, Treatment, and Prevention of Nontuberculous Mycobacterial Diseases. *Am J Respir Crit Care Med*. 2007;175(4):367-416. [PMID: 17277290].
14. Balagué N, Uçkay I, Vostrel P, Hinrikson H, Van Aaken I, Beaulieu JY. Non-tuberculous mycobacterial infections of the hand. *Chir Main*. 2015;34(1):18-23. [PMID: 25579828].
15. Zanoni RG, Florio D, Fioravanti ML, Rossi M, Prearo M. Occurrence of *Mycobacterium* spp. in ornamental fish in Italy. *J Fish Dis*. 2008;31(6):433-41. [PMID: 18471099].
16. Puk K, Banach T, Wawrzyniak A, Adaszek Ł, Ziętek J, Winiarczyk S, Guz L. Detection of *Mycobacterium marinum*, *M. peregrinum*, *M. fortuitum* and *M. abscessus* in aquarium fish. *J Fish Dis*. 2018;41(1):153-6. [PMID: 28699669].