

UCLA

UCLA Previously Published Works

Title

Magnetic Resonance Imaging characteristics in case of TOR1AIP1 muscular dystrophy.

Permalink

<https://escholarship.org/uc/item/5bb9q6tr>

Authors

Bhatia, Aashim
Mobley, Bret C
Cogan, Joy
et al.

Publication Date

2019-11-01

DOI

10.1016/j.clinimag.2019.06.010

Peer reviewed



Published in final edited form as:

Clin Imaging. 2019 ; 58: 108–113. doi:10.1016/j.clinimag.2019.06.010.

Magnetic Resonance Imaging characteristics in case of TOR1AIP1 muscular dystrophy

Aashim Bhatia^{a,*}, Bret C. Mobley^b, Joy Cogan^c, Mary E. Koziura^c, Elly Brokamp^c, John Phillips^d, John Newman^d, Undiagnosed Diseases Network (UDN)^e, Steven A. Moore^f, Rizwan Hamid^c, Undiagnosed Diseases Network AcostaMaria T.AdamsDavid R.AgrawalPankajAlejandroMercedes E.AllardPatrickAlveyJustinAndrewsAshleyAshleyEuan A.AzamianMahshid S.BacinoCarlos A.BademciGuneyBakerEvaBalasubramanyamAshokBaldrigeDustinBaleJimBarbouthDeborahBatzliGabriel F.Bayrak-ToydemirPinarBeggsAlan H.BejeranoGillBellenHugo J.BernsteinJonathan A.BerryGerard T.BicanAnnaBickDavid P.BirchCamille L.BivonaStephanieBohnsackJohnBonnenmannCarstenBonnerDevonBooneBraden E.BostwickBret L.BottoLorenzoBriereLauren C.BrocampEllyBrownDonna M.BrushMatthewBurkeElizabeth A.BurrageLindsay C.ButteManish J.CareyJohnCarrasquilloOlveenChangTa Chen PeterChaoHsiao-TuanClarkGary D.CoakleyTerra R.CobbanLaurel A.CoganJoy D.ColeF. SessionsColleyHeather A.CooperCynthia M.CopeHeidiCraigWilliam J.D'SouzaPrecillaDasariSurendraDavidsMariskaDayalJyoti G.Dell'AngelicaEsteban C.DharShweta U.DorraniNaghmehDorsetDaniel C.DouineEmilie D.DraperDavid D.DuncanLauraEcksteinDavid J.EmrickLisa T.EngChristine M.EstevesCeciliaEstwickTyraFernandezLilianaFerreiraCarlosFiegElizabeth L.FisherPaul G.FogelBrent L.ForghanilrmanFresardLaureGahlWilliam A.GodfreyRena A.GoldmanAlica M.GoldsteinDavid B.GourdineJean-Philippe F.GrajewskiAlanaGrodenCatherine A.GropmanAndrea L.HaendelMelissaHamidRizwanHanchardNeil A.HayesNicholeHighFrancesHolmIngrid A.HomJasonHuangAldenHuangYongIsasiRosarioJamalFarihaJiangYong-huiJohnstonJean M.JonesAngela L.KaravitiLefkotheaKelleyEmily G.KileyDanaKoellerDavid M.KohaneIsaac S.KohlerJennefer N.KrakowDeborahKorrickSusanKoziuraMaryKrierJoel B.KyleJennifer E.LalaniSeema R.LamByronLanpherBrendan C.Lanzalan R.LauC. ChristopherLazarJozefLeBlancKimberlyLeeBrendan H.LeeHaneLevittRoyLevyShawn E.LewisRichard A.LincolnSharyn A.LiuPengfeiLiuXue ZhongLooSandra K.MaasRichard L.MacnamaraEllen F.MacRaeCalum A.MaduroValerie V.MajcherskaMarta M.MalicdanMay Christine V.MamounasLaura A.ManolioTeri A.MaoRongMarkelloThomas C.MaromRonitMarthGaborMartinBeth A.MartinMartin G.Martinez-AgostoJulian A.MarwahaShrutiMayThomasMcCauleyJacobMcConkie-RosellAllynMcCormackColleen E.McCrayAlexa T.MetzThomas O.MightMatthewMorava-KoziczEvaMorettiPaolo M.MorimotoMarieMulvihillJohn J.MurdockDavid R.NathAviNelsonStan F.NewberryJ. ScottNewmanJohn H.NicholasSarah K.NovacicDonnaOglesbeeDevinOrengoJames

*Corresponding author at: Vanderbilt Children's Hospital, 2200 Children's Way, Nashville, TN 37232-9700, USA. aashimbhatia@gmail.com (A. Bhatia).

P.Pace Laura Pallais J. Carl Palmer Christina G.S.Papp Jeanette C.Parker Neil H.Phillips John A.III Posey Jennifer E.Postlethwait John H.Potocki Lorraine Pusey Barbara N.Quinlan Aaron Raja Archana N.Renteria Genecee Reuter Chloe M.Rives Lynette Robertson Amy K.Rodan Lance H.Rosenfeld Jill A.Rowley Robb K.Ruzhnikov Maura Sacco Ralph Sampson Jacinda B.Samson Susan L.Saporta Mario Schaechter Judy Schedl Timothy Schoch Kelly Scott Daryl A.Shakachite Lisa Sharma Prashant Shashi Vandana Shields Kathleen Shin Jimann Signer Rebecca Sillari Catherine H.Silverman Edwin K.Sinsheimer Janet S.Sisco Kathy Smith Kevin S.Solnica-Krezel Lilianna Spillmann Rebecca C.Stoler Joan M.Stong Nicholas Sullivan Jennifer A.Sutton Shirley Sweetser David A.Tabor Holly K.Tamburro Cecelia P.Tan Queenie K.-G.Tekin Mustafa Telischi Fred Thorson Willa Tifft Cynthia J.Toro Camilo Tran Alyssa A.Urv Tiina K.Velinder Matt Viskochil Dave Vogel Tiphonie P.Wahl Colleen E.Walley Nicole M.Walsh Chris A.Walker Melissa Wambach Jennifer Wan Jijun Wang Lee-kai Wangler Michael F.Ward Patricia A.Waters Katrina M.Webb-Robertson Bobbie-Jo M.Wegner Daniel Westerfield Monte Wheeler Matthew T.Wise Anastasia L.Wolfe Lynne A.Woods Jeremy D.Worthey Elizabeth A.Yamamoto Shinya Yang John Yoon Amanda J.Yu Guoyun Zastrow Diane B.Zhao Chunli Zuchner Stephan

^aDepartment of Radiology, Vanderbilt University Medical Center, Nashville, TN, USA

^bPathology, Vanderbilt University Medical Center, Nashville, TN, USA

^cPediatrics, Vanderbilt University Medical Center, Nashville, TN, USA

^dInternal Medicine, Vanderbilt University Medical Center, Nashville, TN, USA

^eDepartment of Biological Sciences, Vanderbilt University Nashville, TN, USA

^fDepartment of Pathology, The University of Iowa, Iowa City, IA, USA

Abstract

Mutations in the torsinA-interacting protein 1 (TOR1AIP1) gene result in a severe muscular dystrophy with minimal literature in the pediatric population. We review a case of *TOR1AIP1* gene mutation in a 16-year-old Caucasian female with a long history of muscle weakness. Extensive clinical workup was performed and MRI at time of initial presentation demonstrated no significant muscular atrophy with heterogenous STIR hyperintensity of the lower extremity muscles. MRI findings seven years later included extensive atrophy of the lower extremities, with severe progression, including the gluteal muscles, iliopsoas, rectus femoris, and obturator internus. There was also significant atrophy of the rectus abdominis and internal and external oblique muscles, and iliacus muscles. The MRI findings showed more proximal involvement of lower extremities and no atrophy of the tibialis anterior, making *TOR1AIP1* the more likely genetic cause. Muscle biopsy findings supported *TOR1AIP1* limb-girdle muscular dystrophy. Though rare, TOR1AIP1 gene mutation occurs in pediatric patients and MRI can aid in diagnosis and help differentiate from other types of muscular dystrophy. Genetic and pathology workup is also crucial to accurate diagnosis and possible treatment of these patients.

Keywords

TorsinA-interacting protein 1 (TOR1AIP1); MRI; Muscular dystrophy

1. Introduction

Muscular dystrophies are a heterogeneous group of hereditary muscle disorders with progressive muscular degeneration and weakness. Genetic analyses have been able to identify new causes of muscular dystrophy with a lack of associated radiological findings in the literature [1,2]. Mutations in the torsinA-interacting protein 1 (TOR1AIP1) gene result in a severe muscular dystrophy. There is minimal literature describing this myopathy or imaging findings in the pediatric population [3–5]. We present a case of a *TOR1AIP1* gene mutation presenting to the Unknown Diagnosis Network (UDN). The patient was evaluated using a multi-disciplinary approach including genetics, pathology, and radiology, and the MRI findings helped differentiate between two possible genetic causes.

2. Case report

The patient is a 16-year-old Caucasian female with a history of progressive muscle weakness due to an unknown etiology. She was the product of a full term pregnancy born to a 22 year old mother. Development in first few years of life was reported as normal, however, she was never completely able to run or jump as expected for her age. She initially presented to Neurology at the age of 8 with gradually progressive lower extremity weakness. At that time she was unable to pull herself onto a horse, had trouble getting into and out of the car, had a waddling gait and could not throw a softball. Her CK level was elevated at 10,000. She had an extensive workup including two muscle biopsies which showed mild myopathy without inflammation, EMG studies showing irritable myopathy, and non-diagnostic genetic testing including a multigene muscular dystrophy and dystroglycanopathy panel.

MRI at time of initial presentation at the age of 10 years, demonstrated minimal atrophy of the gluteus medius and minimus muscles, otherwise, no significant atrophy of the pelvis or lower extremities, with heterogeneous STIR hyperintensity of the lower extremity muscles (Fig. 1). MRI findings at time of presentation to UDN included extensive atrophy of the lower extremities, with severe progression in seven years comparing to her initial MRI, including the gluteal muscles, iliopsoas, rectus femoris, and obturator internus (Fig. 2). There was also significant atrophy of the rectus abdominis, internal and external oblique muscles, and iliacus muscles. Within the thighs, there was significant bilateral symmetric atrophy of the medial and posterior compartments with relative sparing of the anterior compartment. Within the posterior compartment the most significant atrophy was noted within the biceps femoris and semitendinosus muscles with less involvement of the semimembranosus. Within the medial compartment, the adductor muscles and gracilis were involved. There was mild atrophy of the anterior compartment muscles including the rectus femoris and vastus intermedius, vastus lateralis, and vastus medialis. Below the knee, there was no significant atrophy. Heterogeneous T2 hyperintensity involving the muscles was

increased compared to the initial MRI. Similar signal abnormality was present within the muscles of the initial MRI thigh and pelvis seven years ago.

She was referred at the age of 14 to the Undiagnosed Diseases Network (UDN). At the time of her symptoms had progressed to an extent that she was using a wheel chair most of the time. She could still ambulate but could not walk for more than 25–50 ft and not on uneven surfaces. She had significant fatigue and tired easily. She could not manage climbing stairs and could not lift her hands above her shoulders. Her facial muscles were unaffected. Her clinical phenotype also includes dysphagia of liquids, respiratory insufficiency with decreased spirometry, vital capacity and inspiratory capacity, urinary incontinence and abnormal lactate dehydrogenase activity (> 802 U/L, normal range = 60–170 U/L), elevated hepatic enzymes (ALT > 390 U/L, normal 7–56 U/L) (AST > 208 U/L, normal 5–40 U/L), and elevated aldolase levels (> 99.5 U/L, normal = 1–14.5 U/L).

As part of her UDN evaluation she underwent whole genome sequencing (WGS). WGS analysis found a rare missense variant in *myosin heavy chain 7 (MYH7)* and compound heterozygous rare variants in the *TOR1AIP1* gene; both could explain part of her phenotypic presentation. We then proceeded with further phenotyping of the patient to determine if a rare variant in one of these candidate genes was responsible for the clinical presentation.

Muscle biopsy was done and frozen and formalin-fixed sections stained with H&E showed wide variation in fiber size due to the presence of scattered atrophic and hypertrophic fibers. Numerous muscle fibers undergoing necrosis or regeneration were observed (see Fig. 3a). Rare fibers contained rimmed vacuoles. Several small foci of perimysial and endomysial lymphocytic inflammation were also seen. The fiber type distribution appeared normal on ATPase preparations (pH 10.4 and 4.5). No ragged-red fibers were identified on Gomori trichrome stain, and endomysial fibrosis was focal and mild. None of the pathologic findings reported in *MYH7* mutation-associated myopathy [6,7], including hyaline inclusions/bodies, type I fiber predominance, or relative type I fiber smallness were seen.

Immunofluorescence studies showed normal staining for the dystrophin-glycoprotein complex, collagen VI/perlecan, merosin, and spectrin. Caveolin-3 and dysferlin were reduced at the sarcolemma and increased in the cytoplasm of some muscle fibers, a nonspecific pattern seen in a wide range of myopathies. Many fibers expressed embryonic myosin heavy chain, a marker of regeneration, and muscle fiber expression of MHC class I was multifocal. Frequent muscle fibers showed complement C5b-9 deposition at the sarcolemma. Nuclear envelope immunostains (emerin and lamin A/C) showed complex irregularities of many nuclei (Fig. 3b and c).

Ultrastructural analysis showed nuclear envelope splitting or blebbing (Fig. 3d and e). Core-like structural abnormalities were found by light microscopy on toluidine blue-stained sections, and were also seen by electron microscopy (Fig. 3f). Autophagic debris was present, sometimes associated with muscle fiber nuclei (Fig. 3e). EM also showed basal lamina duplication (Fig. 3e), a nonspecific phenomenon in myopathies with increased autophagy and complement deposition [8].

3. Discussion

The *TOR1AIP1* gene encodes lamina-associated peptide 1 (LAP1), a transmembrane protein ubiquitously expressed in the inner nuclear envelope membrane [5]. Recessive mutations in the *TOR1AIP1* gene may result in reduced expression of LAP1 in striated muscle resulting in limb-girdle muscular dystrophy type 2Y (LGMD 2Y) [3–5]. LGMD 2Y initially presents as proximal limb weakness in childhood, progressing to distal weakness with contractures, as well as cardiomyopathy and spinal rigidity in adulthood.

This case demonstrated significant atrophy involving the bilateral pelvic muscles, as well as the posterior and medial compartments of the thigh with minimal involvement of the anterior compartment of the thigh. There was no significant atrophy of the muscles below the knee, however, there was abnormal heterogeneous signal within these muscles suggesting myositis and precursor to further atrophy.

Molecular genetic analysis by whole exome sequencing narrowed the potential causes to two candidate genes, *TOR1AIP1* and *MYH7*. Rare variants in *MYH7* can cause a number of myopathic disorders with associated muscle weakness, such as myosin storage myopathy, Laing distal myopathy, and scapuloperoneal myopathy (OMIM 608358, 255160, 181430, 160500). *MYH7* is also associated with types of cardiomyopathy (OMIM, 613426, 192600, 613426). *TOR1AIP1* can cause limb-girdle muscular dystrophy type 2Y (OMIM 614512). Rare variants in *TOR1AIP1* are associated with an autosomal recessive limb girdle muscular dystrophy type 2y. The literature described *MYH7* mutations typically involving the tibialis anterior and progressing from distal to proximal involvement of the extremities [6]. The MRI findings showed more proximal involvement of lower extremities and no atrophy of the tibialis anterior, making *TOR1AIP1* the more likely genetic cause.

A diagnosis of *TOR1AIP1* limb-girdle muscular dystrophy was also supported by histopathologic features observed in the muscle biopsy. The typical features of *MYH7*-associated myopathy were absent. Instead, the histopathology was that of a necrotizing process with inflammatory changes and abnormalities of nuclear envelope morphology, findings similar to those seen in dystrophies due to mutation in the nuclear envelope protein-encoding gene LMNA [9].

4. Conclusion

Genetic testing and clinical evaluation are crucial to making accurate diagnoses in patients with muscular dystrophies. Radiology also plays an important role in describing the muscles involved and, in this case, making an essential contribution to the diagnosis of *TOR1AIP1* gene mutation.

Authors

Aashim Bhatia^{a,*}, Bret C. Mobley^b, Joy Cogan^c, Mary E. Koziura^c, Elly Brokamp^c, John Phillips^d, John Newman^d, Undiagnosed Diseases Network (UDN)^e, Steven A. Moore^f, Rizwan Hamid^c, Undiagnosed Diseases Network AcostaMaria T.AdamsDavid R.AgrawalPankajAlejandroMercedes

E.AllardPatrickAlveyJustinAndrewsAshleyAshleyEuan A.AzamianMahshid
 S.BacinoCarlos
 A.BademciGuneyBakerEvaBalasubramanyamAshokBaldrigeDustinBaleJimB
 arbouthDeborahBatzliGabriel F.Bayrak-ToydemirPinarBeggsAlan
 H.BejeranoGillBellenHugo J.BernsteinJonathan A.BerryGerard
 T.BicanAnnaBickDavid P.BirchCamille
 L.BivonaStephanieBohnsackJohnBonnenmannCarstenBonnerDevonBooneBr
 aden E.BostwickBret L.BottoLorenzoBriereLauren
 C.BrokampEllyBrownDonna M.BrushMatthewBurkeElizabeth
 A.BurrageLindsay C.ButteManish J.CareyJohnCarrasquilloOlveenChangTa
 Chen PeterChaoHsiao-TuanClarkGary D.CoakleyTerra R.CobbanLaurel
 A.CoganJoy D.ColeF. SessionsColleyHeather A.CooperCynthia
 M.CopeHeidiCraigWilliam
 J.D'SouzaPrecillaDasariSurendraDavidsMariskaDayalJyoti
 G.Dell' AngelicaEsteban C.DharShweta U.DorraniNaghmehDorsetDaniel
 C.DouineEmilie D.DraperDavid D.DuncanLauraEcksteinDavid J.EmrickLisa
 T.EngChristine
 M.EstevesCeciliaEstwickTyraFernandezLilianaFerreiraCarlosFiegElizabeth
 L.FisherPaul G.FogelBrent L.ForghanilrmanFresardLaureGahlWilliam
 A.GodfreyRena A.GoldmanAlica M.GoldsteinDavid B.GourdineJean-Philippe
 F.GrajewskiAlanaGrodenCatherine A.GropmanAndrea
 L.HaendelMelissaHamidRizwanHanchardNeil
 A.HayesNicholeHighFrancesHolmIngrid
 A.HomJasonHuangAldenHuangYongIsasiRosarioJamalFarihaJiangYong-
 huiJohnstonJean M.JonesAngela L.KaravitiLefkotheaKelleyEmily
 G.KileyDanaKoellerDavid M.Kohanelisaac S.KohlerJennefer
 N.KrakowDeborahKorrickSusanKoziuraMaryKrierJoel B.KyleJennifer
 E.LalaniSeema R.LamByronLanpherBrendan C.Lanzalan R.LauC.
 ChristopherLazarJozefLeBlancKimberlyLeeBrendan
 H.LeeHaneLevittRoyLevyShawn E.LewisRichard A.LincolnSharyn
 A.LiuPengfeiLiuXue ZhongLooSandra K.MaasRichard L.MacnamaraEllen
 F.MacRaeCalum A.MaduroValerie V.MajcherskaMarta M.MalicdanMay Christine
 V.MamounasLaura A.ManolioTeri A.MaoRongMarkelloThomas
 C.MaromRonitMarthGaborMartinBeth A.MartinMartin G.Martinez-AgostoJulian
 A.MarwahaShrutiMayThomasMcCauleyJacobMcConkie-
 RosellAilynMcCormackColleen E.McCrayAlexa T.MetzThomas
 O.MightMatthewMorava-KoziczEvaMorettiPaolo
 M.MorimotoMarieMulvihillJohn J.MurdockDavid R.NathAviNelsonStan
 F.NewberryJ. ScottNewmanJohn H.NicholasSarah
 K.NovacicDonnaOglesbeeDevinOrengoJames P.PaceLauraPallaisJ.
 CarlPalmerChristina G.S.PappJeanette C.ParkerNeil H.PhillipsJohn
 A.IIIPoseyJennifer E.PostlethwaitJohn H.PotockiLorrainePuseyBarbara
 N.QuinlanAaronRajaArchana N.RenteriaGeneceeReuterChloe
 M.RivesLynetteRobertsonAmy K.RodanLance H.RosenfeldJill A.RowleyRobb
 K.RuzhnikovMauraSaccoRalphSampsonJacinda B.SamsonSusan

L. Saporta Mario Schaechter Judy Schedl Timothy Schoch Kelly Scott Daryl
A. Shakachite Lisa Sharma Prashant Shashi Vandana Shields Kathleen Shin Jimann
Signer Rebecca Sillari Catherine H. Silverman Edwin K. Sinsheimer Janet
S. Sisco Kathy Smith Kevin S. Solnica-Krezel Lilianna Spillmann Rebecca
C. Stoler Joan M. Stong Nicholas Sullivan Jennifer A. Sutton Shirley Sweetser David
A. Tabor Holly K. Tamburro Cecelia P. Tan Queenie K.-
G. Tekin Mustafa Telischi Fred Thorson Willa Tiff Cynthia J. Toro Camilo Tran Alyssa
A. Urv Tiina K. Velinder Matt Viskochil Dave Vogel Tiphany P. Wahl Colleen
E. Walley Nicole M. Walsh Chris
A. Walker Melissa Wambach Jennifer Wan Jijun Wang Lee-kai Wangler Michael
F. Ward Patricia A. Waters Katrina M. Webb-Robertson Bobbie-Jo
M. Wegner Daniel Westerfield Monte Wheeler Matthew T. Wise Anastasia
L. Wolfe Lynne A. Woods Jeremy D. Worthey Elizabeth
A. Yamamoto Shinya Yang John Yoon Amanda J. Yu Guoyun Zastrow Diane
B. Zhao Chunli Zuchner Stephan
 Acosta Maria T. Adams David R. Agrawal Pankaj Alejandro Mercedes
 E. Allard Patrick Alvey Justin Andrews Ashley Ashley Euan A. Azamian Mahshid S. Bacino Carlos
 A. Bademci Guney Baker Eva Balasubramanyam Ashok Baldridge Dustin Bale Jim Barbouth Debo
 rah Batzli Gabriel F. Bayrak-Toydemir Pinar Beggs Alan H. Bejerano Gill Bellen Hugo
 J. Bernstein Jonathan A. Berry Gerard T. Bican Anna Bick David P. Birch Camille
 L. Bivona Stephanie Bohnsack John Bonnenmann Carsten Bonner Devon Boone Braden
 E. Bostwick Bret L. Botto Lorenzo Briere Lauren C. Brokamp Elly Brown Donna
 M. Brush Matthew Burke Elizabeth A. Burrage Lindsay C. Butte Manish
 J. Carey John Carrasquillo Olveen Chang Ta Chen Peter Chao Hsiao-Tuan Clark Gary
 D. Coakley Terra R. Cobban Laurel A. Cogan Joy D. Cole F. Sessions Colley Heather
 A. Cooper Cynthia M. Cope Heidi Craigen William
 J. D' Souza Precilla Dasari Surendra Davids Mariska Dayal Jyoti G. Dell' Angelica Esteban
 C. Dhar Shweta U. Dorrani Naghmeh Dorset Daniel C. Douine Emilie D. Draper David
 D. Duncan Laura Eckstein David J. Emrick Lisa T. Eng Christine
 M. Esteves Cecilia Estwick Tyra Fernandez Liliana Ferreira Carlos Fieg Elizabeth L. Fisher Paul
 G. Fogel Brent L. Forghani Irman Fresard Laure Gahl William A. Godfrey Rena A. Goldman Alica
 M. Goldstein David B. Gourdine Jean-Philippe F. Grajewski Alana Groden Catherine
 A. Gropman Andrea L. Haendel Melissa Hamid Rizwan Hanchard Neil
 A. Hayes Nichole High Frances Holm Ingrid
 A. Hom Jason Huang Alden Huang Yong Isasi Rosario Jamal Fariha Jiang Yong-hui Johnston Jean
 M. Jones Angela L. Karaviti Lefkothea Kelley Emily G. Kiley Dana Koeller David M. Kohane Isaac
 S. Kohler Jennefer N. Krakow Deborah Korrick Susan Koziura Mary Krier Joel B. Kyle Jennifer
 E. Lalani Seema R. Lam Byron Lanpher Brendan C. Lanza Ian R. Lau C.
 Christopher Lazar Jozef LeBlanc Kimberly Lee Brendan H. Lee Hane Levitt Roy Levy Shawn
 E. Lewis Richard A. Lincoln Sharyn A. Liu Pengfei Liu Xue Zhong Loo Sandra K. Maas Richard
 L. Macnamara Ellen F. MacRae Calum A. Maduro Valerie V. Majchenska Marta M. Malicdan May
 Christine V. Mamounas Laura A. Manolio Teri A. Mao Rong Markello Thomas
 C. Marom Ronit Marth Gabor Martin Beth A. Martin Martin G. Martínez-Agosto Julian
 A. Marwaha Shruti May Thomas McCauley Jacob McConkie-Rosell Allyn McCormack Colleen
 E. McCray Alexa T. Metz Thomas O. Might Matthew Morava-Kozicz Eva Moretti Paolo

M.MorimotoMarieMulvihillJohn J.MurdockDavid R.NathAviNelsonStan F.NewberryJ. ScottNewmanJohn H.NicholasSarah K.NovacicDonnaOglesbeeDevinOrengoJames P.PaceLauraPallaisJ. CarlPalmerChristina G.S.PappJeanette C.ParkerNeil H.PhillipsJohn A.IIIPoseyJennifer E.PostlethwaitJohn H.PotockiLorrainePuseyBarbara N.QuinlanAaronRajaArchana N.RenteriaGeneceeReuterChloe M.RivesLynetteRobertsonAmy K.RodanLance H.RosenfeldJill A.RowleyRobb K.RuzhnikovMauraSaccoRalphSampsonJacinda B.SamsonSusan L.SaportaMarioSchaechterJudySchedlTimothySchochKellyScottDaryl A.ShakachiteLisaSharmaPrashantShashiVandanaShieldsKathleenShinJimannSignerRebecca SillariCatherine H.SilvermanEdwin K.SinsheimerJanet S.SiscoKathySmithKevin S.Solnica-KrezelLiliannaSpillmannRebecca C.StolerJoan M.StongNicholasSullivanJennifer A.SuttonShirleySweetserDavid A.TaborHolly K.TamburroCecelia P.TanQueenie K.-G.TekinMustafaTelischiFredThorsonWillaTiffiTiffanyCynthia J.ToroCamiloTranAlyssa A.UrvTiina K.VelinderMattViskochilDaveVogelTiphonie P.WahlColleen E.WalleyNicole M.WalshChris A.WalkerMelissaWambachJenniferWanJijunWangLee-kaiWanglerMichael F.WardPatricia A.WatersKatrina M.Webb-RobertsonBobbie-Jo M.WegnerDanielWesterfieldMonteWheelerMatthew T.WiseAnastasia L.WolfeLynne A.WoodsJeremy D.WortheyElizabeth A.YamamotoShinyaYangJohnYoonAmanda J.YuGuoyunZastrowDiane B.ZhaoChunliZuchnerStephan

Affiliations

^aDepartment of Radiology, Vanderbilt University Medical Center, Nashville, TN, USA

^bPathology, Vanderbilt University Medical Center, Nashville, TN, USA

^cPediatrics, Vanderbilt University Medical Center, Nashville, TN, USA

^dInternal Medicine, Vanderbilt University Medical Center, Nashville, TN, USA

^eDepartment of Biological Sciences, Vanderbilt University Nashville, TN, USA

^fDepartment of Pathology, The University of Iowa, Iowa City, IA, USA

Acknowledgments

Grant support: U01HG007674. Muscular Dystrophy Cooperative Research Center U54, NS053672.

References

- [1]. Díaz-Manera J, Llauger J, Gallardo E, Illa I. Muscle MRI in muscular dystrophies. *Acta Myol* 2015;34(2–3):95–108. [PubMed: 27199536]
- [2]. Politano L, Nigro G. Magnetic resonance imaging in muscular dystrophies. *Acta Myol* 2015;34(2–3):93–4. [PubMed: 27199535]
- [3]. Kayman-Kurekci G, Talim B, Korkusuz P, et al. Mutation in TOR1AIP1 encoding LAP1B in a form of muscular dystrophy: a novel gene related to nuclear envelopathies. *Neuromuscul Disord* 2014;24(7):624–33. 10.1016/j.nmd.2014.04.007. [PubMed: 24856141]
- [4]. Dorboz I, Coutelier M, Bertrand AT, et al. Severe dystonia, cerebellar atrophy, and cardiomyopathy likely caused by a missense mutation in TOR1AIP1. *Orphanet J Rare Dis* 2014;9:174 10.1186/s13023-014-0174-9. [PubMed: 25425325]

- [5]. Ghaoui R, Benavides T, Lek M, et al. TOR1AIP1 as a cause of cardiac failure and recessive limb-girdle muscular dystrophy. *Neuromuscul Disord* 2016;26(8):500–3. 10.1016/j.nmd.2016.05.013. [PubMed: 27342937]
- [6]. Fiorillo C, Astrea G, Savarese M, et al. MYH7-related myopathies: clinical, histopathological and imaging findings in a cohort of Italian patients. *Orphanet J Rare Dis* 2016;11(1):91 10.1186/s13023-016-0476-1. [PubMed: 27387980]
- [7]. Tajsharghi H, Oldfors A. Myosinopathies: pathology and mechanisms. *Acta Neuropathol* 2013;125(1):3–18. 10.1007/s00401-012-1024-2. [PubMed: 22918376]
- [8]. Dowling JJ, Moore SA, Kalimo H, Minassian BA. X-linked myopathy with excessive autophagy: a failure of self-eating. *Acta Neuropathol* 2015;129(3):383–90. 10.1007/s00401-015-1393-4. [PubMed: 25644398]
- [9]. Komaki H, Hayashi YK, Tsuburaya R, et al. Inflammatory changes in infantile-onset LMNA-associated myopathy. *Neuromuscul Disord* 2011;21(8):563–8. 10.1016/j.nmd.2011.04.010. [PubMed: 21632249]

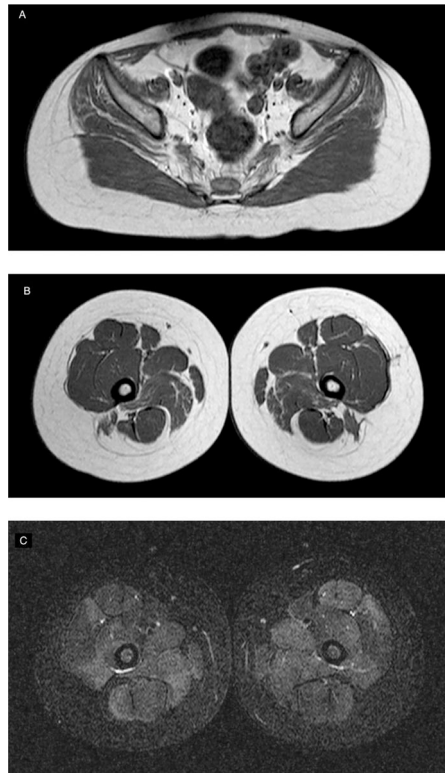

Fig. 1.
Initial presentation: MRI of the lower extremities.
Axial T1 through the pelvis (A) and lower extremities (B) show minimal atrophy of the gluteus medius and minimus muscles, otherwise, no significant atrophy of the muscles.
Axial STIR (C) at the level of the femur show heterogeneous hyperintensity throughout the muscles.

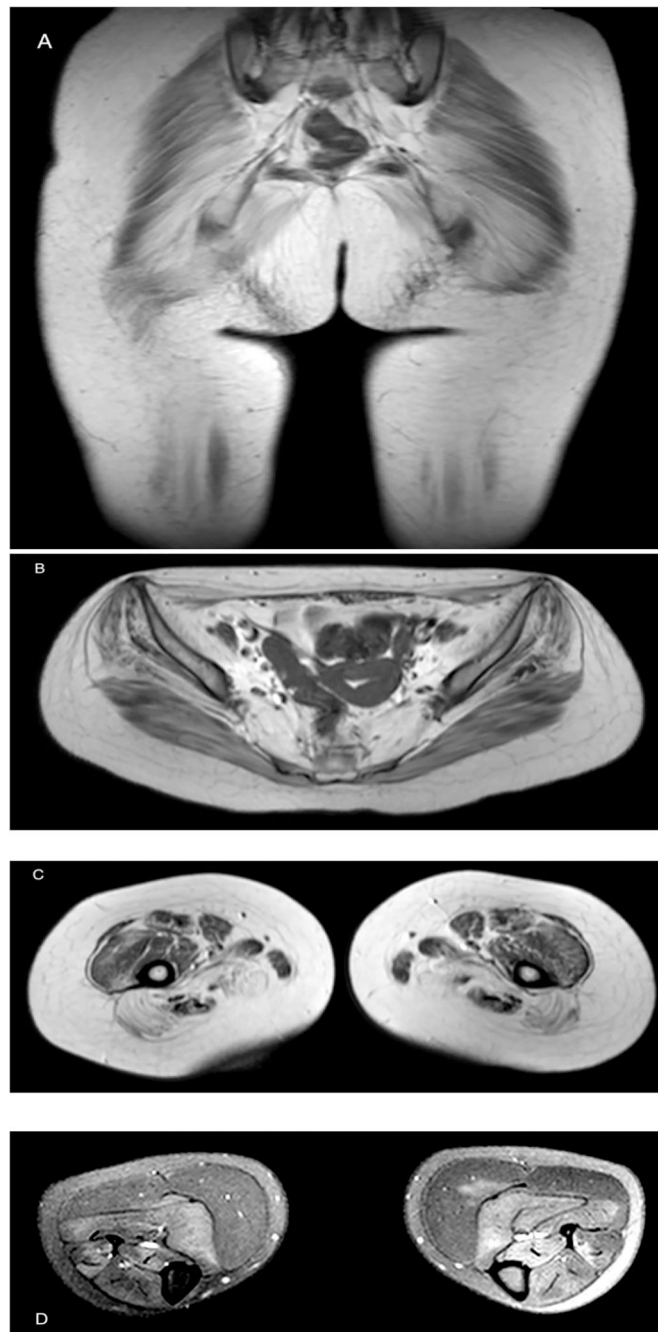


Fig. 2. MRI of the lower extremities seven years after initial presentation. MRI findings Coronal and axial T1 (A, B) show severe atrophy of the gluteal muscles, iliopsoas, rectus femoris, obturator internus, rectus abdominis and internal and external oblique muscles, iliacus muscles. (C) Axial T1 of the thighs demonstrated bilateral symmetric atrophy of the medial and posterior compartments, including biceps femoris and semitendinosus muscles with less involvement of the semimembranosus. Within the medial compartment, the adductor muscles and gracilis are involved. Mild atrophy of the anterior compartment muscles including the rectus femoris and vastus intermedius, vastus lateralis,

and vastus medialis. (D) Axial T2FS below the knee with no significant atrophy. Heterogeneous T2 hyperintensity throughout the muscles.

Author Manuscript

Author Manuscript

Author Manuscript

Author Manuscript

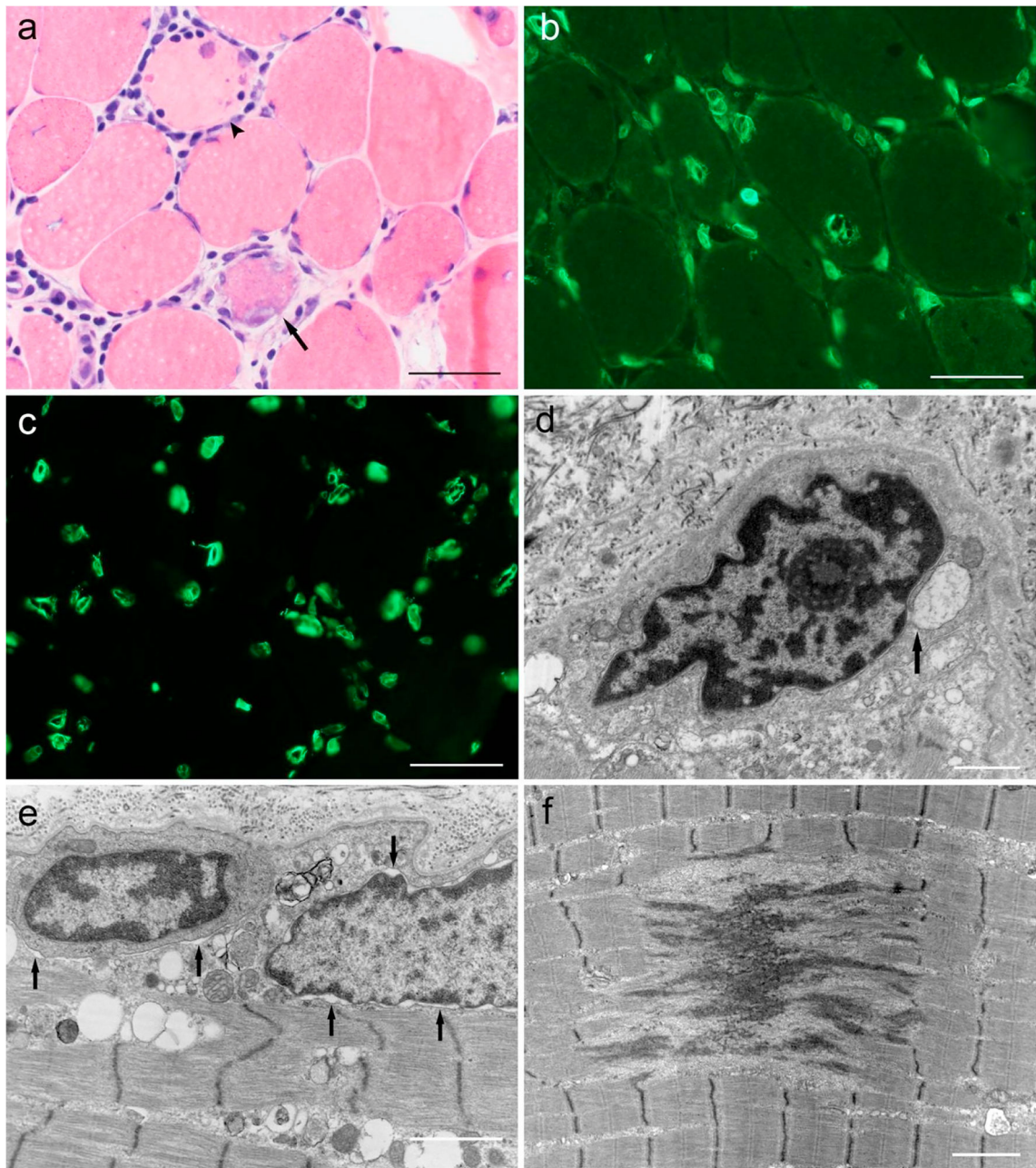


Fig. 3.
 a) Numerous muscle fibers are undergoing necrosis (arrowhead) or regeneration (arrow). Several small foci of endomysial and perimysial lymphocytic inflammation are observed (H&E cryosection, scale bar equals 50 μm). Immunofluorescence studies for the nuclear envelope proteins b) emerlin and c) lamin A/C show complex irregularities of many nuclei (scale bar equals 50 μm). Ultrastructural analysis reveals d) and e) nuclear envelope blebbing or splitting (single arrows). Perinuclear and intersarcomeric autophagic debris is present. Foci with core-like ultrastructural pathology (f) are also observed. Scale bars in electron micrographs equal 3 μm .