

# UC San Diego

## UC San Diego Previously Published Works

### Title

Distal femoral extension osteotomy and patellar tendon advancement or shortening in ambulatory children with cerebral palsy: A modified Delphi consensus study and literature review.

### Permalink

<https://escholarship.org/uc/item/5bv0f91n>

### Journal

Journal of children's orthopaedics, 16(6)

### ISSN

1863-2521

### Authors

Rutz, Erich  
Novacheck, Tom F  
Dreher, Thomas  
[et al.](#)

### Publication Date

2022-12-01

### DOI

10.1177/18632521221137391

Peer reviewed

# Distal femoral extension osteotomy and patellar tendon advancement or shortening in ambulatory children with cerebral palsy: A modified Delphi consensus study and literature review

Erich Rutz<sup>1</sup>, Tom F Novacheck<sup>2</sup>, Thomas Dreher<sup>3</sup>, Jon R Davids<sup>4</sup> , James McCarthy<sup>5</sup>, Robert M Kay<sup>6</sup> , Benjamin J Shore<sup>7</sup>, M Wade Shrader<sup>8</sup>, Matthew Veerkamp<sup>9</sup>, Hank Chambers<sup>10</sup>, Unni Narayanan<sup>11</sup>, Kristan Pierz<sup>12</sup>, Jason Rhodes<sup>13</sup>, Jeffrey Shilt<sup>14</sup>, Tim Theologis<sup>15</sup>, Anja Van Campenhout<sup>16</sup>, and Kerr Graham<sup>1</sup>

## Abstract

**Purpose:** In children with cerebral palsy, flexion deformities of the knee can be treated with a distal femoral extension osteotomy combined with either patellar tendon advancement or patellar tendon shortening. The purpose of this study was to establish a consensus through expert orthopedic opinion, using a modified Delphi process to describe the surgical indications for distal femoral extension osteotomy and patellar tendon advancement/patellar tendon shortening. A literature review was also conducted to summarize the recent literature on distal femoral extension osteotomy and patellar tendon shortening/patellar tendon advancement.

**Method:** A group of 16 pediatric orthopedic surgeons, with more than 10 years of experience in the surgical management of children with cerebral palsy, was established. The group used a 5-level Likert-type scale to record agreement or disagreement with statements regarding distal femoral extension osteotomy and patellar tendon advancement/patellar tendon shortening. Consensus for the surgical indications for distal femoral extension osteotomy and patellar tendon advancement/patellar tendon shortening was achieved through a modified Delphi process. The literature review, summarized studies of clinical outcomes of distal femoral extension osteotomy/patellar tendon shortening/patellar tendon advancement, published between 2008 and 2022.

**Results:** There was a high level of agreement with consensus for 31 out of 44 (70%) statements on distal femoral extension osteotomy. Agreement was lower for patellar tendon advancement/patellar tendon shortening with consensus reached for 8 of 21 (38%) of statements. The literature review included 25 studies which revealed variation in operative

<sup>1</sup>Department of Orthopaedic Surgery, The Royal Children's Hospital Melbourne, Parkville, VIC, Australia

<sup>2</sup>Gillette Children's Specialty Healthcare, Saint Paul, MN, USA

<sup>3</sup>Universitäts-Kinderspital, Zurich, Switzerland

<sup>4</sup>Shriners Hospitals for Children-Northern California, Sacramento, CA, USA

<sup>5</sup>Cincinnati Children's Hospital Medical Center, Cincinnati, OH, USA

<sup>6</sup>Children's Hospital Los Angeles, Los Angeles, CA, USA

<sup>7</sup>Boston Children's Hospital, Boston, MA, USA

<sup>8</sup>Nemours/Alfred I. duPont Hospital for Children, Wilmington, DE, USA

<sup>9</sup>Cincinnati Children's Hospital Medical Center, Cincinnati, OH, USA

<sup>10</sup>Rady Children's Hospital, San Diego, CA, USA

<sup>11</sup>The Hospital for Sick Children, Toronto, ON, Canada

<sup>12</sup>Connecticut Children's Hospital, Hartford, CT, USA

<sup>13</sup>Children's Hospital Colorado, Aurora, CO, USA

<sup>14</sup>Texas Children's Hospital, Houston, TX, USA

<sup>15</sup>Oxford University Hospitals, Oxford, England

<sup>16</sup>UZ Leuven, Leuven, Belgium

Date received: 12 August 2022; accepted: 19 October 2022

## Corresponding Author:

Erich Rutz, Department of Orthopaedic Surgery, The Royal Children's Hospital Melbourne, 50 Flemington Road, Parkville, VIC 3052, Australia; Bob Dickens Chair Paediatric Orthopaedic Surgery, Department of Paediatrics, The University of Melbourne, Melbourne, VIC, Australia. Email: [erich\\_rutz@hotmail.com](mailto:erich_rutz@hotmail.com)



technique for distal femoral extension osteotomy, patellar tendon advancement, and patellar tendon shortening. Distal femoral extension osteotomy and patellar tendon advancement/patellar tendon shortening were generally effective in correcting knee flexion deformities and extensor lag, but there was marked variation in outcomes and complication rates.

**Conclusion:** The results from this study will provide guidelines for surgeons who care for children with cerebral palsy and point to unresolved questions for further research.

**Level of evidence:** level V.

**Keywords:** Crouch gait, distal femoral extension osteotomy, patellar tendon advancement, patellar tendon shortening, modified Delphi, cerebral palsy

## Introduction

In ambulatory children with cerebral palsy (CP), crouch gait is the most common gait pathology in older children.<sup>1</sup> A recent systematic review reported that the natural history of crouch gait was for increasing knee flexion in children with spastic diplegia, over time.<sup>2</sup> A large population-based study found that knee flexion deformity may significantly impair functional mobility, as measured using the Functional Mobility Scale (FMS).<sup>3</sup>

The causes of crouch gait are complex and multifactorial.<sup>2,4</sup> Contributing factors may include weakness of the antigravity muscles, especially the soleus, hamstring spasticity and contracture, contracture of the knee joint, and lever arm deformities in the lower limbs.<sup>4,5</sup> Crouch gait is part of the natural history in some children with spastic diplegia but lengthening of the Achilles' tendons may also be a precipitating factor.<sup>6</sup> Conservative gastrocnemius lengthening (GSL) in Zone 1, in the context of multilevel surgery (MLS), may substantially reduce the risk of iatrogenic crouch gait.<sup>6,7</sup>

In ambulant children with diplegia, knee flexion usually increases slowly during childhood and then more dramatically during the pubertal growth spurt.<sup>2,4,5,8</sup> This may be related to increases in body mass index (BMI) outstripping reserves of muscle strength to maintain upright posture.<sup>3,4,8</sup> The overload of the extensor mechanism may result in anterior knee pain, stress lesions in the patellae, and fatigue fractures.<sup>8</sup> As crouch gait increases, kinematic and kinetic gait parameters deteriorate, the Gait Profile Score (GPS) increases, and deterioration in the FMS may indicate increasing dependence on assistive devices such as crutches or walkers.<sup>2,6,8</sup> Progression of untreated crouch gait in spastic diplegia is illustrated in Figure 1. These are sequential captures of the ground reaction force (GRF), overlaid on a skeletal model, of a girl with spastic diplegia, Gross Motor Function Classification System (GMFCS) II, who attended the Motion Analysis Laboratory over a 4-year period, from age 8–12 years with no surgical intervention. Surgery was delayed because of multiple factors including the COVID-19 pandemic. The principal features included increasing knee flexion and knee pain, the GRF moving behind the knee joint axis, and progressive deterioration in knee kinematics and kinetics, GPS, and FMS.<sup>2,3,8</sup>

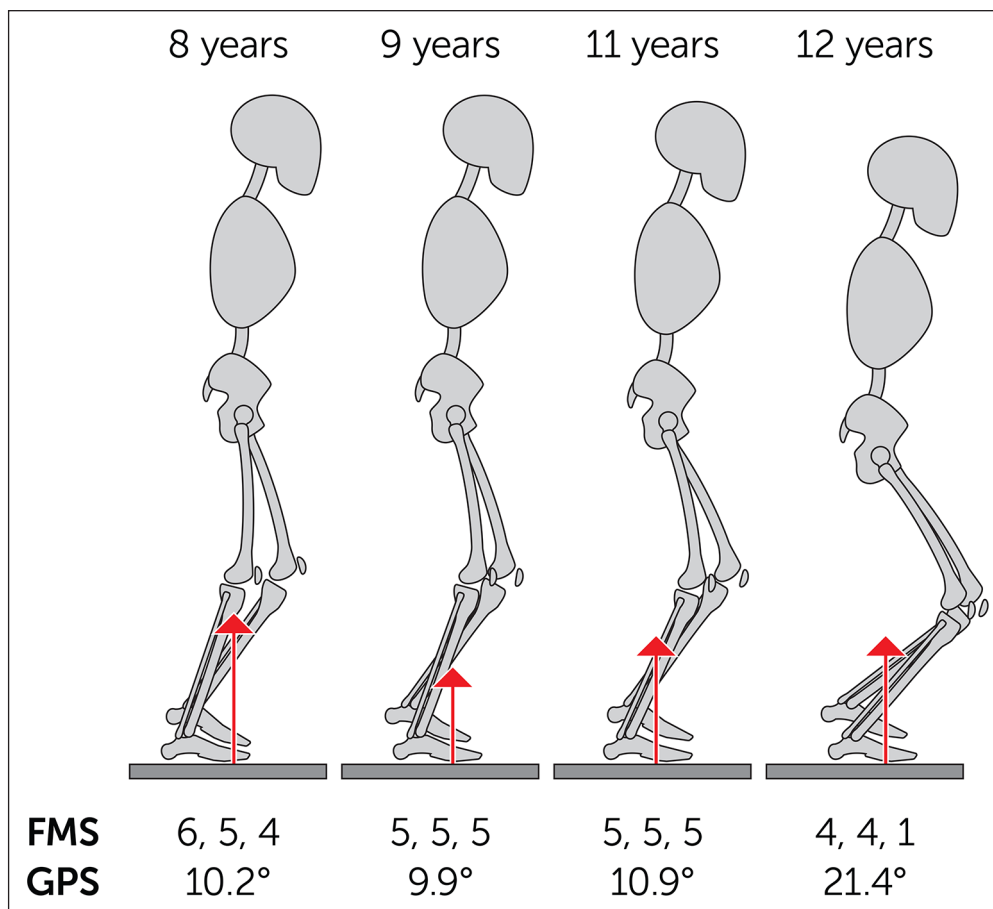
Children who lack knee extension during the stance phase of gait are usually described as having flexed knee gait or crouch gait.<sup>1–6,8,9</sup> Some reserve the term crouch gait for a gait pattern in which there is incomplete extension/excessive flexion at the hip and knee, combined with calcaneus at the ankle.<sup>9</sup> Crouch is a subset of flexed knee gait, and it may be important to recognize it as a distinct entity in a classification system because the etiology, natural history, urgency to treat, treatment options, and outcomes may differ from other types of flexed knee patterns.<sup>4,6,9,10</sup>

Previous studies have reported variation in surgical management for ambulatory children with CP, including discordant responses and knowledge-practice gaps.<sup>7</sup> Variability in decision-making might lead to inconsistent treatment recommendations, suboptimal outcomes and excessive costs to the healthcare systems.<sup>7</sup> In consideration of this background, a group of 16 orthopedic surgeons with fellowship training in pediatric orthopedics used a modified Delphi process to develop consensus guidelines for the management of various aspects of lower limb deformities in ambulatory children with CP.<sup>7,11–13</sup>

The management of flexed knee/crouch gait has been considered to be one of the more difficult problems to address and achieve consistently good long-term outcomes, in ambulatory children with CP.<sup>4,5,14</sup> The introduction of surgical techniques including transfer of the medial hamstrings to the distal femur, as well as anterior distal femoral hemiepiphysiodesis (ADFH), means that the role of distal femoral extension osteotomy (DFEO) combined with patellar tendon advancement (PTA) or patellar tendon shortening (PTS) need to be re-evaluated and better defined.<sup>12,13</sup> For this reason, our group addressed the indications and outcome assessment for DFEO and PTA/PTS, following previous studies addressing hamstring lengthening, transfer of the hamstrings to the distal femur, and the role of guided growth (ADFH) for small flexion deformities of the knee.<sup>12–14</sup>

## Research design and methods

Sixteen fellowship-trained pediatric orthopedic surgeons with expertise in three-dimensional gait analysis (3DGA) and musculoskeletal surgery for children with



**Figure 1.** These are serial screen captures of lower limb alignment and ground reaction force (GRF, vertical red arrow) overlaid on the skeletal model of a girl with spastic diplegia, GMFCS II, between 8 and 12 years, during 3DGA. She attended the Gait Laboratory on four occasions without surgical intervention. This is an illustration of the progressive nature of untreated crouch gait. The deterioration was slow initially and became rapid with the onset of the pubertal growth spurt, between 11 and 12 years. The increasing knee flexion in stance is apparent and was confirmed on kinematics. The deterioration in GPS between age 11 and 12 years was 11.5°, more than seven times the MCID. The deterioration in FMS was also dramatic with the need for a wheelchair for FMS 500m distances, by age 12 years.

CP participated in the consensus-seeking process. Group members had a mean of >20 years of experience (range=10–41 years) in the orthopedic care of children with CP and a mean of 20 years (range=7–31 years) of experience in the interpretation of clinical gait analysis. All members continued their involvement until the end of the consensus-seeking process.

The format consisted of statements in eight categories including, general issues, clinical problems/history, physical examination, imaging, 3DGA, intra-operative assessment, post-operative management, and outcome measures and goals. The sequence of questions and summarizing of responses have been described in previous publications.<sup>7,11–13</sup> We were unable to conduct face-to-face meetings during the COVID-19 pandemic. This was replaced by virtual meetings and three rounds of questions and responses. The modified Delphi process has been described in previous publications, to which the reader is referred.<sup>11–13</sup>

## Literature review

Contemporary techniques for DFEO and PTA/PTS were reported in the literature from 2008.<sup>4</sup> Since then, there has been a rapid increase in publications with variations in surgical techniques and outcome measures.<sup>4,15–22</sup> We reviewed the recent literature to summarize clinical outcomes from recent studies and to compare and contrast with the findings of the modified Delphi consensus building. We focused on studies reporting clinical outcomes of DFEO and/or PTA and/or PTS in patients with CP from 2008 to 2022. We also wanted to survey the choice of outcome measures and the prevalence of complications, especially neural injury and its prevention.<sup>23,24</sup> The search criteria, inclusion criteria, and study summaries are found in Supplemental Appendix.

## Results: modified Delphi

The results of the modified Delphi process are summarized in Tables 1–3. Consensus for agreement occurred

**Table 1.** Modified Delphi results for distal femoral extension osteotomy (Part 1).

Statement	Consensus for statement (% agree)	General agreement for statement (% agree)	No consensus for statement (% agreed, disagreed, neutral)	General disagreement against statement (% disagree)
<b>General</b>				
1. The patient must be at least 10 years or older for this surgery.	81%			
2. The patient must be able to complete the needed post-operative physical therapy.	94%			
3. Children with GMFCS V CP: DFEO has very limited indications and should be used with caution as it may result in difficulties with sitting.	100%			
4. DFEO is rarely indicated for small KFD (under 10°) and only after less invasive techniques are attempted.	94%			
5. For contractures of over 60°, the risks of surgery (DFEO) outweigh the potential benefits.	88%			
6. DFEO should not be performed for KFD over 45–50°, unless other modalities (i.e. casting/physical therapy) are used to reduce the KFD to less than 45–50° first.	81%			
7. DFEO should not be undertaken for contractures of less than 10° unless the patient is less than 2 years from skeletal maturity and all other treatment options have been exhausted.	94%			
8. For patients with severe knee flexion contractures, hamstring lengthening may be indicated to decrease the flexion contracture prior to performing DFEO.			56%, 38%, 6%	
<b>Clinical problems/history</b>				
9. Crouch gait is an indication for DFEO.	94%			
10. Decreasing ambulatory function is an indication for DFEO.	81%			
11. This surgery is indicated in GMFCS level I–III.	100%			
12. DFEO is only indicated if there is a knee flexion contracture on examination, regardless of other indications.	81%			
13. DFEO (with or without a PTA) should be performed for selected GMFCS IV patients who have lost ambulatory ability and are able to participate in extensive physical therapy in an effort to restore ambulatory function.	88%			
14. DFEO (with or without a PTA) should be performed for selected GMFCS IV patients who have KFD to help them stand and perform pivot transfers, even if there is no expectation of ambulatory function.	88%			
15. Anterior knee pain may be an indication for DFEO.	94%			
16. A avulsion fracture of the patella may be indication for DFEO.	81%			
<b>Physical examination</b>				
17. On physical exam, rotational deformity of the femur of 10° or more is a contraindication for DFEO.				100%
18. On physical exam, rotational deformity of the femur of 20° or more is a contraindication for DFEO.				88%
19. On physical exam, rotational deformity of the femur of 30° or more is a contraindication for DFEO.				81%
20. On physical exam, fixed knee contracture of 20/30° or more is an indication for DFEO.	100%			
21. DFEO is only indicated when there is a knee flexion contracture on examination, regardless of any other indications.	81%			
22. PTS/PTA should only be performed if there is an extension lag at the time of surgery (even if this occurs after a DFEO). Imaging			50%, 25%, 25%	
23. Lateral X-rays of the knee are necessary before DFEO. 3D gait analysis	94%			
24. Increased internal extension moments at the knee is one indication for PTS/PTA.		63%		

GMFCS: Gross Motor Function Classification System; CP: cerebral palsy; DFEO: distal femoral extension osteotomy; PTA: patellar tendon advancement; PTS: patellar tendon shortening; KFD: knee flexion deformities. A number is inserted in only one of the four cells or columns, reflecting the numerical results of the level of agreement from the questionnaires, and the responses of the panel to 24 statements regarding DFEO are summarized.

**Table 2.** Modified Delphi results for distal femoral extension osteotomy (Part 2).

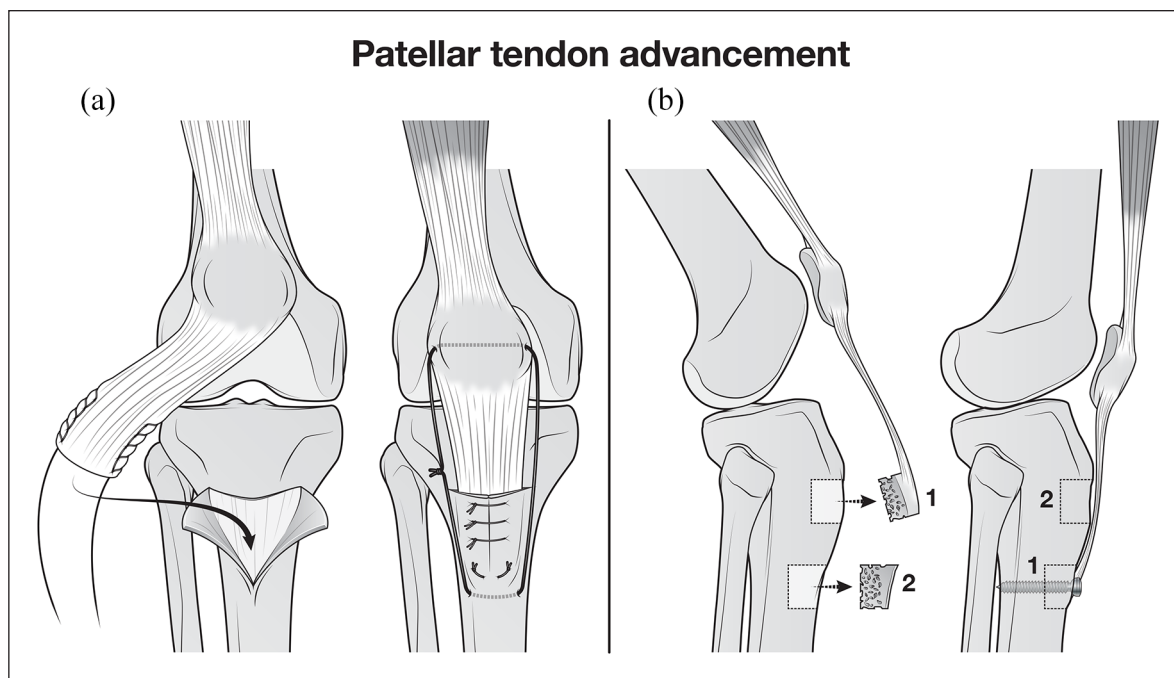
Statement	Consensus for statement (% agree)	General agreement for statement (% agree)	No consensus for statement (% agreed, disagreed, neutral)	General disagreement against statement (% disagree)
<b>Intra-operative assessment</b>				
1. Correction of rotational deformities is important to do (indicated) at the time of DFEO surgery.	94%			
2. Correction of pes planus is important to do (indicated) at the time of DFEO surgery.	88%			
3. Large rotational deformities, generally over 40°, should be performed at a different (more proximal) location and not through the DFEO.	94%			
4. A DFEO should rarely be performed without a concomitant PTA/PTS, and always if the DFEO incorporates femoral shortening.	94%			
5. I typically perform a shortening osteotomy (trapezoidal bone resection) when performing DFEO.	94%			94%
6. I typically do NOT perform a shortening of the femur when performing DFEO.				
7. I rarely (if ever) perform a pure shortening femoral osteotomy to address a fixed knee flexion contracture.	82%			
8. I rarely (if ever) perform a distal rectus femoris transfer at the time of DFEO.	82%			
9. I typically use regional anesthesia for DFEO surgery.			56%, 31%, 13%	
10. I typically use an epidural catheter for post-operative pain management following DFEO.		69%		
11. I rarely (if ever) use an epidural following DFEO surgery.				75%
12. Determine whether to shorten the femur at the time of extension osteotomy depending on the severity of knee flexion contracture.	82%			
<b>Post-operative</b>				
13. After a DFEO, I immobilize my patient with a cast.				100%
14. After a DFEO, I immobilize my patient with a removable brace (e.g. hinged knee brace or knee immobilizer).	82%			
15. After a DFEO, I immobilize my patient with a soft dressing (e.g. bulky Jones) following DFEO.			19%, 81%, 0%	
16. I use a continuous passive motion (CPM) machine following DFEO.			31%, 56%, 13%	
<b>Outcome measures/goals</b>				
17. I routinely assess (decreased) anterior knee pain as an outcome measure post-op for DFEO surgery.	88%			
18. I routinely use knee ROM on physical exam as an outcome measure post-op for DFEO surgery.	100%			
19. I routinely use knee extension in mid stance on 3D gait analysis as an outcome measure post-op for DFEO surgery.	94%			
20. I routinely use normalization of knee movements on 3D gait analysis as an outcome measure post-op for DFEO surgery.	88%			
21. I routinely use normalization of knee moments on 3D gait analysis as an outcome measure.		69%		

DFEO: distal femoral extension osteotomy; PTA: patellar tendon advancement; PTS: patellar tendon shortening; ROM: range of motion. The responses of the panel to an additional 21 statements regarding DFEO are summarized.

**Table 3.** Modified Delphi results for patellar tendon advancement and patellar tendon shortening statements.

Statement	Consensus for statement (% agree)	General agreement for statement (% agree)	No consensus for statement (% agreed, disagreed, neutral)	General disagreement against statement (% disagree)
<b>General</b>				
1. PTS/PTA can be performed in patients if indicated, even if a DFEO is not considered to be needed?	88%			
2. PTS/PTA is indicated in ambulatory patients (GMFCS I–III).	94%			
3. PTS/PTA is indicated in patients who demonstrate improved knee extension (regardless of how it is assessed) after a trial with solid AFOs or GRAFOs (ROUND 2).			37%, 13%, 50%	
4. PTS/PTA is indicated in non-ambulatory patients (GMFCS IV–V) (ROUND 2).			19%, 50%, 31%	
<b>Clinical problem/history</b>				
5. PTS/PTA is indicated in patients with an extension lag (defined at the difference between active and passive knee extension) of $> 10^\circ$ as determined on physical exam.	88%			
6. Significant persistent crouch recalcitrant to other measures or worsening crouch gait as determined on observation gait assessment is one indication for PTS/PTA.	94%			
7. PTS/PTA is indicated in patients with knee pain as determined from clinical history.			56%, 6%, 38%	
8. PTS/PTA is only indicated in patients with progressively worsening crouch gait (regardless of how it is assessed).			31%, 56%, 13%	
<b>Pre-operative assessment</b>				
<b>Imaging</b>				
9. PTS/PTA is indicated in patients with patella alta as determined on lateral knee radiographs.	81%			
Formal 3D gait analysis kinematics/kinetics				
10. Excessive knee flexion in stance as determined on 3D motion analysis is one indication for PTS/PTA.	81%	63%		
11. Increased internal extension moments at the knee as measured on 3D motion analysis (kinetics) is one indication for PTS/PTA.		69%		
12. PTS/PTA is indicated in patients with increased internal extension moments at the knee as measured on 3D motion analysis (kinetics).				
<b>Intra-operative assessment</b>				
13. In cases with open growth plates, I prefer to do PTS?				
14. In cases with closed growth plates, I prefer to do PTA? General disagreement (note this indicates if open growth plates all do a PTS, of closed there is a variation).	88%			63%
15. In a patient with a KFD undergoing ADFH, I will wait to perform a PTA/PTS until the KFD is corrected.		73%		
16. For skeletally mature patients, I typically perform PTA.		75%		
17. For skeletally mature patients, I typically perform PTS.				
18. A PTA/PTS can be performed at the time of ADFH if there is an extension lag.	81%			
19. A PTA/PTS can be performed at the time of ADFH even if there is not an extension lag.			20%, 47%, 33%	
20. A PTA/PTS should not be performed at the time of ADFH.				
21. PTS/PTA should only be performed if there is an extension lag at the time of surgery (even if this occurs after a DFEO).			50%, 25%, 25%	62%

DFEO: distal femoral extension osteotomy; PTA: patellar tendon advancement; PTS: patellar tendon shortening; GMFCS: Gross Motor Function Classification System; ADFH: anterior distal femoral hemiephysiodesis; AFO: ankle foot orthosis; GRAFO: ground reaction ankle foot orthosis; KFD: knee flexion deformities. The responses of the panel to 21 statements regarding PTA and PTS are summarized.



**Figure 2.** These are the techniques for PTA described by Novacheck and colleagues for skeletally immature patients (a) and skeletally mature patients (b).<sup>15</sup> In (a), the patellar tendon is carefully divided with attention to avoiding injury to the growth cartilage of the tibial tuberosity. In (b), the insertion of the patellar tendon is mobilized and moved distally on a bone block and fixed with a compression screw. In both cases, the PTA is protected by a FiberTape (Arthrex, Inc., Naples, FL, USA) loop inserted through drill holes in the patella and proximal tibia (for a full description, see reference Stout et al.<sup>4</sup> and Novacheck et al.<sup>15</sup>).

when at least 80% of the panel selected one of the highest two responses on the 5-point Likert-type scale (strongly agree or agree). Consensus for disagreement occurred when at least 80% of the panel selected one of the lowest two responses (strongly disagree or disagree). General agreement occurred when 60%–79% chose one of the highest two responses, and general disagreement if 60%–79% chose one of the lowest two responses (general agreement or general disagreement). There was no consensus if fewer than 60% of the panel responses were in either the highest or lowest two categories for a given statement.

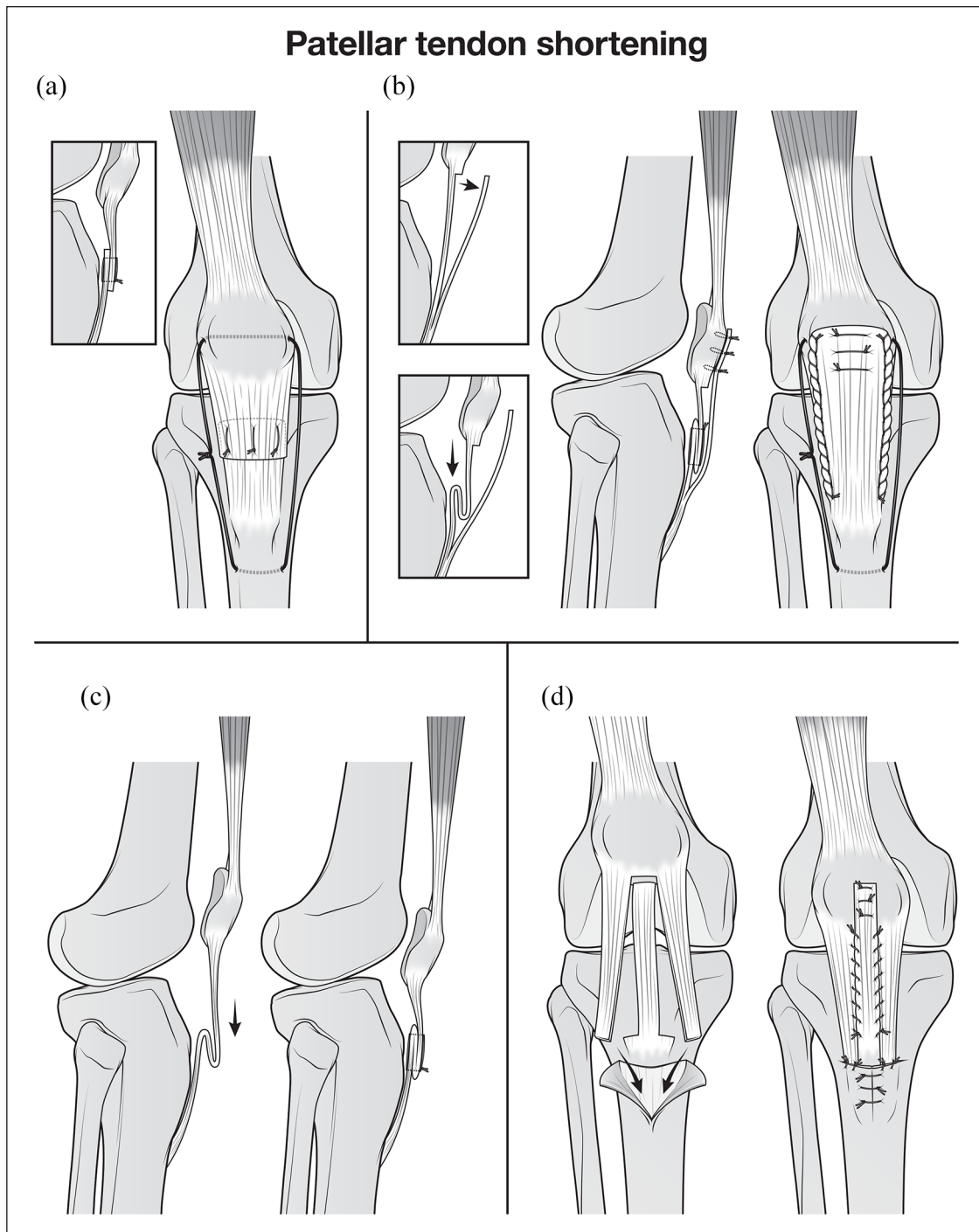
There was consensus for agreement in 31 of 44 (70%) statements regarding DFEO. The subjects covered general issues, clinical problems/history, physical examination, imaging, 3DGA, intra-operative assessment, post-operative management, and outcome measures/goals (Tables 1 and 2). The panel agreed that the primary indication for DFEO was the correction of knee flexion deformities (KFD) of between 10° and 45°, in children who are >10 years with crouch gait, GMFCS Levels I–III, especially in the presence of knee pain and with patellar avulsion fractures. Children at GMFCS IV could be considered for DFEO if there was evidence that progressive KFD had resulted in loss of ambulatory or standing ability, but DFEO would rarely be considered at GMFCS V because of anticipated problems with impaired sitting function (Table 1). Lateral radiographs of the knee in maximum extension are useful

to quantify KFD and to quantify patella alta. There was no consensus on the benefit of hamstring lengthening prior to DFEO to reduce the KFD to a more manageable range. Rotational deformity of the distal femur of up to 30° was not considered a contraindication to DFEO, the implication being that this deformity could be corrected at the same time as KFD. Correction of rotational deformities was considered important with smaller deformities corrected at the same site as the DFEO and a preference for rotational deformities >40° to be corrected in the proximal femur. The view of the panel was that DFEO routinely includes femoral shortening, for bilateral cases when KFD >25°, by excision of a trapezoidal segment of bone and therefore requires concomitant PTA/PTS, to correct the length of the muscle-tendon units around the knee. A hinged brace or knee immobilizer was preferred to a cast after surgery. The panel did not support casting the knee in extension after DFEO surgery.

Statements on the use of regional anesthesia and epidural catheters did not reach consensus. The preferred outcome measures were assessment of knee pain, knee kinematics, and knee kinetics (Table 2).

The level of consensus for PTA/PTS was lower, perhaps reflecting the wider range of techniques described in the literature (Table 3 and Figures 2 and 3). There was consensus that PTA/PTS was indicated in children with excessive knee flexion during stance, GMFCS Levels I–III, with extensor lag >10°, patella alta on a lateral knee





**Figure 3.** These are four of the many techniques which have been described for PTS. The simplest technique is that originally described by Selber and Feraretto, AACD Sao Paulo, Brazil. In their original description, the “vest over pants” repair was protected by a transverse Steinman pin inserted transversely through the patella and incorporated into an above knee cast, with the knee extended. The use of a FiberTape (Arthrex, Inc.) loop offers secure fixation and the freedom to allow the knee to remain flexed to 30° in a hinged brace. Imbrication techniques as described by Sossai et al.<sup>18</sup> and Hyer et al.<sup>22</sup> have the theoretical benefit of allowing the patella to return to the pre-operative position if the repair gives way, but complete dehiscence of the extensor mechanism might be avoided. These benefits are possibly more theoretical than real with the use of FiberTape: (a) Selber et al., (b) Sossai et al., (c) Hyer et al., and (d) Joseph et al.

radiograph, and open growth plates and two or more years of growth remaining. PTA was preferred by some in skeletally mature patients (Table 3).

When DFEO is indicated, a PTS/PTA is also required but a DFEO is not always indicated when performing PTS/PTA. That is, a PTA/PTS may be helpful in crouch gait when there is an extensor lag but minimal or no KFD and a DFEO is not required or guided growth is the preferred option (Tables 2 and 3).

Areas with lower levels of agreement were reported in skeletally immature patients with crouch gait and extensor lag, because of the overlap in indications between DFEO and ADFH.<sup>13</sup> There was uncertainty about the timing of PTS, given that correction of KFD is *acute* with DFEO and *gradual* with guided growth.<sup>4,13</sup>

## Results: literature review

The literature search identified 110 papers, with 25 meeting the inclusion criteria, summarized in Supplemental Appendix Tables 1 and 2. The sample size in most studies was rather small (<40) with short-term follow-up (mean <3 years). The notable exceptions were the study by Stout et al.<sup>4</sup> and De Morais Filho et al.<sup>25</sup> which included 73 patients and the study by Filho and colleagues which included 95 subjects, subdivided into three treatment groups. There were two long-term studies: the study by Kuchen et al. with a mean follow-up of 9 years<sup>26</sup> and Boyer et al.<sup>27</sup> with a mean follow-up in excess of 13 years. The study designs were most often a retrospective case series, but there were several studies with comparison groups and one randomized clinical trial (RCT).<sup>20</sup>

Notable findings in the patient populations were the predominance of children at GMFCS Levels II and III, and the very high prevalence of prior surgical intervention, usually GSL and/or hamstring lengthening.<sup>4,5,15,23</sup> DFEO and PTS/PTA were most often used to salvage failure of prior hamstring lengthening for crouch gait.<sup>4,5,15,18,22,23</sup>

The instrumentation for DFEO was usually a fixed angle blade plate (FABP) or a distal femoral locking plate (LCP).<sup>4,15,18,28</sup> The locking plate may offer greater ease of correction in all three planes as described by Sossai et al.<sup>18</sup> and Brunner et al.<sup>28</sup> Two studies reported the use of a straight plate with a distal femoral shortening osteotomy (DFS) rather than an extension osteotomy.<sup>16,29</sup>

A wide range of techniques were described for shortening the extensor mechanism, including PTA as described by Stout et al.<sup>4</sup> and Novacheck et al.<sup>15</sup> One study reported a high prevalence of premature closure of the anterior part of the proximal tibial apophysis, and this may have decreased the utilization of PTA influenced in favor of PTS, in the skeletally immature patient.<sup>30</sup> Another factor may have been the availability of strong synthetic materials for protecting PTS constructs, with Fibertape replacing wire cerclage in most recent studies.<sup>15,18–20,22</sup>

The majority of patients in the reviewed studies had an MLS approach with concomitant correction of fixed deformities at multiple levels.<sup>4,5,18–20,22</sup> This is ethically appropriate and good for individual patients but makes the evaluation of surgery at the knee level more difficult.

The prevalence of reported surgical complications varied from 0% to 40% with neural injury causing the greatest concern.<sup>4,23,24</sup> Proposals for the reduction of nerve stretch injury included femoral shortening, immobilization in 20–30° of flexion after surgery, and most recently, the use of intra-operative neuromonitoring (IONM).<sup>24</sup>

Satisfactory correction of KFD, extensor lag, and patella alta were reported.<sup>4,21,22,27</sup> Studies with 3DGA reported improvements in Gait Deviation Index (GDI), GPS, and specific kinematic parameters at the knee.<sup>4,18–20,22</sup> There were only three studies which reported kinetic parameters, despite the modified Delphi process identifying knee kinetics as being an important outcome measure. An increase in anterior pelvic tilt (APT) was noted in several studies after DFEO/PTS and was associated in one study with pre-operative increased spasticity in rectus femoris and limitations in hip extension.<sup>30</sup>

There were a few studies which included functional outcomes, such as the FMS and the Functional Assessment Questionnaire (FAQ), and the results were mixed.<sup>27,31</sup> Only the long-term study by Boyer et al.<sup>27</sup> included a range of patient-reported outcomes measures (PROMs).

## Discussion

Management of flexed knee/crouch gait in ambulatory children with CP is undergoing rapid change with the introduction of new surgical techniques including combinations of soft tissue surgery which include distal hamstring lengthening and transfer of one or more of the hamstring tendons to the distal femur.<sup>12–14</sup> In addition, ADFH has had an impact by extending the menu of procedures and potentially reducing the need for DFEO and PTS.<sup>13</sup> The panel therefore considered that it could be useful to study consensus for the indications for DFEO/PTS, as a logical follow-up after establishing consensus for soft tissue surgery (distal hamstring lengthening/transfer of the hamstrings) and guided growth for the correction of KFDs.<sup>13</sup>

Although description of DFEO and PTS occurred sporadically in the second half of the twentieth century, widespread adoption of DFEO and PTA did not happen until the procedure was refined and described by the Gillette Children's Hospital team.<sup>4,15</sup> This heralded increasing interest in the procedure and widespread adoption throughout North America and in many other countries.<sup>18–22</sup>

The expert panel agreed that there may be a need for DFEO when flexion deformity at the knee exceeds 30°, in a skeletally immature patient with ambulatory CP and >2 years of growth remaining, and a flexion deformity of >10° in the skeletally mature patient, refractory to less

invasive therapies. Although the adoption of hamstring lengthening/transfer combined with additional modalities such as serial casting has extended the role of soft tissue surgery, many children present with more severe flexion deformities which are not amenable to this management.<sup>12,13</sup> The literature reviewed found that DFEO and PTA/PTS were used to salvage recurrent crouch gait after hamstring lengthening, in the majority of patients. For those who are skeletally immature, the panel has previously advocated the use of soft tissue surgery *combined* with guided growth for less invasive correction of small KFDs, typically in the region of 10–30° in growing children.<sup>13</sup> This still leaves a group of skeletally mature teenagers and young adults with severe flexed knee/crouch gait and severe functional impairment who may require more invasive management by DFEO and PTA/PTS. PTA/PTS is always indicated with DFEO, but the corollary is not always true. That is, PTA/PTS may be indicated without DFEO. The panel wishes to emphasize that DFEO with PTA/PTS is a major reconstructive surgical option which is not indicated solely by a set of agreed indications. A complete appraisal of the patient, family circumstances, and preferences as well as a careful consideration of the experience of both the surgical and rehabilitation team are required.<sup>15,23</sup>

The literature review identified 25 clinical studies. Most studies were small, and the mean follow-up was relatively short term apart from the long-term study by Kuchen et al.<sup>26</sup> and Boyer et al.<sup>27</sup> The study design was most often a retrospective analysis of a case series, but there were several comparative studies and one RCT.<sup>20</sup>

Most studies included pre- and post-operative physical examination measures including knee flexion deformity, radiographic measurement of patella alta, and extensor lag. In future studies, the use of these three measures is encouraged to determine if the surgical procedure has been effective for the correction of KFD. It is accepted that patella alta has a poor correlation with knee pain, crouch gait, and functional mobility. However, it is a key objective measure to assess the effectiveness of PTA/PTS at both short-term and long-term follow-up. The outcome measures included observational gait analysis, 3DGA (kinematics, rarely kinetics) with few studies including measures of gross motor or community function (Gross Motor Function Measure (GMFM), FAQ, and FMS). Only the long-term study by Boyer et al.<sup>27</sup> included a raft of patient reported outcome measures.

The majority of patients in the included studies had surgery prior to DFEO and PTA/PTS, most often gastrocnemius lengthening and hamstring lengthening.<sup>4,5,18–20</sup> The interpretation of these data includes the fact that isolated GSL, especially in Zone 3, may precipitate crouch gait.<sup>6,14</sup> Distal hamstring lengthening may be relatively ineffective for the correction of crouch gait with a high rate of incomplete correction and recurrence.<sup>4–6,8,12,13</sup>

The majority of patients in the included studies had surgery at other levels with DFEO, including a full single-event multilevel surgery (SEMLS) approach.<sup>19,20,22</sup> These precipitating and confounding issues are worthy of further study.

The safety of acute correction of KFD has been a concern in the literature for many years, especially the risk of neurovascular complications.<sup>4,5</sup> It has been suggested that a DFSO might be safer than a DFEO. The two studies which utilized a shortening osteotomy with no extension component reported no neural injuries.<sup>16,29</sup> However, Inan and colleagues who reported a significant prevalence of neural stretch injuries have proposed a possible solution, the use of intra-operative neuromonitoring.<sup>23,24</sup> In their study of neural monitoring during DFEO, alert signals were recorded in all cases, and in two knees, they chose to under correct the KFD to relieve neural stretch. This suggests that all lower limbs are at risk of neural injury during DFEO, and extreme caution is advised.<sup>24</sup> Reporting of surgical adverse events or complications in this review was variable, and a few studies used a validated system.

Those who are considering study design for future studies are referred to Supplemental Appendix Tables 1 and 2 to review what has been trialed in the literature to date. More robust study designs with prospective inclusion of baseline and post-operative PROMs would improve the level of evidence.

## Conclusion

We identified areas of agreement and disagreement for DFEO and PTA/PTS surgery in children with CP, which may be useful to surgeons who manage this difficult problem.

Taken as a whole, the clinical outcomes literature provides a good description of surgical techniques, anticipated outcomes, and complications. The summary of outcome measures in Supplemental Appendix Tables 1 and 2 may give some guidance for those designing future studies. Prospective, multicenter studies with PROMs would improve the evidence base significantly.

## Acknowledgements

The authors acknowledge Josephine Skelton for assisting in the preparation of this manuscript and Bill Reid for the illustrations. Kerr Graham is supported by NHMRC, CP-Achieve.

## Author contributions

E.R. contributed to the conception and design, drafting of the article, critical revision of the article for important intellectual content, and final approval of the article. T.F.N. contributed to the conception and design, drafting of the article, critical revision of the article for important intellectual content, and final approval of the article. T.D. contributed to the conception and design, drafting of the article, critical revision of the article for important intellectual content, and final approval of the article. J.R.D. contributed to the conception and design, drafting of the article, critical revision

of the article for important intellectual content, and final approval of the article. J.M.C. contributed to the conception and design, acquisition of the data, analysis and interpretation of the data, drafting of the article, critical revision of the article for important intellectual content, final approval of the article, obtaining of funding, administrative, technical, or logistic support, and Collection and assembly of data. R.M.K. contributed to the conception and design, drafting of the article, critical revision of the article for important intellectual content, and final approval of the article. B.J.S. contributed to the conception and design, drafting of the article, critical revision of the article for important intellectual content, and final approval of the article. M.W.S. contributed to the conception and design, drafting of the article, critical revision of the article for important intellectual content, final approval of the article, and obtaining of funding. M.V. contributed to the conception and design, acquisition of the data, analysis and interpretation of the data, drafting of the article, critical revision of the article for important intellectual content, final approval of the article, statistical expertise, obtaining of funding, administrative, technical, or logistic support, and collection and assembly of data. H.C. contributed to the conception and design, drafting of the article, critical revision of the article for important intellectual content, and final approval of the article. U.N. contributed to the conception and design, drafting of the article, critical revision of the article for important intellectual content, and final approval of the article. K.P. contributed to the conception and design, drafting of the article, critical revision of the article for important intellectual content, and final approval of the article. J.R. contributed to the conception and design, drafting of the article, critical revision of the article for important intellectual content, and final approval of the article. J.S. contributed to the conception and design, drafting of the article, critical revision of the article for important intellectual content, and final approval of the article. T.T. contributed to the conception and design, drafting of the article, critical revision of the article for important intellectual content, and final approval of the article. A.V.C. contributed to the conception and design, drafting of the article, critical revision of the article for important intellectual content, and final approval of the article. K.G. contributed to the conception and design, drafting of the article, critical revision of the article for important intellectual content, and final approval of the article.

### Declaration of conflicting interests

The author(s) declared no potential conflicts of interest with respect to the research, authorship, and/or publication of this article.

### Ethical approval

Ethical approval for this study was not required.

### Funding

The author(s) disclosed receipt of the following financial support for the research, authorship, and/or publication of this article: Kerr Graham received non financial support from NHMRC CP-Achieve grant.

### Informed consent

Informed consent was not required, apart from the parents of the child, whose data were used to develop Figure 1.

### ORCID iDs

Jon R Davids  <https://orcid.org/0000-0002-1639-6519>

Robert M Kay  <https://orcid.org/0000-0002-4498-6815>

### Supplemental material

Supplemental material for this article is available online.

### References

1. Rethlefsen SA, Blumstein G, Kay RM, et al. Prevalence of specific gait abnormalities in children with cerebral palsy revisited: influence of age, prior surgery, and Gross Motor Function Classification System level. *Dev Med Child Neurol* 2017; 59(1): 79–88.
2. O'Sullivan R, Horgan F, O'Brien T, et al. The natural history of crouch gait in bilateral cerebral palsy: a systematic review. *Res Dev Disabil* 2018; 80: 84–92.
3. Pantzar-Castilla EHS, Wretenberg P and Riad J. Knee flexion contracture impacts functional mobility in children with cerebral palsy with various degree of involvement: a cross-sectional register study of 2,838 individuals. *Acta Orthop* 2021; 92(4): 472–478.
4. Stout JL, Gage JR, Schwartz MH, et al. Distal femoral extension osteotomy and patellar tendon advancement to treat persistent crouch gait in cerebral palsy. *J Bone Joint Surg Am* 2008; 90: 2470–2484.
5. Taylor D, Connor J, Church C, et al. The effectiveness of posterior knee capsulotomies and knee extension osteotomies in crouched gait in children with cerebral palsy. *J Pediatr Orthop B* 2016; 25(6): 543–550.
6. Vuillermin C, Rodda J, Rutz E, et al. Severe crouch gait in spastic diplegia can be prevented: a population-based study. *J Bone Joint Surg Br* 2011; 93(12): 1670–1675.
7. Rutz E, McCarthy J, Shore BJ, et al. Indications for gastrocnemius lengthening in ambulatory children with cerebral palsy: a Delphi consensus study. *J Child Orthop* 2020; 14: 405–414.
8. Graham HK, Thomason P, Willoughby K, et al. Musculoskeletal pathology in cerebral palsy: a classification system and reliability study. *Children* 2021; 8: 252.
9. Rodda JM, Graham HK, Carson L, et al. Sagittal gait patterns in spastic diplegia. *J Bone Joint Surg Br* 2004; 86: 251–258.
10. Rodda JM, Graham HK, Nattrass GR, et al. Correction of severe crouch gait in patients with spastic diplegia with use of multilevel orthopaedic surgery. *J Bone Joint Surg Am* 2006; 88(12): 2653–2664.
11. Davids JR, Shilt J, Kay R, et al. Assessment of foot alignment and function for ambulatory children with cerebral palsy: results of a modified Delphi technique consensus study. *J Child Orthop* 2022; 16(2): 111–120.
12. Kay RM, McCarthy J, Narayanan U, et al. Finding consensus for hamstring surgery in ambulatory children with cerebral palsy using the Delphi method. *J Child Orthop* 2022; 16(1): 55–64.
13. Shore BJ, McCarthy J, Shrader MW, et al. Anterior distal femoral hemiepiphysiodesis in children with cerebral palsy: establishing surgical indications and techniques using

- the modified Delphi method and literature review. *J Child Orthop* 2022; 16(1): 65–74.
14. Young JL, Rodda J, Selber P, et al. Management of the knee in spastic diplegia: what is the dose? *Orthop Clin North Am* 2010; 41(4): 561–577.
  15. Novacheck TF, Stout JL, Gage JR, et al. Distal femoral extension osteotomy and patellar tendon advancement to treat persistent crouch gait in cerebral palsy. Surgical technique. *J Bone Joint Surg Am* 2009; 91(Suppl. 2): 271–286.
  16. Joseph B, Reddy K, Varghese RA, et al. Management of severe crouch gait in children and adolescents with cerebral palsy. *J Pediatr Orthop* 2010; 30(8): 832–839.
  17. Rutz E, Gaston MS, Camathias C, et al. Distal femoral osteotomy using the LCP pediatric condylar 90-degree plate in patients with neuromuscular disorders. *J Pediatr Orthop* 2012; 32(3): 295–300.
  18. Sossai R, Vavken P, Brunner R, et al. Patellar tendon shortening for flexed knee gait in spastic diplegia. *Gait Posture* 2015; 41(2): 658–665.
  19. Klotz MCM, Hirsch K, Heitzmann D, et al. Distal femoral extension and shortening osteotomy as a part of multilevel surgery in children with cerebral palsy. *World J Pediatr* 2017; 13(4): 353–359.
  20. Klotz MCM, Krautwurst BK, Hirsch K, et al. Does additional patella tendon shortening influence the effects of multilevel surgery to correct flexed knee gait in cerebral palsy: a randomized controlled trial. *Gait Posture* 2018; 60: 217–224.
  21. Aroojis A, Patel M, Shah A, et al. Distal femoral extension osteotomy with 90[degrees] pediatric condylar locking compression plate and patellar tendon advancement for the correction of crouch gait in cerebral palsy. *Indian J Orthop* 2019; 53: 45–52.
  22. Hyer LC, Carpenter AM, Saraswat P, et al. Outcomes of patellar tendon imbrication with distal femoral extension osteotomy for treatment of crouch gait. *J Pediatr Orthop* 2021; 41: e356–e366.
  23. İnan M, Sarikaya İA, Yildirim E, et al. Neurological complications after supracondylar femoral osteotomy in cerebral palsy. *J Pediatr Orthop* 2015; 35(3): 290–295.
  24. Erdal OA, Gorgun B, Sarikaya IA, et al. Intraoperative neuromonitoring during distal femoral extension osteotomy in children with cerebral palsy. *J Pediatr Orthop B* 2022; 31: 194–201.
  25. De Morais Filho MC, Blumetti FC, Kawamura CM, et al. The increase of anterior pelvic tilt after crouch gait treatment in patients with cerebral palsy. *Gait Posture* 2018; 63: 165–170.
  26. Kuchen DB, Eichelberger P, Baur H, et al. Long-term follow-up after patellar tendon shortening for flexed knee gait in bilateral spastic cerebral palsy. *Gait Posture* 2020; 81: 85–90.
  27. Boyer ER, Stout JL, Laine JC, et al. Long-term outcomes of distal femoral extension osteotomy and patellar tendon advancement in individuals with cerebral palsy. *J Bone Joint Surg Am* 2018; 100: 31–41.
  28. Brunner R, Camathias C, Gaston M, et al. Supracondylar osteotomy of the paediatric femur using the locking compression plate: a refined surgical technique. *J Child Orthop* 2013; 7(6): 571–574.
  29. Park H, Park BK, Park KB, et al. Distal femoral shortening osteotomy for severe knee flexion contracture and crouch gait in cerebral palsy. *J Clin Med* 2019; 8: 1354.
  30. Patthanachoenphon C, Maples DL, Saad C, et al. The effects of patellar tendon advancement on the immature proximal tibia. *J Child Orthop* 2013; 7(2): 139–146.
  31. Das SP, Pradhan S, Ganesh S, et al. Supracondylar femoral extension osteotomy and patellar tendon advancement in the management of persistent crouch gait in cerebral palsy. *Indian J Orthop* 2012; 46(2): 221–228.