

UC Irvine

UC Irvine Previously Published Works

Title

Generalized Chrysiasis Improved with Pulsed Dye Laser

Permalink

<https://escholarship.org/uc/item/5cm5134g>

Journal

Dermatologic Surgery, 35(3)

ISSN

1076-0512

Authors

WU, JASHIN J
PAPAJOHN, NICHOLAS G
MURASE, JENNY E
[et al.](#)

Publication Date

2009-03-01

DOI

10.1111/j.1524-4725.2009.01092.x

Copyright Information

This work is made available under the terms of a Creative Commons Attribution License, available at <https://creativecommons.org/licenses/by/4.0/>

Peer reviewed



Published in final edited form as:

Dermatol Surg. 2009 March ; 35(3): 538–542. doi:10.1111/j.1524-4725.2009.01092.x.

Generalized Chrysiasis Improved with Pulsed Dye Laser

Jashin J. Wu, MD^{*}, Nicholas G. Papajohn, MD[†], Jenny E. Murase, MD^{‡,§}, Willem Verkrusse, PhD[¶], and Kristen M. Kelly, MD^{¶,||}

^{*}Department of Dermatology, Kaiser Permanente, Los Angeles Medical Center, Los Angeles, California

[†]University of South Alabama College of Medicine, Mobile, Alabama

[‡]Department of Dermatology, University of California at San Francisco, San Francisco, California

[§]Palo Alto Foundation Medical Group, Mountain View, California

[¶]Beckman Laser Institute and Medical Clinic

^{||}Department of Dermatology, University of California at Irvine, Irvine, California

Chrysiasis is the phenomenon of bluish to slate-gray skin pigmentation induced by prolonged treatment with gold salts. The most common etiology is the administration of gold salts to patients with rheumatoid arthritis. Although parental gold salt administration is now uncommon because of the availability of biologic agents and disease-modifying antirheumatic drugs, chrysiasis may still be seen because this condition can develop decades after discontinuing gold salts. Discoloration can persist for a lifetime.

Aurothioglucose, the active agent in Solganal (gold salts for parenteral administration; Schering-Plough, Kenilworth, NJ; manufacture discontinued May 2002), contains approximately 50% gold content by weight. Ultraviolet light-induced chrysiasis is typically associated with this parenteral formulation, although chrysiasis has also been reported with oral gold therapy.¹ A study of 40 patients with rheumatoid arthritis treated with intramuscular gold salts showed a positive relationship between the cumulative dose of gold and the severity of pigmentation.² Pigmentary changes occur typically at 20 mg/kg (approximately 1.3 g) of elemental gold² but have been reported in patients who have received lower cumulative doses.³

Gold concentrates in the lens and cornea,⁴ reticulo-endothelial system, and skin. Pigmentation is often most noticeable in photo-exposed areas. It is believed that deposits occur in all skin but become most clinically apparent when exposed to ultraviolet light. Non-sun exposed skin becomes hyperpigmented with experimental ultraviolet light administration.⁵

Light microscopy typically demonstrates aggregates of gold in the papillary and reticular dermis in a perivascular distribution. Gold deposits are often found within macrophages and endothelial cells, but extracellular granules may also be seen.⁶ On fluorescent microscopy, gold particles display orange-red birefringence.⁷ Electron microscopy shows faceted electron-dense particles within macrophage vesicles and endothelial cell lysosomes known as aurosomes.⁸ Patients with chrysiasis also have higher concentrations of melanin in the epidermis and dermis of involved skin. Gold deposits in the dermis may enhance melanogenesis by indirectly increasing tyrosinase activity. Ultraviolet light may induce hyperpigmentation³ or stimulate preferential uptake of gold by the skin.⁵

Human leukocyte antigens may also play a factor in the development of chrysiasis. The B27 antigen was associated with chrysiasis, and the DR7 antigen had a protective effect against gold toxicity.⁹

The discoloration associated with chrysiasis can be disfiguring for patients, and treatment is difficult. We present the first case to our knowledge of extensive intense chrysiasis treated with a pulsed dye laser.

Case Report

A 66-year-old Caucasian woman veteran was diagnosed with rheumatoid arthritis in 1977. She received Solganal gold salts 100mg every week for rheumatoid arthritis between 1979 and 1981 and between 1983 and 1993. Her cumulative elemental gold dose was 33.8g.

In 1983, the patient began to develop chrysiasis manifested by pronounced gray pigmentation, most notable on the face, neck, trunk, and arms. This discoloration severely and adversely affected her daily life. She constantly wore thick makeup to cover the gray color of her skin, yet she still endured stares and comments regarding her skin tone. In 2006, she sought treatment at the Beckman Laser Institute at the University of California, Irvine.

Biopsy of the left shoulder, in an area not treated with any lasers, showed exogenous pigment in the superficial dermis and within macrophages down to a depth of 2.5 mm (Figure 1).

Reflectance spectroscopic measurements were performed using a handheld spectrometer (2,600-D, Konica, Minolta, Tokyo, Japan) with a wavelength range of 360 to 740 nm. Unfortunately, no focal peaks of absorption were noted, only absorption over a wide range. Color measurements were performed using a CR-400 (Konica, Minolta, Tokyo, Japan) calibrated at standard illuminant D65 (representing daylight). Color values were expressed in the CIELAB (CIE 1967, Commission International d'Eclairage) as three values in the L*, a*, and b* space, where L* expresses the overall lightness (0–100, for black to white), a* represents balance between green and red (negative and positive values, respectively), and b* expresses the balance between blue and yellow. Measurements were taken at the same sites for all visits to minimize effect of spatial skin color inhomogeneities. Clear differences were demonstrated between measurements in this patient's skin and those expected for someone with her skin type (Table 1).

In February 2006, test spots were performed on the left shoulder with the GentleLase (Candela Corporation, Wayland, MA) 755-nm laser (10-mm spot size, 3-ms pulse duration). Four test spots with radiant exposures between 25 and 35 J/cm² were performed. In March 2006, radiant exposures up to 50 J/cm² were used. Cryogen spray cooling settings for all test spots were 50 ms of cryogen with a 30-ms delay. Test spots on the left shoulder initially revealed no improvement, and there was no improvement at 6 months. Test spots on the arm were also performed using a pulsed dye laser (595 nm; 7 mm; 3 ms pulse duration; 6–14 J/cm²) 30 ms of cryogen with a 20-ms delay, but again no response was noted, even on follow-up 16 months later.

In March 2006, the patient also requested treatment of facial telangiectases and was cautiously treated using a 595 nm pulsed dye laser (VBeam initially and later Perfecta; Candela Corporation). A small area of the face was treated first using a 7-mm spot size, 3-ms pulse duration, and radiant exposure starting at 8.5 J/cm² and slowly moving up to 10 J/cm².

It was hoped that the chrysiasis might also improve, because absorption at this wavelength had been demonstrated, and pigmentation was darkest on the face because of sun exposure (presumably increased chromophore for better absorption). After a 6-week observation period, no adverse effects were noted, and there was slight improvement in the gray discoloration. The patient was pleased and underwent nine full-face treatments for chrysiasis at 4- to 8-week intervals. After the first two treatments, the neck and décolletage area was added.

Clinically, she has demonstrated improvement in her chrysiasis and telangiectases 13 months after the first treatment to the face (Figure 2A, B). Treatment was continued primarily to improve the chrysiasis, but serial chromometer and spectrophotometer measurements have not demonstrated clear differences.

To our surprise, although there was no improvement of the 755-nm left shoulder test spots noted at 6-month follow-up, there was lightening clearly evident at a 16-month follow-up visit (Figure 3). The patient had been followed at monthly intervals, and improvement had not been previously noted, but after the 6-month follow-up visit, the arm test sites were not routinely checked. Spectrum analysis demonstrates differences between these test sites and untreated areas (Figure 4).

Discussion

In this case report, we describe the first reported treatment of extensive intense chrysiasis.

Argyria can be successfully treated using Q-switched lasers, but use of these devices on patients who have received gold salts may result in immediate tissue discoloration.^{1,10,11} Q-switched lasers may alter physiochemical properties in dermal gold,¹⁰ with electron microscopy studies having demonstrated a decrease in particle size and loss of the characteristic faceted appearance (thought to signify a change from crystalline to elemental gold). More numerous, smaller gold particles may amplify optical scattering of visible light in the dermis.¹⁰

Yun and colleagues¹ suggested the use of millisecond lasers between 550 and 850 nm for treatment of laser-induced chrysiasis. We have demonstrated that these wavelengths may also have utility for treating more extensive chrysiasis, although our patient required significantly more than the two treatments reported in the Yun and colleagues paper. This may be because of long-term recurrent sun exposure over time and the large amount of gold administered to this patient. Despite the need for many treatments, the pulsed dye laser is a reasonable option because there are few other available treatment modalities. Sun avoidance and protection to minimize ultraviolet-induced exacerbation is also important.

Although there was a slight lightening trend (increased L* value) in the treated areas with respect to the untreated areas, changes in chromometer measurements were significantly less than improvement noted clinically. This difference is difficult to explain. It is possible that we created a fine scar that was not perceptible to the eye but increased scattering and decreased the gray appearance of the patient's skin. Such changes might be similar to those observed with laser skin resurfacing. The average person would not develop a scar from a pulsed dye laser at these settings, but chrysiasis alterations may result in an unusual response. Alternatively, the chromometer may not have been sensitive enough to detect small changes.

Improvement in the 755-nm test spots 18 months after treatment was surprising. All test spots appeared the same despite the different fluence used. Comparison between treated and untreated skin spectra indicated that reflectance had increased approximately 2% over the entire measured wavelength range. Again, the observed changes would be consistent with fine, clinically imperceptible scarring.

In conclusion, we report the first case of extensive intense chrysiasis improved using a 595-nm pulsed dye laser. The patient reported that treatment profoundly improved her quality of life, eliminating the need for makeup and easing social interactions.

References

1. Yun PL, Arndt KA, Anderson RR. Q-switched laser-induced chrysiasis treated with long-pulsed laser. *Arch Dermatol.* 2002; 138:1012–4. [PubMed: 12164737]
2. Smith RW, Leppard B, Barnett NL, et al. Chrysiasis revisited: a clinical and pathological study. *Br J Dermatol.* 1995; 133:671–8. [PubMed: 8555015]
3. Fleming CJ, Salisbury EL, Kirwan P, et al. Chrysiasis after low-dose gold and UV light exposure. *J Am Acad Dermatol.* 1996; 34:349–51. [PubMed: 8655724]
4. Lopez JD, del Castillo JM, Lopez CD, Sanchez JG. Confocal microscopy in ocular chrysiasis. *Cornea.* 2003; 22:573–5. [PubMed: 12883354]
5. Leonard PA, Moatamed F, Ward JR, et al. Chrysiasis: the role of sun exposure in dermal hyperpigmentation secondary to gold therapy. *J Rheumatol.* 1986; 13:58–64. [PubMed: 3084781]
6. Cox AJ, Marich KW. Gold in the dermis following gold therapy for rheumatoid arthritis. *Arch Dermatol.* 1973:655–7. [PubMed: 4201477]
7. al-Talib RK, Wright DH, Theaker JM. Orange-red birefringence of gold particles in paraffin wax embedded sections: an aid to the diagnosis of chrysiasis. *Histopathology.* 1994; 24:176–8. [PubMed: 7910148]
8. Oryschak AF, Ghadially FN. Evolution of aurosomes in rabbit synovial membrane. *Virchows Arch B Cell Pathol.* 1976; 20:29–39. [PubMed: 816069]

9. Rodriguez-Pérez M, González-Dominguez J, Matarán L, et al. Association of HLA-DR5 with mucocutaneous lesions in patients with rheumatoid arthritis receiving gold sodium thiomalate. *J Rheumatol.* 1994; 21:41–3. [PubMed: 8151585]
10. Trotter MJ, Tron VA, Hollingdale J, Rivers JK. Localized chrysiasis induced by laser therapy. *Arch Dermatol.* 1995; 131:1411–4. [PubMed: 7492130]
11. Geist DE, Phillips TJ. Development of chrysiasis after Q-switched ruby laser treatment of solar lentigines. *J Am Acad Dermatol.* 2006; 55:S59–60. [PubMed: 16843130]

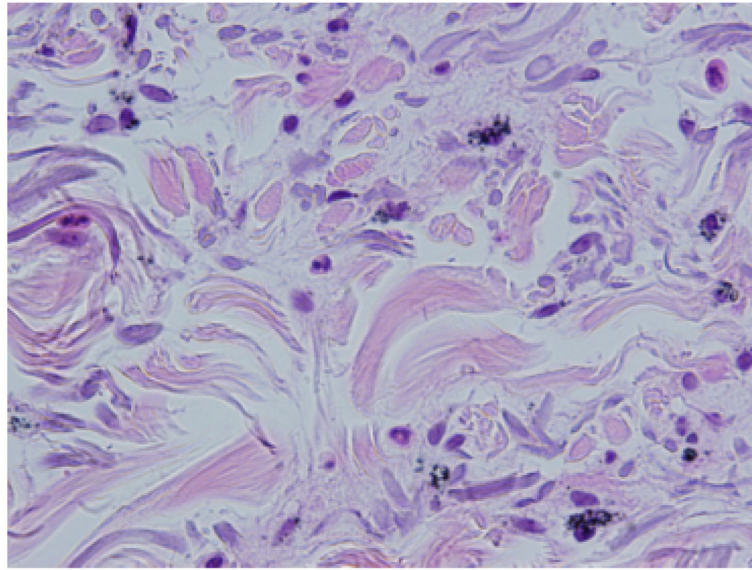


Figure 1. Biopsy of left shoulder (hematoxylin and eosin, $\times 40$) shows exogenous pigment in the superficial dermis and within macrophages.

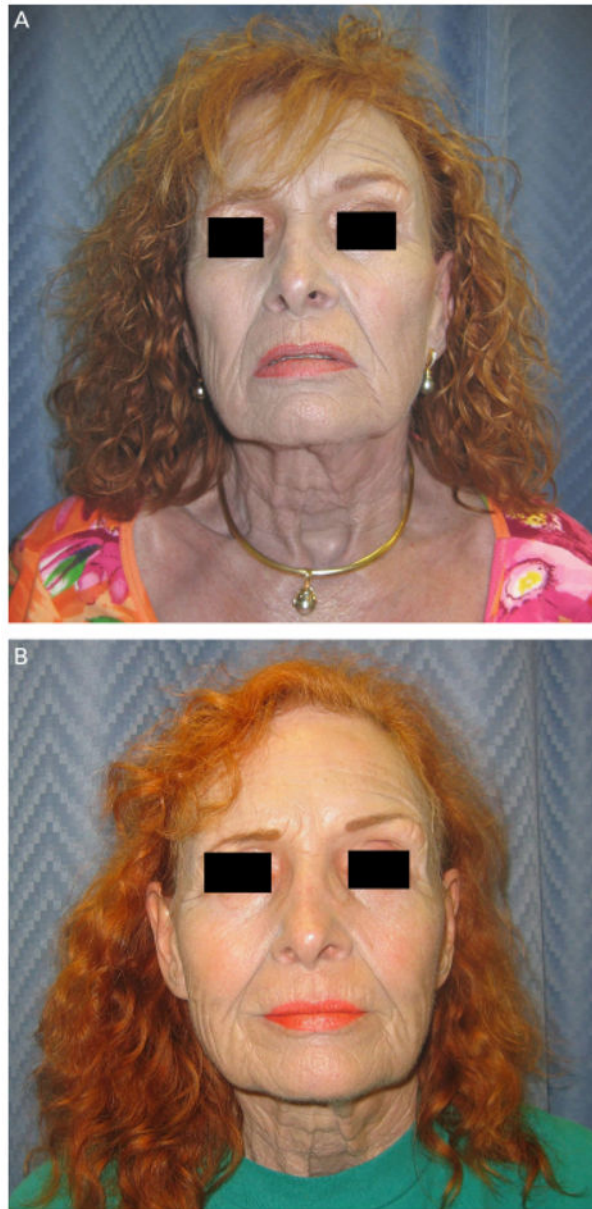

Figure 2. (A) Before and (B) 13 months after nine treatments with the pulsed dye laser. Improvement in chrysiasis and telangiectases can be seen.

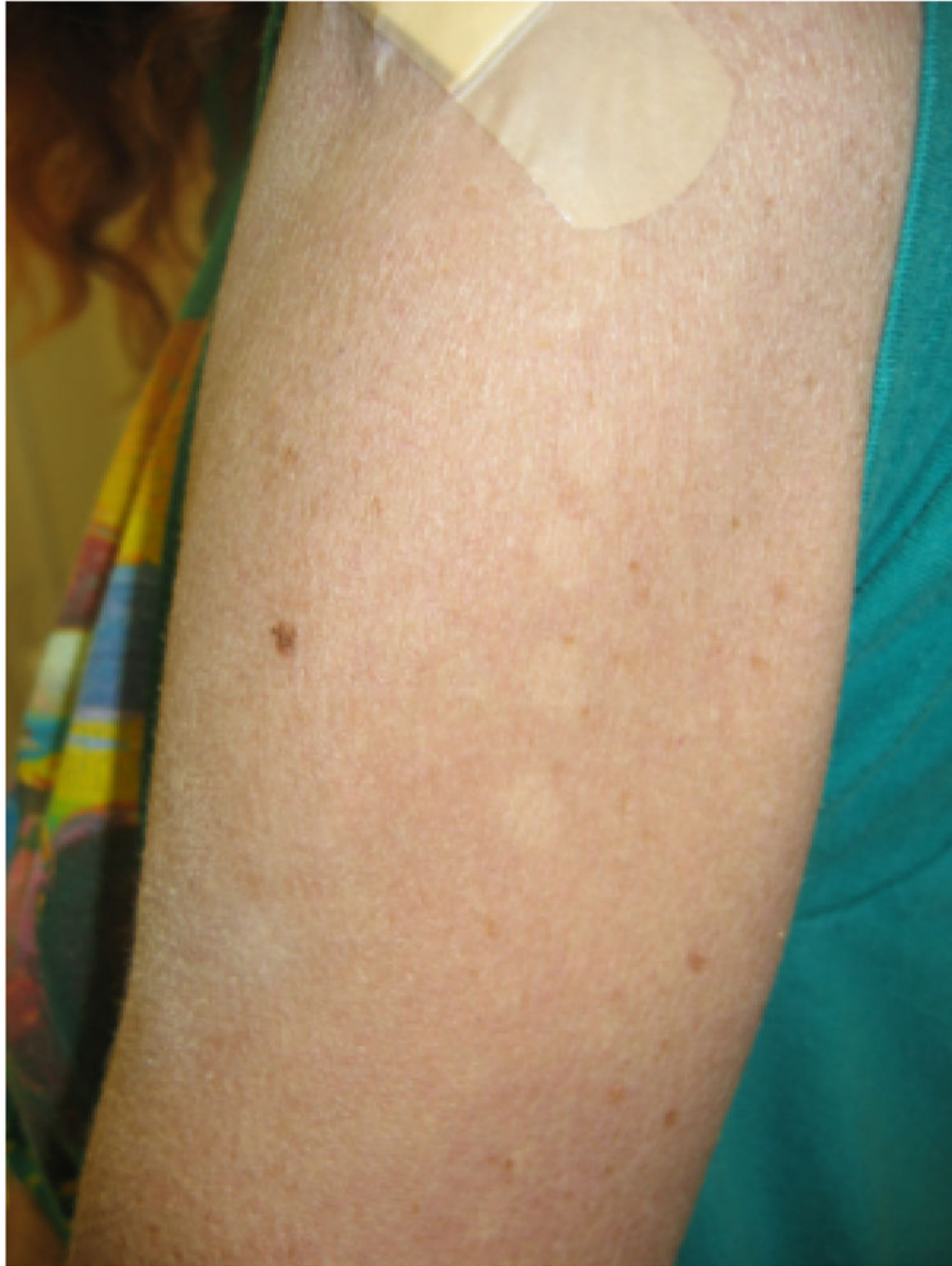

Figure 3.
Lightening of left shoulder test spots noted 16 months after treatment with 755-nm laser.

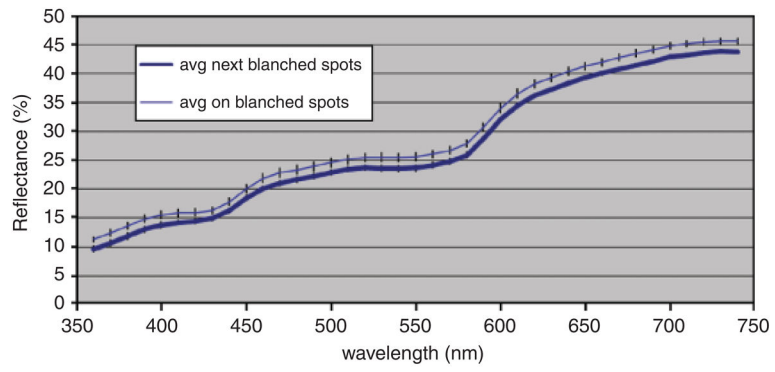


Figure 4. Eighteen-month postintervention spectrum analysis of 755-nm laser treatment sites compared with untreated areas. Reflectance went up by an average of 2%.

TABLE 1

Comparison of L*, a*, b* Values for the Presented Chrysiasis Patient Compared with Normal Subject with Similar Skin Type

	Chrysiasis	Normal Skin (Estimated for Her Skin Type (Type I))
L*	53–58	63–68
a*	7–12	10–18
b*	7–11	8–15