

# UC Davis

## UC Davis Previously Published Works

### Title

Clinician accuracy in identifying essential laryngeal landmarks on swallowing fluoroscopy.

### Permalink

<https://escholarship.org/uc/item/5cp9r6sb>

### Journal

Laryngoscope Investigative Otolaryngology, 8(5)

### ISSN

2378-8038

### Authors

Zhao, Nina  
MacDonald, Bridget  
Pietrowski, Jessica  
et al.

### Publication Date

2023-10-01




### DOI

10.1002/lio2.1127

Peer reviewed

## ORIGINAL RESEARCH

# Clinician accuracy in identifying essential laryngeal landmarks on swallowing fluoroscopy

Nina W. Zhao MD, MAEd<sup>1,2</sup>  | Bridget V. MacDonald MD<sup>1</sup> |  
Jessica R. Pietrowski MS, CCC-SLP<sup>1</sup> | Joey Laus MS, CCC-SLP<sup>3</sup> |  
Lisa M. Evangelista CScD, CCC-SLP, BCS-S<sup>1</sup>  | Ian Joseph BA<sup>4</sup> |  
Clark A. Rosen MD<sup>3</sup>  | Peter C. Belafsky MD, PhD<sup>1</sup>

<sup>1</sup>Department of Otolaryngology—Head and Neck Surgery, University of California, Davis, Sacramento, California, USA

<sup>2</sup>Department of Otolaryngology—Head and Neck Surgery, University Hospitals Cleveland Medical Center, Cleveland, Ohio, USA

<sup>3</sup>Department of Otolaryngology—Head and Neck Surgery, University of California, San Francisco, San Francisco, California, USA

<sup>4</sup>School of Medicine, University of California, Davis, Sacramento, California, USA

## Correspondence

Nina W. Zhao, Department of Otolaryngology—Head and Neck Surgery, University Hospitals Cleveland Medical Center, 11100 Euclid Avenue, Lakeside Suite 4500, Cleveland, OH 44106, USA.  
Email: [nina.zhao.md@gmail.com](mailto:nina.zhao.md@gmail.com)

## Abstract

**Objective:** Identification of anatomical landmarks is essential for interpretation of video fluoroscopic swallow studies (VFSS). This investigation sought to confirm the location of essential laryngeal landmarks and determine clinician accuracy in structure identification on VFSS.

**Methods:** A single human cadaver was used to generate unmarked standard lateral and anterior–posterior (AP) fluoroscopic images. Essential laryngeal structures (e.g., true vocal fold, arytenoid) were directly identified using a guidewire placed through an endoscope while obtaining corresponding marked fluoroscopic images. Licensed clinicians (speech-language pathologists [SLP], laryngologists) and trainees (otolaryngology residents, SLP clinical fellows [CF]) identified 18 structures (9 lateral, 9 AP) on unmarked images. Answers were compared to corresponding marked images. The percentage of accurate identification was calculated for each clinician and then compared between groups using *t*-tests.

**Results:** Twenty-four individuals (10 SLPs, 1 CF, 9 residents, 4 laryngologists) from six institutions completed structure identification. Mean overall accuracy was  $41.7 \pm 13.0\%$  (range 18.8–68.8%). There were no significant differences in mean overall accuracy between trainees ( $41.9 \pm 12.9\%$ ) and clinicians ( $42.0 \pm 13.1\%$ ),  $p = .97$ , or between SLPs ( $45.5 \pm 12.8\%$ ) and physicians ( $38.9 \pm 12.3\%$ ),  $p = .22$ . On average, participants were significantly more accurate identifying structures on lateral view ( $53.1 \pm 16.1\%$ ) than AP ( $27.3 \pm 22.8\%$ ),  $p < .001$ . Less than half of participants accurately identified the laryngeal ventricle, cricoid, epiglottic petiole, and the anterior commissure on lateral view.

**Conclusions:** The ability of certified clinicians and trainees to correctly identify essential anatomic landmarks on swallowing fluoroscopy may be poor. Future work is needed to identify how we can train clinicians on more accurate identification of essential anatomic structures on swallowing fluoroscopy.

Level of Evidence: NA.

This is an open access article under the terms of the [Creative Commons Attribution-NonCommercial-NoDerivs](https://creativecommons.org/licenses/by-nc-nd/4.0/) License, which permits use and distribution in any medium, provided the original work is properly cited, the use is non-commercial and no modifications or adaptations are made.

© 2023 The Authors. *Laryngoscope Investigative Otolaryngology* published by Wiley Periodicals LLC on behalf of The Triological Society.

## KEYWORDS

fluoroscopy, laryngeal anatomy, modified barium swallow study, videofluoroscopic swallow study

## 1 | INTRODUCTION

The modified barium swallow study (MBSS) or videofluoroscopic swallow study (VFSS) is one of the gold standards in instrumental swallow evaluation,<sup>1-3</sup> providing a comprehensive, dynamic, and real-time view of the oral, pharyngeal, and cervical esophageal phases of the swallow. Information obtained via VFSS is used to describe the anatomy and physiology of the swallow, swallow efficiency, airway protection, and presence/severity of swallow impairment. The results are used by clinicians, including speech-language pathologists (SLPs) and otolaryngologists, to form recommendations and plan evidence-based treatment.

Although accurate and reliable VFSS interpretation is critical for clinical practice, there is no standardized approach for interpretation, which remains highly subjective. Prior studies have shown poor interrater reliability for multiple parameters on VFSS.<sup>4-6</sup> One explanation for this variability is that many of the subjective parameters (e.g., degree of laryngeal elevation, strength of pharyngeal contraction) are not universally defined; however, another underlying issue is that many of the anatomical landmarks on fluoroscopy important for swallowing are challenging to identify. Although many assessment tools have been developed to aid VFSS analysis, including the Penetration-Aspiration Scale (PAS), Modified Barium Swallow Impairment Profile (MBSImp™), and quantitative structural displacement,<sup>7-9</sup> use of all these tools assume clinician competency in identifying laryngeal anatomy, but these structures are small and often poorly defined and visualized on fluoroscopy. In addition, a swallowing clinician's training in identifying laryngeal anatomy on fluoroscopy is variable, with knowledge primarily gathered through clinical experience.

Accurate identification of laryngeal and surrounding anatomy is crucial to characterizing important aspects of the swallow such as airway protection, location of residue, and swallow efficiency but current literature suggests that clinicians face visualization challenges on VFSS. Prior work by Pisegna and Langmore has shown that clinician self-reported visualization of anatomical structures on VFSS is significantly reduced compared to the flexible endoscopic evaluation of swallowing (FEES), which is conducted using a nasolaryngoscope.<sup>10</sup> In particular, participants reported significantly less visualization of laryngeal structures such as the arytenoids, true vocal folds, and false vocal folds. The authors suggest that “this may reflect a lack of anatomical competency and highlight the need for better training in identifying important swallowing structures” on VFSS.<sup>10</sup> However, to our knowledge, no one has empirically verified the anatomic landmarks of the larynx on fluoroscopy or assessed clinician accuracy in identifying these landmarks. Therefore, the objectives of this study were to (1) identify laryngeal landmarks on lateral and anterior-posterior fluoroscopic images, and (2) assess clinician and trainee accuracy and self-perception of certainty in identification of laryngeal landmarks on

fluoroscopic images. The results of this study can facilitate more accurate VFSS interpretation, leading to improved clinical training and patient care.

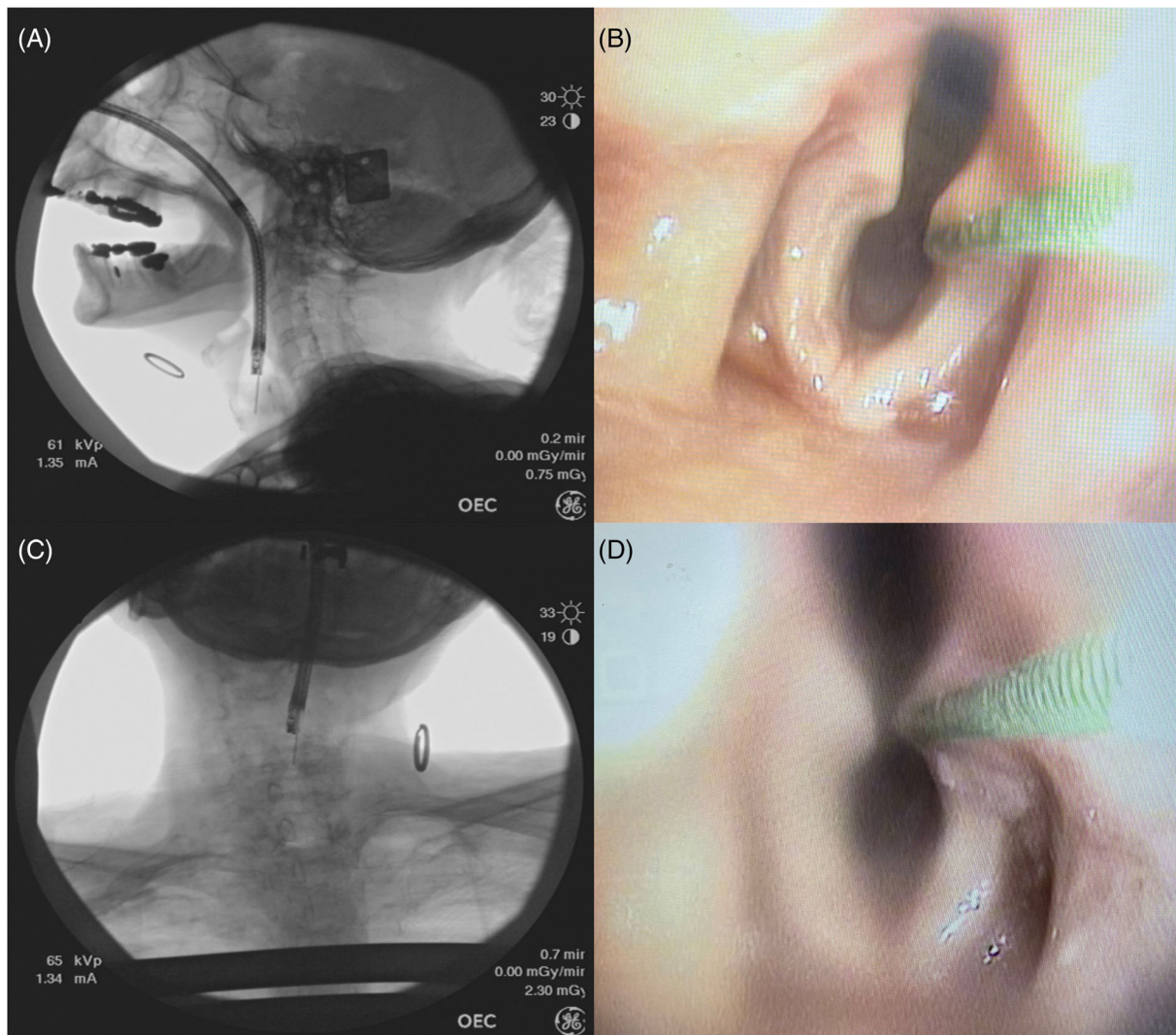
## 2 | MATERIALS AND METHODS

This study was conducted at the University of California, Davis (Sacramento, CA) under IRB approval (#1944040) and with the permission of the human body donation program at the University of California at Davis School of Medicine. All participants provided electronic consent prior to survey completion.

### 2.1 | Identification of laryngeal landmarks

A single female human fresh-frozen cadaver bust positioned within a mobile C-arm fluoroscopy system (OEC Medical Systems Mobile 9800 Radiographic/Fluoroscopic Unit, Salt Lake City, UT) was used to generate all fluoroscopic images in standard lateral and anterior-posterior (AP) projections. A cadaver model was selected because confirming the landmarks on fluoroscopy would ideally involve directly marking the structure of interest while obtaining a simultaneous fluoroscopic image. At the same time, the surrounding tissues should remain undisturbed to maintain appropriate image contrast. As a result, the study team elected to endoscopically mark laryngeal structures while performing simultaneous fluoroscopy. This procedure would be challenging to conduct in live patients given that the endoscopic marking would be physically uncomfortable and would also subject patients to extra radiation. In addition, the cadaver model allowed the study team to maintain consistency between images by securing the model in a fixed position within the fluoroscopy system.

Prior to structure identification in each projection, an unmarked fluoroscopic image of the cadaver without the endoscope in place was taken. The cadaver was then maintained in a fixed location whereas an experienced operator (B.V.M. or C.A.R.) placed a 60 cm flexible distal-chip channeled videoendoscope attached to the DEFINA EPK-3000 Video Processor (Pentax Medical, Montvale, NJ) through the nasal cavity to visualize the laryngeal structures. A 0.9 mm diameter endoscopic guidewire (Cook Medical, Bloomington, IN) was then placed through the working channel of the endoscope to directly identify a series of anatomic sites of interest. These sites were determined jointly between laryngologists and SLPs as anatomic locations of clinical significance. Sites included the true vocal folds, anterior commissure, false vocal folds, laryngeal ventricle, epiglottic tip and petiole, arytenoid, pyriform sinus, vallecula, and subglottis. The anterior cricoid cartilage was palpated and marked with a 2 mm radiopaque skin marker (PDC Healthcare, Valencia, CA).



**FIGURE 1** Simultaneous digital laryngoscopic and fluoroscopic images of the left true vocal fold in lateral (A and B) and anterior–posterior (C and D) captured during structure identification.

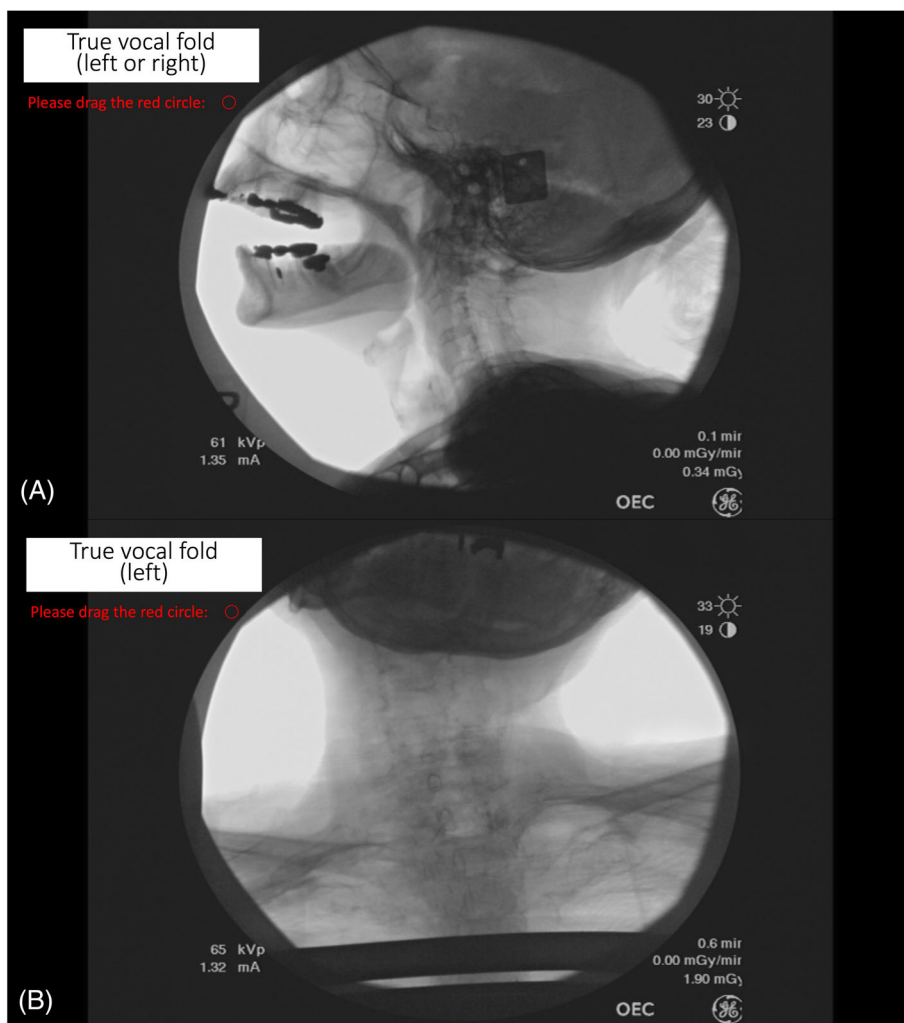
For each anatomic location, a digital laryngoscopic and fluoroscopic image was captured simultaneously (Figure 1). This process was conducted first in the lateral position then repeated in the AP position.

## 2.2 | Fluoroscopic anatomy survey

Using the captured fluoroscopic images as a guide, a fluoroscopic anatomy survey was created on PowerPoint (Microsoft Corporation, Redmond, WA). Participants were asked to identify 18 structures on a series of unmarked fluoroscopic images (9 lateral and 9 AP, resolution  $1920 \times 1080$  pixels). On each slide, participants were asked to identify an indicated structure by placing an open circle on the location on the image that they felt best represented the structure of interest (Figure 2). Decisions of which structures to include in each view were made based on clinical relevance and captured image quality. Table 1 depicts the final structures selected for presentation. Structure laterality was not distinguished on lateral view. The circle was set to a

diameter of 0.5 cm on each slide based on consensus of the authors that this size was reasonable for structure identification. This 0.5 cm equated to 0.63 cm after calibration to the image size using a 1.9 cm ring that was placed on the cadaver model during fluoroscopy.

After marking each structure, participants were then asked to rate the certainty of their answer on a Likert scale of 1 to 5 (1 = not all certain, 5 = extremely certain). Demographic information including degree, years in practice or year in training, practice setting and location, gender, prior training for VFSS interpretation, and estimated amount of time reviewing VFSS per workweek were also collected at the end of the survey. The survey was piloted with four participants, two SLPs and two resident physicians, for clarity and user-friendliness. Cognitive interviews according to recommendations for survey development<sup>11</sup> were also completed. All pilot subjects agreed the circle size felt adequate for structure identification with a reasonable room for error, and they described that their decisions for circle placement included trying to place the structure of interest within the middle of the circle.



**FIGURE 2** Sample survey questions in (A) lateral and (B) anterior–posterior views. Participants were asked to identify the indicated structure (in white box) by placing an open 0.5 cm diameter circle (0.63 cm when calibrated to image size) on the location on the image that they felt best represented the structure of interest. Participants were not asked to distinguish laterality for paired structures on lateral view.

**TABLE 1** Survey structures.

Lateral	Anteroposterior
Tip of epiglottis	True vocal fold (left)
Petiole of epiglottis	True vocal fold (right)
Apex of arytenoid (left or right) <sup>a</sup>	False vocal fold (left)
True vocal fold (left or right) <sup>a</sup>	False vocal fold (right)
Anterior commissure	Laryngeal ventricle (left)
False vocal fold (left or right) <sup>a</sup>	Laryngeal ventricle (right)
Pyriform sinus (left or right) <sup>a</sup>	Pyriform sinus (left)
Laryngeal ventricle (left or right) <sup>a</sup>	Vallecula (right)
Cricoid cartilage (anterior)	Cricoid cartilage (midline)

<sup>a</sup>Participants were not asked to distinguish laterality for paired structures on lateral view.

A convenience sample of practicing clinicians (SLPs and laryngologists) and trainees (SLP clinical fellows and otolaryngology residents) who work with patients with dysphagia were recruited to complete the survey via email. All surveys were de-identified, and two authors (N.W.Z. and B.V.M.) reviewed all responses for accuracy by comparing individual answers to corresponding images with the endoscopically located

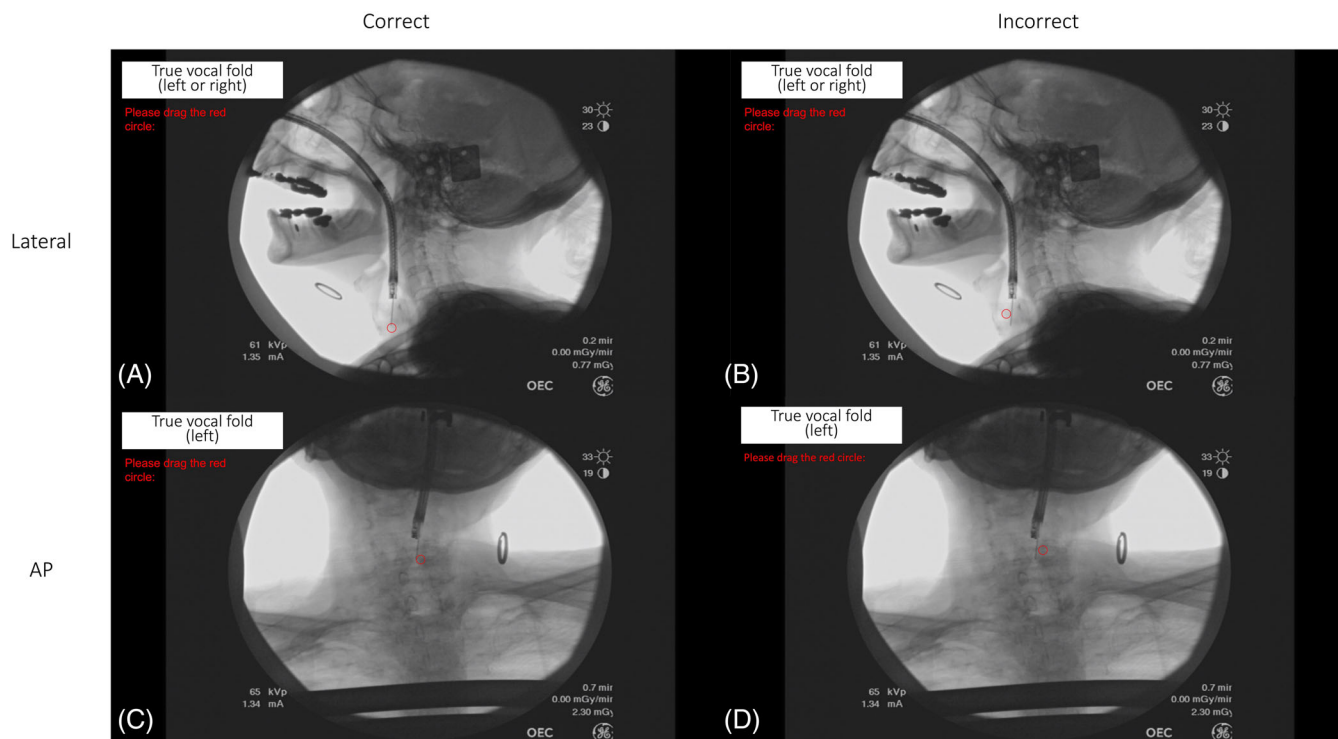
structure. A structure was judged to be accurately marked if the tip of the endoscopic wire was within the boundary of the placed circle (Figure 3). The percentage of correct identification was calculated for each subject and then compared between groups using *t*-tests (Microsoft® Excel for Mac version 6.67, Microsoft Corporation, Redmond, VA).

## 3 | RESULTS

### 3.1 | Demographics

Twenty-four individuals (11 SLPs, 13 MDs) from 6 institutions across 4 states completed structure identification (Table 2). Of those individuals, 24.7% ( $n = 10$ ) were trainees (1 SLP clinical fellow, 9 otolaryngology residents), 58.3% ( $n = 14$ ) were practicing clinicians (10 SLPs and 4 laryngologists). Years in practice ranged from 1 to 12 years, with a mean ( $\pm$ SD) of 6.6 ( $\pm$ 4.3) years. The majority ( $n = 18$ , 75.0%) of participants reported some prior training in VFSS interpretation, though the type of training was variable (e.g., self-study, on-the-job training, courses, certifications). Self-reported time looking at VFSS every week ranged from 0 to 1440 min, with a mean ( $\pm$ SD) of 255.8 ( $\pm$ 424.7) min.





**FIGURE 3** Representative answers classified as correct and incorrect in lateral and anterior–posterior (AP) views. The participants' circle was overlaid onto images with the endoscopically marked structures for comparison. (A) Correct versus (B) incorrect identification of the true vocal fold on lateral view. (C) Correct versus (D) incorrect identification of the left true vocal fold on AP view.

### 3.2 | Survey results

Mean overall accuracy was  $41.7 \pm 13.0\%$  (range 18.8–68.8%). There were no significant differences in mean overall accuracy between trainees ( $41.9 \pm 12.9\%$ ) and clinicians ( $42.0 \pm 13.1\%$ ),  $p = .97$ , or between SLPs ( $45.5 \pm 12.8\%$ ) and physicians ( $38.9 \pm 12.3\%$ ),  $p = .22$ . On average, participants were significantly more accurate identifying structures on lateral view ( $53.1 \pm 16.1\%$ ) compared to AP ( $27.3 \pm 22.8\%$ ),  $p < .001$ . As a group, SLPs were significantly more accurate on average in identifying structures on lateral view ( $59.6 \pm 13.4\%$ ) than physicians ( $46.2 \pm 16.3\%$ ),  $p = .04$ ; however, this effect disappeared when comparing only practicing SLPs ( $43.1 \pm 13.0\%$ ) and physicians ( $37.5 \pm 16.1\%$ ),  $p = .5$ . There were no significant differences in accuracy on AP view between SLPs ( $27.3 \pm 23.4\%$ ) and physicians ( $29.7 \pm 23.7\%$ ),  $p = .8$ .

Table 3 summarizes the overall number of individuals who accurately identified each structure and the respective average certainty rating of the group. Less than half of participants accurately identified the location of the laryngeal ventricle ( $n = 4$ , 16.7%), cricoid ( $n = 6$ , 25.0%), epiglottic petiole ( $n = 7$ , 29.2%), and the anterior commissure ( $n = 11$ , 45.8%) on lateral view. No structure on AP view was identified by more than 50% of participants. As whole, participant certainty about their answers was low, with only one structure, tip of the epiglottis on lateral view, receiving an average certainty rating of greater than 4 (very certain).

### 4 | DISCUSSION

The results of this present study reveal that both laryngeal landmarks and surrounding anatomy on still fluoroscopic images are challenging to identify, even for the trained clinician. In addition, clinicians are relatively uncertain about their abilities to identify these structures. Though the study is small, the outcomes highlight a potential gap in VFSS education and training. Currently, there is no agreed upon method for teaching VFSS,<sup>12</sup> and multiple studies have shown that interrater reliability for various VFSS measures is variable and even questionable when raters are not pretrained to a specific criterion.<sup>5–7,12–14</sup> Our data suggest that clinicians' abilities to recognize laryngeal anatomy on fluoroscopy may be undeveloped, which may explain some of the observed rater variability. In particular, use of scales like the PAS requires clinicians to be able to distinguish the level of the vocal folds to determine whether aspiration or penetration has occurred; however, only about 70% of the participants in our study were able to do this task accurately on lateral view. Therefore, there is an opportunity to improve clinician knowledge of anatomy on fluoroscopy, which may in turn improve our clinical assessments.

Not surprisingly, the rate of accurate structure identification on AP view was lower than lateral. Although the AP view is a recommended component of the VFSS,<sup>2</sup> it is not as thoroughly analyzed as the lateral view, and clinicians are likely not as familiar with how or where structures should appear.<sup>15</sup> Although the results in our study are not directly comparable as participants did not identify the exact

**TABLE 2** Participant demographics.

	n (%)
Degree	
SLP	11 (45.8%)
MD	13 (54.2%)
Trainee	
Yes	10 (24.7%)
No	14 (58.3%)
Trainee year (n = 10)	
PGY1	1 (10.0%)
PGY2	2 (20.0%)
PGY3	1 (10.0%)
PGY4	3 (30.0%)
PGY5	2 (20.0%)
SLP CF	1 (10.0%)
Practice setting	
Academic	22 (91.7%)
Community	2 (8.3%)
Practice location	
California	17 (70.8%)
Georgia	2 (8.3%)
Ohio	4 (16.7%)
New York	1 (4.2%)
Prior training in VFSS interpretation	
Yes	18 (75.0%)
No	5 (20.8%)
No response	1 (4.2%)

Abbreviations: CF, clinical fellow; MD, medical doctor; PGY, postgraduate year; SLP, speech-language pathologist; VFSS, videofluoroscopic swallow study.

same structures on both views, the study team felt that the structures that were queried were more clinically relevant for AP view than some of lateral structures. As a result, scores likely would have been lower if the exact same structures were presented. But even more importantly than participant scores, our study indicates that there are visible contours of the larynx on AP view that may be useful to assist VFSS structure identification.

Prior work examining how clinicians perceive fluoroscopic anatomy has been limited. However, results of our study are consistent with a 2016 study by Pisegna and Langmore that showed clinicians reported significantly reduced ability to visualize anatomical structures such as the true vocal fold(s), false vocal fold(s), arytenoid(s), and pyriform sinus(es) on VFSS compared to FEES.<sup>10</sup> Our work reveals that these structures are indeed present on fluoroscopy, but currently, clinicians have difficulty perceiving them. These findings not only underscore a need for improved training for VFSS anatomy identification and interpretation, but also highlight the need for further study of anatomical delineations on fluoroscopy.

This study has several limitations that should be considered. First, the sample size was small and was skewed toward practicing SLPs and

**TABLE 3** Frequency of accurate identification for each structure and associated mean certainty rating.

Structure	Frequency of accurate identification, n (%)	Average certainty, mean ( $\pm$ SD)
Lateral		
Tip of epiglottis	24 (100%)	4.8 ( $\pm$ 0.4)
True vocal fold	17 (70.8%)	3.2 ( $\pm$ 1.2)
Pyriform sinus	16 (66.7%)	3.3 ( $\pm$ 1.3)
False vocal fold	15 (62.5%)	2.8 ( $\pm$ 0.5)
Apex of arytenoid	12 (50.0%)	3.3 ( $\pm$ 1.1)
Anterior commissure	11 (45.8%)	2.9 ( $\pm$ 1.1)
Petiole of epiglottis	7 (29.2%)	3.5 ( $\pm$ 1.0)
Cricoid cartilage (anterior)	6 (25.0%)	2.9 ( $\pm$ 1.0)
Laryngeal ventricle	4 (16.7%)	2.3 ( $\pm$ 1.3)
Anteroposterior		
True vocal fold (right)	12 (50.0%)	2.2 ( $\pm$ 1.2)
False vocal fold (left)	9 (37.5%)	1.9 ( $\pm$ 1.1)
False vocal fold (right)	8 (33.3%)	1.8 ( $\pm$ 1.0)
Vallecula (right)	6 (25.0%)	1.6 ( $\pm$ 0.8)
True vocal fold (left)	5 (20.8%)	2.3 ( $\pm$ 1.2)
Pyriform (left)	3 (12.5%)	1.9 ( $\pm$ 0.9)
Cricoid cartilage (midline)	3 (12.5%)	1.8 ( $\pm$ 0.3)
Laryngeal ventricle (right)	1 (4.2%)	1.6 ( $\pm$ 0.9)
Laryngeal ventricle (left)	1 (4.2%)	1.6 ( $\pm$ 0.9)

otolaryngology residents in academic settings, which limits generalizable conclusions. However, we did not find evidence that those with more experience exhibit higher accuracy rates. There is also the potential for selection and nonresponse bias given participation was purely voluntary. In addition, we only used one cadaver to generate the images, so we were unable to assess the reliability of each individual's performance. Using additional cadavers could also help assess the impact of anatomic variation on clinicians' perceptions; for example, differences in structure calcification between cadavers may make some structures more easy or difficult to identify. Finally, the images were static, but clinically, fluoroscopy is interpreted in the setting of dynamic swallowing with the addition of barium, which may improve the ability to visualize mucosal structures. Future studies should investigate these factors to further elucidate the challenges of identifying laryngeal landmarks on VFSS and strategies to improve accuracy.

## 5 | CONCLUSION

The data suggest that the ability of both certified clinicians and trainees to correctly identify essential anatomic landmarks on

swallowing fluoroscopy is poor. Future work is needed to identify how we can train clinicians on the more accurate identification of essential anatomic structures on swallowing fluoroscopy.

### CONFLICT OF INTEREST STATEMENT

Clark A. Rosen reports the following disclosures and financial relationships: Olympus America Inc., consultant; Instrumentarium, royalties; Freudenberg Medical, consultant; Reflux Gourmet LCC, shareholder. Peter C. Belafsky reports the following disclosures and financial relationships: Reflux Gourmet, LLC, co-founder; Hope Medical, co-founder; California Institute of Regenerative Medicine, grant support; Innovio, grant support. The other authors have no financial relationships or conflicts of interest to disclose.

### ORCID

Nina W. Zhao  <https://orcid.org/0000-0002-9847-505X>

Lisa M. Evangelista  <https://orcid.org/0000-0002-7825-1497>

Clark A. Rosen  <https://orcid.org/0000-0003-1571-1086>

### REFERENCES

- Langmore SE. History of fiberoptic endoscopic evaluation of swallowing for evaluation and management of pharyngeal dysphagia: changes over the years. *Dysphagia*. 2017;32(1):27-38. doi:10.1007/s00455-016-9775-x
- Martin-Harris B, Canon CL, Bonilha HS, Murray J, Davidson K, Lefton-Greif MA. Best practices in modified barium swallow studies. *Am J Speech Lang Pathol*. 2020;29(2S):1078-1093. doi:10.1044/2020\_AJSLP-19-00189
- Martin-Harris B, Jones B. The videofluorographic swallowing study. *Phys Med Rehabil Clin N Am*. 2008;19(4):769-785. doi:10.1016/j.pmr.2008.06.004
- Stoeckli SJ, Huisman TAGM, Seifert BAGM, Martin-Harris BJW. Interrater reliability of videofluoroscopic swallow evaluation. *Dysphagia*. 2003;18(1):53-57. doi:10.1007/s00455-002-0085-0
- Kuhlemeier KV, Yates P, Palmer JB. Intra- and interrater variation in the evaluation of videofluorographic swallowing studies. *Dysphagia*. 1998;13(3):142-147. doi:10.1007/PL00009564
- Lee JW, Randall DR, Evangelista LM, Kuhn MA, Belafsky PC. Subjective assessment of videofluoroscopic swallow studies. *Otolaryngol Head Neck Surg*. 2017;156(5):901-905. doi:10.1177/0194599817691276
- Rosenbek JC, Robbins JA, Roecker EB, Coyle JL, Wood JL. A penetration-aspiration scale. *Dysphagia*. 1996;11(2):93-98. doi:10.1007/BF00417897
- Martin-Harris B, Brodsky MB, Michel Y, et al. MBS measurement tool for swallow impairment—MBSImp: establishing a standard. *Dysphagia*. 2008;23(4):392-405. doi:10.1007/s00455-008-9185-9
- Leonard RJ, Kendall KA, McKenzie S, Gonçalves MI, Walker A. Structural displacements in normal swallowing: a videofluoroscopic study. *Dysphagia*. 2000;15(3):146-152. doi:10.1007/s004550010017
- Pisegna JM, Langmore SE. Parameters of instrumental swallowing evaluations: describing a diagnostic dilemma. *Dysphagia*. 2016;31(3):462-472. doi:10.1007/s00455-016-9700-3
- Artino A. Developing questionnaires for educational research: AMEE guide No. 87. *Med Teach*. 2014;36(6):463. doi:10.3109/0142159X.2014.889814
- Wooi M, Scott A, Perry A. Teaching speech pathology students the interpretation of videofluoroscopic swallowing studies. *Dysphagia*. 2001;16(1):32-39. doi:10.1007/s004550000040
- Hind JA, Gensler G, Brandt DK, et al. Comparison of trained clinician ratings with expert ratings of aspiration on videofluoroscopic images from a randomized clinical trial. *Dysphagia*. 2008;24(2):211-217. doi:10.1007/s00455-008-9196-6
- McCullough GH, Wertz RT, Rosenbek JC, Mills RH, Webb WG, Ross KB. Inter- and intrajudge reliability for videofluoroscopic swallowing evaluation measures. *Dysphagia*. 2001;16(2):110-118. doi:10.1007/PL00021291
- Hazelwood RJ, Armeson KE, Hill EG, Bonilha HS, Martin-Harris B. Identification of swallowing tasks from a modified barium swallow study that optimize the detection of physiological impairment. *J Speech Lang Hear Res*. 2017;60(7):1855-1863. doi:10.1044/2017\_JSLHR-S-16-0117

**How to cite this article:** Zhao NW, MacDonald BV, Pietrowski JR, et al. Clinician accuracy in identifying essential laryngeal landmarks on swallowing fluoroscopy. *Laryngoscope Investigative Otolaryngology*. 2023;8(5):1265-1271. doi:10.1002/lio2.1127