

The spectrum and clinical sequelae of human papillomavirus infection

Bradley J. Monk^{*}, Krishnansu S. Tewari¹

*The Division of Gynecologic Oncology, Department of Obstetrics and Gynecology, The Chao Family Comprehensive Cancer Center,
University of California, Irvine-Medical Center, 101 The City Drive, Orange, CA 92868-3298, USA*

Received 25 July 2007

Abstract

Infection with the human papillomavirus (HPV) is the most common sexually transmitted disease afflicting approximately 80% of the population. HPV infection is an essential factor in cervical carcinogenesis and cervical carcinoma is the second most common cause of cancer among women worldwide. In addition to cervical cancer, other malignancies in both men and women such as esophageal, oropharyngeal, and anal cancer have been causally associated with this virus. Other gender-specific HPV-related cancers include penile, vulvar and vaginal cancer. HPV-16 is the most common HPV type associated with a malignant phenotype regardless of organ of origin. HPV-16 together with HPV-18 accounts for approximately 70% of cervical cancers. Other non-oncogenic HPV types including HPV types 6 and 11 are associated with over 90% of benign HPV-related lesions such as genital warts and juvenile respiratory papillomatosis.

© 2007 Elsevier Inc. All rights reserved.

Keywords: Human papillomavirus; Cervical cancer; Anogenital warts; Juvenile-onset recurrent respiratory papillomatosis; Anal cancer; Oropharyngeal cancer

Introduction

The human papillomavirus (HPV) is a group of epitheliotropic double-stranded DNA viruses which can infect the skin, anogenital tract, mouth, larynx and esophagus [1]. During the 1970s, zur Hausen proposed that the human papillomavirus (HPV) was integral in the development of genital tract neoplasias. Additionally, using molecular biology techniques in the 1980s, HPV DNA sequences were identified from genital warts. HPVs associated with genital tract lesions have been divided into low-risk and high-risk types based on each genotype's association with benign or malignant lesions (Table 1) [2–4]. Approximately 30 different types of HPV can infect the anogenital tract. Over 90% of genital condylomata are due to infection by HPV-6 or HPV-11. These HPV types replicate as an episome. In contrast, HPV-16 and HPV-18 can be recovered in approximately 70% of invasive cervical carcinomas. These high-risk HPV types, along with types 31,

33, 45, 51, 52, 56, 58 and 59, integrate their genetic material into the host DNA during malignant transformation.

Anogenital warts in adults

HPV is one of the most common sexually transmitted diseases (STD) in the United States. Among adolescents and young adults, HPV may be the most common STD. It is estimated that there are nearly one million new cases of genital warts diagnosed each year. Condyloma acuminata are clinically apparent in at least 1% of the sexually active population. Approximately two thirds of individuals who have sexual contact with an infected partner develop genital warts. The exact incubation time is unknown, but most investigators believe that the incubation period is approximately 3 months. Infection caused by HPV results in local infections and appears as warty papillary condylomatous lesions when caused by HPV types 6 and 11. In addition to anogenital warts, HPV infection can result in skin warts, laryngeal papillomas (laryngeal warts) and oral papilloma (oral warts) [5].

Vulvo-vaginal warts

In addition to an estimated 24 million Americans currently infected with HPV, 500,000 to 1 million new cases of genital

^{*} Corresponding author.

E-mail address: bjmonk@uci.edu (B.J. Monk).

¹ Dr Monk and Dr Tewari contributed equally to the completion of this manuscript.

Table 1
Examples of low- and high-risk oncogenic HPV genotypes

Low-risk HPV genotypes	High-risk HPV genotypes
6, 11, 42, 43, 44	16, 18 31, 33, 35, 45, 51, 52, 56, 58, 59

warts are believed to occur annually, resulting in 600,000 health care provider visits per year. Brown et al. analyzed 40 patients with exophytic condylomata acuminata for HPV DNA using Southern blot technique and hybrid capture methods [6]. HPV-6 subtypes accounted for 28 of 39 HPV-positive lesions. Eight lesions contained HPV type 11 and three contained HPV type 16.

Genital warts are generally described as classic *condyloma acuminata* which are pointed or cauliform *keratotic warts* with a thick, horny surface resembling common skin warts; *papular smooth warts*; and *flat warts* which are frequently observed on the cervix. The typical exophytic condylomas are more likely to occur on keratinized epithelium, and multiple lesions may coalesce to produce the *giant condyloma* (Fig. 1) [5].

Nearly 50% of patients have involvement of multiple sites. Although warts are often asymptomatic and discovered during a routine pelvic examination, many patients may report pruritis, burning, vaginal discharge, and even bleeding. Dyspareunia may also occur with vulvo-vaginal condyloma, and if the giant condyloma is present, obstructive symptoms at the urethra, vagina and/or rectum may manifest.

The differential diagnosis of condyloma acuminata in women includes microglandular papillomatosis, hymenal remnants, molluscum contagiosum, condyloma lata, nevi, dysplasia and cancer. It is important to recognize that warts, dysplasia and carcinoma are all epithelial lesions and may appear indistinguishable making biopsy a necessary step in diagnosis. A higher index of suspicion for malignancy should be maintained in the presence of an immunocompromised patient, the presence of a large, atypical lesion, lesions refractory to treatment, pigmented lesions, and in patients older than 40 years.

Perianal warts

Although the vulva is the most common site for lesions among women, it is important to inspect the perianal region

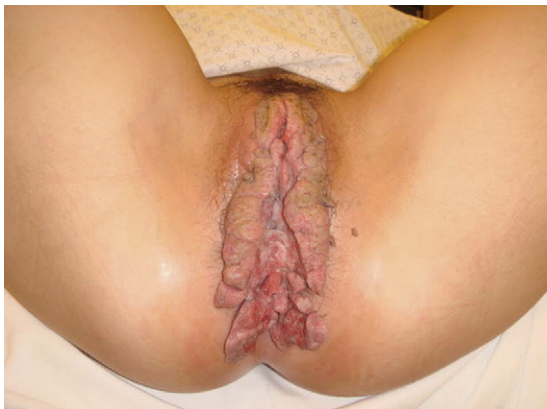

Fig. 1. Giant condyloma.

because up to 25% of patients with vulvo-vaginal condyloma will also have perianal condyloma seen as well (Fig. 2) [7]. Although those who engage in anal intercourse have a higher frequency of perianal condylomata, the majority of patients with perianal condylomata have not engaged in anal intercourse. Infection is believed to occur due to pooling of secretions in the anal area.

Of 33 perianal and/or anal condylomata in which HPV DNA was detected, Duggan et al. determined that 13 contained HPV-6 and -11, 12 HPV-6, 7 HPV-11, and 1 HPV-6, -11 and -18 [8]. These observations suggest that the cloacogenically derived anal epithelium is susceptible to infection by the same HPV types which infects the similarly derived epithelium of the lower female genital tract.

Typically pink-to-brown papules or nodules will converge on the anus. Like vulvo-vaginal condyloma and penile warts (discussed below), perianal warts should be treated as they tend to spread quickly to sexual partners. Tincture of 5% podophyllin is the most popular treatment. If left untreated, the warts may coalesce into a large mass and extend into the rectum. In these cases, surgical treatment is required. If a partner has perianal warts, they should also be checked for vulvo-vaginal wart or a penile wart. Perianal warts are also common in men having sex with men, who are prone to harbor other venereal disorders, including HIV disease.

Penile warts

Condyloma acuminata in men may also develop on the penis, and when they do, most commonly involve the glans penis, penile shaft and prepuce (Fig. 3) [9]. Involvement of the meatus and urethra occurs only rarely and constitutes a greater therapeutic

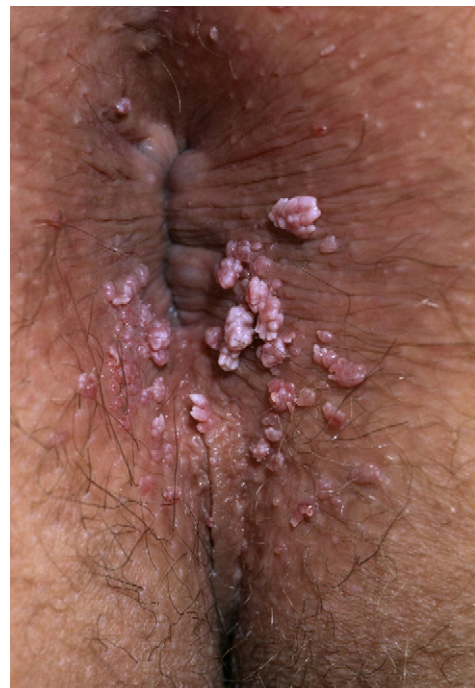

Fig. 2. Perianal warts.

challenge. Once again, when these lesions occur on the penis, they are linked to HPV infection [10]. O'Brien et al. studied 26 men with penile condyloma and found that lesions were caused by HPV types 6, 11 and 31 and uncharacterized types [11]. Five patients had penile shaft and urethral condyloma.

Nielson et al. tested 463 men ages 18 to 40 years for HPV at the glans/corona, penile shaft, scrotum, urethra, perianal area, anal canal and in a semen sample [12]. Subjects acknowledged no history of genital warts and had penile–vaginal intercourse within the past year. When HPV results from any sampling site were considered, 237 (51.2%) men were positive for at least one oncogenic or nononcogenic HPV type, and another 66 (14.3%) men were positive for an unclassified HPV type. The type with the highest prevalence was HPV-16. External genital samples (glans/corona, shaft and scrotum) were more likely than anal samples to contain oncogenic HPV (25.1% versus 5.0%). HPV-positive penile shaft and glans/corona samples were also more likely to be infected with multiple HPV types than other sites. It appears that the use of penile and urethral brushing is the most accurate method to diagnose HPV infection in men [13].

Treatment of anogenital warts

A variety of therapies exist for treatment of anogenital warts (Table 2). The goal of therapy is to eliminate as many of the visible lesions as possible until the patient's immune system can control viral replication. Because of the phenomenon of spontaneous regression, the need to treat subclinical or mild disease continues to be debated. Unfortunately, HIV-positive or immunosuppressed patients will often require more than one treatment modality to manage refractory condyloma. Before any ablative therapy is performed, a biopsy is considered

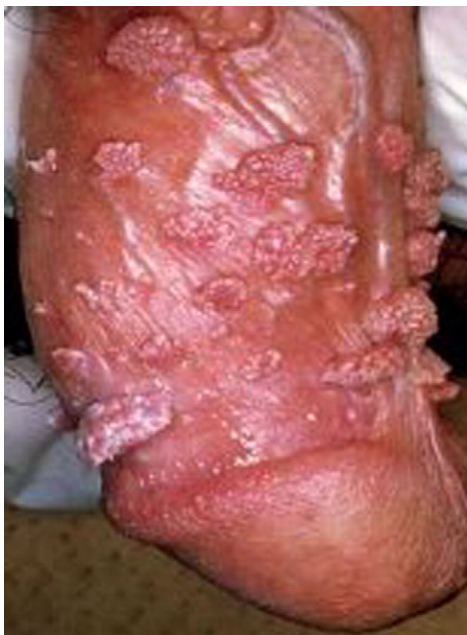

Fig. 3. Penile warts.

Table 2

Guidelines for the treatment of external genital warts

Patient administered	Health care provider administered
0.5% Podofilox	10%–25% podophyllin resin
5% Imiquimod cream	80%–90% BCA/TCA
Veregen (green tea catechins)	Cryotherapy
	Surgical removal
	Laser vaporization
	Intralesional interferon

prudent as verrucous carcinomas may be misdiagnosed as a wart, and the anal lesion of syphillis (condyloma latum) is usually flat, but when raised, may resemble condyloma acuminatum. The long-term consequences of HPV infection are of major concern and continued surveillance of patients treated for anogenital warts is mandatory as infection with other (i.e., high-risk) HPV subtypes has been associated with the development of cervical, vulvar, anal, penile and oropharyngeal cancer (Table 3) [14].

HPV infection in children

The incidence of anogenital warts in children has paralleled the five-fold rise in the incidence of this condition in adult outpatient visits over the preceding four decades [15]. The presence of anogenital warts in the pediatric population not only represents a diagnostic and therapeutic challenge, but is inherently problematic due to potentially long latency periods, several possible modes of transmission and varying sensitivity of detection techniques. Particular attention must be focused on the requirement of reporting cases of anogenital warts in children suspected of child sexual abuse.

HPV infection in children manifests in the genital and respiratory tracts as each of these sites lies along the inoculation path during perinatal (i.e., vertical) transmission and sexual abuse during childhood [15]. Vertical transmission of HPV can occur via *in utero* exposure to amniotic fluid or transmission of HPV from the maternal genital tract. Some studies have noted an increase in anogenital HPV infections among susceptible populations during pregnancy, with

Table 3

Worldwide data for cancers attributable to infection with oncogenic types of HPV. Adapted from Parkin et al. [14]

Site	Total cancers (No.)	Attributable fraction ^a (%)	Attributable cancers (No.)	% of all cancer
Cervix	492,800	100	492,800	4.5
Penis	26,300	40	10,500	0.1
Vulva, vagina	40,000	40	16,000	0.2
Anus	30,400	90	27,400	0.2
Mouth	274,100	3	8200	0.1
Oropharynx	52,100	12	6300	0.1
All sites	10,843,600		561,200	5.2

HPV = human papillomavirus.

^a Attributable fraction accounts for the proportion of a specific cancer that could be avoided if the agent responsible was eliminated.

condyloma peaking during the third trimester. Large lesions may obstruct labor, and during vaginal delivery, the virus can be transmitted to the fetus, resulting in laryngeal papillomas. Cesarean delivery appears to be at least partially effective in preventing the acquisition of laryngeal papillomas and anogenital warts in infants [15].

Although the incubation period for children is not known with certainty, a period of several months typically elapses between viral infection at delivery and clinical manifestations in the infant. Treatment of condyloma in the infant includes excision under general anesthesia or the use of the medical therapies listed above although experience in this population is limited.

It is very disturbing that the majority of cases of childhood condyloma manifest beyond a reasonable incubation period following vertical transmission, suggesting the probability of child sexual abuse. Sexual abuse increases with age, with a report by Sinclair et al. noting that children ages 4 to 8 years old with anogenital warts were 2.9 times as likely and those 8 to 12 years old were 12.1 times as likely to have been sexually abused as those younger than 4 years old [16]. Among 1316 children ages 6 to 11 years in the United States, Dunne et al. noted that the prevalence of HPV-16 antibodies was 2.4% [17].

Anogenital warts in children

The mean age at presentation for anogenital warts in children ranges from 2.8 to 5.6 years [15]. Most children present because of a small flesh-colored papulae are noted by their caretaker. The lesions can develop rapidly into clusters of flat, papillomatous or pedunculated lesions, and occasionally larger cauliflower- or strawberry-type masses may develop. In girls and boys, the perianal site is the most common occurring in 37% and 57%, respectively. The labial site accounts for 23% in girls. Girls may also have warts on the hymen or in the vestibular fossa. In boys the penis and scrotum sites account for 17%. HPV types 6 and 11 account for 39–90% of anogenital warts in children. Most children are asymptomatic, although some warts can be a source of itching, burning and bleeding. Some children may complain of pain and/or bleeding with bowel movements, and girls with periurethral warts may experience dysuria.

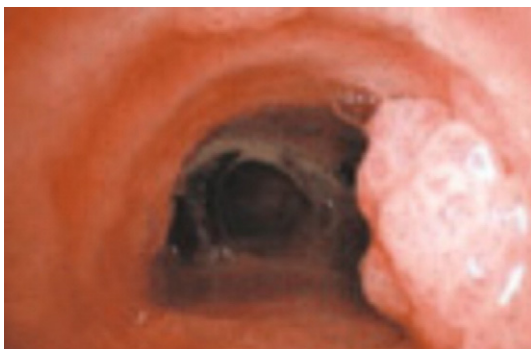

Fig. 4. Juvenile-onset recurrent respiratory papillomatosis. Copyright© 2005 Massachusetts Medical Society. All rights reserved.

Juvenile-onset recurrent respiratory papillomatosis (JO-RRP)

The primary form of JO-RRP is the laryngeal papilloma (Fig. 4). This is the most common tumor of the larynx in childhood worldwide. The prevalence of JO-RRP among children in the United States is 1.7–2.6 per 100,000, with an equal distribution among boys and girls [15]. When the disease persists over years, significant physical and emotional sequelae ensue leading to more than \$100 million in health care expenditures annually. The mean age at diagnosis is 4.0 years, and many children will require ≥ 5 surgeries annually following the diagnosis. Laryngeal papillomas manifest as progressive hoarseness, stridor and cough. Like benign genital warts, the predominant HPV types found in laryngeal papilloma include HPV-6 and -11.

The association of HPV with human cancer

Cervical cancer

Due to widespread acceptance of Papanicolaou screening in this country, both the incidence and mortality rates of cervical cancer have declined dramatically during the preceding half century. The American Cancer Society estimates that for 2007 there will be 11,150 new cases of invasive cervical cancer diagnosed and 3670 deaths from this disease [18]. In our country, the racial incidences are led by the Hispanic/Latino population at 16.8 women per 100,000 followed by black (12.4), Asian and Pacific Islander (10.2), white (9.2), and American Indian and Alaskan native (6.9). Unfortunately, because most of the world is poor there is a lack of access to cervical cancer screening for most women and as a result cervical cancer remains a global disease of epidemic proportions, causing at least 250,000 deaths annually.

The majority of cervical carcinomas are squamous cell cancers and develop in the transformation zone of the cervix where the columnar epithelium of the endocervical canal is replaced by a stratified squamous epithelium of the ectocervix through squamous metaplasia. When dysplasia (i.e., pre-invasive disease) is suspected by abnormal cervical cytology, colposcopic examination of the cervix with acetic acid staining and biopsy is often required for confirmation. Cervical intraepithelial neoplasia (CIN, dysplasia) is graded in severity from I to III. Although a significant proportion of CIN I and/or II will spontaneously regress (Table 4), [19] the majority of cases of CIN III will require some form of ablative treatment, including cryotherapy, CO₂ laser vaporization or excisional biopsy. The median age at diagnosis for cervical dysplasia and invasive cancer is 29 years and 47 years, respectively.

Patients typically remain asymptomatic during the dysplastic and microinvasive phases of cervical cancer. However, once the cancer is clinically visible on the cervix patients may report increased vaginal discharge and/or abnormal vaginal bleeding which may occur after sexual intercourse, between menstrual periods or following menopause (Fig. 5). Locally advanced disease may result in lower extremity pain and/or swelling, flank discomfort, rectal bleeding, hematuria and fistulae. Metastases may produce bone fracture, gastric outlet obstruction and/or hemoptysis.

Table 4
Natural history of cervical intraepithelial neoplasia [19]

Lesion type	Regression (%)	Persistence (%)	Progression to CIN 3 (%)	Invasion (%)
CIN 1	60	30	10	1
CIN 2	40	40	20	5
CIN 3	33	–	–	>12

CIN=cervical intraepithelial neoplasia.

The epidemiologic and molecular evidence linking oncogenic HPVs to human cancer is strongest for cervical cancer (Tables 5 and 6) [20]. In one of the earliest studies, Shirasawa et al. detected HPV-16 DNA in 23% of mild dysplasias, 32% of moderate dysplasias, 55% of severe dysplasias and 62% of carcinomas in situ [21]. The investigators also detected virus–cell junction sequences in 86% of dysplasias, suggesting that the integration of HPV-16 DNA occurs in the precancerous stage.

Later, Burger et al. tested the hypothesis that differences in survival among patients with invasive cervical carcinoma may be associated with HPV DNA type [22]. The investigators studied fresh primary tumor tissue samples from 291 women with all stages of cervical carcinoma. After a median follow-up of 38.9 months only stage was predictive of survival in the entire study population. However, among the 171 patients treated with surgery, multivariate analysis determined that lymph node status, depth of stromal invasion and the presence of HPV-18 DNA were statistically significant predictors of survival.

Vulvar cancer

Vulvar cancer accounts for about 4% of all gynecological cancers and typically affects women during the 7th and 8th decades of life. Younger women with risk factors (e.g., HPV infection, immunosuppression) are also at risk. During 2007, it is estimated that 3490 new cases of vulvar cancer will be diagnosed in the United States and 880 deaths from this disease will occur [18]. Just as squamous cell carcinoma of the cervix is preceded by an intraepithelial neoplastic process that lends itself to study and treatment, the vast majority of cases of squamous cell carcinoma of the vulva also follow an intraepithelial precursor lesion called vulvar intraepithelial neoplasia (VIN, Fig. 6).

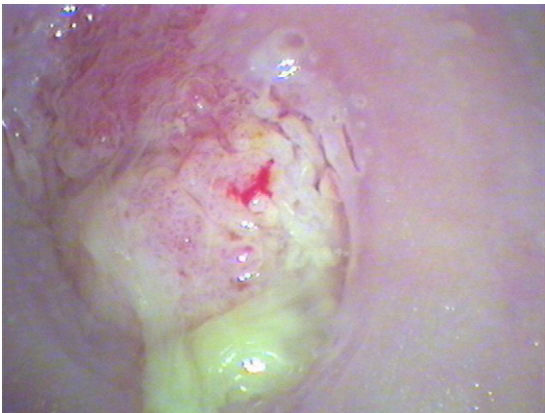

Fig. 5. Cervical cancer.

Table 5
Incidence of HPV types in patients with cervical cancer compared with control women [21]

HPV type	% of infected patients (n=1739)	% of infected controls (n=259)
HPV-16	54.6	24.3
HPV-18	11.0	7.3
HPV-16 and -18	2.1	1.2

HPV=human papillomavirus.

A widely accepted grading system for the degrees of severity of VIN has been published by the International Society for the Study of Vulvovaginal Diseases and includes VIN I, VIN II and VIN III, the latter representing severe dysplasia or carcinoma in situ (Table 7) [23]. The lesion(s) of VIN are varied in presentation with respect to location on the vulva, size, regularity and pigmentation. Patients with VIN are often asymptomatic and in these cases the lesion(s) are only discovered during an otherwise routine pelvic examination. Some patients, however, may report pruritis or occasional burning. A biopsy is always recommended for any new vulvar lesion.

The most common histologic type of invasive vulvar cancer is the squamous cell carcinoma. A verrucous carcinoma is a subtype of the squamous cell cancer and tends to appear as a slowly growing wart. Typically a lesion is present in the form of a lump or ulceration, often associated with itching, irritation, sometimes local bleeding and discharge. Also dysuria, dyspareunia and pain may be noted. Because of modesty or embarrassment, symptoms may not be heeded in a timely fashion.

Most squamous cell carcinomas are unifocal and originate primarily in the labia majora. Other areas affected include the clitoris, fourchette and the local glands. The lymphatic drainage of the labia proceeds to the upper vulva and mons then to the inguinal and femoral nodes. The tumor may also invade adjacent organs such as the vagina, urethra and rectum and spread via their lymphatics.

As in the case of CIN and cervical cancer, a role for HPV infection in the development of a significant proportion of cases of VIN and vulvar cancer has been established [24]. Indeed, the increased occurrence of high-risk human papillomavirus (HPV) infection seems to be associated with the increasing frequency of VIN. Hillemans et al. noted that 24 of 30 VIN lesions (80%) harbored HPV-16 (n=23) and HPV-18 DNA [25]. Integration of HPV-16 and HPV-18 genome was observed in eight (38.1%) of 21 HPV-16/18 positive VIN III cases.

Table 6
Risk of squamous cell cervical cancer associated with various HPV types [21]

HPV type	Patients (%)	Controls (%)	Odds ratio	95% CI
Overall	96.6	15.6	158.2	(113.4–220.6)
HPV-16	50.5	3.3	434.5	(278.2–678.7)
HPV-18	13.1	1.3	248.1	(138.1–445.8)
HPV-16 and -18	2.7	0.2	327.7	(95.7–1119.1)
HPV-45	5.5	0.7	197.6	(91.7–425.7)
HPV-31	2.7	0.6	123.6	(53.5–286.0)
HPV-52	2.7	0.3	200.0	(67.8–590.1)

CI=confidence interval; HPV=human papillomavirus.

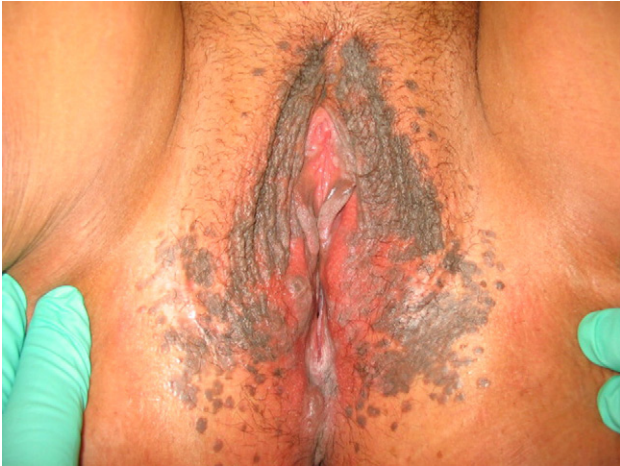

Fig. 6. Vulvar intraepithelial neoplasia.

Monk et al. sought to determine the histopathologic, epidemiologic and prognostic significance of human papillomavirus (HPV) DNA in 55 vulvar cancers [26]. Thirty-three tumors (60%) contained HPV DNA. The authors noted that HPV DNA was more common in vulvar cancers of young women who smoke than in older nonsmokers. Using life-table analysis, the absence of HPV DNA and the presence of regional nodal metastasis were predictive of recurrence and death from vulvar cancer. When controlling for lesion size, age, tumor grade and nodal metastasis using the Cox proportional hazards model, only HPV status remained an independent prognostic factor.

Anal cancer

Squamous cell carcinoma of the anus is rare and accounts for only 1.5% of cases of gastrointestinal tract cancer in the United States. The age-adjusted incidence rate is 1.5 per 100,000 and Surveillance Epidemiology and End Results (SEER) data from 1975 to 2003 suggest that the incidence is rising. For 2007, cancers of the anus, anal canal and anorectum are estimated to approach 4650 in the United States, including 1900 cases in males and 2750 cases in females [18]. It is estimated that a total of 690 deaths from anal cancer will occur in 2007 of which 260 will be in males and 430 in females. Patients may report rectal bleeding or anal pruritis, pain and/or change in stool width. If bleeding is mistakenly attributed to hemorrhoids, a potential delay in diagnosis may occur. Early stage anal cancers may be asymptomatic but detectable upon digital examination of the canal.

Historically, anal cancer was believed to result of chronic irritation due to hemorrhoids, fissures and/or inflammatory

bowel disease. Contemporary studies have replaced these risk factors with new ones including a history of persistent high-risk genotype HPV infection, infection with multiple HPV genotypes, cervical dysplasia or cancer, HIV seropositivity, low CD4 count, cigarette smoking, anoreceptive intercourse and immunosuppression following solid organ transplant [27]. Tachezy et al. detected HPV-16 in 18 of 22 anal SCCA specimens (81.8%) [28]. Palefsky et al. studied 24 anal tissue specimens and found that HPV-16 was associated exclusively with high-grade AIN and invasive cancer [29]. HPV types 6 and 11 were associated with condyloma and low-grade AIN.

The precursor lesion, anal intraepithelial neoplasia (AIN) (Fig. 7), is usually detected by chance during routine hemorrhoidectomy or excision of anal warts. The value of anal cytology as a screening tool has been debated. Fox et al. reported their results from an anoscopy clinic established in the United Kingdom for patients with unexplained anal symptoms, suspicious lesions in the anal canal, those diagnosed with AIN following routine anal surgery, as well as for some asymptomatic patients who had fears about anal cancer [30]. The ‘anal Pap tests’ were obtained using the Palefsky method from San Francisco which involves inserting a Dacron swab blindly 3 cm into the anal canal and gradually withdrawing it in a spiral motion with outward pressure applied on the anal canal. The investigator’s reported a sensitivity of 83% and a specificity of 38% for AIN, which is comparable with that reported for cervical cytology.

Penis cancer

After accounting for cancers of the prostate and testis, it is estimated that primary carcinoma of the penis and other male genital organs will be diagnosed in 1280 patients in 2007 in the United States [18]. Two hundred and ninety deaths from penile carcinoma are projected for this year. Risk factors for penile cancer include HPV infection, smoking, smegma, phimosis, treatment of psoriasis, age and AIDS. A draining sore on the foreskin or glans of the penis may be a sign of penile cancer. Evidence suggests that circumcision in childhood reduces the incidence of penile cancer by decreasing the risk of HPV infection in males, however, the American Medical Association has stated that the use of infant circumcision to prevent penile cancer in adulthood is not justified.

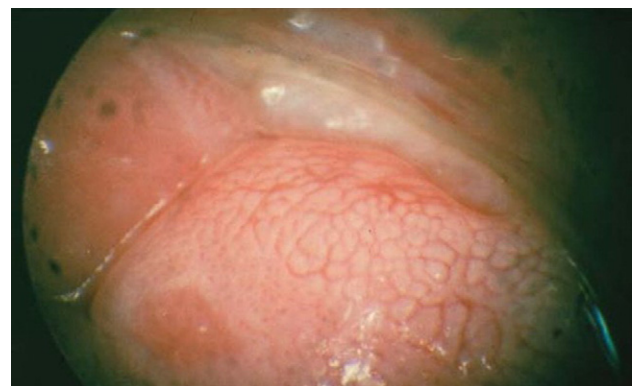


Fig. 7. Anal intraepithelial neoplasia.

Table 7
International society for the study of vulvo-vaginal diseases classification of vulvar intraepithelial neoplasia (VIN) [23]

Squamous intraepithelial neoplasia	VIN 1
	VIN 2
	VIN 3 (severe dysplasia or carcinoma in situ)
Non-squamous intraepithelial neoplasia	Paget’s disease Tumors of melanocytes, non-invasive

The lesions of the precursor, penile intraepithelial neoplasia (PIN), are often flat and measure between 0.2 and 3.5 cm in diameter. They have a reddish or slight brown coloring with a smooth, glistening, sometimes verrucous surface. Lesions may be solitary or multiple which may coalesce to form plaques. The most frequent type of HPV linked to PIN is HPV-16. Previous reports have confirmed that high-risk males whose partners are women with cervical cancer have a higher incidence of penile carcinoma. For example, Barrasso et al. used penoscopy with acetic acid to evaluate the male sexual partners of women with cervical flat condyloma ($n=294$) or CIN ($n=186$) [31]. Condylomata acuminata, papules and macules were observed in 64.4% of the 480 men (64.4%). PIN was found in 61 partners (32.8%) of women with cervical intraepithelial neoplasia. HPV types 6, 11 and 42 were found in lesions showing features of condyloma or minimal histologic changes. HPV-16 and -33 were almost exclusively found in PIN.

Cupp et al. studied HPV DNA in 42 cases of invasive penile cancer, 13 of carcinoma in situ, 12 of PIN, as well as 29 routine neonatal and 32 adult circumcision specimens [32]. Overall, the detection rates for HPV DNA were 55% for invasive squamous cell carcinoma, 92% for carcinoma in situ, 92% for penile intraepithelial neoplasia, 0% for neonatal circumcision and 9% for adult circumcision. In all groups, HPV-16 was the most common genotype identified.

Oropharyngeal cancer

Oropharyngeal cancer typically occurs during the fifth through seventh decades of life, with men being afflicted 3 to 5 times more than women. In 2007, 34,360 oropharyngeal cancers will be diagnosed among men ($n=24,180$) and women ($n=10,180$) in the United States [18]. It is estimated that 5180 men and 2370 women will die from oropharyngeal cancers in 2007. Two precursor lesions, leukoplakia and erythroplakia, have been identified, with the latter being more likely to progress to dysplasia and carcinoma.

Tobacco and alcohol abuse represent the most significant risk factors for the development of oropharyngeal cancer. Additional risk factors include a diet poor in fruits and vegetables, consumption of the South American stimulant mate, the chewing of the Asian betel quid preparation and infection with HPV-16.

Squamous cell carcinomas make up the vast majority of these malignancies and patients may present with a neck mass or neck pain due to adenopathy, dysphagia, odynophagia, weight loss, mouth bleeding and/or sinus congestion.

D'Souza et al. performed a case-control study of 100 patients with newly diagnosed oropharyngeal cancer and 200 controls to evaluate the associations between HPV and oropharyngeal cancer [33]. Interestingly, a high lifetime number of vaginal-sex partners (≥ 26) was associated with oropharyngeal cancer as was a high lifetime number of oral-sex partners (≥ 6). Oropharyngeal cancer was significantly associated with oral HPV-16 infection and seropositivity for the HPV-16 capsid protein. HPV-16 capsid protein seropositivity was highly associated with oropharyngeal cancer among subjects with a history of heavy tobacco and alcohol use and among those

without such a history. HPV-16 DNA was detected in 72% of 100 paraffin-embedded tumor specimens. HPV-positive oropharyngeal cancers may represent a distinct disease entity that is associated with an improved prognosis.

Other neoplastic disorders

Vaginal intraepithelial neoplasia (VAIN)

After accounting for cancers of the uterine cervix, uterine corpus, ovary and vulva, it is estimated that there will be 2140 new cases of vaginal and other gynecologic cancers in 2007 and 790 deaths from these diseases [18].

The incidence of the precursor lesion, VAIN, is unknown, but it is estimated that in the United States there are at least 0.2 to 0.3 cases per 100,000 women. It has been noted that the diagnosis of this entity has increased over the past several decades, most likely as a consequence of heightened awareness, expanded cytologic screening and liberal use of colposcopy. Much of our information on this rare entity represents an extrapolation of knowledge from the natural history of CIN and VIN which occur more commonly. Multiple risk factors have been implicated including HPV infection of other genital tract sites, history of vaginal condyloma, HIV infection, genetic and acquired immunosuppression (including HIV infection), low family income and low level of education. The mean age at diagnosis occurs between the ages of 43 and 60 years.

Sroden et al. compared the distribution of HPV types in 33 cases of VIN I, 34 cases of VIN III, 17 cases of VAIN I and 16 cases of VAIN III and noted that a significant number of low-grade vulvar and vaginal lesions contain high-risk HPV types [34].

Esophageal cancer

Cancers of the esophagus are expected to be diagnosed in 12,130 men and 3430 women (total of 15,560 patients) in the United States during 2007 [18]. Ten thousand and nine hundred men and 3040 women are expected to die in 2007. Esophageal tumors usually lead to dysphagia and odynophagia. Fluids and soft foods may be tolerated, but hard, bulky substances (e.g., bread and meat) create significant difficulty. Weight loss and burning, spasmodic pain may be experienced by some patients along with an unusually husky or raspy voice. When the tumor disrupts normal peristalsis, nausea, vomiting, regurgitation of food, coughing and aspiration pneumonia may develop. Finally, some patients may present with hematemesis, superior vena cava syndrome and esophageal-tracheal fistula.

Syrjanen noted that among 1485 squamous cell carcinomas of the esophagus, 22.9% were positive for HPV DNA [35]. In light of the highly variable geographic incidence rates of esophageal carcinoma worldwide, it is likely that oncogenic HPVs play an important causal role in high-risk areas.

Summary

Research has shown that HPV infection is the primary cause of almost all cases of cervical cancer. Evidence also indicates

that HPV infection may cause a proportion of cancers of the anus, vulva, vagina, penis and oropharynx. Infection with high-risk HPV types (e.g., HPV-16 and 18) increases the likelihood of viral persistence, HPV transmission and cancer.

Low-risk HPVs (e.g., HPV-6 and 11) very rarely induce malignant transformation but are associated with other benign neoplastic lesions such as warts and JO-RRP.

Questions and answers

Which forms of cancer are associated with HPV- infection?

Research has shown that HPV infection is the primary cause of almost all cases of cervical cancer. Evidence also indicates that HPV infection may cause a proportion of cancers of the anus, vulva, vagina, and penis as well as some cancers of the oropharynx.

Which strains of HPV are associated with genital warts?

Infection caused by HPV results in local infections and appears as warty papillary condylomatous lesions when caused by HPV types -6 and -11. In addition to anogenital warts, HPV infection can result in skin warts, laryngeal papillomas (laryngeal warts) and oral papilloma (oral warts) [5]. Of 33 perianal and/or anal condylomata in which HPV DNA was detected, in a study performed by Duggan et al., 13 condylomata contained HPV-6 and -11, 12 HPV-6, 7 HPV-11, and 1 HPV-6, -11 and -18 [8]. These observations suggest that the cloacogenically derived anal epithelium is susceptible to infection by the same HPV types which infect the similarly derived epithelium of the lower female genital tract.

Conflict of interest statement

BM serves on Speaker's Bureaus for Merck, GlaxoSmithKline and Digene. KT declares that he has no conflict of interest.

References

- [1] Tewari KS, Taylor JA, Liao SY, DiSaia PJ, Burger RA, Monk BJ, et al. Development and assessment of a general theory of cervical carcinogenesis utilizing a severe combined immunodeficiency murine-human xenograft model. *Gynecol Oncol* 2000;77:137–48.
- [2] Tyring SK. Human papillomavirus infections: epidemiology, pathogenesis, and host immune response. *J Am Acad Dermatol* 2000;43:S18–26.
- [3] Sellors JW, Mahony JB, Kaczorowski J, et al. Prevalence and predictors of human papillomavirus infection in women in Ontario, Canada. Survey of HPV in Ontario Women (SHOW) Group. *CMAJ* 2000;163:503–8.
- [4] IARC monographs programme on the evaluation of carcinogenic risks to humans. Human papillomaviruses (HPV). Lyon, France: International Agency for Research on Cancer, 1995.
- [5] Gunter J. Genital and perianal warts: new treatment opportunities for human papillomavirus infection. *Am J Obstet Gynecol* 2003;189:S3–S11.
- [6] Brown DR, Bryan JT, Cramer H, Fife KH. Analysis of human papillomavirus types in exophytic condylomata acuminata by hybrid capture and Southern blot techniques. *J Clin Microbiol* 1993;31:2667–73.
- [7] Handley JM, Maw RD, Lawther H, et al. Human papillomavirus DNA detection in primary anogenital warts and cervical low-grade intraepithelial neoplasias in adults by in situ hybridization. *Sex Transm Dis* 1992;19: 225–9.
- [8] Duggan MA, Boras VF, Inoue M, et al. Human papillomavirus DNA determination of anal condylomata, dysplasias, and squamous carcinomas with in situ hybridization. *Am J Clin Pathol* 1989;92:16–21.
- [9] Watson RA. Human papillomavirus: confronting the epidemic—A urologist's perspective. *Rev Urol* 2005;7:135–44.
- [10] Lassus J, Niemi KM, Syrjanen S, et al. A comparison of histopathologic diagnosis and the demonstration of human papillomavirus-specific DNA and proteins in penile warts. *Sex Transm Dis* 1992;19:127–32.
- [11] O'Brien WM, Jensen AB, Lancaster WD, Maxted WC. Human papillomavirus typing of penile condyloma. *J Urol* 1989;141:863–5.
- [12] Nielson CM, Flores R, Harris RB, et al. Human papillomavirus prevalence and type distribution in male anogenital sites and semen. *Cancer Epidemiol Biomarkers Prev* 2007;16:1107–14.
- [13] Giovaneneli L, Migliore MC, Capra G, et al. Penile, urethral, and seminal sampling for diagnosis of human papillomavirus infection in men. *J Clin Microbiol* 2007;45:248–51.
- [14] Parkin DM. The global health burden of infection-associated cancers in the year 2002. *Int J Cancer* 2006;118:3030–44.
- [15] Sinal SH, Woods CR. Human papillomavirus infections of the genital and respiratory tracts in young children. *Semin Pediatr Infect Dis* 2005;16:306–16.
- [16] Sinclair KA, Woods CR, Kirse DJ, Sinal SH. Anogenital and respiratory tract human papillomavirus infections among children: age, gender, and potential transmission through sexual abuse. *Pediatrics* 2005;116:815–25.
- [17] Dunne EF, Karem KL, Sternberg MR, et al. Seroprevalence of human papillomavirus type 16 in children. *J Infect Dis* 2006;191:1817–9.
- [18] Jemal A, Siegel R, Ward E, et al. Cancer statistics. *CA Cancer J Clin* 2007;57:43–66.
- [19] Ostor AG. Natural history of cervical intraepithelial neoplasia: a critical review. *Int J Gynecol Pathol* 1993;12:186–92.
- [20] Shirasawa H, Tomita Y, Kubota K, et al. Detection of human papillomavirus type 16 DNA and evidence for integration into the cell DNA in cervical dysplasia. *J Gen Virol* 1986;67:2011–5.
- [21] Munoz N, Bosch FX, de Sanjose S, et al. Epidemiologic classification of human papillomavirus types associated with cervical cancer. *N Engl J Med* 2003;348:518–27.
- [22] Burger RA, Monk BJ, Kurosaki T, et al. Human papillomavirus type 18: association with poor prognosis in early stage cervical cancer. *J Natl Cancer Inst* 1996;88:1361–8.
- [23] Ridley CM, Frankman O, Jones IS, et al. New nomenclature for vulvar disease. International Society for the Study of Vulvar Disease. *Hum Pathol* 1989;20:495–6.
- [24] Gastrell FH, McConnell DT. Human papillomavirus and vulval intra-epithelial neoplasia. *Best Practices Res Clin Obstet Gynaecol* 2001;15:769–82.
- [25] Hillemanns P, Wang X. Integration of HPV-16 and HPV-18 DNA in vulvar intraepithelial neoplasia. *Gynecol Oncol* 2006;100:276–82.
- [26] Monk BJ, Burger RA, Lin F, et al. Prognostic significance of human papillomavirus DNA in vulvar carcinoma. *Obstet Gynecol* 1995;85:709–15.
- [27] Uronis HE, Bendell JC. Anal cancer: an overview. *Oncologist* 2007;12:524–34.
- [28] Tachezy R, Jirasek T, Salakova M, et al. Human papillomavirus infection and tumours of the anal canal: correlation of histology, PCR detection in paraffin sections and serology. *APMIS* 2007;115:195–203.
- [29] Palefsky JM, Holly EA, Gonzales J, et al. Detection of human papillomavirus DNA in anal intraepithelial neoplasia and anal cancer. *Cancer Res* 1991;51:1014–9.
- [30] Fox PA, Seet JE, Stebbing J, et al. The value of anal cytology and human papillomavirus typing in the detection of anal intraepithelial neoplasia: a review of cases from an anoscopy clinic. *Sex Transm Infect* 2005;81:142–6.
- [31] Barrasso R, De Brux J, Croissant O, Orth G. High prevalence of papillomavirus-associated penile intraepithelial neoplasia in sexual partners of women with cervical intraepithelial neoplasia. *N Engl J Med* 1987;317:916–23.
- [32] Cupp MR, Malek RS, Goellner JR, et al. The detection of human papillomavirus deoxyribonucleic acid in intraepithelial, in situ, verrucous and invasive carcinoma of the penis. *J Urol* 2005;174:1024–9.
- [33] D'Souza G, Kreimer AR, Viscidi R, et al. Case-control study of human papillomavirus and oropharyngeal cancer. *N Engl J Med* 2007;356:1944–56.
- [34] Srodon M, Stoler MH, Baber GB, Kurman RJ. The distribution of low and high-risk HPV types in vulvar and vaginal intraepithelial neoplasia (VIN and VaIN). *Am J Surg Pathol* 2006;30:1513–8.
- [35] Syrjanen KJ. HPV infections and oesophageal cancer. *J Clin Pathol* 2002;55:721–8.