

UCLA

UCLA Previously Published Works

Title

Immediate loading with a novel implant featured by variable-threaded geometry, internal conical connection and platform shifting: three-year results from a prospective cohort study.

Permalink

<https://escholarship.org/uc/item/5d90z5jg>

Journal

International journal of oral implantology (Berlin, Germany), 8(1)

ISSN

2631-6420

Authors

Pozzi, Alessandro
Tallarico, Marco
Moy, Peter K

Publication Date

2015

Peer reviewed

Alessandro Pozzi, Marco Tallarico, Peter K. Moy

Immediate loading with a novel implant featured by variable-threaded geometry, internal conical connection and platform shifting: Three-year results from a prospective cohort study

Key words conical connection, dental implant, immediate loading, platform switching, post-extractive

Purpose: To evaluate the clinical and radiological performance of an immediately loaded novel implant design over a 3-year period.

Materials and methods: This prospective study includes 54 consecutive partially edentulous patients treated between December 2010 and October 2011. Outcome measures were: implant and prosthetic failures; biological and mechanical complications; marginal bone loss (MBL); sulcus bleeding index (SBI); and plaque score (PS).

Results: A total of 118 (29 narrow platform, 70 regular platform and 19 wide platform) NobelReplace Conical Connection implants were placed in both post-extraction sockets and healed sites and immediately loaded. The mean insertion torque was 63.4 ± 7.1 Ncm. One hundred out of 118 implants (84.7%) were inserted with a torque ranging between 55 and 70 Ncm. Each patient received a single prosthesis. At the 3-year follow-up, no patient dropped out and only two post-extractive implants failed (1.7%) in two patients (3.7%). The only complication (1.9%) observed was an event of peri-implantitis, consisting of a mean mesiodistal peri-implant bone loss of 3.2 mm reported in a healed site of a smoker patient at the 2-year follow-up examination. No prosthesis failures were detected. The cumulative mean MBL between implant placements at the 3-year follow-up was 0.68 mm (95% CI: 0.44, 0.92). At the 3-year follow-up session, the SBI and PS were 5.7% and 15.4%, respectively.

Conclusions: The NobelReplace Conical Connection implant can be considered as a valuable treatment option for immediate implant placement and loading in the partially edentulous patients over a 3-year period. Insertion torques ranging between 55 and 70 Ncm are not detrimental to osseointegration.

Conflict of interest statement: All the authors have no conflict of interest to declare. This study was completely self-financed and no funding was sought or obtained, not even in the form of free materials.



Alessandro Pozzi, DDS, PhD

Interim Chair Oral Surgery/
Implant Dentistry,
Marche Polytechnic
University,
Private Practice, Rome, Italy

Marco Tallarico, DDS

Guest Lecturer,
Marche Polytechnic
University,
Private Practice, Rome, Italy

Peter K. Moy, DMD

West Coast Oral and
Maxillofacial Surgery Center,
Nobel Biocare Endowed
Chair, Surgical Implant
Dentistry, University of Cali-
fornia, Los Angeles, USA

Correspondence to:

Alessandro Pozzi
Viale Liegi 44, 00198 Rome,
Italy
Tel: +39 366 7798110
Fax: +39 062 3329622
Email: profpozzi@me.com

Introduction

The immediate loading of dental implants can be considered a successful procedure. The risk of implant failure can be substantially minimised by ensuring proper patient selection and by using well-trained

operators¹. The major clinical implication of immediate provisionalisation/loading protocols, relates to the treatment time, which can be drastically reduced for the patients' benefit without jeopardising the implant success²⁻⁵. However, high primary implant stability and lack of micromovements are considered

two of the main factors necessary for achieving a predictable high success rate⁶. Nevertheless, there is no conclusive evidence as to the ideal insertion torque required to prevent implant failure. A minimum insertion torque of 32 Ncm has been suggested for loading implants early or immediately¹, but no consensus has been reached regarding the optimal and/or maximum recommended insertion torque values.

The hypothesis that high insertion torques can compress the peri-implant bone, disturbing the microcirculation, and leading to osteocyte necrosis and bone resorption⁷ has been recently rejected. No statistical differences in terms of marginal bone resorption and implant success rate have been found for insertion torques ranging between 30 and 50 Ncm and higher than 70 Ncm^{8,9}. Moreover, in order to minimise early implant failures, it is preferable to insert single implants with insertion torques above 35 Ncm, when loading them immediately¹⁰.

Recently, new implant designs and surfaces have been introduced to decrease the risk of early failure of immediately loaded implants^{11,12}. Various adaptations to clinical procedures have been proposed: the under-preparation of the implant site to achieve high primary stability even in poor bone¹³; the use of a non-occluding temporary prosthesis during the first 2 months of healing¹⁴; and the progressive loading of the prostheses¹⁵.

The root-form implant design with a variable-threaded geometry, and a moderately rough surface has been introduced to facilitate the one-stage surgical procedures and in order to allow for immediate placement and anticipated loading protocols¹⁶⁻¹⁹. The osteotome effect of the tapered implant body design improves the likelihood of adequate primary stability needed to ensure immediate implant placement and loading²⁰. Moreover, in an attempt to overcome the potential mechanical drawbacks of the pristine internal connections, a new prosthetic interface with a 12°C conical connection design and a hexagonal interlocking in the bottom has been developed²¹. The conical connection interface is mechanically more stable and tighter than the external hexagon and the internal trilobe prosthetic interfaces, meaning it can withstand higher torque values during the implant insertion²²⁻²⁴. Furthermore, a tight connection ensures the implant-abutment

interface is sealed properly, therefore minimising microleakage and micromovements^{25,26}.

The purpose of this prospective cohort study was to investigate, over a 3-year period, the clinical and radiological effectiveness of an immediately loaded novel implant, which consists of a variable-threaded tapered design, moderately rough surface, internal conical connection and in-built platform shifting (NobelReplace Conical Connection, Nobel Biocare, Göteborg, Sweden). This study is reported in accordance with the Strengthening the Reporting of Observational Studies in Epidemiology (STROBE) statement²⁷ for improving the quality of observational studies (<http://www.strobe-statement.org>).

■ Materials and methods

This prospective clinical study was conducted at the Department of Oral Rehabilitation, University of Rome Tor Vergata, between December 2010 and October 2011. Partially edentulous patients of both sexes, requiring one or more dental implants and immediate temporisation, who were aged 18 years or older and were able to sign an informed consent form were enrolled and treated consecutively. This was provided that they fulfilled the inclusion criteria and gave their written consent to take part in this study. All procedures were conducted in accordance with the Declaration of Helsinki (1964) for biomedical research involving human subjects, as amended in 2008. One clinician performed all the surgical and prosthetic procedures, and one dental laboratory manufactured all the restorations. The following inclusion criteria were used: healthy patients; full mouth bleeding and full mouth plaque index lower than or equal to 25%; sufficient bone to allow placement of at least 10 mm-long implants; and bone width of at least 5 mm, 6 mm, 7 mm for the narrow platform (NP 3.5 mm), regular platform (RP 4.3 mm) and wide platform (WP 5.0 mm) implants, respectively; fresh extraction sockets in the presence of an intact buccal wall and at least 5 mm of bone beyond the root apex in the maxilla and 4 mm in the mandible; and a minimal insertion torque of 45 Ncm. The exclusion criteria were: positive medical findings (such as stroke, recent cardiac infarction, severe bleeding disorder, uncontrolled

diabetes, or cancer); psychiatric therapy; pregnancy or nursing; smoking more than 10 cigarettes per day; untreated periodontitis; acute and chronic infections of the adjacent tissues or natural dentition; previous radiotherapy of the oral and maxillofacial region within the last 5 years; dehiscence or lack of buccal bone plate after tooth extraction; absence of teeth in the opposing jaw; severe clenching or bruxism; severe maxillo-mandibular skeletal discrepancy; and poor oral hygiene. Patients were informed about the clinical procedures, the materials to be used, the benefits, potential risks and complications, as well as any follow-up evaluations required for the clinical study. The medical history of the enrolled patients was collected and study models were made. Preoperative radiographs including periapical and panoramic radiographs, computed tomography (CT) scan, or cone beam computed tomography (CBCT) were obtained for initial screening and evaluation. Patients were treated by one surgeon, who had considerable clinical expertise in immediate loading procedures.

■ Surgical protocol

During the day of surgery, a single dose of antibiotic (2 g of amoxicillin and clavulanic acid or clindamycin 600 mg if patients were allergic to penicillin) was administered prophylactically 1 h prior to surgery. This treatment continued for 7 days (1 g amoxicillin and clavulanic acid or 300 mg clindamycin twice a day) after surgery. Prior to the start of surgery, patients rinsed with 0.2% chlorhexidine for 1 min. Local anaesthesia was induced by using a 4% articaine solution with epinephrine 1:100 000 (Ubistesin; 3M Italia, Milan, Italy).

Implants were placed in the planned anatomic sites by using a flapless or a miniflap approach. Bone density was assessed during the drilling phase, based on the clinician's experience and judgement and the assessment was according to the Lekholm and Zarb classification²⁸. The drilling protocol recommended by the manufacturer was customised by under-preparing the width of the implant site according to the bone density. The purpose of this was to obtain a primary stability with an insertion torque of at least 45 Ncm. Each drill was used under copious irrigation and by bringing the tip of the drill back and forward in order to avoid overheating.

In the healed sites of the maxilla for the NP implants the first drill (twist drill 2.0 mm) was used to the planned depth. Furthermore, the last drill (tapered drill NP) was used to half of its working length. For the RP and WP implants the first drill (twist drill 2.0 mm) was used to the planned depth. Additionally, the intermediate tapered drills were used to all of their working lengths, while the last one (tapered drill RP or WP according to the implant diameter) was used to half of its working length. No screw tapping was performed in order to engage as much cortical bone as possible. In the mandible, the drilling protocol recommended by the manufacturer was followed carefully by preparing the implant site for the entire planned depth with all the suggested drills, with the exception of poor bone quality in which the last tapered drill according to the implant diameter was used to half of the working length. Screw tapping was performed from one third up to a half of the working length according to the bone quality. The implant platform was positioned at the alveolar crest level or slightly below in the aesthetic areas.

In the post-extractive sites, atraumatic tooth extractions were performed in order to preserve the remaining alveolar bone and surrounding tissues (Fig 1). Crowns of multi-rooted teeth were sectioned and then the roots were individually removed if needed using a periosteal elevator (Fig 2). The residual extraction sockets were debrided thoroughly of granulation tissue and residual periodontal ligament fibres with curettes. An examination of the residual alveolar socket was performed with the aid of a periodontal probe in order to evaluate minor residual bony defects, such as a slightly resorbed crestal bone or a small bony fenestration. During this assessment the depth and inclination of the alveolus as well as interproximal bone peaks, buccal and oral wall heights were all checked. In case of multi-rooted teeth, osteotomes were used in the maxilla to allow the displacement of the septum toward the vestibular wall, therefore increasing the primary stability and the bone preservation. A dedicated starting drill suggested by the manufacturer (precision drill, REF 36118, NobelBiocare) was used in order to ensure the most favourable insertion axis from a biomechanical and occlusal standpoint. In order to gain the maximal degree of stability the drilling depth was at least 5 mm beyond the root apex in the maxilla and 4 mm in the mandible, and

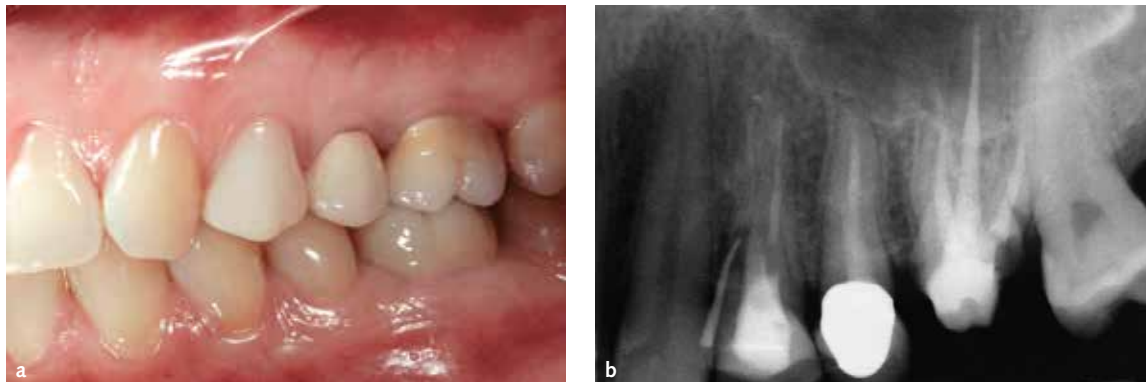


Fig 1 a) Left maxillary first premolar that was to be extracted due to a vertical root fracture. b) preoperative periapical radiograph with gutta-percha cone through the fistula and root fracture.

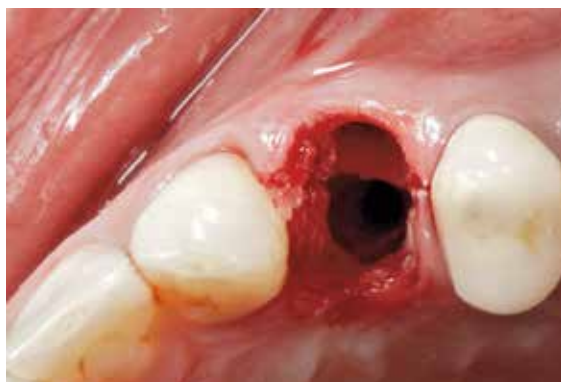

Fig 2 The premolar was atraumatically extracted sectioning the tooth into two separate roots, fully preserving the interdental septum.

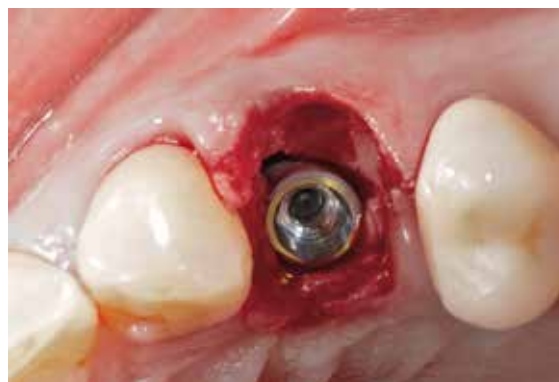

Fig 3 The implant was immediately placed in the palatal socket and 1.5 mm apical to the intact buccal bone level.

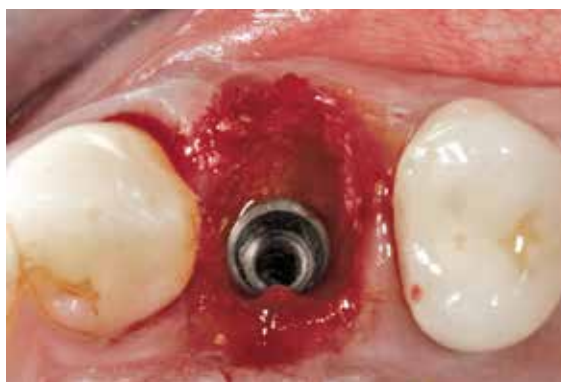

Fig 4 The gap between implants and the surrounding bone was filled with 0.25 to 1 mm granules of anorganic bovine bone hydrated using the patient's blood mixed with antibiotic solution.

the implant platform was positioned 1.5 mm below the buccal wall margin (Fig 3). The insertion torque values of the implants were measured and recorded during surgery using a surgical unit (OsseoCare Pro

Drill Motor Set, Nobel Biocare). Finally, a socket preservation procedure was performed in order to compensate for the horizontal and vertical ridge alterations that can be expected after tooth extraction²⁹. The gap between the implants and the surrounding bone was filled with 0.25 to 1 mm granules of slowly resorbing bone substitute material (Bio-Oss or Bio-Oss Collagen, Geistlich Pharma, Wolhusen, Switzerland), which was hydrated using the patient's blood mixed with antibiotic solution (Rifocin 250 mg/10 ml, Sanofi-aventis, Milan, Italy) (Fig 4).

Following implant placement, all patients received oral and written recommendations about medication, oral hygiene maintenance and diet. Post-surgical analgesic treatment was performed with ibuprofen 600 mg, which was administered twice a day for 2 days after the surgery, and later on if required. The patients were instructed to rinse the

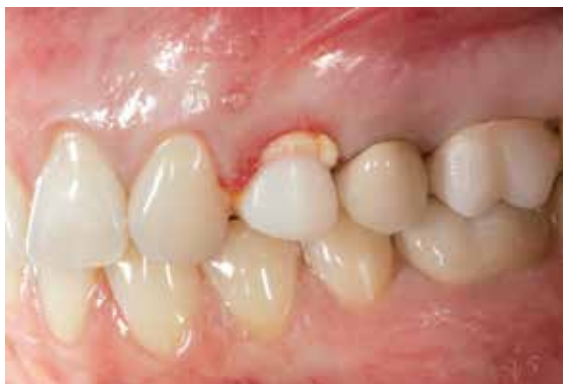

Fig 5 A pre-fabricated zirconia abutment was tightened to the implant and an acrylic temporary restoration was relined in situ. A collagen sponge was applied to fill the void between the gingival tissue and the abutment surface.

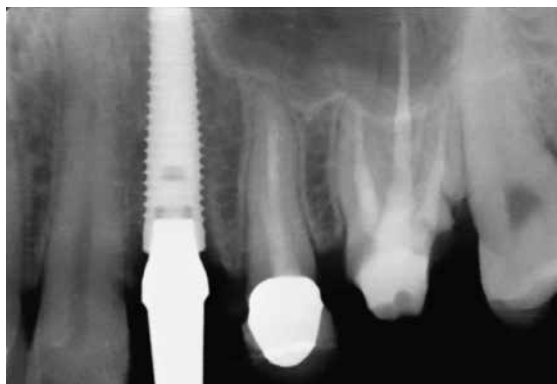

Fig 6 Periapical radiograph immediately after implant placement.

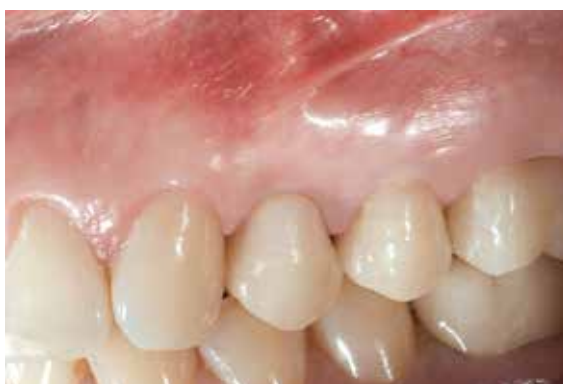

Fig 7 Clinical view of the final CAD/CAM zirconia-ceramic restoration 3 years after implant placement.

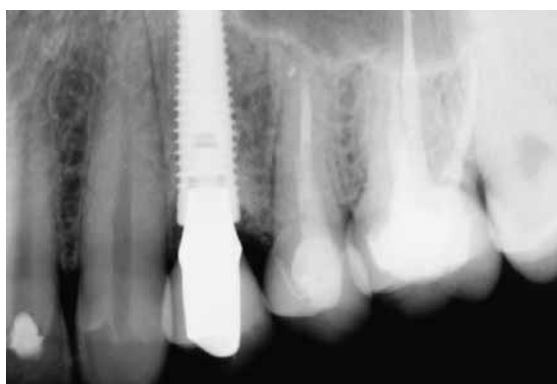

Fig 8 Periapical radiograph 3 years after implant placement.

mouth with 0.2% chlorhexidine mouthwash thrice a day without brushing the implant area until suture removal (10 to 14 days after).

■ Prosthetic protocol

Titanium temporary abutments or titanium or zirconia prefabricated definitive abutments were fixed to the implants with prosthetic screws tightened to 35 Ncm on the day of the surgery. The cement- or screw-retained provisional restorations were relined with an autopolymerising polyurethane resin (Structur 3, Voco, Cuxhaven, Germany), and then trimmed and polished chair-side (Fig 5 and Fig 6). In order to avoid any static and dynamic contacts, all of the implants received a 'non-occluding' temporary restoration. To reduce the flexibility of the acrylic resin, the multiple implant-supported temporary restorations were metal-reinforced. Patients were instructed to eat a soft diet and to wear a

night-guard during the first 5 weeks for the mandibular implants and 8 weeks for the maxillary implants.

After an individual healing period ranging from between 2 and 4 months in the mandible and 3 and 5 months in the maxilla, an open tray impression was taken with a polyether material (Impregum, 3M ESPE, Seefeld, Germany). All the final restorations were fabricated by computer-aided design (CAD)/computer-aided manufacturing (CAM) technology (NobelProcera System, Nobel Biocare) and delivered at implant or abutment level. The abutments and the screw-retained definitive restorations were screwed using the Torque Controller (Torq Control, Anthogyr, Sallanches, France) at the torque setting suggested by the manufacturer, which was 35 Ncm. Occlusion was adjusted and patients followed-up at 1, 2 and 4 months after implant insertion, and annually up to 3 years after surgery for maintenance and data collection (Fig 7 and Fig 8). Standardised periapical

radiographs were taken at the time of implant placement and then annually with a positioning jig and a customised Rinn holder (Rinn, Illinois, USA). Periodontal parameters (sulcus bleeding index (SBI) and plaque score (PS)) were recorded at each planned visit. All patients were included in a long-term maintenance protocol, which involved receiving professional cleaning treatment from a dental hygienist every 4 months. Scaling and oral hygiene instructions and motivations were delivered as needed.

■ Outcomes

The primary outcome measures were the success rates of the implants and prostheses. An independent blinded assessor recorded all of the measurements and gathered the related data. The criteria were:

- An implant was considered a failure if it presented any mobility, assessed by tapping or rocking the implant head with the metallic handles of two instruments, and/or any signs of radiolucency, progressive marginal bone loss or infection, and any mechanical complications (e.g. implant fracture) rendering the implant unusable, though still mechanically stable in the bone. This was evaluated on an intraoral radiograph taken with a paralleling technique strictly perpendicular to the implant-bone interface. The implant stability was assessed at initial loading and following 3 years of application, with the prostheses removed.
- A prosthesis was considered a failure if it needed to be replaced by an alternative prosthesis.

Secondary outcomes were: any surgical and prosthetic complications which occurred during the entire follow-up, marginal bone level changes and periodontal parameters (SBI and PS).

- Complications: any biological (pain, swelling, suppuration, etc) and/or mechanical complications (fracture of the framework and/or the veneering material, screw loosening, etc) were considered.
- Marginal bone levels were assessed using intraoral digital periapical radiographs at the subsequent follow-ups: implant placement (baseline) and yearly up to the 3-year follow-up session. Intraoral radiographs were taken with the

parallel technique by means of a periapical radiograph with a customised holder. The radiographs were accepted or rejected for evaluation based on the clarity of the implant threads. All readable radiographs were displayed in an image analysis program (DFW2.8 for windows, Soredex, Tuusula, Finland) on a 24-inch LCD screen (iMac, Apple, California, USA) and evaluated under standardised conditions (SO 12646:2004). The software was calibrated for every single image using the known distance of the implant diameter or length. The distance from the most coronal margin of the implant collar and the top of the bone crest was taken as marginal bone level. The average radiographic values of mesial and distal measurements were taken for each implant at the time of the implant placement, and then yearly up to the 3-year follow-up session. The difference between marginal bone levels at different timepoints was taken as marginal bone loss (MBL). An independent radiologist performed all the bone measurements.

- Soft tissue parameters around the implant/abutment interfaces were assessed at the 3-year examination using a plastic periodontal probe (Plast-o-Probe, Dentsply Maillefer, Ballaigues, Switzerland). The SBI was evaluated at four sites around each implant (mesial, distal, buccal and lingual) according to the Mombelli Index³⁰. The bleeding elicited within 20 s after the careful insertion of a periodontal probe 1 mm into the mucosal sulcus, parallel to where the abutment wall was assessed (0 = no bleeding; 1 = spot bleeding, 2 = linear bleeding, and 3 = spontaneous bleeding). The PS, defined as the presence of plaque (yes/no) on the abutment/restoration complex, was measured by running the periodontal probe parallel to the abutment surfaces, and scored at one site for implants. The data was collected for the overall sample size. An independent blinded dental hygienist who was not involved in the study performed all the periodontal measurements.

■ Statistics

To the best of our knowledge, at the time of writing this article, there were no other published studies

evaluating the use of the NobelReplace Conical Connection implants. This makes it difficult to calculate a convenient sample size related to the peri-implant bone resorption. The sample size was estimated by referring to a different 2-year clinical study, which investigated the same implants. Based on these data, a 2-year MBL of 0.71 with a SD of 1.53 mm was projected. By setting type I error at 0.05 and type II error at 0.20 and using the calculation from the difference in means, a total of 39 patients were required (G* Power 3.1.3 for Mac OS X, version 10.7.2).

Patient data was compiled from the records of the eligible patients using an Excel spreadsheet (Microsoft) that reflected the parameters in the patient records. The data was then exported into SPSS software for Mac OS X (version 22.0; SPSS, Chicago, Illinois, USA), for the statistical analysis. Descriptive analysis was performed for numeric parameters using means and standard deviations. Comparison between each follow-up was made by paired *t* tests to detect any change in marginal bone levels during the follow-up. All statistical comparisons were two-tailed and conducted at the 0.05 level of significance. The patient was used as the statistical unit of analysis.

Results

The main patient and implant characteristics are shown in Table 1. A total of 118 moderately rough oxidised tapered-body implants (29 narrow platform, 70 regular platform and 19 wide platform) with internal conical connection and in-built platform shifting were placed in 54 consecutive patients recruited and treated between December 2010 and October 2011. Fifty-eight patients were initially selected for this study but only 54 were included. Four patients were excluded due to the presence of dehiscence or fenestrations of the buccal alveolar wall, or they required a guided bone regeneration procedure at the same time of implant placement and were treated with a conventional loading protocol 6 months after submerged healing. Patients were of both genders (22 males and 32 females) and had an average age of 56.2 years (range 23 to 80). Forty-eight implants in 25 patients were immediately placed in post-extraction sockets, while

Table 1 Main patient and implant characteristics.

	Total (n = 54)
Number of female patients	32 (59.3%)
Age at insertion (range)	56.2 (23 – 80)
Total number of smokers	3 (5.6%)
Number of patients treated in the maxilla	33 (61.1%)
Number of implants placed in the maxilla	68 (57.6%)
Total number of implants placed	118 (100%)
Patients who received 1 implants	21 (38.9%)
Patients who received 2 implants	11 (20.4%)
Patients who received 3 implants	13 (24.1%)
Patients who received 4 implants	9 (16.6%)
10 mm-long implants	3 (2.5%)
11.5 mm-long implants	18 (15.3%)
13 mm-long implants	51 (43.2%)
16 mm-long implants	46 (39.0%)
Narrow platform (3.5 mm) implant Diameter	29 (24.6%)
Regular platform (4.3 mm) implant Diameter	70 (59.3%)
Wide platform (5 mm) implant diameter	19 (16.1%)
Implants in incisor position	27 (22.9%)
Implants in canine position	4 (3.4%)
Implants in premolar position	56 (47.4%)
Implants in molar position	31 (26.3%)

70 implants in 29 patients were placed in healed sites. All patients were followed-up with a minimum period of 3 years (mean 38.5 ± 2.1 months, range 36 to 43). Although, the overall insertion torque ranged between 45 to 70 Ncm (mean 63.4 ± 7.1 Ncm), 100 out of 118 implants (84.7%) were placed with an insertion torque ranging between 55 and 70 Ncm (Table 2). The definitive restorations were delivered 2 to 4 months after the placement of implants. An open-tray impression was made using polyether material (Impregum Penta, 3M Italia, Milan, Italy). Forty-five single crowns were delivered in 33 patients while the remaining 21 patients each received a fixed partial denture (FPD) supported by 2 to 4 implants. Definitive prostheses were cemented on 77 implants (49 restorations [38 single crowns and 11 FPDs]) while, in the remaining 41 implants (17 restorations [7 single crowns and 10 FPDs]) the final restorations were screwed.

Table 2 Distribution of implants [N (%)] according to the insertion torque and implant length/diameter (mm).

Insertion Torque	Narrow platform [29 (24.6)]				Regular platform [70 (59.3)]				Wide platform [19 (16.1)]				Total
	10	11.5	13	16	10	11.5	13	16	10	11.5	13	16	
45 – 55			2 (6.9)	2 (6.9)		3 (4.3)	4 (5.7)	4 (5.7)		1 (5.3)	2 (10.5)		18 (15.2)
55 – 65			9 (31.0)	8 (27.6)	1 (1.4)	4 (5.7)	13 (18.6)	18 (25.7)		3 (15.8)	6 (31.6)		62 (52.6)
65 – 70			4 (13.8)	4 (13.8)	1 (1.4)	4 (5.7)	8 (11.4)	10 (14.3)	1 (5.3)	3 (15.8)	3 (15.8)		38 (32.2)
Total			15 (51.7)	14 (48.3)	2 (2.9)	11 (15.7)	25 (35.7)	32 (45.7)	1 (5.3)	7 (36.8)	11 (57.9)		118

Table 3 Frequency (%) table reporting the 3-year mean marginal bone changes.

Marginal bone levels (mm)	Total (n = 116)
> 3.0	1 (0.9%)
1.0 – 2.0	25 (21.5%)
0.1–1.0	57 (49.1%)
0	21 (18.1%)
-1.0 – -0.1	7 (6%)
-2.0 – -1.1	3 (2.6%)
-3.0 – -2.1	1 (0.9%)
< -4.0	1 (0.9%)
Total	116 (100%)

No deviations occurred and all patients were treated according to the original protocol. The data of all patients were evaluated in the statistical analyses and no patients dropped out from the study.

At the 3-year follow-up, two post-extractive implants out of 118 failed (1.7%) in two patients (3.7%). One implant failed before definitive prosthesis delivery, however it was replaced successfully. The second failed implant was removed 30 months after placement. Therefore, only one definitive prosthesis failed resulting in a prosthetic Cumulative Success Rate (CSR) of 98.15%. Both the implant and the prosthesis were successfully replaced 3 months after bone healing. One implant (RP diameter and 13 mm length), which was placed in the healed site of a smoker patient and supporting a single screw-retained restoration, showed a peri-implantitis consisting of a mean mesio-distal peri-implant bone

loss of 3.2 mm with a spot bleeding on probing, at the 2-year follow-up examination (1.9%) (Table 3). Nevertheless, the implant neck was never exposed. The patients received nonsurgical therapy consisting of manual debridement using titanium curettes and a glycine-based air-powder abrasive device, and the local application of antimicrobial agents (minocycline HCl 1 mg, Arestin, OraPharma, Pennsylvania, USA), followed by oral hygiene instructions and motivation, together with a strict follow-up protocol³⁰. In these follow-up visits the bone stopped receding and the soft tissue remained stable, with the implant neck covered (Fig 9). No other biological or mechanical complications occurred during the entire follow-up. All the remaining 52 patients, accounting for a total of 116 implants were followed for the entire follow-up.

The radiographic data is summarised in Table 4. The cumulative mean MBL between implant placements at the 3-year follow-up was 0.68 mm; 95% CI: 0.44, 0.92. The mean MBL was statistically different during the first year of function (0.42 mm; 95% CI: 0.29, 0.55; $P < 0.001$), as well as, between the 1- and 2-year follow-ups (0.19 mm; 95% CI: 0.11, 0.27; $P = 0.033$). On the contrary, the mean MBL between the 2- and 3-year follow-ups was not statistically different (0.07 mm; 95% CI: -0.13, 0.27; $P = 0.140$).

At the 3-year follow-up session, SBI was detected around nine implants (7.8%) in 7 patients (13.5%). Ten patients showed a slight amount of plaque around 20 implant-abutment interfaces, thus PS was 17.2 % and 19.2% at implant and patient level, respectively.

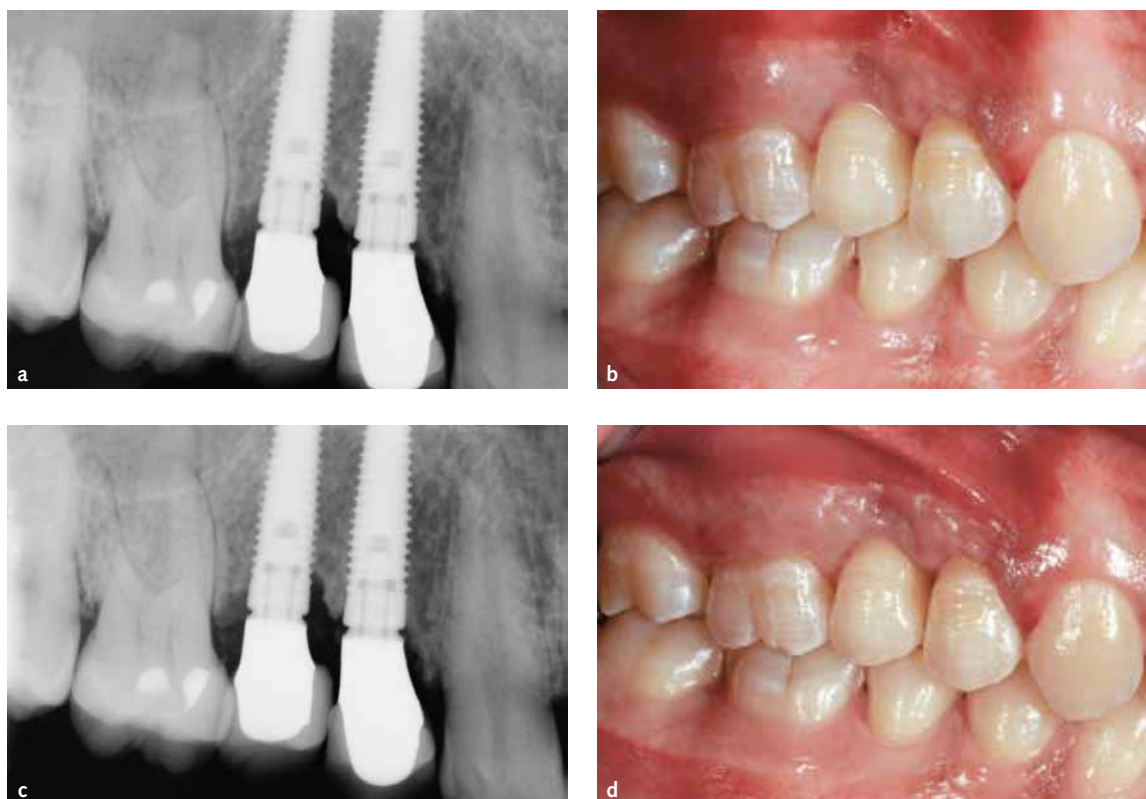

Fig 9 Sequence of treatment of the only complication (peri-implantitis): a) periapical radiograph 2 years after implant placement showing a bone loss up to the third thread; b) clinical situation 2 years after implant placement showing bluish discoloration of the soft tissue related to the inflammation; c) periapical radiograph at the 3-year follow-up, showing stable peri-implant bone; d) clinical situation 3 years after implant placement, showing a healthy peri-implant tissues with no sign of inflammation.

Table 4 Mean (standard deviation [SD]) marginal bone levels at different time points.

	Baseline (n = 118)	1-year follow-up (n = 117)	2-year follow-up (n = 117)	3-year follow-up (n = 116)
Single time points	-0.47 (0.78) mm	-0.04 (0.39) mm	0.15 (0.32) mm	0.12 (0.35) mm
Difference between previous time point (MBL)		0.42 (0.48) mm	0.19 (0.29) mm	0.07 (0.31) mm
P Value		0.000*	0.033*	0.140§
Difference from baseline (MBL)				0.68 (0.59) mm
P Value				0.000*

*Statistically significant.

§ Not statistically significant.

Discussion

The aim of this prospective cohort study was to investigate, over a 3-year period, the clinical and radiological performance of the NobelReplace Conical Connection implant, placed in both fresh extractive sockets and healed sites, to rehabilitate partially edentulous patients with immediate temporisation. In the present study, 2 out of 118 implants failed

(1.7%) over a period of 3 years. Both of these implants were placed in fresh extractive sockets in 2 out of 54 patients, scoring an overall implant CSR of 96.3%. The major clinical conclusion of this prospective study was that immediate temporisation and loading performed with the NobelReplace Conical Connection implant, may be considered an effective and reliable treatment option when patients desire to shorten the overall treatment time and be

rehabilitated immediately. However, based on the results of the latest Cochrane review of different types of dental implants, there was no evidence showing that any particular type of dental implant has superior long-term success over another type³². Moreover, proper patient selection and well-trained operators are needed to minimise the risk of implant failure. The immediate implant placement and temporisation in both fresh extractive and healed sites, have to be considered technically demanding procedures and the surgical and prosthetic skills needed are superior to those necessary for conventional implant treatment.

There are many interacting factors, which are likely to affect the success of immediately loaded implants, including but not limited to bone quality and quantity, clinician skill and experience, implant design, implant primary stability, micro- and macro-movement, and occlusion^{1,3}. Primary implant stability and lack of micromovements are considered to be two of the main factors necessary for achieving predictable high success of osseointegrated oral implants³³. A successful osseointegrated oral implant is anchored directly to bone, however, in the presence of movement a soft tissue interface may encapsulate the implant causing its failure³⁴. According to the latest Cochrane review, although the quality of the evidence is assessed as very low, a high value of insertion torque (at least 35 Ncm) seems to be one of the prerequisites for a successful immediate/early loading procedure¹. Furthermore, the quality and quantity of bone at the implant site have been shown to be important factors in determining the success of dental implants and are critical for ensuring the initial stability of the implant upon insertion^{2,35}.

Primary stability can be improved by using a tapered implant in a slightly underprepared implant site^{9,10}. In this study, the NobelReplace Conical Connection implant ensured an insertion torque ranging between 45 and 70 Ncm (mean 63.4 ± 7.1 Ncm) was obtained in all the recipient sites (Table 2) of both fresh extraction and healed scenarios, with no implant biomechanical drawbacks assessed. According to Khayat et al, primary implant stability was improved by using a tapered implant in a slightly underprepared implant site⁹. Ottoni et al³⁶, in one study investigating immediate non-occluding loading or conventional loading and survival of

single-tooth implants, reported a strong correlation between implant failures and the initial insertion torque, suggesting an insertion torque of at least 32 Ncm, to reduce the risk of failures of immediately loaded single-implant restorations.

More recently, Grandi et al⁸, in a multicentre controlled cohort study did not experience any relationship between the insertion torque values and crestal bone resorption. The clinical outcomes and the peri-implant marginal bone levels of implants placed with high insertion torque (range 50 to 80 Ncm, mean 74.8 ± 7.9) and implants placed with low insertion torque (range 30 to 45 Ncm, mean 37.4 ± 8.2) were similar. The use of high insertion torque (up to 80 Ncm) did not prevent osseointegration and did not increase bone resorption around tapered implants, which were loaded early up to 1 year after implant placement¹⁰. Nevertheless, there is no conclusive evidence as to the ideal insertion torque required to prevent implant failure. The root-form implant design with a variable-threaded geometry, and a moderately rough surface, has been introduced to facilitate the 1-stage surgical procedures and allow for immediate placement and anticipated loading protocols¹⁶⁻¹⁸. Furthermore long implants were used, whenever possible, to increase the predictability of the immediate implant placement and anticipated loading protocols, in accordance with the evidence reported in the literature that longer implants exhibited higher primary stability compared to shorter ones with the same diameter³⁷, allowing good primary mechanical stability also in poor bone quality due to the engagement of their tip with dense cortical bone structures³⁸. Nevertheless when a conventional loading is the treatment choice, short implants may offer greater simplicity and safety compared with bone augmentation procedures needed to place longer implants³⁹.

Excessive tightening may create important compression forces in the surrounding bone. It has been theorised to disturb microcirculation and lead to crestal bone resorption^{10,40}. Although these concepts are widely accepted in the literature, a few studies have been published proving these hypotheses. In a randomised controlled trial, Cannizzaro et al reported a peri-implant apical radiolucency not associated with any clinical symptoms in 3 out of 50 implants inserted with a torque > 80 Ncm (6%). This may represent a bone necrosis around the apical

portion of the implants, possibly due to excessive bone compression at implant placement. Such radiolucency disappeared at 6-month radiographic examination, confirming that spontaneous bone healing may have occurred over time¹¹. Moreover it has been reported that the use of high insertion torques (up to 176 Ncm) neither prevent osseointegration nor increased marginal bone resorption around tapered multi-threaded dental implants⁹.

Throughout the course of this study, 100 out of 118 implants (84.7%) were placed with an insertion torque ranging between 55 and 70 Ncm (Table 2). Despite using the medium-high insertion torque, neither negative effects on MBL nor clinical signs of bone compression were observed. The marginal bone levels were similar to those currently reported (0.6 to 1 mm) for implants placed via a traditional, two-stage surgical protocol^{11,21,37,41}, which was in agreement with a previous randomised controlled trial, reporting no statistically significant differences for bone levels between immediately loaded single implants inserted with medium (from 25 to 35 Ncm) or high insertion torque (> 80 Ncm)¹⁰.

To the best of our knowledge, at the time of writing this article, there were no other published studies evaluating the use of the NobelReplace Conical Connection implant. This makes it difficult to evaluate how the present results fit with other comparable studies. However, there are a few randomised controlled trials investigating a different implant featured by the same internal conical connection, in-built platform shifting and moderately rough oxidised surface (NobelActive)^{11,21,22,31,37,42,43}, which may provide some comparable data. In the present study the NobelReplace Conical Connection experienced an overall MBL of 0.68 ± 0.59 mm at the 3-year follow-up. Pozzi et al²¹ has recently published the 3-year results of a previous study, reporting a mean MBL of 0.83 ± 0.27 mm for NobelActive implants placed in healed sites of the posterior mandible. Arnhart et al¹¹ reported a mean MBL of 0.89 ± 1.65 mm at 3 years when investigating the Nobel Active implants placed in healed sites in both jaws. The mean MBL reported in the present study between the 1- and 2-year follow-up sessions, as well as, the 2- and 3-year sessions were 0.19 ± 0.29 mm and 0.07 ± 0.31 mm, respectively. This result is comparable with the data reported in the literature for two-piece implants,

where the initial bone loss occurred at the 1-year follow-up, and was followed up by about 0.1 to 0.2 mm of crestal bone loss annually^{20,44}.

In this study no mechanical complications (e.g. implant fracture, stripping of the internal connection, implant driver stuck at implant insertion) were reported. Nevertheless the aforementioned mechanical drawbacks and the inability to place the implant at the planned working length, particularly in dense bone, represent the author's major concerns with high insertion torques, which is in agreement with previous findings^{8,10}. For the latter, extrapolation of the present results to other implant systems has to be made with caution. The clinicians that want to place the implants with high insertion torque have to use an implant system, which has been tested to withstand high rotational forces.

In the present study one implant placed in the healed site of a smoker patient showed a peri-implantitis at the 2-year follow-up examination. The implant was treated by nonsurgical therapy and the neck was never exposed. In the subsequent follow-up visits the bone stopped receding and the soft tissue remained stable. No other biological or mechanical complications occurred during the entire follow-up. According to the latest Cochrane review after 3 years, implants with turned surfaces had a 20% reduced risk of being affected by peri-implantitis; however, the 5-year and 10-year data did not show any evidence of a difference. Moreover there was limited evidence showing that implants with relatively smooth (turned) surfaces are less prone to lose bone due to chronic infection (peri-implantitis) than implants with much rougher surfaces. Furthermore there was a tendency for implants with turned surfaces to fail early more often than implants with roughened surfaces³¹.

In the present study at the 3-year follow-up session, the SBI and PS (5.7% and 15.4%, respectively) were within the ranges reported by previous prospective studies on implants with moderately rough surfaces and there were comparable follow-up times, indicating the presence of healthy soft tissue around NobelReplace Conical Connection implants in well maintained and motivated patients⁴⁵⁻⁵⁰.

The main limitations of the present study were the small sample size and the short follow-up. Nevertheless, even though the number of patients

enrolled in this study cannot ensure definitive conclusions can be made, a sample size calculation has been performed, allowing the results of the present study to be generalised to a larger population with similar characteristics. Although the implant and prosthetic CSR and the mean MBL have been assessed up to a period of 3 years, a relatively short timeframe can be considered to be sufficient to understand the role of the immediate loading on the establishment and maintenance of the osseointegration in both groups.

■ Conclusions

Within the limitations of the present study, the findings suggest that in partially edentulous patients, the NobelReplace Conical Connection implant can be considered as a valuable treatment option for immediate implant placement and loading in both post-extractive and healed sites, at least for a period of 3 years. Insertion torques ranging between 55 and 70 Ncm are not detrimental to osseointegration.

■ References

- Esposito M, Grusovin MG, Maghazeh H, Worthington HV. Interventions for replacing missing teeth: different times for loading dental implants. *Cochrane Database Syst Rev* 2013;3:CD003878.
- Xu L, Wang X, Zhang Q, Yang W, Zhu W, Zhao K. Immediate versus early loading of flapless placed dental implants: a systematic review. *J Prosthet Dent* 2014;112:760–769.
- Atieh MA, Payne AG, Duncan WJ, Cullinan MP. Immediate restoration/loading of immediately placed single implants: is it an effective bimodal approach? *Clin Oral Implants Res* 2009;20:645–659.
- Vogl S, Stopper M, Hof M, Wegscheider WA, Lorenzoni M. Immediate occlusal versus non-occlusal loading of implants: a randomized clinical pilot study. *Clin Implant Dent Relat Res* [pub ahead of print 30 Sep 2013].
- Del Fabbro M, Testori T, Francetti L, Taschieri S, Weinstein R. Systematic review of survival rates for immediately loaded dental implants. *Int J Periodontics Restorative Dent* 2006;26:249–263.
- Tsukioka T, Sasaki Y, Kaneda T, Buch K, Sakai O. Assessment of relationships between implant insertion torque and cortical shape of the mandible using panoramic radiography: preliminary study. *Int J Oral Maxillofac Implants* 2014;29:622–626.
- O'Sullivan D, Sennerby L, Meredith N. Measurements comparing the initial stability of five designs of dental implants: a human cadaver study. *Clin Implant Dent Relat Res* 2000;2:85–92.
- Grandi T, Guazzi P, Samarani R, Grandi G. Clinical outcome and bone healing of implants placed with high insertion torque: 12-month results from a multicenter controlled cohort study. *Int J Oral Maxillofac Surg* 2013;42:516–520.
- Khayat PG, Arnal HM, Tourbah BI, Sennerby L. Clinical outcome of dental implants placed with high insertion torques (Up to 176 Ncm). *Clin Implant Dent Relat Res* 2013;15:227–233.
- Cannizzaro G, Leone M, Ferri V, Viola P, Gelpi F, Esposito M. Immediate loading of single implants inserted flapless with medium or high insertion torque: a 6-month follow-up of a split-mouth randomised controlled trial. *Eur J Oral Implantol* 2012;5:333–342.
- Arnhart C, Kielbassa AM, Martinez-de Fuentes R, Goldstein M, Jackowski J, Lorenzoni M, Maiorana C, Mericske-Stern R, Pozzi A, Rompen E, Sanz M, Strub JR. Comparison of variable-thread tapered implant designs to a standard tapered implant design after immediate loading. A 3-year multicentre randomised controlled trial. *Eur J Oral Implantol* 2012;5:123–136.
- Kim YK, Lee JH, Lee JY, Yi YJ. A randomized controlled clinical trial of two types of tapered implants on immediate loading in the posterior maxilla and mandible. *Int J Oral Maxillofac Implants* 2013;28:1602–1611.
- Cannizzaro G, Leone M. Restoration of partially edentulous patients using dental implants with a microtextured surface: a prospective comparison of delayed and immediate full occlusal loading. *Int J Oral Maxillofac Implants* 2003;18:512–522.
- Testori T, Bianchi F, Del Fabbro M, Szmukler-Moncler S, Francetti L, Weinstein RL. Immediate non-occlusal loading vs early loading in partially edentulous patients. *Pract Proced Aesthet Dent* 2003;15:787–794.
- Appleton RS, Nummikoski PV, Pigno MA, Cronin RJ, Chung KH. A radiographic assessment of progressive loading on bone around single osseointegrated implants in the posterior maxilla. *Clin Oral Implants Res* 2005;16:161–167.
- Lang NP, Jepsen S, Working Group 4. Implant surfaces and design (Working Group 4). *Clin Oral Implants Res* 2009;20(Suppl 4):228–231.
- Glauser R, Ruhstaller P, Windisch S, Zembic A, Lundgren A, Gottlow J, Hammerle CH. Immediate occlusal loading of Branemark System TiUnite implants placed predominantly in soft bone: 4-year results of a prospective clinical study. *Clin Implant Dent Relat Res* 2005;7(Suppl 1):S52–S59.
- Mura P. Immediate loading of tapered implants placed in post-extraction sockets: retrospective analysis of the 5-year clinical outcome. *Clin Implant Dent Relat Res* 2012;14:565–574.
- Esposito M, Grusovin MG, Polyzos IP, Felice P, Worthington HV. Interventions for replacing missing teeth: dental implants in fresh extraction sockets (immediate, immediate-delayed and delayed implants). *Cochrane Database Syst Rev* 2010;9:CD005968.
- Pozzi A, Mura P. Clinical and radiologic experience with moderately rough oxidized titanium implants: up to 10 years of retrospective follow-up. *Int J Oral Maxillofac Implants* 2014;29:152–161.
- Pozzi A, Tallarico M, Moy PK. Three-year post-loading results of a randomised, controlled, split-mouth trial comparing implants with different prosthetic interfaces and design in partially posterior edentulous mandibles. *Eur J Oral Implantol* 2014;7:47–61.
- Gultekin BA, Gultekin P, Leblebicioglu B, Basegmez C, Yalcin S. Clinical evaluation of marginal bone loss and stability in two types of submerged dental implants. *Int J Oral Maxillofac Implants* 2013;28:815–823.
- Schmitt CM, Nogueira-Filho G, Tenenbaum HC, Lai JY, Brito C, Doring H, Nonhoff J. Performance of conical abutment (Morse Taper) connection implants: a systematic review. *J Biomed Mater Res A* 2014;102:552–574.

24. Larrucea Verdugo C, Jaramillo Núñez G, Acevedo Avila A, Larrucea San Martín C. Microleakage of the prosthetic abutment/implant interface with internal and external connection: in vitro study. *Clin Oral Implants Res* 2014;25:1078–1083.
25. Harder S, Dimaczek B, Açil Y, Terheyden H, Freitag-Wolf S, Kern M. Molecular leakage at implant-abutment connection—in vitro investigation of tightness of internal conical implant-abutment connections against endotoxin penetration. *Clin Oral Investig* 2009;14:427–432.
26. Bateli M, Att W, Strub JR. Implant neck configurations for preservation of marginal bone level: a systematic review. *Int J Oral Maxillofac Implants* 2011;26:290–303.
27. von Elm E, Altman DG, Egger M, Pocock SJ, Gotsche PC, Vandenbroucke JP. The strengthening the reporting of observational studies in epidemiology (STROBE) statement: guidelines for reporting observational studies. *Rev Esp Salud Publica* 2008;82:251–259.
28. Lekholm U, Zarb GA. Patient selection and preparation. In: Brånemark PI, Zarb GA, Albrektsson T (eds). *Tissue-integrated prostheses osseointegration in clinical dentistry*. Chicago: Quintessence Publishing Co Inc;1985:199–209.
29. Vittorini Orgeas G, Clementini M, De Risi V, De Sanctis M. Surgical techniques for alveolar socket preservation: a systematic review. *Int J Oral Maxillofac Implants* 2013;28:1049–1061.
30. Mombelli A, Lang NP. The diagnosis and treatment of peri-implantitis. *Periodontol* 2000 1998;17:63–76.
31. Pozzi A, Agliardi EL, Tallarico M, Barlattani A. Clinical and radiological outcomes of two implants with different prosthetic interfaces and neck configurations: randomized, controlled, split-mouth clinical trial. *Clin Implant Dent Relat Res* 2012;16:96–106.
32. Esposito M, Ardebili Y, Worthington HV. Interventions for replacing missing teeth: different types of dental implants. *Cochrane Database Syst Rev*. 2014 Jul 22;7:CD003815.
33. Albrektsson T, Linder L. A method for short- and long-term in vivo study of the bone-implant interface. *Clin Orthop Relat Res* 1981;159:269–273.
34. Brunski JB, Moccia AF Jr, Pollack SR, Korostoff E, Trachtenberg DI. The influence of functional use of endosseous dental implants on the tissue-implant interface. I. Histological aspects. *J Dent Res* 1979;58:1953–1969.
35. Papaspyridakos P, Chen CJ, Chuang SK, Weber HP. Implant loading protocols for edentulous patients with fixed prostheses: a systematic review and meta-analysis. *Int J Oral Maxillofac Implants* 2014;29(Suppl):256–270.
36. Ottoni JM, Oliveira ZF, Mansini R, Cabral AM. Correlation between placement torque and survival of single-tooth implants. *Int J Oral Maxillofac Implants* 2005;20:769–776.
37. Barikani H, Rashtak S, Akbari S, Fard MK, Rokn A. The effect of shape, length and diameter of implants on primary stability based on resonance frequency analysis. *Dent Res J (Isfahan)* 2014;11:87–91.
38. Renvert S, Lessem J, Dahlén G, Renvert H, Lindahl C. Mechanical and repeated antimicrobial therapy using a local drug delivery system in the treatment of peri-implantitis: a randomized clinical trial. *J Periodontol* 2008;79:836–844.
39. Guljé F, Abrahamsson I, Chen S, Stanford C, Zadeh H, Palmer R. Implants of 6 mm vs 11 mm lengths in the posterior maxilla and mandible: a 1-year multicenter randomized controlled trial. *Clin Oral Implants Res* 2013;24:1325–1331.
40. Bashutski JD, D'Silva NJ, Wang HL. Implant compression necrosis: current understanding and case report. *J Periodontol* 2009;80:700–704.
41. Grandi T, Guazzi P, Samarani R, Grandi G. A 3-year report from a multicentre randomised controlled trial: immediately versus early loaded implants in partially edentulous patients. *Eur J Oral Implantol* 2013;6:217–224.
42. Kielbassa AM, Martinez-de Fuentes R, Goldstein M, Arnhart C, Barlattani A, Jackowski J, Knauf M, Lorenzoni M, Maiorana C, Merickske-Stern R, Rompen E, Sanz M. Randomized controlled trial comparing a variable-thread novel tapered and a standard tapered implant: Interim one-year results. *J Prosthet Dent* 2009;101:293–305.
43. Bell C, Bell RE. Immediate restoration of NobelActive implants placed into fresh extraction sites in the anterior maxilla. *J Oral Implantol* 2014;40:455–458.
44. Albrektsson T, Zarb G, Worthington P, Eriksson AR. The long-term efficacy of currently used dental implants: a review and proposed criteria of success. *Int J Oral Maxillofac Implants* 1986;1:11–25.
45. Glauser R, Zembic A, Ruhstaller P, Windisch S. Five-year results of implants with an oxidized surface placed predominantly in soft quality bone and subjected to immediate occlusal loading. *J Prosthet Dent* 2007;97(Suppl 6):S59–S68.
46. Mertens C, Steveling HG. Early and immediate loading of titanium implants with fluoride-modified surfaces: results of 5-year prospective study. *Clin Oral Implants Res* 2011;22:1354–1360.
47. Bergkvist G, Nilner K, Sahlholm S, Karlsson U, Lindh C. Immediate loading of implants in the edentulous maxilla: use of an interim fixed prosthesis followed by a permanent fixed prosthesis: a 32-month prospective radiological and clinical study. *Clin Implant Dent Relat Res* 2009;11:1–10.
48. Fischer K, Stenberg T, Hedin M, Sennerby L. Five-year results from a randomized, controlled trial on early and delayed loading of implants supporting full-arch prosthesis in the edentulous maxilla. *Clin Oral Implants Res* 2008;19:433–441.
49. Weibrich G, Buch RS, Wegener J, Wagner W. Five-year prospective follow-up report of the Astra tech standard dental implant in clinical treatment. *Int J Oral Maxillofac Implants* 2001;16:557–562.
50. Zembic A, Glauser R, Khraisat A, Hammerle CH. Immediate vs early loading of dental implants: 3-year results of a randomized controlled clinical trial. *Clin Oral Implants Res* 2010;21:481–489.