

# UC Davis

## Dermatology Online Journal

### Title

Herpes zoster presenting as unilateral vasculitis

### Permalink

<https://escholarship.org/uc/item/5dd717sw>

### Journal

Dermatology Online Journal, 24(11)

### Authors

Clark, Ashley K  
Dhossche, Julie  
Korcheva, Veselina B  
[et al.](#)

### Publication Date

2018

### DOI

10.5070/D32411042007

### Copyright Information

Copyright 2018 by the author(s). This work is made available under the terms of a Creative Commons Attribution-NonCommercial-NoDerivatives License, available at <https://creativecommons.org/licenses/by-nc-nd/4.0/>

Peer reviewed

# Herpes zoster presenting as unilateral vasculitis

Ashley K Clark<sup>1</sup> MD, Julie Dhossche<sup>2</sup> MD, Veselina B Korcheva<sup>2</sup> MD, Jesse J Keller<sup>2</sup> MD

Affiliations: <sup>1</sup>School of Medicine, University of California, Davis, Sacramento, California, USA, <sup>2</sup>Department of Dermatology, Oregon Health and Science University, Portland, Oregon, USA

Corresponding Author: Jesse Keller MD, <sup>2</sup>Department of Dermatology, Oregon Health and Science University, 3303 SW Bond Avenue, Portland, OR 97239, Tel: 503-418-3376, Email: [kellerje@ohsu.edu](mailto:kellerje@ohsu.edu)

## Abstract

Vasculitis can be a primary disorder or a cutaneous manifestation of a viral infection. The present case describes an atypical localized cutaneous varicella-zoster virus infection inducing a small vessel vasculitis in a patient with multisystem sarcoidosis. Additionally, we discuss the differential diagnoses and treatment options. Varicella-Zoster infection occurs more frequently in immunosuppressed populations and can present with uncharacteristic clinical manifestations complicating the diagnosis as in the present case.

*Keywords: secondary vasculitis, varicella zoster infection, immunosuppression, leg ulcers*

## Introduction

Vasculitis is inflammation directed at blood vessels leading to tissue ischemia and infarction. Cutaneous small vessel vasculitis, a condition characterized by palpable purpura, can be a primary disorder or a cutaneous manifestation of a connective tissue disease, bacterial or viral infection, or drug ingestion [1]. Cutaneous vasculitis can occur as a result of multiple disorders. Therefore, clinical, histopathologic, and laboratory assessments are essential in confirming the diagnosis. It is estimated that infections account for 23 percent of cutaneous vasculitis cases [2].

Herpes zoster is a viral disease caused by reactivation of the varicella zoster virus (VZV) typically presenting with erythematous papules that evolve into painful vesicles and bullae. VZV infection occurs more frequently and severely in immunosuppressed

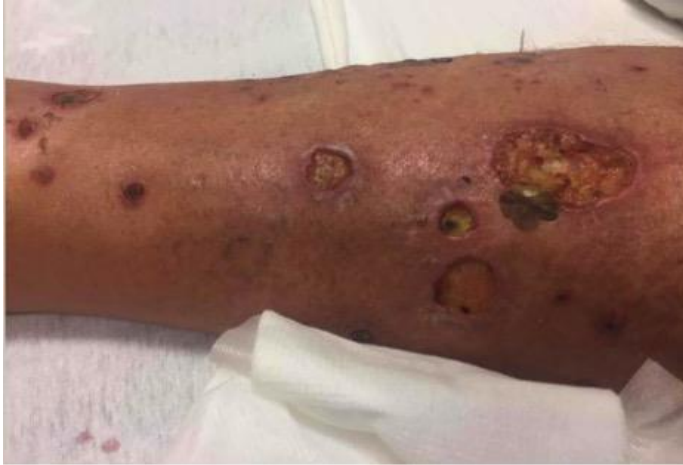populations and can present with atypical clinical manifestations complicating the diagnosis [3].

Herein, we describe an atypical localized cutaneous VZV infection inducing a small vessel vasculitis in a patient with multisystem sarcoidosis. Our report highlights a rare clinical presentation of VZV infection, the components of the differential diagnosis to consider, and treatment options.

## Case Synopsis

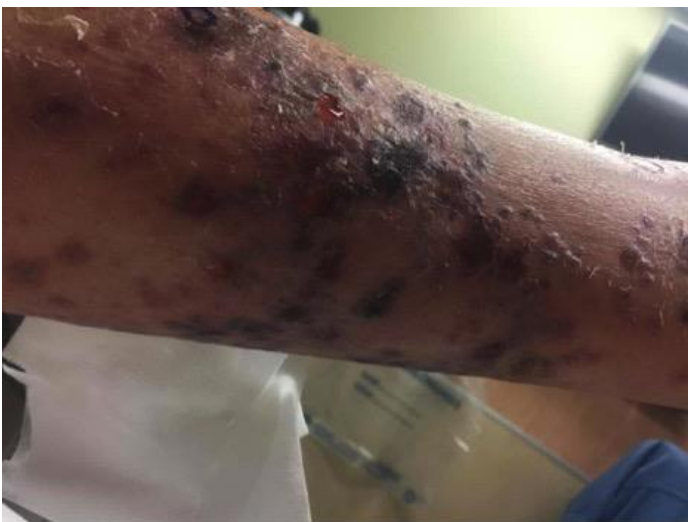A dermatology consultation was requested to evaluate a 66-year-old man with a 6-year history of multisystem sarcoidosis, hypertension, and chronic kidney disease who presented to the emergency department (ED) for evaluation of left lower extremity ulcerations and increasing left leg pain.

He reported first developing red papules on the left lower leg 10 months previously. At the time they were asymptomatic. However, 6 months later the lesions started to ulcerate, at which time he sought treatment from a dermatologist. A biopsy was performed and the results were reported as consistent with cutaneous sarcoidosis, though there were no definite granulomas (thought to be secondary to his immunosuppression with prednisone and methotrexate). He had no other cutaneous manifestations of sarcoidosis. He had been taking methotrexate 15mg weekly for the past 2 years. His prednisone was recently increased from 5mg to 40mg daily owing to worsening of the ulcerations. A wound swab was also performed which grew *Pseudomonas* and *Enterococcus*. He was subsequently started on a course of ciprofloxacin and doxycycline; he recently finished this



**Figure 1.** Leg ulcer. The left lower leg had multiple well-demarcated 1-3cm ulcers with sharp borders and shallow fibrinous base. Additionally, there were multiple scattered violaceous papules covering the left calf.

combination with no improvement in his symptoms. He had also been doing bleach washes and gentamicin ointment as wound care. Given his worsening skin symptoms as well as worsening pain, he presented to the ED on the recommendation of his dermatologist. He described the leg pain as dull, constant and aching, isolated to the area of ulceration and non-radiating. The pain worsened with palpation. He denied any significant drainage from wounds, fevers, leg swelling, or shortness of breath. On examination, the left lower leg had multiple well-demarcated 1-3cm ulcers with sharp borders and shallow fibrinous bases (**Figure 1**).



**Figure 2:** Palpable purpura. On the left leg, multiple violaceous papules coalescing into plaques.

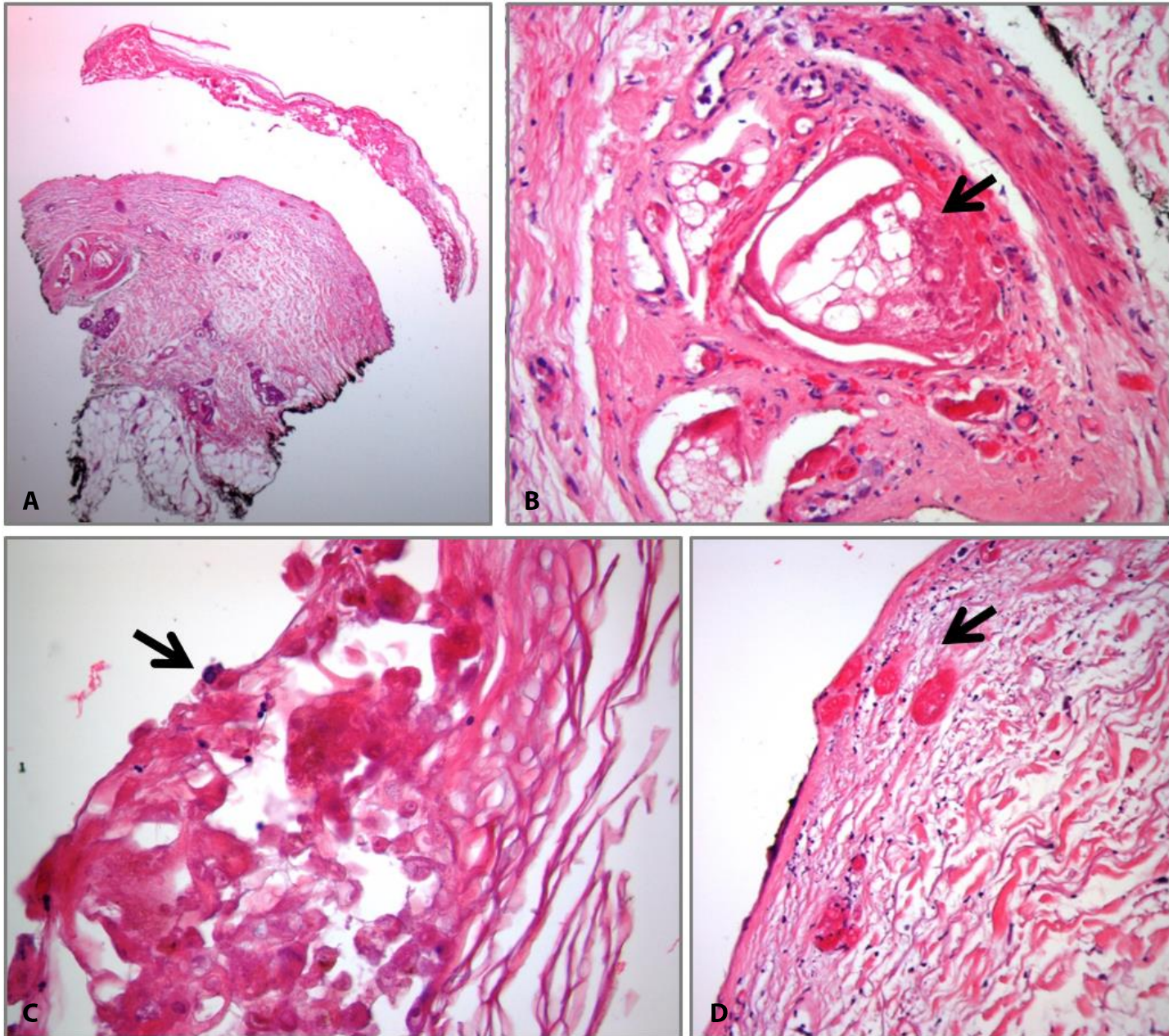
Additionally, there were multiple scattered violaceous papules covering the left calf (**Figure 2**).

In the ED, he was started on IV cefepime given previous positive culture to pseudomonas and enterococcus along with his immunosuppressed status. He reported his pain improved with oxycodone though it returned when the medication wore off.

Additional diagnostic studies revealed mildly elevated lactate (2.9, reference range 0.5-2.2 mmol/L), creatinine at patient's baseline (1.45, reference range 0.7-1.45 mg/dL), mild transaminase elevation (aspartate aminotransferase 61, reference range <41 U/L, alanine aminotransferase 78, reference range <60 U/L), no leukocytosis, anemia or thrombocytopenia. Erythrocyte sedimentation rate and C-reactive protein were within normal limits. Anti-neutrophil cytoplasmic antibody, rheumatoid factor, C3 and C4 were within normal limits. Left lower extremity X-ray was without findings of osteomyelitis. Duplex ultrasound did not reveal a deep venous thrombosis.

Blood and superficial wound cultures were obtained. Blood cultures were negative. Wound culture resulted in *Escherichia coli* and *Stenotrophomonas maltophilia* growth. Additional testing for trichomonas, hepatitis A, B and C, *Aspergillus*, *Blastomyces*, *Coccidioides*, and *Histoplasma* were all negative.

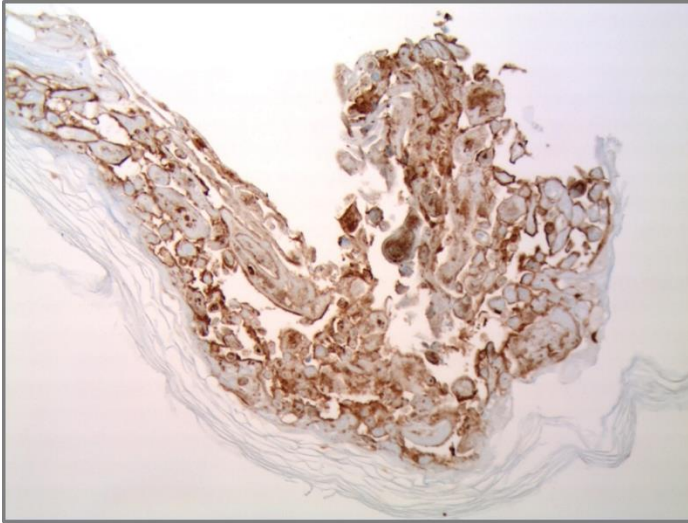
Punch biopsies of the left lower leg were performed for routine histology and direct immunofluorescence study and tissue culture for bacterial, mycobacteria, and fungal organisms. The biopsy revealed epidermal necrosis, a very sparse perivascular and interstitial inflammatory infiltrate composed of lymphocytes and neutrophils, leukocytoclasia, sebaceous glands necrosis, and focal fibrin exudation and thrombosis of small blood vessels in the superficial dermis (**Figure 3**). Special stains, Gram and periodic acid-Schiff were negative for bacterial and fungal organisms, respectively. Immunohistochemical stain for VZV was positive (**Figure 4**) whereas staining for herpes simplex virus (HSV) was negative. Direct immunofluorescence showed moderately intense granular deposition of



**Figure 3:** **A)** Low power (2.5 $\times$ ) view showing epidermal separation with epidermal necrosis, sebaceous gland necrosis, and a very sparse accompanying inflammation in the dermis. **B)** Epidermal necrosis with occasional multinucleated keratinocytes (arrow) showing nuclear chromatin margination, 20 $\times$ . **C)** Necrotic sebaceous gland (arrow, 10 $\times$ ). **D)** Thrombosis of small blood vessels in the superficial dermis, 10 $\times$ .

IgM as well as moderately intense granular and homogenous deposition of C3 within the walls of superficial and mid-dermal vessels. Additionally, there was strong deposition of fibrinogen within the walls of superficial and mid-dermal blood vessels as well as along the connective tissue fibers of the upper and mid dermis, immunopathologic findings seen in leukocytoclastic vasculitis and reactive vasculitis. Diagnosis of VZV with cutaneous small

vessel vasculitis was established based on these histopathologic findings. Intravenous acyclovir was initiated. Ultimately serum VZV by polymerase chain reaction was positive as well, but the patient did not have findings of disseminated VZV — the lesions remained localized to adjacent dermatomes on the left leg. His laboratory tests, including liver function tests, remained stable and his clinical course was one of improvement. Intravenous acyclovir was given for



**Figure 4:** Immunohistochemical staining for Varicella-Zoster virus showing infected keratinocytes in the necrotic epidermis, 20x.

7 days and then followed by oral valacyclovir for 7 days. Ulcerations and leg pain greatly improved prior to discharge.

## Case Discussion

The clinical presentation of VZV infection in this patient with multisystem sarcoidosis was unusual because of the chronic, ulcerating, and initially painless lesions without a vesicular phase eruption, as well as the clinical and histological findings of small vessel vasculitis. Herpes zoster is caused by reactivation of VZV from sensory nerve ganglia. When cell-mediated immunity wanes, the virus reactivates and then transaxonally infects the epidermis and replicates in keratinocytes, producing the typical morphological findings of painful grouped vesicles [4]. The immunocompromised are at high risk for herpes zoster; lifetime risk for reactivation is estimated at around 20% for healthy adults and 50% in immunocompromised [4-5].

VZV can have atypical manifestations in immunocompromised patients, including the absence of a vesicular phase. In addition, ecthymatous, chronic, verrucous, painless, and vasculitic manifestations can be seen [3-5]. The particular combination of ulcerative lesions and vasculitis has been rarely described in the literature previously [4]. VZV is a neurotropic virus, but can

also infect blood vessels, leading to vasculitis [6]. There are two proposed mechanisms for this: 1) contiguous infection from nerves to vessels, and 2) hematogenous dissemination owing to low level viremia which causes viral replication in endothelial cells, which then causes destruction of microvasculature [3-5]. Evidence of endothelial infection with VZV has been demonstrated in previously reported cases with electron microscopy showing herpesvirus particles within endothelial cells of obliterated vessels and by immunohistochemical staining with monoclonal antibodies against VZV demonstrating infection of endothelial cells, leading to a diagnosis of cutaneous VZV-induced vasculitis in these cases [4, 6].

There is a growing body of literature on the link between VZV and vascular disease. Herpes zoster virus reactivation is associated with CNS vasculitis in the case of granulomatous angiitis of the nervous system and CNS vasculopathies including ischemic and hemorrhagic strokes and aneurysms (especially in the case of herpes zoster ophthalmicus), [7]. CNS vascular disease is hypothesized to occur secondary to transaxonal spread of the virus to cerebral arteries [6-7], though it has also been suggested that circulating virus infecting arterial tissue may be responsible for the increased risk of stroke and myocardial infarction for months and years after acute herpes zoster, given that VZV DNA has been detected in blood for months after acute herpes zoster infection [7].

Of note, sarcoidosis is often accompanied by various skin complications that can present with a variety of morphologies including papules, nodules, plaques, infiltrated scars, and ulcerative lesions [8]. Furthermore, such patients are often in an immunosuppressive state, placing them at a high risk of developing viral, bacterial, and fungal infections related to immunosuppressant treatment, making a diagnosis of the skin lesions in this patient more complicated.

The initial presentation pointed towards ulcerative sarcoidosis given the patient's history. Cutaneous lesions are reported in approximately 20 to 35% of sarcoidosis patients, with approximately 1.1% developing ulcerative lesions, most commonly on

the lower extremities. Additionally, women are 3 times more common than men to develop ulcerative sarcoidosis [9]. A definitive diagnosis of sarcoidosis relies on the demonstration of non-caseating granulomas on microscopic examination with negative culture results for infectious etiologies. In this case, on our histology, no granulomas were present, although the patient was immunosuppressed and this could theoretically suppress granuloma formation.

## Conclusion

This patient's clinical presentation of unilateral lower leg vasculitis and subsequent findings consistent

with herpes zoster infection were unusual and surprising. He improved significantly with anti-viral treatment. We favor this to be an atypical clinical presentation of herpes zoster with small vessel vasculitis and a reminder that zoster can have atypical presentations in the immunocompromised who have decreased cell-mediated immunity. Heightened clinical awareness of the varied clinical presentations of atypical zoster can shorten the time to diagnosis and appropriate treatment. It is also important to realize that there is an expanding body of literature on the link between VZV and vascular disease, particularly in those patients with herpes zoster ophthalmicus and those that are immunocompromised.

## References

1. Blanco, R., et al., Cutaneous vasculitis in children and adults. Associated diseases and etiologic factors in 303 patients. *Medicine (Baltimore)*, 1998. 77(6): p. 403-18. [PMID: 9854604].
2. Carlson, J.A., B.T. Ng, and K.R. Chen, Cutaneous vasculitis update: diagnostic criteria, classification, epidemiology, etiology, pathogenesis, evaluation and prognosis. *Am J Dermatopathol*, 2005. 27(6): p. 504-28. [PMID: 16314707].
3. Erhard, H., et al., Atypical varicella-zoster virus infection in an immunocompromised patient: result of a virus-induced vasculitis. *J Am Acad Dermatol*, 1995. 32(5 Pt 2): p. 908-11 DOI: 10.1016/0190-9622(95)91560-5.
4. Mendoza N et al. Human Herpesviruses. In Bologna JL, Jorizzo JL, Schaffer JV, Eds. *Dermatology*. 3<sup>rd</sup> Ed. Philadelphia: Elsevier Saunders, 2012.
5. Dayan RR, Peleg R. Herpes zoster-typical and atypical presentations. *Postgrad Med*. 2017;129(6):567-571.[PMID: 28540752].
6. Burgard B, Smola S, Vogt T, Müller CSL. Small Vessel Vasculitis in Herpes Zoster-Discussion of Current Aspects of Varicella Zoster Virus Vasculopathy. *Am J Dermatopathol*. 2018;40(8):602-604. [PMID: 29570133].
7. Breuer J, Pacou M, Gauthier A, Brown MM. Herpes zoster as a risk factor for stroke and TIA: a retrospective cohort study in the UK. *Neurology*. 2014;82(3):206-12. [PMID: 24384645].
8. Marcoval, J., J. Mana, and M. Rubio, Specific cutaneous lesions in patients with systemic sarcoidosis: relationship to severity and chronicity of disease. *Clin Exp Dermatol*, 2011. 36(7): p. 739-44. [PMID: 21790725].
9. Albertini, J.G., W. Tyler, and O.F. Miller, 3rd, Ulcerative sarcoidosis. Case report and review of the literature. *Arch Dermatol*, 1997. 133(2): p. 215-9. [PMID: 9041836].