

UC Irvine

UC Irvine Previously Published Works

Title

Comparison of Two Core Biopsy Techniques Before and After Laparoscopic Cryoablation of Small Renal Cortical Neoplasms

Permalink

<https://escholarship.org/uc/item/5dq2r2rb>

Journal

JLS Journal of the Society of Laparoscopic & Robotic Surgeons, 15(4)

ISSN

1086-8089

Authors

Truesdale, Matthew D
Mues, Adam C
Sartori, Samantha
et al.

Publication Date

2011

DOI

10.4293/108680811x13176785204157

Copyright Information

This work is made available under the terms of a Creative Commons Attribution License, available at <https://creativecommons.org/licenses/by/4.0/>

Peer reviewed

Comparison of Two Core Biopsy Techniques Before and After Laparoscopic Cryoablation of Small Renal Cortical Neoplasms

Matthew D. Truesdale, MD, Adam C. Mues, MD, Samantha Sartori, PhD, Cristin N. Casazza, MS, Gregory W. Hruby, MS, Lara R. Harik, MD, Kathleen M. O'Toole, MD, Ketan K. Badani, MD, Alberto Pérez-Lanzac, MD, Jaime Landman, MD

ABSTRACT

Introduction: Cryoablation is an acceptable treatment option for small renal cortical neoplasms (RCN). Unlike extirpative interventions, intraoperative needle biopsy is the only pathologic data for ablated tumors. It is imperative that sampled tissue accurately captures pathology. We studied the optimal intraoperative needle core biopsy protocol for small RCN during laparoscopic renal cryoablation (LCA).

Methods: Patients with RCN < 4cm underwent intraoperative biopsy during LCA. Four biopsy cores were taken per tumor, 2 before and 2 after LCA by using both a standard and modified technique. Standard technique: needle biopsy device was deployed after insertion into the renal tissue at a depth of 5mm. Modified technique: needle biopsy device was deployed 1mm outside of the renal tissue. Biopsies were examined and compared with reference standard pathology. Percentage agreement was calculated across biopsy types (standard vs. modified) and time points (pre- vs. postcryoablation). Logistic regression was used to identify factors impacting biopsy accuracy.

Results: Thirty patients with 33 RCNs underwent LCA. The mean patient age was 69.1 ± 8.0 yrs, and mean tumor size was 2.3 ± 0.7 cm. No significant bleeding resulted from

biopsies. A definitive diagnosis was made in 31/33 RCNs (94.0%). Ten tumors (30.3%) were benign, 21 (63.7%) were malignant, and 2 (6.0%) were nondiagnostic. Biopsy length was significantly longer using the standard vs. modified technique with mean lengths of 9.3mm vs. 7.0mm, respectively ($P = .02$). Highest agreement was seen in preablation biopsies (90.3%). A significant association with agreement was seen for younger age ($P = .05$) and larger tumor size ($P = .02$).

Conclusions: Younger age and larger tumor size were associated with improved accuracy. Preoperative sampling resulted in superior accuracy and the standard technique resulted in significantly longer cores. Use of preablation standard biopsy technique may result in the most accurate pathologic diagnosis for patients undergoing cryoablation for small RCNs.

Key Words: Renal cell carcinoma, Renal cryoablation, Needle core biopsy, Renal pathology.

University of California in San Francisco, Department of Urology San Francisco, California, USA (Dr. Truesdale).

New York University School of Medicine, New York, NY, USA (Dr. Mues).

Columbia University Medical Center, Department of Urology, New York, New York, USA (Drs. Badani, Pérez-Lanzac, Ms. Casazza, Mr. Hruby).

Mount Sinai School of Medicine, Institute for Translational Epidemiology, New York, New York, USA (Dr. Sartori).

Columbia University Medical Center, Department of Pathology, New York, New York, USA (Drs. Harik, O'Toole).

University of California in Irvine, Department of Urology, Irvine, California, USA (Dr. Landman).

Matthew Truesdale's work was supported by a research fellowship sponsored by the Doris Duke Charitable Foundation. The authors would also like to thank the contributions of Alison Conforto and Amy Cooper for their help with data gathering.

Address correspondence to: Jaime Landman, UC Irvine Department of Urology, Irvine, California 92697, USA. Telephone: (714) 456-7005, Fax: (212) 342-0694, E-mail: landman.jaime@gmail.com, adamammues@gmail.com

DOI: 10.4293/108680811X13176785204157

© 2011 by JSLs, *Journal of the Society of Laparoscopic Surgeons*. Published by the Society of Laparoscopic Surgeons, Inc.

INTRODUCTION

In contemporary clinical practice, preoperative renal biopsy is not routinely performed to guide treatment decisions for contrast enhancing renal cortical neoplasms (RCNs). It is well known that 80% to 90% of all enhancing RCNs are malignant in nature with reported rates of benign disease of surgically treated masses ranging from 6.1% to 16.9%.¹⁻³ Pathologic evaluation of renal masses demonstrates significant differences in oncologic outcomes, including progression to distant metastasis and cancer-specific death based on the Heidelberg histological subtype.⁴ Following extirpation, the pathologic evaluation of tissue provides valuable information about the stage of the malignancy and the patient's prognosis in terms of cancer recurrence and survival. For ablative techniques, postoperative tissue evaluation is limited to core needle biopsy or aspiration taken at the time of surgery. This information can be helpful, because up to a third of RCNs (<4.0cm) are benign.⁵ Given that needle biopsy at the time of surgery is often the only pathologic data for tumors treated with ablation, it is imperative that the sam-

pled tissue accurately captures the true underlying tumor histopathology. A meta-analysis of 47 series of cryoablation and RFA procedures for RCNs revealed that only 82.3% of cryoablation cases and 62.2% of RFA cases underwent preablation biopsy.⁶ Of the RCNs that were biopsied, 33.5% had unknown or indeterminate pathology highlighting the high rate of intraoperative biopsy failure for ablative modalities.

Side effects from preoperative renal biopsy are rare but include a 1% to 2% risk of hemorrhage, infection, and a 0.01% risk of tumor seeding along the needle tract.⁷⁻¹⁰ Ideally, an intraoperative biopsy protocol would optimize histopathologic accuracy and minimize side effects associated with the procedure. In a porcine pilot study, we demonstrated the feasibility of a postablative biopsy protocol in an effort to optimize the oncologic safety and address the concern with tumor seeding, which has served as a real barrier for many clinicians, preventing the universal practice of intraoperative biopsies of RCNs.¹¹ Theoretically, postablative biopsy should reduce the risk of tumor seeding, given that the tissue in question would not be viable prior to extraction through the needle tracts. In addition, a second pilot study in our laboratory compared the accuracy of 2 different biopsy techniques at detecting renal tumor architecture during cryoablation and concluded that a modified technique (**Figure 1**)¹² was as equally safe and feasible as the currently used standard technique.¹³ The modified technique was developed with the hope that the longer time for the biopsy needle to accelerate outside the renal parenchyma may result in sharper cuts and cleaner biopsy specimens. In the current study, we compared 2 core needle biopsy techniques taken before and after renal cryoablation. The main objective of this study was to identify the biopsy protocol associated with the highest level of accuracy for identifying tumor histopathology in patients undergoing LCA for small RCNs. By identifying the ideal biopsy protocol, we hope to improve upon the low intraoperative biopsy rate and the high biopsy failure rate for ablative treatments of RCNs.⁶

MATERIALS AND METHODS

Patients

This prospective study was conducted under the review and approval of our institutional review board. Between July 2007 and February 2009, 30 consecutive patients with solid, enhancing RCNs <4cm in diameter underwent intraoperative tumor biopsy during standard LCA by a single

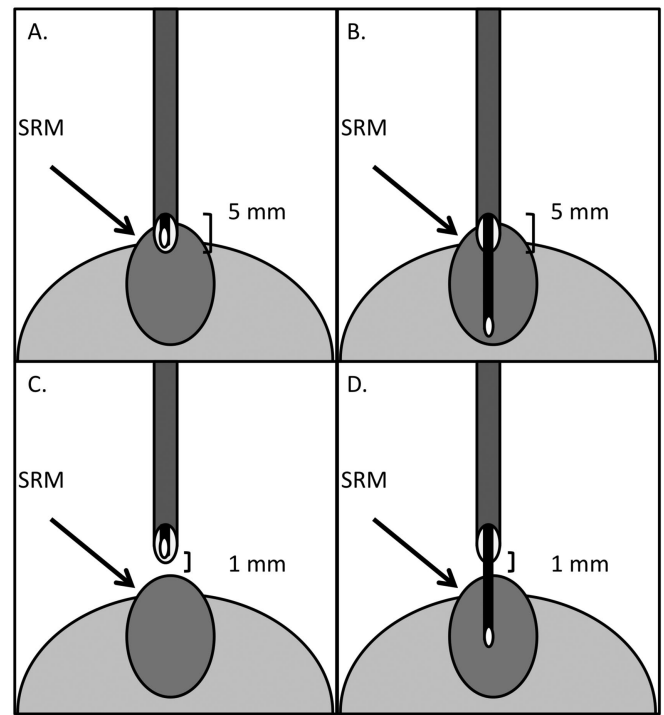


Figure 1. Biopsy Techniques.¹⁴ Image A and B depict the Modified Technique in which the biopsy needle is placed at a depth of 5mm in the renal parenchyma (A) prior to sampling (B). Image C and D depict the Standard Technique in which the biopsy needle is held 1mm outside the renal parenchyma (C) prior to sampling (D).

surgeon (JL). All enrolled subjects signed an IRB-approved consent form and underwent LCA via either a retroperitoneal or transperitoneal approach.

Procedure

Following mobilization of the affected kidney, the location of the tumor was identified and confirmed using a standard laparoscopic ultrasound system (SUS) (BK Medical Systems Inc, Peabody, MA). Once identified, an 18-gauge biopsy needle (Bard MaxCore, Covington, GA) was used to sample (preablation biopsy) the renal mass prior to placement of the icerods (Galil Medical Inc., Arden Hills, MN). A total of 2 cores were taken, one using a standard and one using a modified technique as previously described and illustrated in **Figure 1**.¹² In the standard technique, the needle biopsy device was deployed after insertion into the renal tissue under ultrasound guidance at a depth of 5mm. In the modified technique, the needle biopsy device was deployed 1mm outside of the renal tissue. For exophytic lesions, the biopsy needle was guided to the lesion under direct vision. For endophytic

lesions, the laparoscopic ultrasound was used to guide needle placement. A standard double freeze-thaw cycle was used as previously described to adequately ablate the involved tissue.¹⁴ Procedures were performed using a commercially available cryoablation machine (SeedNet Gold) (Galil Medical Inc., Arden Hills, MN) and utilized a variable number of 1.47-mm cryoablation probes (IceRods, Galil Medical Inc., Arden Hills, MN). Complete ablation was confirmed using SUS to measure the size and extent of the ice ball formation. Once the tissue was fully thawed and the icerods had been removed, 2 postablation core needle biopsy specimens (standard and modified) were taken under ultrasound guidance utilizing the identical protocol performed preoperatively.

Information was recorded for each patient including age, race, tumor size, location (exophytic/endophytic/mesophytic), biopsy core length, and specimen histology. We classified lesions based on the percentage of tumor that extends beyond the normal renal parenchymal contour; exophytic tumors have >60% of their mass outside the natural contour of the kidney. Endophytic tumors have >60% of their mass within the natural border of the kidney, and mesophytic tumors have 40% to 60% of their mass in either direction.¹³

Biopsy Processing

All 4 biopsy cores were separately labeled in containers and then fixed in 5% formalin solution, placed in cassettes, and embedded in paraffin. Each cassette was then sectioned 3 times and stained using hematoxylin and eosin. Physical characteristics of each biopsy specimen were obtained, including gross measurements of the core lengths as well as a pathologic description of the tumor architecture. Each biopsy core was evaluated by 1 of 2 dedicated urologic pathologists (LH or KMO) who were blinded to the nature of the biopsy technique used and whether the biopsy was pre- or postcryoablation. A final pathologic description/diagnosis of each biopsy specimen was recorded.

Biopsies were classified as malignant, benign, or nondiagnostic based on the interpretation of the uropathologist. Malignant tumors were classified per the Heidelberg classification system.¹⁵ Benign tumors included oncocytoma, angiomyolipoma, metanephric adenoma, or a renal cyst. Nondiagnostic biopsies were identified if only normal renal parenchyma or fibrosis was present, preventing a definitive diagnosis.

Statistical Methods

The reference standard histopathology was determined for each tumor by taking the maximum (ie, highest grade) tumor pattern across all 4 biopsy specimens. Therefore, if one biopsy was classified as malignant and the remaining 3 were benign, the reference standard was deemed malignant. Further, if one biopsy was classified as benign and the remaining were nondiagnostic, the reference standard was deemed benign. In cases in which all 4 biopsies were termed nondiagnostic, no true diagnosis was given. Because no reference standard could be determined, these patients were subsequently removed from the analysis of biopsy agreement.

The accuracy of biopsies to identify the reference standard cell type histopathology (not grade) was evaluated using agreement scores or percentage of biopsies in agreement with the reference standard pathology. Agreement was defined as an individual biopsy resulting in the identical cell type histopathologic diagnosis as the reference standard for the RCN. Cohen's kappa was used as a measure of agreement between reference standard pathology for each individual biopsy. A kappa coefficient up to 0.20 was considered as a slight agreement, between 0.21 and 0.40 as a fair agreement, between 0.41 and 0.60 as a moderate agreement, between 0.61 and 0.80 as a substantial agreement, and >0.80 as an almost perfect agreement.¹⁶

Logistic regression was used to evaluate the impact of biopsy length, age, race, tumor size, and tumor location on biopsy agreement. This calculation reflected the fact that 4 biopsies from each patient shared repeated variables, including age, race, tumor size, and tumor location through repeated measure analysis. Finally, biopsy length was compared across all biopsy types using a Wilcoxon rank sum test. The threshold for significance was set at $P \leq .05$.

RESULTS

Thirty patients with 33 renal tumors underwent LCA. Patient demographic information is summarized in **Table 1**. The mean patient age was 69.1 ± 8.0 years with a mean tumor size of 2.3 ± 0.7 cm (range, 0.5 to 3.8). One (3%) patient was Asian, 5 (15%) were African American, 1 (3%) was Hispanic, 22 (67%) were Caucasian, and 4 (12%) selected "other" as their race. Sixteen (49%) of the tumors were classified as endophytic, 14 (42%) were exophytic, and 3 (9%) were mesophytic. The mean estimated blood loss for all procedures was 72.6 ± 103.5 mL (range, 5 to 300).

A total of 188 needle core biopsies were taken intraoperatively under SUS guidance with 33 occurring preablation with the standard method, 33 occurring preablation with the modified method, 26 occurring postablation with the standard method, and 26 occurring postablation with the modified method. No significant intraoperative bleeding resulted from any of the biopsies taken. Overall, when all biopsies were included, a definitive diagnosis was made in 31 of the 33 renal tumors (94.0%). Of the 31 lesions in which a pathologic diagnosis was made, 10 (32.2%) were designated as benign RCNs with the remaining 21 (67.7%) described as malignant. **Table 2** details the breakdown of pathologic diagnoses given for all patients.

Across all samples, biopsy length was significantly longer using the standard technique compared to the mod-

ified technique with mean lengths of 9.3 ± 5.9 mm vs. 7.0 ± 4.6 mm, respectively ($P = .02$). No significant difference in length was seen when comparing biopsy length for all preablation vs. postablation samples with mean lengths of 8.8 ± 5.8 mm vs. 7.3 ± 4.8 mm, respectively ($P = .2$) (**Figure 2**).

Table 3 summarizes the percentage (%) agreement and kappa score for each biopsy type with the pathologic reference standard diagnosis. The highest agreement was seen in preablation biopsies using both the standard and modified approach, 90.3% each. Following logistic regression analysis (**Table 4**), significant association with agreement was seen for age ($P = .05$) and tumor size ($P = .02$). No significant association was seen for biopsy length ($P = .09$), race ($P = .4$), or tumor location (exophytic, $P = .2$ /endophytic, $P = .6$). When controlling for race, biopsy size, tumor size, and tumor location, percentage agreement with reference standard histopathology decreased as age increased ($P = .05$). When controlling for age, race, biopsy size, and tumor location, percentage agreement with reference standard histopathology increased as tumor size increased ($P = .02$).

DISCUSSION

In standard practice, biopsies taken during renal ablation procedures are typically performed prior to the ablative intervention. While there is little clinical evidence for tumor seeding during cryoablation procedures, some urologists have been hesitant to biopsy renal tumors at the time of the procedure. In 2004, Margulis and colleagues¹⁷ reported that post-RFA biopsy is sufficient for accurate pathologic diagnosis. Postablation biopsy will theoretically reduce the risk of tumor seeding, given that the tissue in question would not be viable prior to disruption of the tumor and extraction

Table 1.
Patient Demographic Information

Sample Size	33
Mean Patient Age (years)	69.1 ± 8.0
Mean Tumor Size (diameter in cm)	2.3 ± 0.7
Race (%)	
Asian	1 (3)
African American	5 (15)
Hispanic	1 (3)
Caucasian	22 (67)
Other	4 (12)
Tumor Location (%)	
Endophytic	16 (49)
Exophytic	14 (42)
Mesophytic	3 (9)
Estimated Blood Loss (mL)	72.6 ± 103.5

Table 2.
Histopathology After Renal Core Biopsy

Biopsy Result	Pathology	# of tumors	% of tumors	
Malignant	Clear Cell Renal Carcinoma	12	36.4	63.7
	Papillary Renal Carcinoma	6	18.2	
	Chromophobe Renal Carcinoma	3	9.1	
Benign	Oncocytoma	9	27.3	30.3
	Angiomyolipoma	1	3.0	
Nondiagnostic	Normal Renal Parenchyma	1	3.0	6.0
	Scant Fibrous Tissue	1	3.0	
Total		33	100	

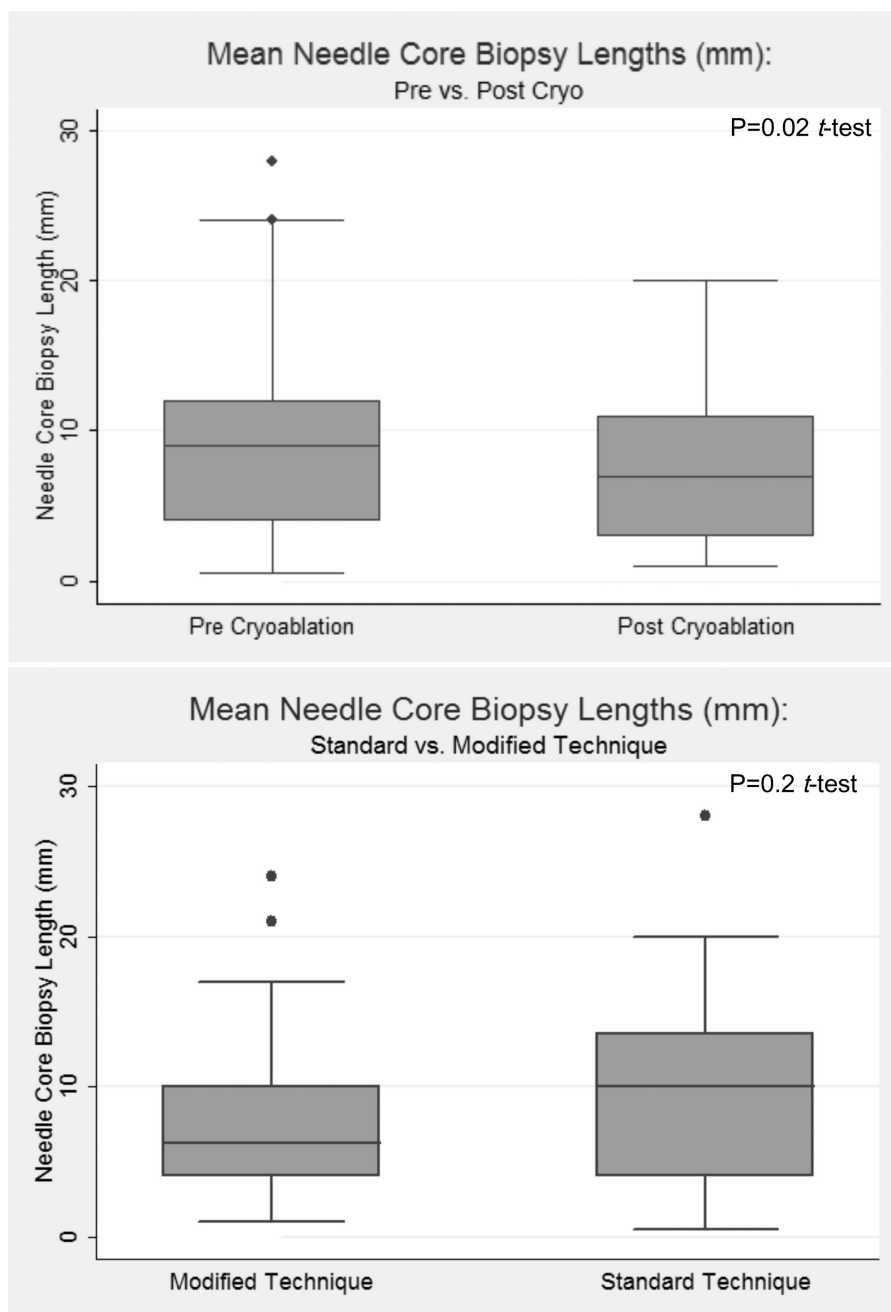


Figure 2. Box-plot of biopsy lengths (mm) (pre- vs. postablation and standard vs. modified technique).

through the needle tracts. As cryoablation and RFA have distinctly different ablation mechanisms, we previously evaluated and demonstrated the feasibility of postcryoablation biopsy in the porcine setting.¹¹

In recent years, advancements in renal biopsy technology and pathologic analysis have led to improvements in the accuracy of distinguishing benign from malignant

tumors.¹⁸ Studies comparing renal biopsy results with pathologic evaluation of nephrectomy specimens report average concordance rates of 92% to 95%^{7,9,19} up from an average rate of 88.9% before 2001.¹⁸ Furthermore, a metaanalysis across all renal mass biopsy studies reported mean sensitivity and specificity of 92.1% and 89.7%, respectively.¹⁸ Across all renal biopsies, our

Table 3.
Percentage Agreement and Kappa Score by Biopsy Type

Biopsy Type	% Agreement with Reference Standard	Kappa	SE	P-Value	% Nondiagnostic Specimens
Preablation Standard	90.3 (28/31)	0.81	0.15	<.0001	15.2 (5/33)
Preablation Modified	90.3 (28/31)	0.81	0.15	<.0001	15.2 (5/33)
Postablation Standard	41.7 (10/24)	0.25	0.08	.0007	61.5 (16/26)
Postablation Modified	37.5 (9/24)	0.21	0.07	.002	65.4 (17/26)

Column 1 details the percentage agreement with the reference standard pathology for each individual biopsy. For this calculation, only RCNs with a definitive diagnosis (n=31 for preablation biopsies and n=24 for postablation biopsies) were included as described in the Methods. In addition, kappa score with standard error and P-values are listed. Column 3 details the overall percentage of nondiagnostic specimens across all biopsies taken (n=33 for preablation biopsies and n=26 for postablation biopsies).

Table 4.
Analysis of Empirical Standard Error Estimates for Logistic Regression Analysis of Repeated Measures

Parameter	Estimate	Standard Error	95% Confidence Limits	Z	Pr > Z	
Biopsy Length	0.0838	0.0499	-0.0140 0.1815	1.68	0.09	
Age	-0.0645	0.0323	-0.1279 -0.0011	-1.99	0.05	
Race	Other	-0.1309	0.8060	-1.7107 1.4490	-0.16	0.87
	Hispanic	-0.5686	0.4696	-1.4891 0.3518	-1.21	0.2
	White	-0.5024	0.6063	-1.6908 0.6860	-0.83	0.4
	Asian	-1.7447	0.9076	-3.5236 0.0341	-1.92	0.06
Tumor Size	0.1123	0.0468	0.0206 0.2039	2.40	0.02	
Tumor Location	Exophytic	-1.2134	0.8612	-2.9014 0.4746	-1.41	0.2
	Endophytic	-0.5256	0.9503	-2.3882 1.3371	-0.55	0.6

overall concordance rate with reference standard histopathology was 94%, which parallels results from contemporary renal biopsy studies. Previously, we evaluated the histologic accuracy of needle core biopsy before and after renal cryoablation.¹¹ Diagnostic accuracy of both pre- and postcryoablation sampling was 70%. In a separate pilot evaluation, we evaluated the accuracy of 2 different biopsy techniques (standard vs. modified) at determining tumor histopathology during renal cryoablation.¹² The biopsy techniques studied are illustrated in **Figure 1**. The pilot study revealed that the standard and modified techniques established a diagnosis in 7 of 10 and 9 of 10 cases, respectively.¹²

In our study, a diagnosis could not be made in 2 (6%) of the patients. False-negative results are usually due to sampling error, which can include sampling of necrotic tissue, normal renal parenchyma, or an insufficient amount of tissue. Previous studies report false-negative rates due to

technical limitations or insufficient tissue sampling ranging from 0% to 30%,⁹ which is slightly higher than our reported failure rate. Finally, contemporary studies document that up to 40% of all RCNs are benign, which is consistent with our pathologic results and confirms that our sample accurately reflects the general population.^{5,20-22}

Results from this study indicate that factors associated with improved pathologic accuracy of the renal biopsy include a younger patient age and larger tumor size. It should be noted that all patients in the current study had T1a (<4cm) renal masses, and the term “larger” must be taken in this context. Previous studies demonstrate that biopsy failure rates are higher for smaller renal tumors.²³ A study by Lechevallier and coworkers²³ found that biopsy failure rates were as high as 37% for tumors <3cm compared with 9% for tumors >3cm. This observation is intuitive, because there is a greater chance of miss-sampling the

affected tissue for smaller tumors. Of course, this finding is not consistently found in all renal biopsy studies. A recent study by Wang and Wood²⁴ demonstrated that of 110 small RCN biopsies ≤ 4 cm, no difference was found in terms of diagnostic accuracy as a function of tumor size. Regardless, improvements in image-guided biopsy techniques should continue to reduce this sampling error by enhancing the ability of real-time tumor identification. Such results suggest that more aggressive biopsy protocols for those patients at greatest risk for biopsy failure, (older patients with smaller tumors) may improve sampling accuracy.

Diagnostic accuracy in our study was vastly superior for the preablation samples compared to those taken postablation with percentage accuracies of 90% vs. approximately 40%. Furthermore, the percentage of nondiagnostic samples was much greater for the postablation biopsies with rates $>60\%$ vs. only 15% in the preablation samples. No major difference in accuracy was seen for biopsy technique (standard vs. modified). These results contradict the findings of our previous pilot study, which found no difference in diagnostic accuracy for samples taken pre- vs. postcryoablation (70% for both).¹¹ A likely explanation for this discrepancy is the very small sample size of our pilot study, which was likely insufficient to detect a significant difference across sampling time points.

When interpreting these findings, it is important to consider that the artifact created by the ablative process and the preablation biopsy procedure confound the results. Such an artifact likely impacted the quality of the postablation specimens and may partially explain the differential results. With the current data, it is certainly reasonable to perform only postablation biopsies if the surgeon is concerned about tumor seeding. However, the diminished results from postcryoablation biopsy should be taken into consideration in this setting.

Although no difference in the diagnostic accuracy of samples taken via the standard or modified technique was seen, our results show that the standard technique results in significantly longer samples. This is highly intuitive, because the modified technique does not allow for full excursion of the biopsy mechanism into the tumor. There are also limitations to the modified technique. Specifically, lesions that are completely endophytic may not be accessible via the modified technique, because the depth of penetration is limited. Given the small differences in diagnostic accuracy across biopsy techniques, no statement of superiority can be made. However, given the improved biopsy length and the possible limitations of the modified

technique, it is our recommendation that the standard technique remains the gold standard at this time.

The diagnostic accuracy for individual biopsies ranged from only 37.5% to 90.3%; however, when combined together, the accuracy improved to 94.0%. Results from our prior study also supported this finding, demonstrating an improvement from 70% to 90% for individual biopsies to 100% when combining results of all biopsies.¹² Increased accuracy of identifying “true” pathology with greater number of biopsies has been illustrated in previous studies of renal tumors²⁵ and is well established in prostate cancer.²⁶ The greater number of biopsies likely increases the chance of sampling the affected tissue. Although it would seem that a greater number of biopsies should result in increased risk of bleeding, studies to date have not shown this to be true for fine needle biopsies of renal tumors.¹⁹

An important limitation of our study is that no third party reference standard was used to make a definitive pathologic diagnosis of the renal tumor. Because there is no postoperative extirpative sample in cryoablation, only the biopsy specimens can be used to make the final diagnosis. Furthermore, although each biopsy was treated as an independent measure, the repeated measures across biopsies per tumor (ie, patient age, tumor location, tumor size, and race) introduced confounders into our analysis. Although we tried to control for this statistically using the generalized estimating equation, it is impossible to completely remove this effect from the final results. In addition, postablation biopsies may have been impacted by mechanical artifacts introduced by preablation biopsies, and no randomization protocol was used to control for this effect.

CONCLUSION

This prospective study confirms the diagnostic accuracy of intraoperative renal tumor needle core biopsy for patients undergoing cryoablation for RCNs. Factors associated with improved diagnostic accuracy include younger age and larger tumor size. Preablation sampling results in superior diagnostic accuracy, and the standard biopsy technique results in significantly longer biopsy cores. Use of a preablation standard biopsy technique results in the most accurate pathologic diagnosis for patients undergoing cryoablation for RCNs.

References:

1. Dechet CB, Sebo T, Farrow G, Blute ML, Engen DE, Zincke H. Prospective analysis of intraoperative frozen needle biopsy of

solid renal masses in adults. *J Urol.* 162(4):1282-1284, 1999 Oct; discussion 4-5.

2. Ozen H, Colowick A, Freiha FS. Incidentally discovered solid renal masses: what are they? *Br J Urol.* 72(3):274-276, 1993 Sep.

3. Silver DA, Morash C, Brenner P, Campbell S, Russo P. Pathologic findings at the time of nephrectomy for renal mass. *Ann Surg Oncol.* 4(7):570-574, 1997 Oct-Nov.

4. Leibovich BC, Lohse CM, Crispen PL, et al. Histological subtype is an independent predictor of outcome for patients with renal cell carcinoma. *J Urol.* 183(4):1309-1315, 2010 Apr.

5. Frank I, Blute ML, Cheville JC, Lohse CM, Weaver AL, Zincke H. Solid renal tumors: an analysis of pathological features related to tumor size. *J Urol.* 170(6 Pt 1):2217-2220, 2003 Dec.

6. Kunkle DA, Uzzo RG. Cryoablation or radiofrequency ablation of the small renal mass: a meta-analysis. *Cancer.* 113(10):2671-2680, 2008 Nov 15.

7. Wood BJ, Khan MA, McGovern F, Harisinghani M, Hahn PF, Mueller PR. Imaging guided biopsy of renal masses: indications, accuracy and impact on clinical management. *J Urol.* 161(5):1470-1474, 1999 May.

8. Nadel L, Baumgartner BR, Bernardino ME. Percutaneous renal biopsies: accuracy, safety, and indications. *Urol Radiol.* 1986;8(2):67-71.

9. Volpe A, Kachura JR, Geddie WR, et al. Techniques, safety and accuracy of sampling of renal tumors by fine needle aspiration and core biopsy. *J Urol.* 178(2):379-386, 2007 Aug.

10. Herts BR, Baker ME. The current role of percutaneous biopsy in the evaluation of renal masses. *Semin Urol Oncol.* 13(4):254-261, 1995 Nov.

11. Lambert EH, Hruby GW, Abundez JO, et al. Comparison of the histologic accuracy of needle biopsy before and after renal cryoablation: laboratory and initial clinical experience. *Urology.* 70(5):1024-1027, 2007 Nov.

12. Hruby GW, Lehman D, Mitchell R, et al. Optimizing renal cortical neoplasm tissue sampling through a modified biopsy technique: laboratory experience and initial clinical experience. *Urology.* 70(3):431-434, 2007 Sep.

13. Finley DS, Lee DI, Eichel L, Uribe CA, McDougall EM, Clayman RV. Fibrin glue-oxidized cellulose sandwich for laparoscopic wedge resection of small renal lesions. *J Urol.* 173(5):1477-1481, 2005 May.

14. Gill IS, Novick AC, Meraney AM, et al. Laparoscopic renal cryoablation in 32 patients. *Urology.* 56(5):748-753, 2000 Nov 1.

15. Kovacs G, Akhtar M, Beckwith BJ, et al. The Heidelberg classification of renal cell tumours. *J Pathol.* 183(2):131-133, 1997 Oct.

16. Landis J, Koch G. The measurement of observer agreement for categorical data. *Biometrics.* 1977;33:159-174.

17. Margulis V, Matsumoto ED, et al. Acute histologic effects of temperature-based radiofrequency ablation on renal tumor pathologic interpretation. *Urology.* 64(4):660-663, 2004 Oct.

18. Lane BR, Samplaski MK, Herts BR, Zhou M, Novick AC, Campbell SC. Renal mass biopsy—a renaissance? *J Urol.* 179(1):20-27, 2008 Jan.

19. Neuzillet Y, Lechevallier E, Andre M, Daniel L, Coulange C. Accuracy and clinical role of fine needle percutaneous biopsy with computerized tomography guidance of small (less than 4.0 cm) renal masses. *J Urol.* 171(5):1802-1805, 2004 May.

20. Remzi M, Ozsoy M, Klingler HC, et al. Are small renal tumors harmless? Analysis of histopathological features according to tumors 4 cm or less in diameter. *J Urol.* 176(3):896-899, 2006 Sep.

21. Leuret T, Poulain JE, Molinie V, et al. Percutaneous core biopsy for renal masses: indications, accuracy and results. *J Urol.* 178(4 Pt 1):1184-1188, 2007 Oct; discussion 8.

22. Maturen KE, Nghiem HV, Caoili EM, Higgins EG, Wolf JS, Jr., Wood DP, Jr. Renal mass core biopsy: accuracy and impact on clinical management. *AJR Am J Roentgenol.* 188(2):563-570, 2007 Feb.

23. Lechevallier E, Andre M, Barriol D, et al. Fine-needle percutaneous biopsy of renal masses with helical CT guidance. *Radiology.* 216(2):506-510, 2000 Aug.

24. Wang R, Wood DP, Jr. Evolving role of renal biopsy in small renal masses. *Urol Oncol.* 27(3):332-334, 2009 May-Jun.

25. Cestari A, Guazzoni G, dell'Acqua V, et al. Laparoscopic cryoablation of solid renal masses: intermediate term followup. *J Urol.* 172(4 Pt 1):1267-70, 2004 Oct.

26. Epstein JI, Potter SR. The pathological interpretation and significance of prostate needle biopsy findings: implications and current controversies. *J Urol.* 166(2):402-410, 2001 Aug.