

UC Davis

Dermatology Online Journal

Title

Histiocytoid autoimmunity-related neutrophilic dermatosis in a patient with rheumatoid arthritis

Permalink

<https://escholarship.org/uc/item/5ht6v1rp>

Journal

Dermatology Online Journal, 23(9)

Authors

Paek, Jennifer
Ho, Jonathan Dale
Al-Haseni, Ali
[et al.](#)

Publication Date

2017

DOI

10.5070/D3239036492

Copyright Information

Copyright 2017 by the author(s). This work is made available under the terms of a Creative Commons Attribution-NonCommercial-NoDerivatives License, available at <https://creativecommons.org/licenses/by-nc-nd/4.0/>

Peer reviewed

Histiocytoid autoimmunity-related neutrophilic dermatosis in a patient with rheumatoid arthritis

Jennifer Paek¹, Jonathan Dale Ho^{1,2} MBBS MSc, Dip Dermpath, Ali Al-Haseni¹ MD MSc, Jean McGee¹ MD PhD, Allison Larson¹ MD, Jag Bhawan^{1,2} MD

Affiliations: ¹Boston University School of Medicine, Department of Dermatology, Boston Massachusetts ²Boston University School of Medicine, Section of Dermatopathology, Boston Massachusetts

Corresponding Author: Ali Al-Haseni, 609 Albany Street, Boston MA, 02118, Tel: 617-987-5260, Email: alighazi@bu.edu

Abstract

Autoimmunity-associated neutrophilic dermatoses are a recently recognized manifestation of connective tissue diseases, in particular, lupus erythematosus. These entities are clinically and sometimes histopathologically distinct from classic neutrophilic dermatoses. We describe a case of an autoimmunity-related neutrophilic dermatosis in a patient with rheumatoid arthritis. In addition to this uncommon association, there was an absence of mature neutrophils and a population of immature histiocytoid granulocytes. This unusual case expands the concept of histiocytoid neutrophilic dermatoses to include those seen in association with autoimmune connective tissue diseases.

Keywords: neutrophilic dermatosis, histiocytoid, rheumatoid arthritis, autoimmunity, Sweet syndrome

Introduction

Neutrophilic dermatoses (NDs) are uncommon inflammatory diseases, which are frequently associated with underlying systemic disease. In recent times, the occurrence of non-classical NDs has been identified in patients with lupus erythematosus (LE) and only very rarely in other autoimmune connective tissue diseases (AICTD). We report patient with a neutrophilic dermatosis, distinct from Sweet syndrome (SS) or any other typical ND, in a patient with seropositive rheumatoid arthritis (RA). Fascinatingly, there was a complete absence of mature neutrophils, but rather a population of immature granulocytes with a histiocytoid cytomorphology, which is

exceedingly rare outside of cases of otherwise typical histiocytoid SS.

Case Synopsis

A 77-year-old man with a history of seropositive rheumatoid arthritis (RA), presented to our clinic with a rash of 15 months duration involving the scalp, face, neck, and upper chest. The patient endorsed lesional pruritus and burning but denied photosensitivity. The rash was episodic in nature, with periodic exacerbations followed by partial spontaneous resolution of lesions. There was no history of prior treatment. He reported a flare of his RA with left wrist swelling and pain around the time of initial presentation. Additional comorbid diseases included chronic obstructive pulmonary disease, a previous history of alcohol abuse, and a ten-year history of stable anemia and leukopenia

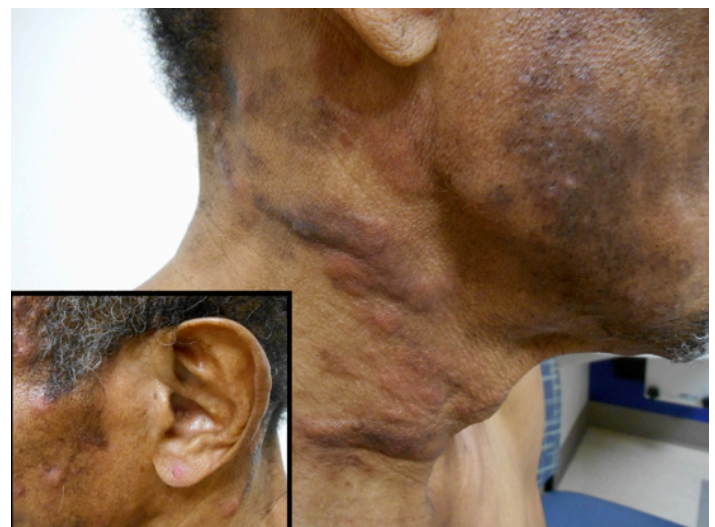

Figure 1. Erythematous, indurated papules and plaques involving the lateral neck, face, and ears (inset). Note hyperpigmented patches corresponding to burnt-out lesions.

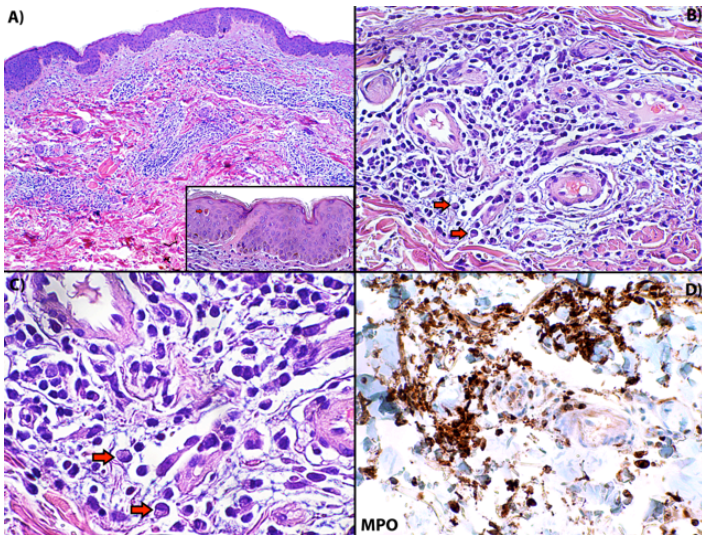


Figure 2. Histiocytoid neutrophilic dermatosis, (A) demonstrating a superficial and mid perivascular, periappendageal and interstitial inflammatory cell infiltrate, H&E, 40x, inset 100x; focal basal vacuolar change with rare individually necrotic keratinocytes (inset, arrow) and increased dermal mucin. B, C) The infiltrate is comprised of scattered lymphocytes and an unusual population of histiocytoid cells with eccentric, C-shaped nuclei and abundant pink cytoplasm (arrows); H&E, 100x; C) 200x. D) Positive staining with myeloperoxidase (MPO), confirming myeloid lineage, 100x.

followed by the hematology department as alcohol related bone-marrow suppression. He denied fever or other constitutional symptoms and there was no history of preceding gastrointestinal or respiratory infection, recent vaccination, or new medications. His medications included tiotropium bromide, omeprazole, citalopram, cyanocobalamin, ergocalciferol, and albuterol along with acetaminophen, and ibuprofen as needed. His RA was previously treated with methotrexate with good response, but this was discontinued owing to relative disease inactivity, having had no other documented flare of his RA in over 2 years.

On physical exam he was noted to have indurated erythematous nodules and plaques involving the anterior scalp, face, lateral neck, and upper chest (**Figure 1**). Hyperpigmented patches corresponding to areas of previously active lesions, consistent with the episodic nature of the rash were also noted.

In addition to his positive RF, lab evaluation revealed a positive ANA at >1:2560. Other notable findings were stable anemia (hemoglobin and hematocrit ranging from 10.1-12.0 g/dl and 32.1-37.6% with averages of 11.1g/dl and 34.5%, respectively) and

leukopenia (WBC 1.8-5.3 $\times 10^9/L$, mean 2.7 $\times 10^9/L$), which had been previously attributed to his alcohol use. Additional laboratory work-up including liver function tests, urinalysis, dsDNA, C3/C4, ESR, and CRP were all otherwise unremarkable.

A lesional biopsy was performed, which revealed focal basal layer vacuolar change, a superficial and mid-perivascular, periappendageal, and interstitial inflammatory cell infiltrate, and increased dermal mucin (**Figure 2A-B**). No vasculitis, extravasated erythrocytes, or leukocytoclasia were present. In addition to scattered lymphocytes, numerous small to medium-sized histiocytoid cells with eccentric, hyperchromatic, reniform nuclei and an eosinophilic cytoplasm were noted (**Figure 2B-C**). Owing to the unusual cytomorphology, markers to establish lineage were performed. The cells were CD45/LCA (+), CD68 (+), myeloperoxidase (MPO) positive (**Figure 2D**), and negative for CD1a, consistent with an immature myeloid phenotype. Given the subtlety of the histologic findings, the histiocytoid morphology of the infiltrate, the history of RA, and the lack of criteria for SS or any other conventional ND, a diagnosis of histiocytoid autoimmunity-related neutrophilic dermatosis was rendered. The patient was prescribed triamcinolone 0.1% ointment to be applied twice daily and reported marked improvement of his skin lesions. Additionally, he was referred to the rheumatology department for management of his arthritis, but unfortunately defaulted from further follow up.

Case Discussion

The neutrophilic dermatoses are a related group of inflammatory conditions primarily characterized by the histologic finding of neutrophilic infiltration in the skin. NDs reported to occur in the setting of AICTDs include SS, palisaded and neutrophilic granulomatous dermatitis (PNGD), interstitial granulomatous dermatitis, amicrobial pustulosis of the folds, pyoderma gangrenosum, bullous lupus erythematosus, erythema elevatum diutinum, and rheumatoid neutrophilic dermatitis (RND), [1]. Recently, the occurrence of non-classic neutrophilic dermatoses in patients with lupus erythematosus (LE) has been described [2]. Although initially thought to be exclusively associated with LE, a recent review highlighted a single case associated with rheumatoid

arthritis and secondary Sjogren syndrome and proposed the more generic name autoimmunity-related neutrophilic dermatosis (ARND), [3]. Lesions of ARND are often clinically difficult to classify, typically failing to meet the criteria for established NDs and demonstrating overlapping clinical and pathologic features with classic NDs. Reported clinical presentations include erythematous papules, annular plaques, urticarial lesions, a dermatomyositis-like eruption, and subcutaneous and palmoplantar nodules [2, 4-7]. The histologic picture is variable, but two main patterns have been described. The first is a Sweet-like dermatosis with pan-dermal neutrophilic inflammation, dermal edema, extravasated erythrocytes, and prominent leukocytoclasia [2, 4, 8, 9]. The second pattern demonstrates vacuolar interface change, a superficial and deep perivascular and interstitial neutrophilic infiltrate, leukocytoclasia, and increased dermal mucin [3, 5-7]. Our patient's biopsy was most similar to the latter, but differed with regards to a complete absence of mature neutrophils and leukocytoclasia and the presence of histiocytoid granulocytes, confirmed by positivity for CD45 LCA, CD68, and myeloperoxidase (MPO). Given the lack of criteria for SS and the histopathologic picture, we term this a histiocytoid autoimmunity-associated neutrophilic dermatosis in a patient with RA.

Histiocytoid variants are a new concept in NDs and are characterized by infiltration of immature granulocytes with a histiocyte-like appearance, rather than mature polymorphonuclear leukocytes [10]. The cells are described as having eccentric 'C-shaped' nuclei with an eosinophilic cytoplasm, as demonstrated in our case (**Figure 2C**), [11]. Retention of myeloid markers allow for identification of lineage. A histiocytoid morphology has predominantly been described in patients with otherwise clinically typical Sweet syndrome, termed histiocytoid Sweet syndrome (HSS). Importantly, this variant is associated with concurrent hematologic malignancy, with up to thirty-five percent of patients having an underlying myeloid neoplasm [12]. Given this association in the prototypical histiocytoid neutrophilic dermatosis and our patient's long-standing cytopenias, a hematology consultation was requested. Evaluation, however, failed to reveal evidence of a malignancy and given the stability of the cytopenias (approximately 10 years) and lack of

significant constitutional symptoms, his hematologic abnormalities were re-attributed to bone-marrow suppression secondary to prolonged alcohol intake. In this case, it is plausible that the patient's pre-existing bone-marrow suppression of myeloid lines resulted in a failure to produce mature lines, leading to the immature histiocytoid morphology observed.

Histiocytoid neutrophilic dermatoses outside of HSS are only very rarely reported in the literature and to our knowledge has never been reported in a patient with RA. A single case report of two patients with a non-bullous histiocytoid neutrophilic eruption, felt to represent HSS in the setting of LE, has been published [9]. Although clinically similar to our patient, the reported histology was more in keeping with typical HSS comprising a dense infiltrate, scattered mature neutrophils, and prominent leukocytoclasia.

The temporal relationship of the flare in our patient's rheumatoid arthritis with the appearance of the eruption, is suggestive of association with his preexisting RA. However, given the high titer ANA positivity, new-onset lupus or an overlap connective tissue disease was considered. At the time of writing, however, the patient failed to meet the American College of Rheumatology (ACR) criteria for diagnosis of lupus erythematosus. Nevertheless, as LE is often a disease of serial rather than simultaneous manifestations, evolving LE/RA overlap cannot be excluded. RND and PNGD were also considered, but not favored. RND typically presents papules and plaques affecting the trunk and extremities in a symmetric manner and is characterized histologically by dense neutrophilic infiltration and prominent leukocytoclasia [13]. Similarly, the lack of a prominent histiocytic component and absence of vasculitis was not in-keeping with PNGD. It should be stated, however, that nosologic separation of these entities based on the degree of intensity of the clinical or histopathologic findings may be artificial, as these dermatoses likely lie on a spectrum ranging from non-specific cutaneous eruptions like ARND at one end and well-defined syndromes such as SS, at the other. Similarities in clinical and sometimes histologic findings suggest that ARNDs may be forme frustes of SS.

Conclusion

In conclusion, we report a rare case of a histiocytoid autoimmune-associated neutrophilic dermatosis in a patient with seropositive RA. It is likely that this does not represent an RA specific phenomenon, but rather a general proclivity for the development of NDs in patients with a variety of AICTDs. Familiarity with this entity including the characteristic cytomorphology and its association with non-LE AICTD is crucial to avoid misdiagnosis.

References

1. Hau E, Vignon Pennamen M-D, Battistella M, et al. Neutrophilic Skin Lesions in Autoimmune Connective Tissue Diseases: Nine Cases and a Literature Review. Moore C, ed. *Medicine*. 2014;93(29):e346. [PMID: 25546688].
2. Pavlidakey P, Mills O, Bradley S, Casey J, Morgan MB. Neutrophilic dermatosis revisited: an initial presentation of lupus? *J Am Acad Dermatol*. 2012;67:e29-e35. [PMID: 21907449].
3. Saeb-Lima M1, Charli-Joseph Y, Rodríguez-Acosta ED, Domínguez-Cherit J. Autoimmunity-related neutrophilic dermatosis: a newly described entity that is not exclusive of systemic lupus erythematosus. *Am J Dermatopathol*. 2013 Aug;35(6):655-60. [PMID: 23518639].
4. Owen CE1, Malone JC, Callen JP. Sweet-like dermatosis in 2 patients with clinical features of dermatomyositis and underlying autoimmune disease. *Arch Dermatol*. 2008 Nov;144(11):1486-90. [PMID: 19015424].
5. Brinster NK1, Nunley J, Pariser R, Horvath B. Nonbullous neutrophilic lupus erythematosus: a newly recognized variant of cutaneous lupus erythematosus. *J Am Acad Dermatol*. 2012 Jan;66(1):92-7. [PMID: 22050914].
6. Gleason BC1, Zembowicz A, Granter SR. Non-bullous neutrophilic dermatosis: an uncommon dermatologic manifestation in patients with lupus erythematosus. *J Cutan Pathol*. 2006 Nov;33(11):721-5. [PMID: 17083690].
7. Quatrano NA1, Criscito MC1, Femia AN1, Brinster NK1. Systemic lupus erythematosus-associated neutrophilic dermatosis with palmoplantar involvement. *JAAD Case Rep*. 2016 Aug 17;2(4):329-33. [PMID: 27570816].
8. Larson AR1, Granter SR2. Systemic lupus erythematosus-associated neutrophilic dermatosis—an underrecognized neutrophilic dermatosis in patients with systemic lupus erythematosus. *Hum Pathol*. 2014 Mar;45(3):598-605. [PMID: 24457080].
9. Camarillo D1, McCalmont TH, Frieden IJ, Gilliam AE. Two pediatric cases of nonbullous histiocytoid neutrophilic dermatitis presenting as a cutaneous manifestation of lupus erythematosus. *Arch Dermatol*. 2008 Nov;144(11):1495-8. [PMID: 19015425].
10. Requena L1, Kutzner H, Palmedo G, et al. Histiocytoid Sweet syndrome: a dermal infiltration of immature neutrophilic granulocytes. *Arch Dermatol*. 2005 Jul;141(7):834-42. [PMID: 16027297].
11. Magro CM1, Momtahan S1, Nguyen GH2, Wang X1. Histiocytoid Sweet's Syndrome: A localized cutaneous proliferation of macrophages frequently associated with chronic myeloproliferative disease. *Eur J Dermatol*. 2015 Jul-Aug;25(4):335-41. [PMID: 26067166].
12. Bush JW1, Wick MR2. Cutaneous histiocytoid Sweet syndrome and its relationship to hematological diseases. *J Cutan Pathol*. 2016 Apr;43(4):394-9. doi: 10.1111/cup.12659. Epub 2016 Feb 8. [PMID: 26694973].
13. Sánchez JL, Cruz A. Rheumatoid neutrophilic dermatitis. *J Am Acad Dermatol*. 1990;22(5 Pt 2):922-5. [PMID: 2335586].