UCSF
UC San Francisco Electronic Theses and Dissertations

Title
Human anatomy

Permalink
https://escholarship.org/uc/item/5jg123r0

Author
Steigerwald, Sara Lee

Publication Date
1982

Peer reviewed|Thesis/dissertation

eScholarship.org Powered by the California Digital Library
University of California

HUMAN ANATOMY An Illustrated Laboratory Guide

HUMAN ANATOMY
An Illustrated Laboratory Guide

The illustration, design and production of this laboratory guide was the thesis/project of Bob Burnett, Susan Leopold, Sara Steigerwald, and Lydia Young for a Master of Arts degree in Medical and Biological Illustration. It was created as a self-instructional teaching aid, and was prepared for use by the Department of Anatomy to instruct the first year Pharmacy students at UCSF.

This project was made possible by a University of California Instructional Improvement Award and an award by the Graduate Division from the Anthony Endowment Fund for Graduate Research.

We gratefully acknowledge the assistance and guidance of Sexton Sutherland Ph.D., of the Department of Anatomy and the faculty of the Graduate Program in Medical and Biological Illustration, Ruth C. Wakerlin, Richard A. Beindorf, and Marsha Dohrmann.

©1982 by the Regents of the University of California

All rights reserved
No part of this publication may be reproduced, stored in a retrieval system, or transmitted in any form or by any means, electronic, mechanical, photocopying, recording, or otherwise, without the prior permission of the Graduate Program in Medical and Biological Illustration, University of California, San Francisco.

HUMAN ANATOMY

An Illustrated Laboratory Guide

COMPILED BY

Dr. Alison Evans
Dr. Pat Patterson
Dr. Dan Riley
Dr. Sexton Sutherland

ILLUSTRATED AND DESIGNED BY

Bob Burnett
Susan Leopold
Sara Steigerwald
Lydia Young

CONTENTS

THORAX

1 THORACIC WALL
2 PLEURAL CAVITY
3 LUNGS
4 PERICARDIUM
5 CORONARY VESSELS
6 CHAMBERS OF THE HEART
7 MEDIASTINUM
THORAX REVIEW

ABDOMEN

8 ABDOMINAL WALL AND INGUINAL REGION
9 ABDOMINAL VISCERA AND RELATIONSHIPS
10 BLOOD SUPPLY OF THE INTESTINES
11 REMOVAL OF THE INTESTINE
12 PORTA HEPATIS AND DUODENUM
13 LIVER
14 KIDNEYS AND SUPRARENAL GLANDS
ABDOMEN REVIEW

HEAD AND NECK

15 TRIANGLES OF THE NECK
16 FACE AND PAROTID REGION
17 MEDIAN SECTION OF HEAD AND NECK
HEAD AND NECK REVIEW

UPPER EXTREMITY
18 AXILLA AND UPPER ARM
19 CUBITAL FOSSA AND FOREARM
20 WRIST AND HAND
UPPER EXTREMITY REVIEW

PELVIS AND PERINEUM
21 PELVIC STRUCTURES
22 MALE GENITO-URINARY SYSTEM
23 FEMALE GENITO-URINARY SYSTEM
PELVIS-PERINEUM REVIEW

LOWER EXTREMITY
24 FRONT OF THIGH
25 GLUTEAL REGION, BACK OF THIGH AND CALF
LOWER EXTREMITY REVIEW

Each section in this laboratory manual is followed by references, which may be particularly appropriate for the preceeding section. The references are preceeded by "GA", which refers to illustrations in Grants' Atlas of Anatomy, seventh edition by James E. Anderson, M.D. (Williams and Wilkins Co/Baltimore).



THORAX

1 THORACIC WALL

1. THORACIC CAVITY

a. On the skeleton study the thoracic cage; identify the sternum, manubrium, xiphoid process, clavicle, ribs, and thoracic vertebrae. Notice that ribs 1-6 articulate with the manubrium and sternum directly while ribs 7-10 attach indirectly via the cartilaginous costal margin. Ribs 11-12 are "floating ribs," that is, they have no skeletal attachment to the sternum. Note the sternomanubrial angle (of Louis). It is an important landmark used in counting ribs, locating specific intercostal spaces, and lies at the 4th vertebral level.

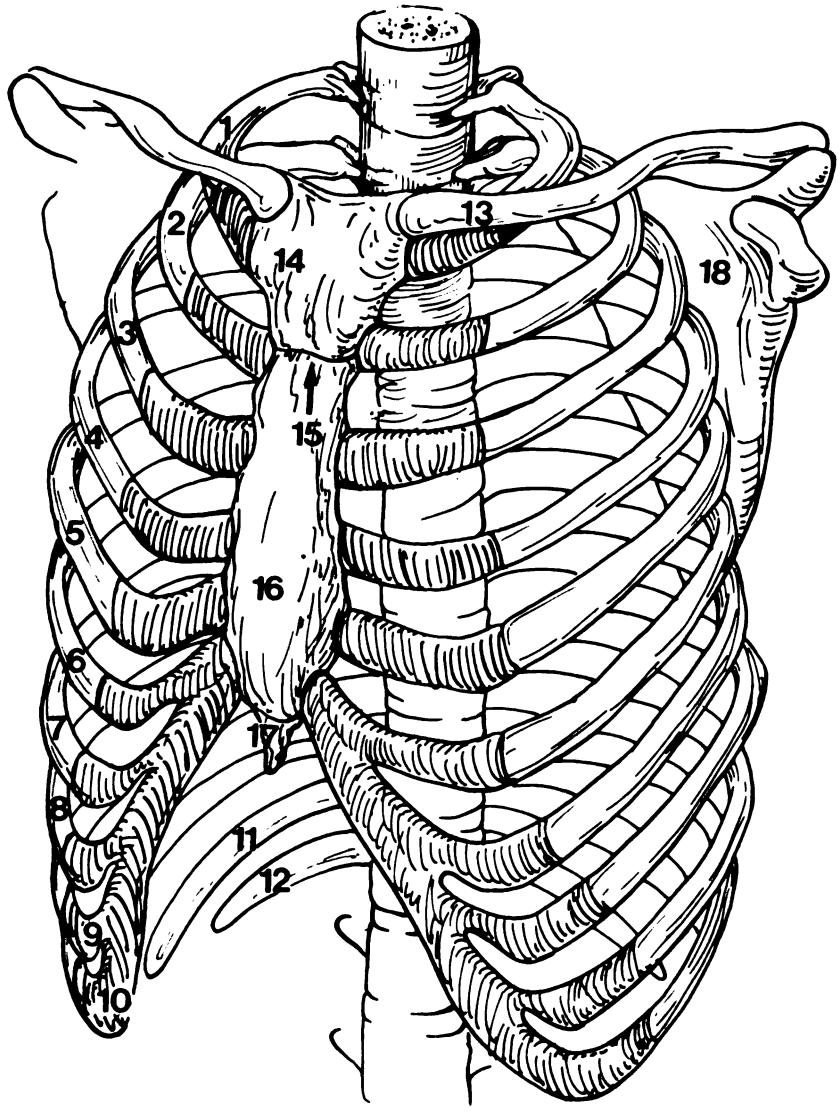

FIG. 1
1-12 Ribs
13 Clavicle
14 Manubrium
15 Sternomanubrial angle
16 Body of sternum
17 Xiphoid process
18 Scapula

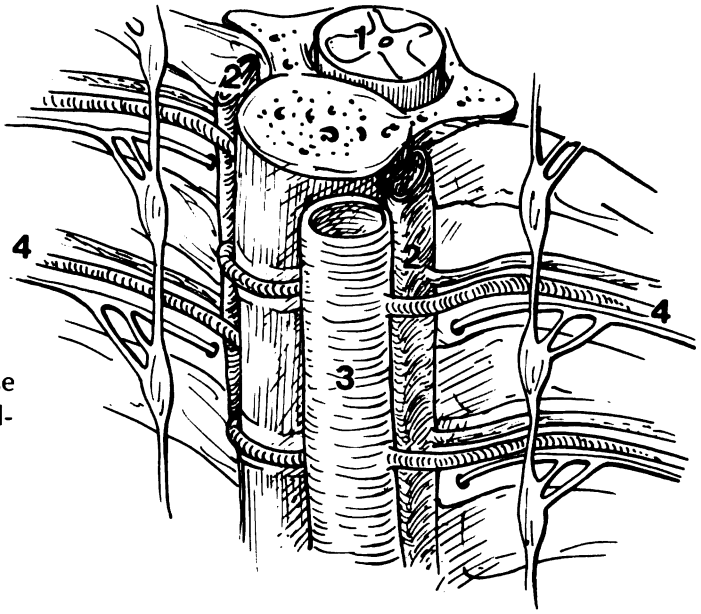

b. Turn back the skin and fascial flaps from the rib cage. Remove the "breastplate." Dissect an intercostal space in or close to the midaxillary line. Note the neurovascular bundle and its relation to the rib.

c. Note the direction of internal and external intercostal muscle fibers.

d. Note the internal thoracic artery. It is important in the blood supply to the breast and anterior abdominal wall.

(GA: 1-1, 1-13, 1-15, 1-16, 1-19)

Fig. 2
1 Spinal cord
2 Azygos vv.
3 Aorta
4 Neurovascular bundle

Fig. 3
5 Aorta
6 Subclavian a.
7 Internal thoracic a.
8 Post. intercostal a.
9 Ant. intercostal a.
10 Intercostal n.
11 External intercostal
12 Internal intercostal

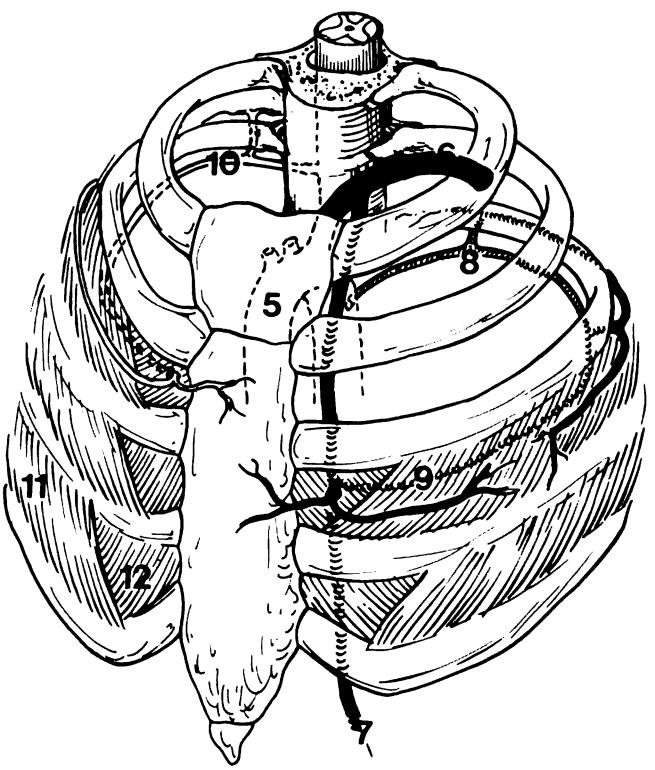

2 PLEURAL CAVITY

a. Separate the visceral pleura of the lungs from the parietal pleura lining the thoracic cavity.

b. Place a hand in the pleural cavity and slide it into the costomediastinal recess. Your hand is stopped by the reflection forming the anterior border of the pleura. Note the close approximation of the two anterior borders of the two pleural cavities.

c. Locate the costodiaphragmatic recess and trace its extent.

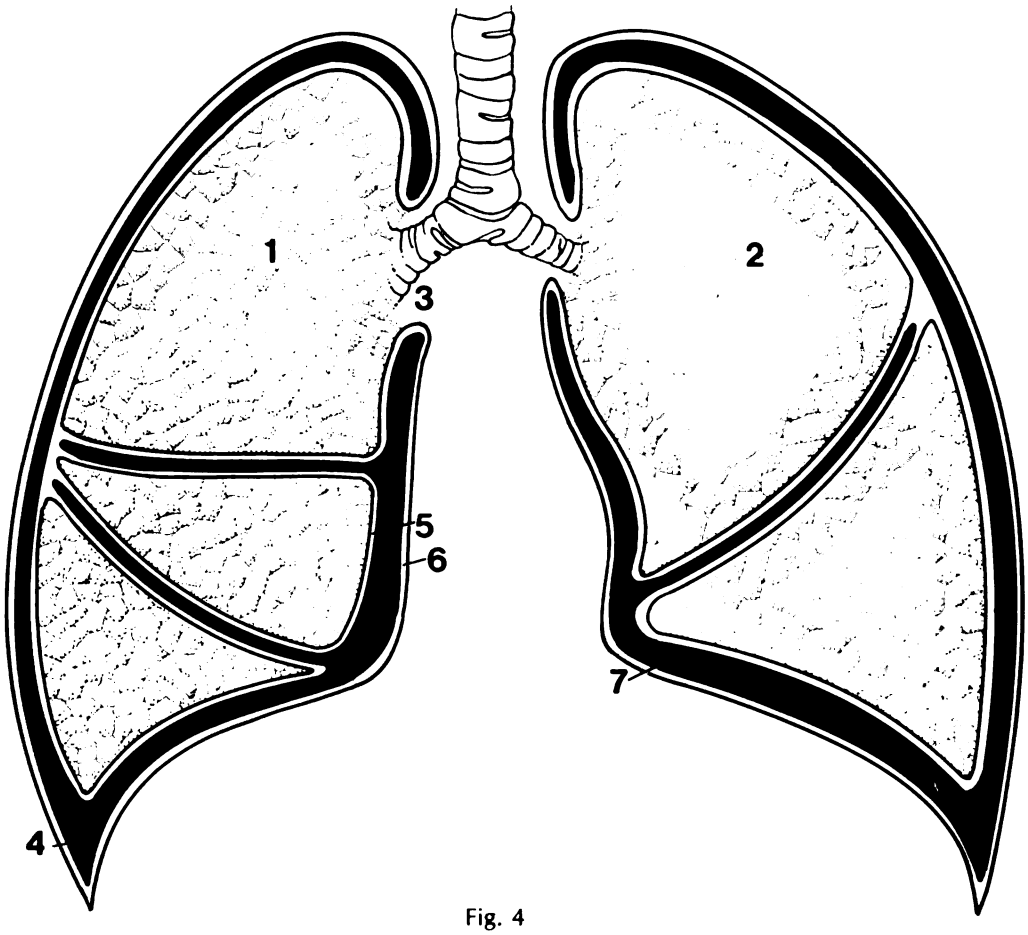

Fig. 4
1 Right lung
2 Left lung
3 Root of lung
4 Costodiaphragmatic recess
5 Visceral pleura
6 Parietal pleura
7 Pleural cavity (potential space)

d. Identify the root of the lung. Place one hand anterior to the root and the other hand posterior to the root. Note that the fingers meet above the root of the lung, but do not meet below it because of the pulmonary ligament. The latter is formed by the reflection of the visceral pleura of the lung anteriorly and posteriorly onto the mediastinal structures as it becomes parietal pleura.

3. Preserve the phrenic nerves as they course medial and anterior to the root of the lung. They will be studied later.

(GA: 1-22, 1-24, 1-28, 1-29, 1-46, 1-47)

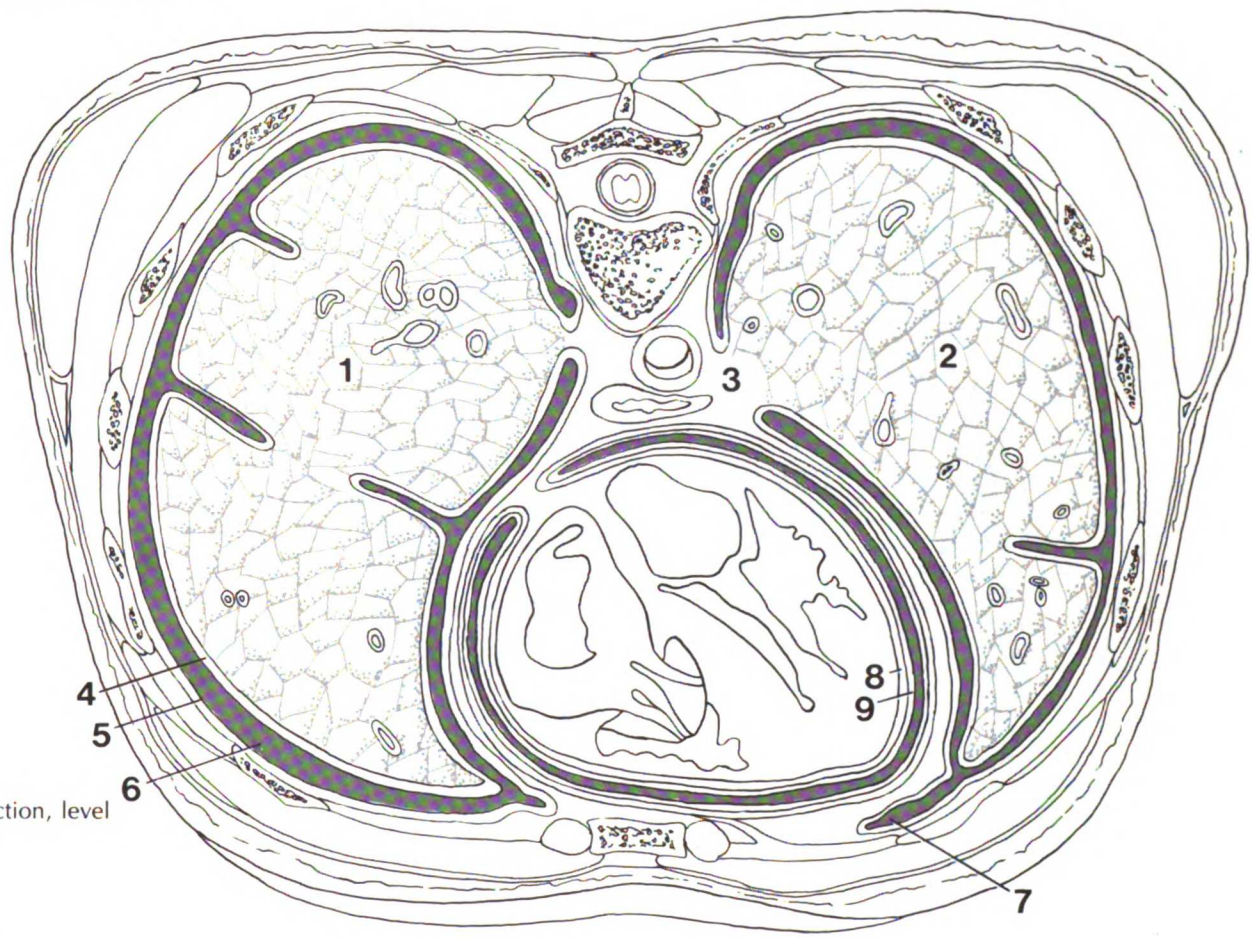

Fig. 5 Cross section, level T-7

1 Right lung
2 Left lung
3 Root of lung
4 Visceral pleura
5 Parietal pleura
6 Pleural cavity
7 Costomediastinal recess
8 Visceral serous pericardium
9 Parietal serous pericardium

3 LUNGS

a. Remove the lung: cut through the root of the lung superiorly and continue the incision inferiorly through the pulmonary ligament.

b. With the lung out of the pleural cavity, note how far into the neck the parietal pleura extends i.e., about 1" above the clavicle.

c. Study the lobes and fissures of each lung; identify the lobes of each lung.

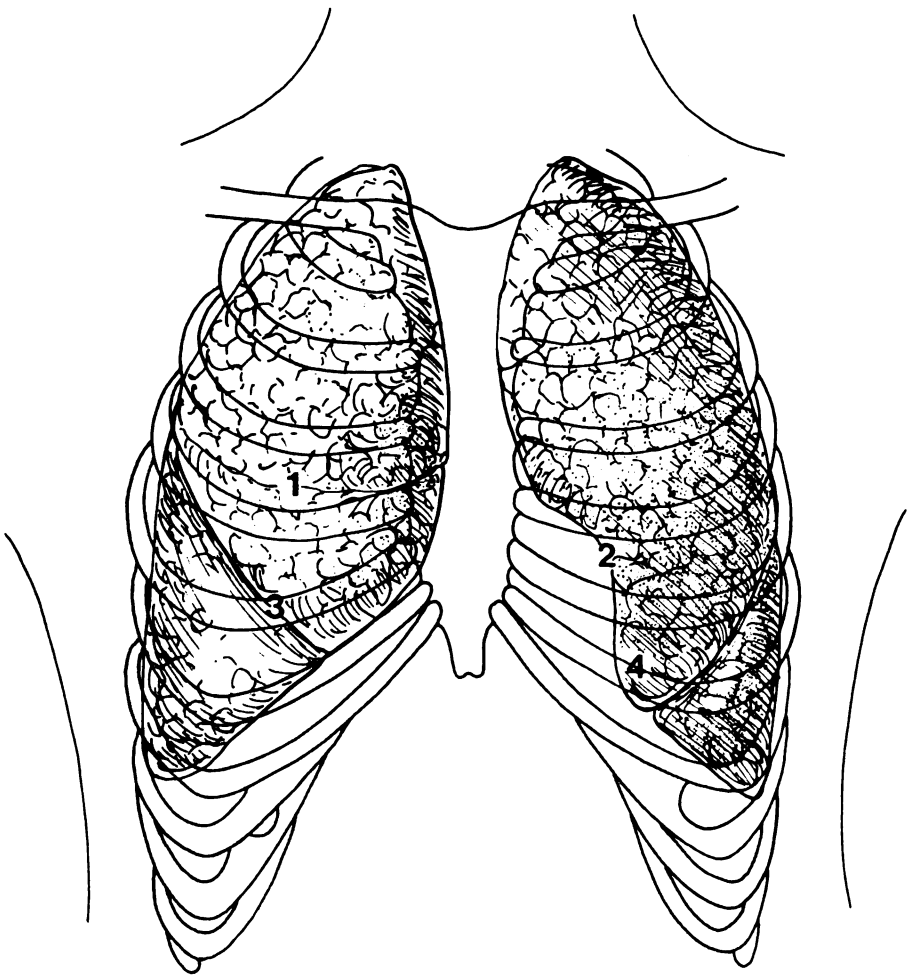

Fig. 6
1 Horizontal fissure
2 Cardiac notch
3 Oblique fissure
4 Lingula

Fig. 7
5 Oblique fissure
6 Horizontal fissure

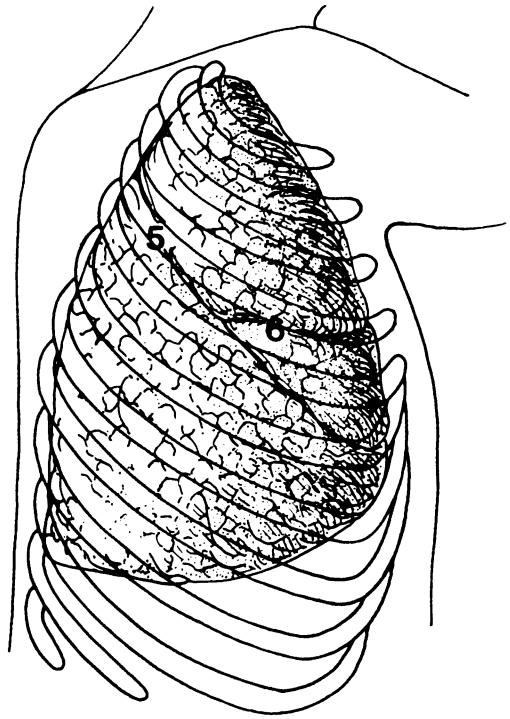

Note the lungs are divided into upper and lower lobes by the oblique fissure. The oblique fissure begins posteriorly at approximately the 3rd thoracic vertebra and courses around the thoracic cage laterally to cross the 5th rib in the midaxillary tissue and ending anteriorly at the 6th costal cartilage.

In addition, the upper lobe right lung is further subdivided into a wedge-shaped middle lobe by the horizontal fissure beginning at the 4th rib anteriorly and 5th rib in the midaxillary line. The lingula of the left lung corresponds to the middle lobe of the right lung.

Identify the cardiac notch of the left lung.

(GA: 1-20, 1-26)

4 PERICARDIUM

a. Before opening the pericardium, note its superior extent and inferior attachment to the diaphragm. Open the pericardium with the cruciate cut anteriorly and reflect the four flaps. Note the inner serous lining and observe how this is reflected onto the heart as visceral pericardium. The parietal layer of the serous membrane lines the inside of the fibrous pericardium.

b. Identify the following portions of the heart and its chambers and major vessels in situ.
–right atrium and auricle
–superior vena cava and inferior vena cava
–sulcus terminalis
–right ventricle
–pulmonary trunk
–left atrium
–pulmonary veins
–left ventricle
–ascending aorta

c. Which chamber of the heart forms the anterior surface of the heart? The apex? The right border? The posterior surface?

d. Cut the inferior vena cava, the pulmonary veins, and the superior vena cava at their entrances into the pericardium. Cut the aorta and pulmonary trunk ½ - 1 inch above their origin and remove the heart from the pericardial sac.

(GA: 1-23, 1-53, 1-61)

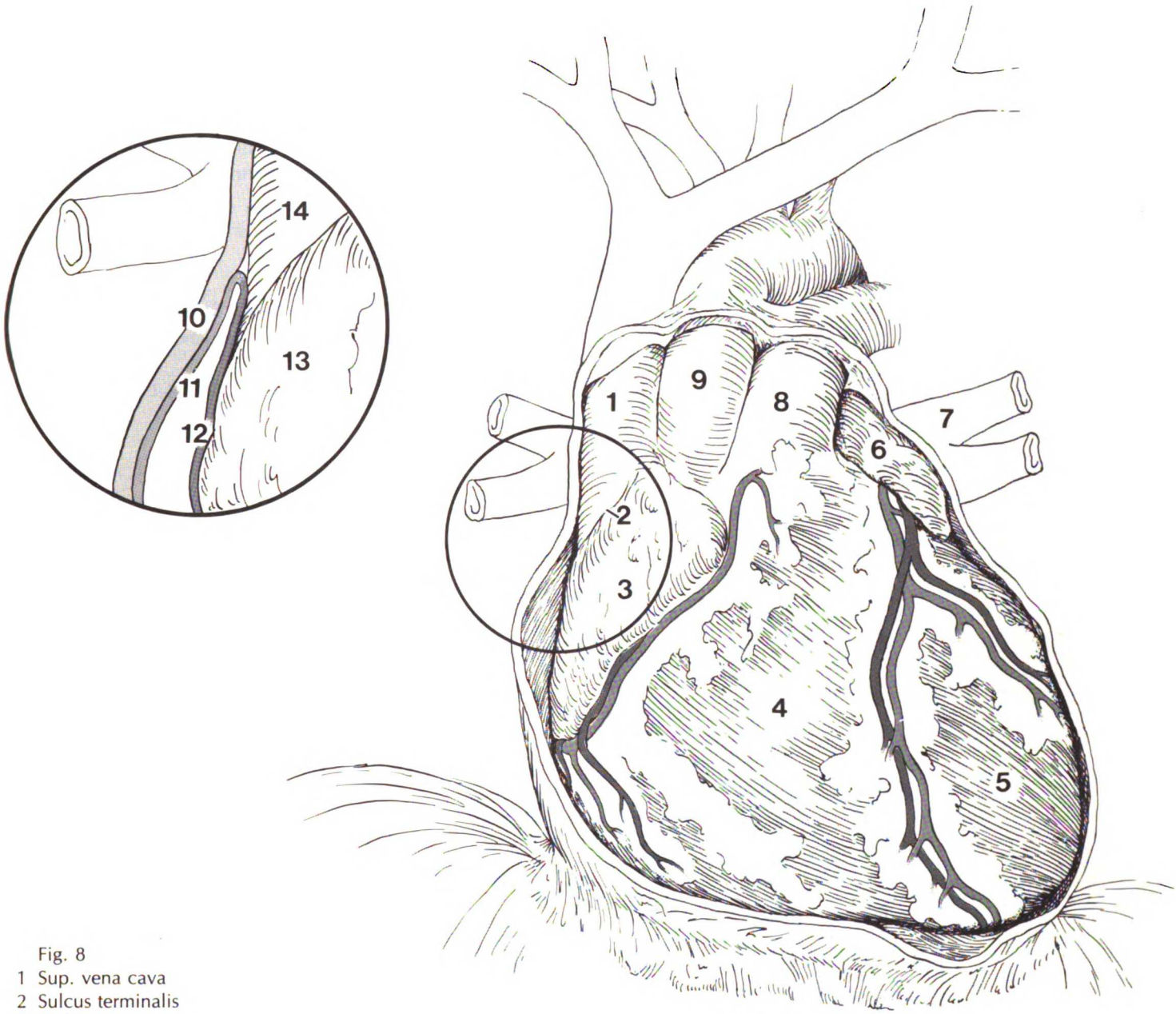

Fig. 8

1 Sup. vena cava
2 Sulcus terminalis
3 Right atrium
4 Right ventricle
5 Left ventricle
6 Left atrium/auricle
7 Pulmonary veins
8 Pulmonary trunk
9 Ascending aorta
10 Fibrous pericardium
11 Parietal serous pericardium
12 Visceral serous pericardium
13 Heart/right atrium
14 Sup. vena cava

5 CORONARY VESSELS

a. Identify and dissect the coronary vessels
Left coronary artery:
–circumflex branch
–anterior descending interventricular branch
Right coronary artery:
–marginal branch
–posterior interventricular branch

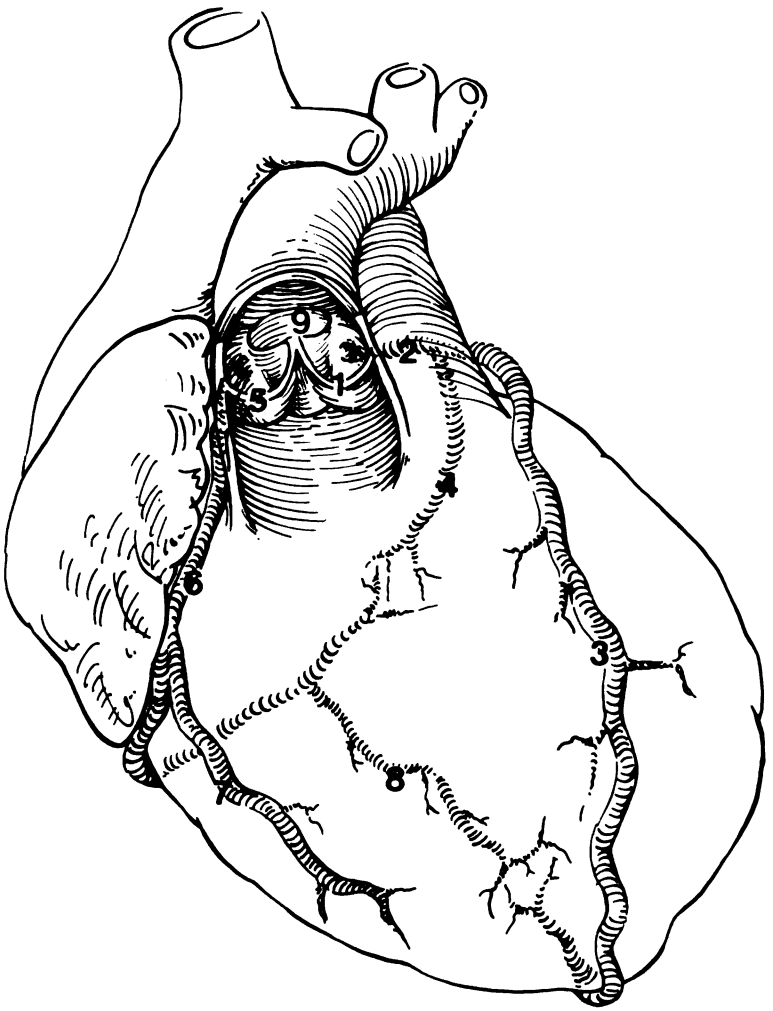

Fig. 9
1 Left aortic cusp
2 Left coronary a.
3 Ant. descending interventricular br.
4 Circumflex br.
5 Right aortic cusp
6 Right coronary a.
7 Marginal br.
8 Post. descending interventricular br.
9 Aortic sinus

Coronary sinus:
–great cardiac vein accompanying the anterior interventricular artery
–middle cardiac vein running with the posterior interventricular artery
–small cardiac vein running with the marginal branch of the right coronary artery

d. Incise the aorta and note the origin of the coronary arteries behind the cusps of the aortic valves. This region is the aortic sinus.

(GA: 1-57, 1-58, 1-53, 1-70)

Fig. 10
1 Right atrium
2 Coronary sinus
3 Great cardiac v.
4 Middle cardiac v.
5 Small cardiac v.

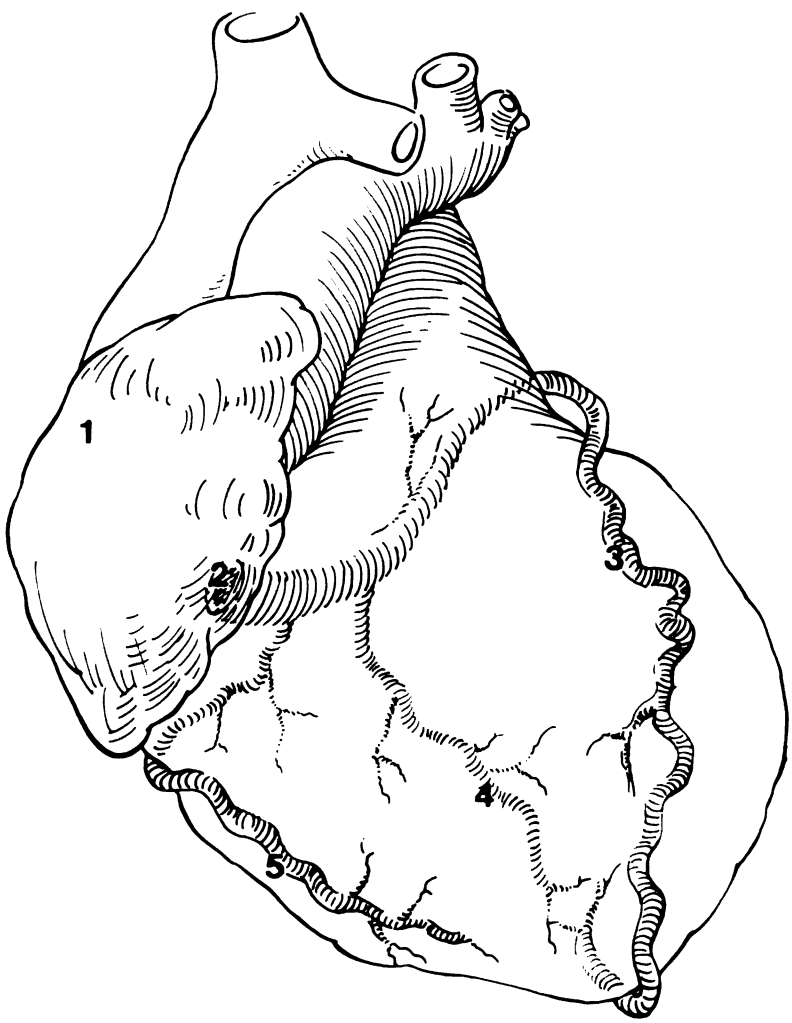

6 CHAMBERS OF THE HEART

a. Open the heart by making a vertical incision through the superior vena cava to the inferior vena cava. Stay lateral to avoid crista terminalis. Make a horizontal incision from the vertical incision to the tip of the right ventricle that passes through the atrioventricular foramen.

Fig. 11 Right atrium and ventricle
1 Sup. vena cava
2 Inf. vena cava
3 Aorta
4 Auricle
5 Crista terminalis
6 Fossa ovalis
7 Coronary sinus
8 Pulmonary trunk
9 Tricuspid valve
10 Interventricular septum
11 Moderator band
12 Ant. papillary m.

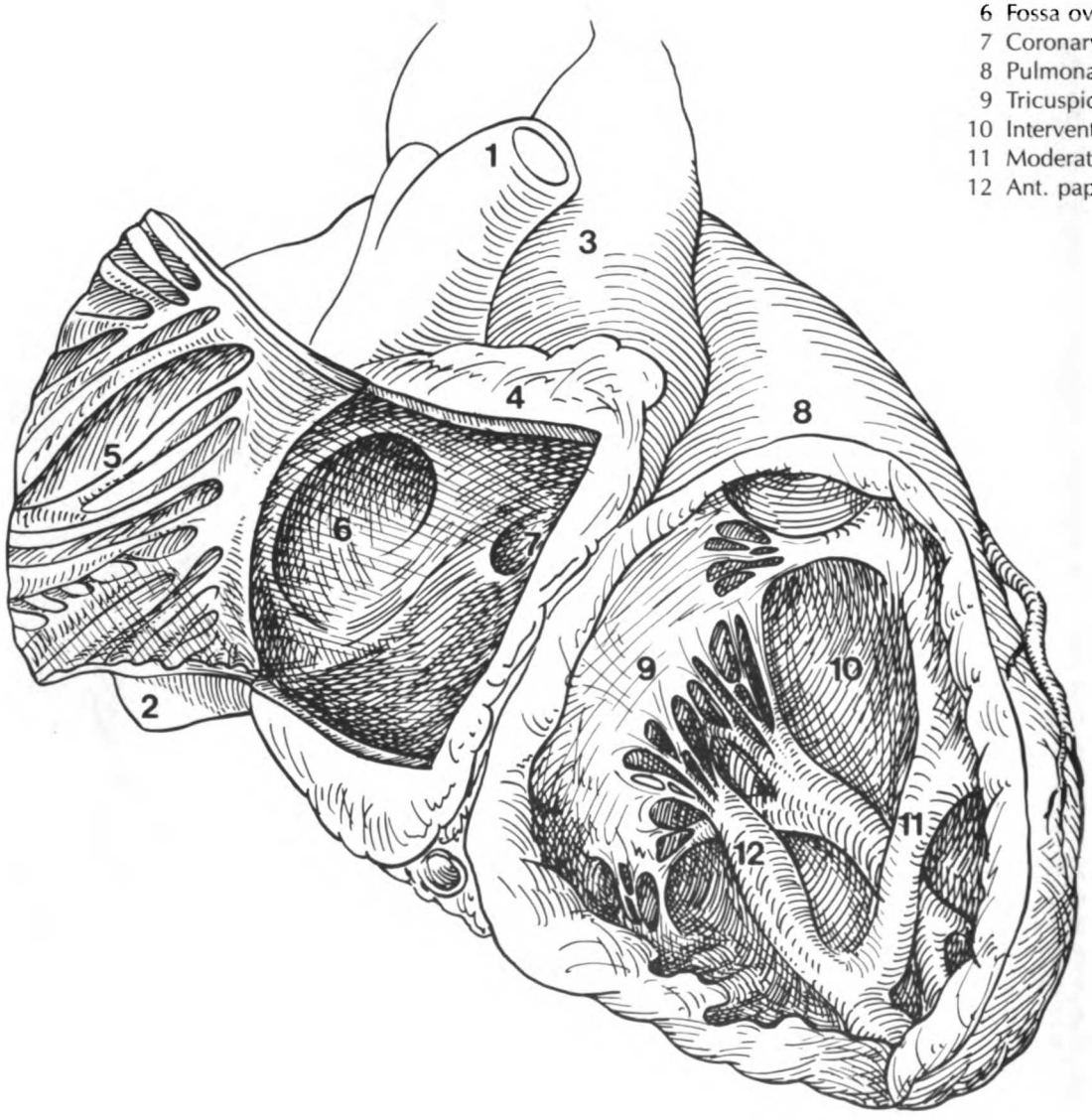

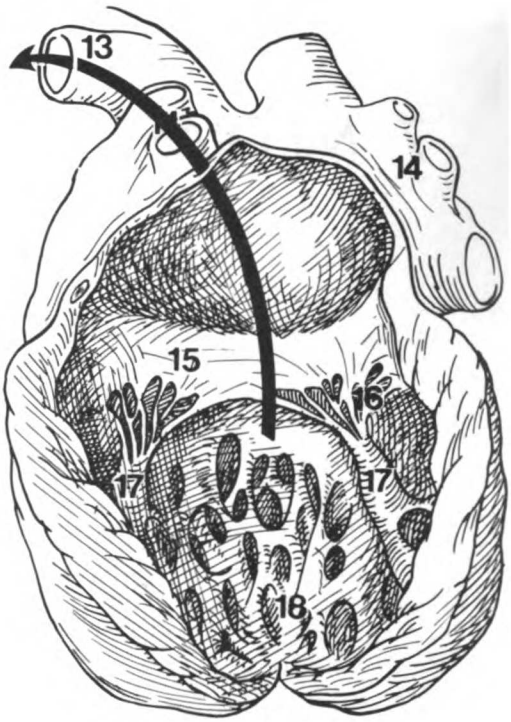

b. On the posterior surface of the heart make a vertical incision, passing between the right and left pulmonary veins of the left atrium to the tip of the left ventricle.

c. Wash out the interior of the heart over the strainers in the steel sinks.

d. In the right atrium note the auricle, the crista terminalis, the valves of the coronary sinus and inferior vena cava, and the fossa ovalis.

e. In the right ventricle and the left ventricle note the trabeculae carnae, papillary muscles, chordae tendinae, the interventricular septum, and the moderator band (septomarginal trabecula).

f. In the left atrium note the openings of the pulmonary veins (how many?), the left auricle, and the fossa ovalis. What is the patent foramen ovale?

g. Note the tricuspid, pulmonary, bicuspid (mitral), and aortic valves.

h. Study the models and demonstration material of the conduction system of the heart.

i. Trace the course of a drop of blood from the superior vena cava, to the aortic arch.

(GA: 1-63, 1-64, 1-65)

Fig. 12 Left atrium and ventricle
13 Aorta
14 Pulmonary vv.
15 Bicuspid valve
16 Trabeculae carnae
17 Papillary mm.
18 Cordae tendinae

7 MEDIASTINUM

a. Remove the pleura from the mediastinal structures and study the thoracic side of the diaphragm, noting its dome-shaped structure. Note its attachments the sternum, costal, and lumbar regions.

b. Dissect the phrenic nerve and follow the nerve to the diaphragm. It arises from the roots C 3, 4 and 5 in the neck.

c. Identify the intercostal nerves at the costovertebral angles in the intercostal spaces. Dissect out the sympathetic trunk and the associated sympathetic ganglia as it courses under the pleura covering the bodies of the thoracic verterbrae.

d. Find the splanchnic nerves leaving the sympathetic ganglia (T 5 and below) and passing medially toward the diaphragm.

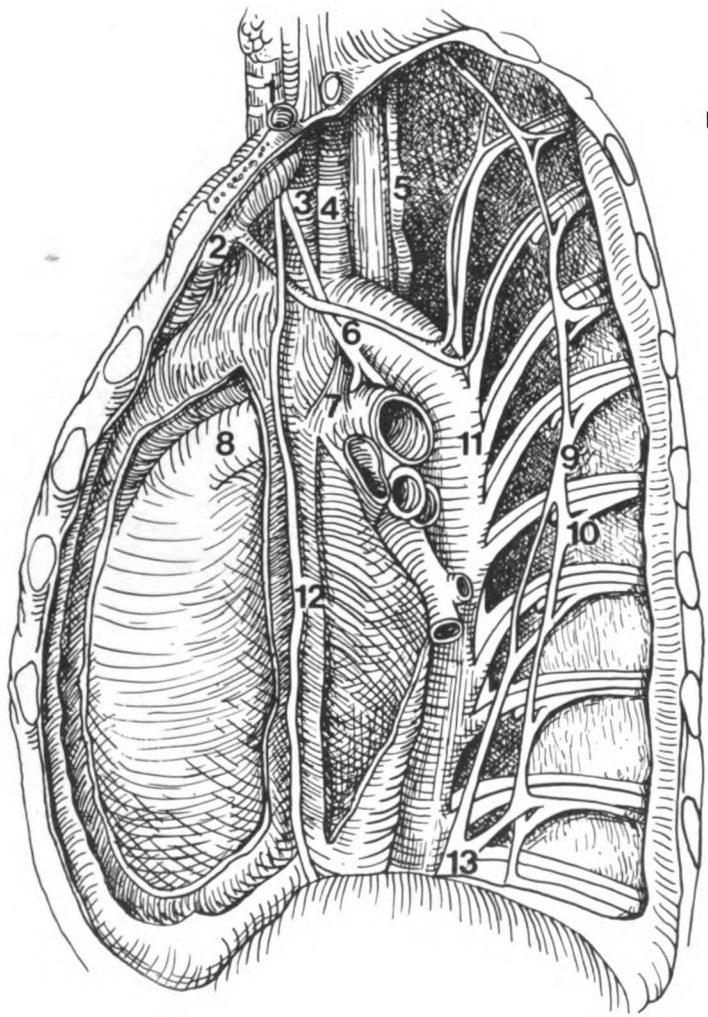

Left mediastinum

Fig. 13
1 Trachea
2 Brachiocephalic v.
3 Common carotid a.
4 Subclavian a.
5 Thoracic duct
6 Vagus n.
7 Ligamentum arteriosum
8 Pulmonary a.
9 Sympathetic trunk
10 Sympathetic ganglion
11 Aorta
12 Phrenic n.
13 Greater splanchnic n.

Fig. 14
14 Esophagus
15 Trachea
16 Right vagus n.
17 Azygos v.
18 Sup. vena cava
19 Phrenic n.

e. On the right side of the mediastinum note:
–the arched azygos vein entering the superior vena cava
–the right brachiocephalic vein, superior vena cava, and inferior vena cava
–the trachea and right main bronchus
–the vagus nerve next to the trachea coursing posteriorly behind the root of the lung to the esophagus
–look for the thoracic duct posterior to the esophagus lying between the azygos and the thoracic aorta.

f. On the left side of the mediastinum note:
-the trachea and left main bronchus
-the descending aorta and branches of the arch of the aorta: left subclavian, left common carotid, right brachiocephalic
-the left brachiocephalic, subclavian, and jugular veins
-the left vagus nerve, (beside the left common carotid artery) coursing over the aortic arch, and giving rise to the left recurrent laryngeal nerve at the level of the liagmentum arteriosum
-follow the vagus nerves to the esophagus
-identify the hemiazygos veins

g. Incise the pericardial sac posteriorly and note the esophagus; the latter lies immediately posterior to the left atrium of the heart. Follow the vagal fibers onto the esophagus. The left vagus passes anterior and the right vagus passes posterior to the esophagus forming the anterior and posterior vagal trunks.

h. Complete the dissection of the greater splanchnic nerves. Trace them to the diaphragm, which they pierce. Review the type of nerve fibers they contain.

(GA: 9-3, 9-1, 9-4, 9-15, 9-32, 9-36, 9-6, 9-7, 9-38, 9-10, 9-2)

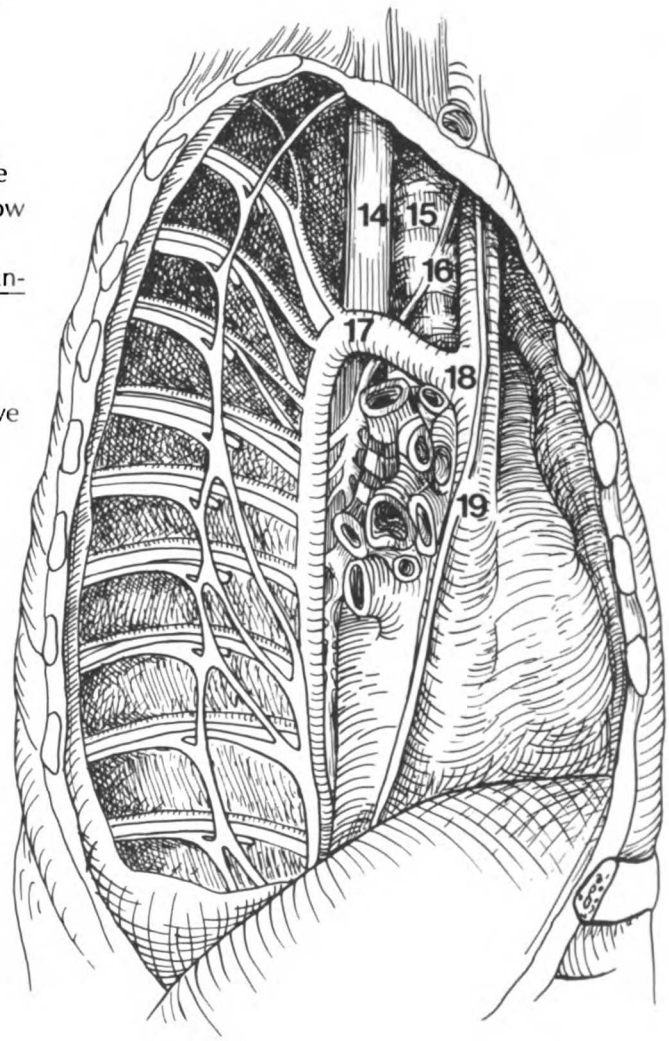

Right mediastinum

THORAX REVIEW

1 Diagram a typical spinal nerve, illustrating the origins of its component fibers and its distribution to the body wall.

2 Diagram the arterial and venous supply of one intercostal space.

3 Describe the mechanism whereby intercostal muscles and diaphragm change the dimensions of the thoracic space during respiration.

4 Name the branches of the ascending and descending aortae and the arch of the aorta.

5 What is the origin of the internal thoracic artery? What do the anterior perforating branches supply?

6 Understand the double-walled nature of the pleural sac, one of the serous cavities of the thorax.

7 What are the surface projection and landmarks of the heart (base, apex, margins) in the living; what portion of the outline are formed by the various chambers?

8 Understand the organization of the heart: the thickness of its walls, chambers, cavities, and valves, and the location of entering and exiting vessels.

9 Trace the course of a drop of blood from the superior vena cava to the aortic arch.

10 Diagram the typical distribution of the coronary arteries and cardiac veins. When is blood flow maximal through the coronary arteries?

11 What are the functions of the cardiac skeleton?

12 What are the components and the approximate sites of the cardiac plexus and the cardiac conduction system?

13 What are the sources of the sensory and motor innervation of the heart?

14 Define: fossa ovalis, ligamentum arteriosum. What are the functions of their embryological precursors?

15 Review the location and principal branches of the great vessels of the thorax (aorta, superior vena cava, azygos vein system); locate and review the following important structures which course through the thorax: esophagus, phrenic nerve, vagus nerve, and thoracic duct.

16 Understand the main components of the autonomic nervous system (sympathetic or thoraco-lumbar and parasympathetic or craniosacral division).

17 State the location of the preganglionic cell bodies for both the sympathetic and parasympathetic nervous systems.
State the location of the preganglionic cell bodies for both the sympathetic and parasympathetic nervous systems.

18 Classify the type of nerve fibers in the:
–Ventral root
–Dorsal ramus
–Grey rami communicantes
–Greater splanchnic nerve

ABDOMEN

8 ABDOMINAL WALL AND INGUINAL REGION

a. Make a midline incision from the xiphoid process to the symphysis pubis passing around both sides of the umbilicus. Make incisions from the xiphoid process passing laterally, curving around the costal margins. Make curved incisions from each anterior superior iliac spine passing downward, curving medially, below the inguinal ligament, to the symphysis pubis. Reflect the skin.

b. Identify the inguinal ligament and the superficial inguinal ring (specializations of the external oblique muscle layer).

c. Note the direction of the muscle fibers of each of the muscles of the anterior abdominal wall: external oblique, internal oblique, and transversus abdominis.

d. Open the sheath of the rectus abdominis muscle by a vertical incision beginning at the upper end of each muscle, one inch from the median plane, to 3 inches above the symphysis pubis. By sharp dissection, separate the anterior layer of the sheath from the tendinous inscriptions. Reflect the muscle inferiorly by cutting it from the costal margins. Note the superior epigastric artery (a branch from the internal thoracic artery).

e. Again identify the superficial inguinal ring and note it contains the spermatic cord in the male (round ligament of the uterus in the female). Their coverings are derived from the muscles and fascia of the anterior abdominal wall.

f. The contents of the inguinal canal are best studied in the male cadaver. Note how the ductus deferens and testicular artery pass upward into the abdominal cavity. They derive a thin coating from each muscle that they traverse in the inguinal canal. The fascial layers are respectively from superficial to deep: the external spermatic fascia, the cremasteric fascia and the internal spermatic fascia.

g. The abdominal entrance to the inguinal canal is the internal (or deep) inguinal ring (specialization of the transversalis fascia).

h. Note that the internal ring lies lateral to the inferior epigastric artery.

(GA: 2-6, 2-8, 2-9, 2-11, 2-13, 2-14, 2-15, 2-22)

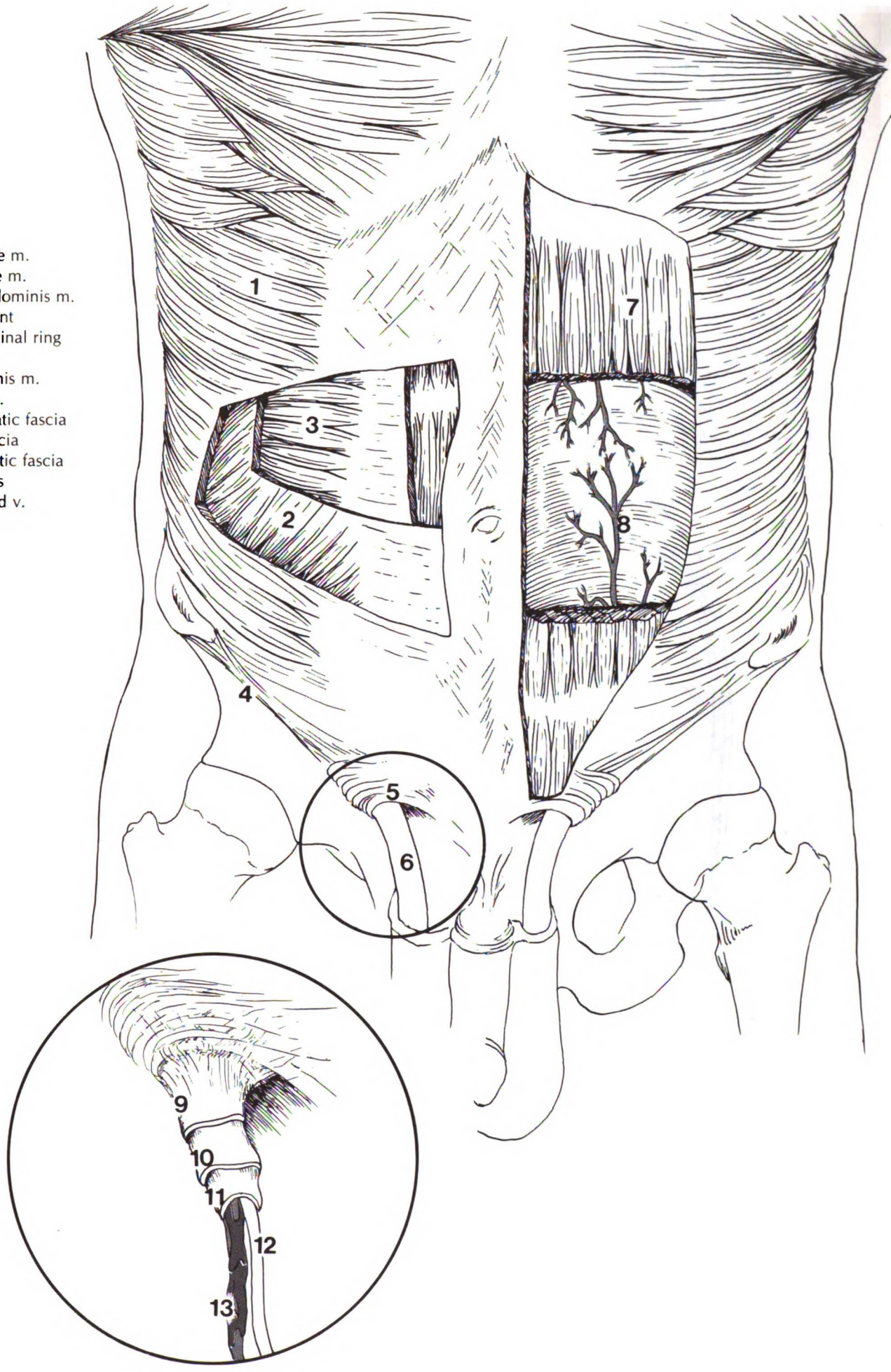

Fig. 15
1 External oblique m.
2 Internal oblique m.
3 Transversus abdominis m.
4 Inguinal ligament
5 Superficial inguinal ring
6 Spermatic cord
7 Rectus abdominis m.
8 Inf. epigastric a.
9 External spermatic fascia
10 Cremasteric fascia
11 Internal spermatic fascia
12 Ductus deferens
13 Testicular a. and v.

9 ABDOMINAL VISCERA AND RELATIONSHIPS

a. Before you begin your dissection of the abdomen, consult your atlas in order to locate and identify the anatomical structures that can be identified without dissection once the anterior abdominal wall has been opened.

b. Identify the falciform ligament and the round ligament of the liver; follow both of these structures to the liver.



Fig. 16
1 Diaphragm
2 Liver
3 Falciform ligament
4 Round ligament
5 Gall bladder
6 Lesser omentum
7 Epiploic foramen of Winslow
8 Stomach
9 Spleen
10 Greater omentum
11 Ascending colon
12 Descending colon
13 Paracolic grooves

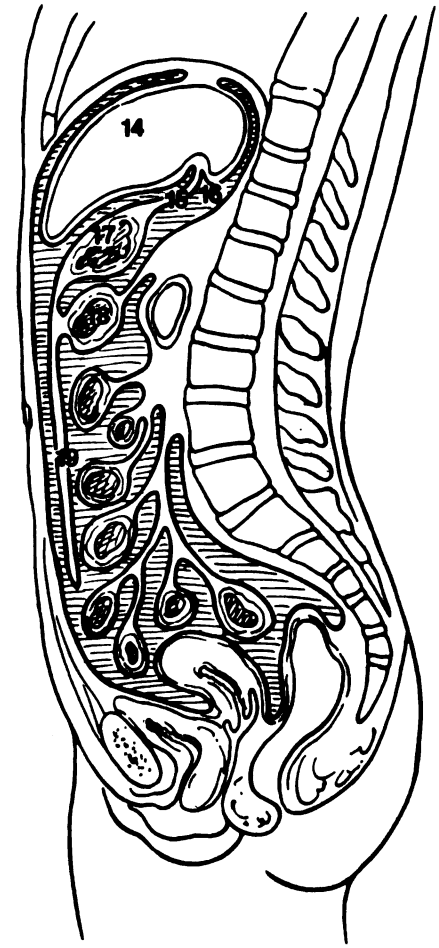

c. Identify the diaphragm, liver, gall bladder, stomach, greater omentum, lesser omentum, spleen, small intestine, mesentery of the small intestine, cecum, appendix, ascending, transverse and descending colons, sigmoid colon, and urinary bladder.

d. Identify the right free edge of the lesser omentum. Insert the index finger through the epiploic foramen of Winslow into the lesser sac. As you palpate the free edge of the lesser omentum remember that portal vein, hepatic artery, and bile duct lie within it. Make an incision in the lesser omentum and identify the inferior vena cava and the aorta.

e. Lift the greater omentum and note the paracolic grooves lateral to the ascending and descending colon.

(GA: 2-26, 2-27, 2-28, 2-30, 2-31, 2-32)

Fig. 17
14 Liver
15 Lesser omentum
16 Lesser sac
17 Stomach
18 Transverse colon
19 Greater omentum

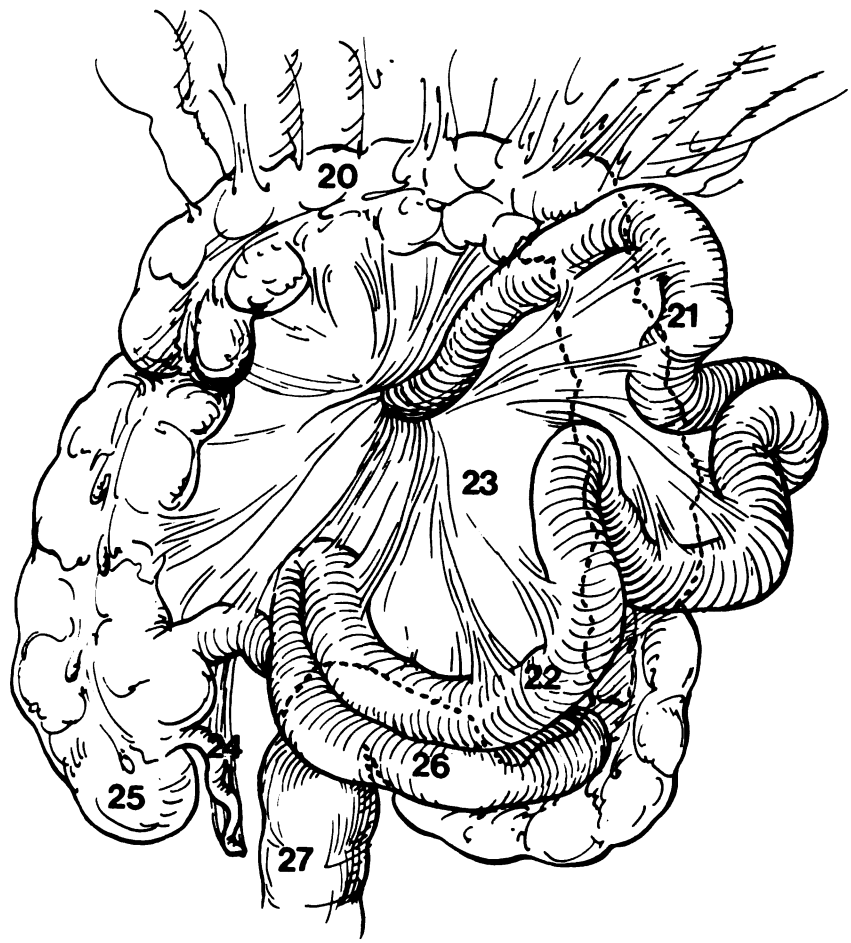

Fig. 18 Greater omentum reflected superiorly
20 Transverse colon
21 Jejunum
22 Ileum
23 Mesentery of small intestine
24 appendix
25 cecum
26 sigmoid colon
27 rectum

10 BLOOD SUPPLY OF THE INTESTINE

a. Study the mesentery of the small intestine and dissect the superior mesenteric artery in the mesentery and note the accompanying veins.

b. Reflect the mesentery and small bowel upward. Use your atlas to locate the inferior mesenteric artery. In order to accomplish this you will have to clean the fat and fascia away from the abdominal aorta. Begin at the bifurcation of the aorta into common iliac arteries and work superiorly until you locate the point where the inferior mesenteric artery arises from the aorta to travel inferiorly and to the left. Notice that the inferior mesenteric vein does not drain into the inferior vena cava. Instead it eventually drains into the portal vein.

(GA: 2-49, 2-50, 2-45)

Fig. 19
1 Sup. mesenteric a.
2 Colic a.
3 Mid. colic a.
4 Ilio-colic a.
5 Appendicular a.
6 Inf. mesenteric a.
7 Left colic a.
8 Sigmoidal a.
9 Sup. rectal a.


1
2
3
4
5
6
7
8
9

11 REMOVAL OF THE INTESTINE

Tie two ligatures around the small intestine beyond the duodenojejunal flexure and two ligatures around the distal portion of the sigmoid colon. Cut BETWEEN each pair of ligatures. Remove the intestine by cutting mesentery and contained vessels where they attach to the intestinal wall. Elevate the cecum, cut the peritoneum and vessels, and free the cecum and ascending colon. Cut the transverse mesocolon and free the descending and sigmoid colon from the posterior abdominal and pelvic walls. Remove the intestine and store it in a plastic bag.

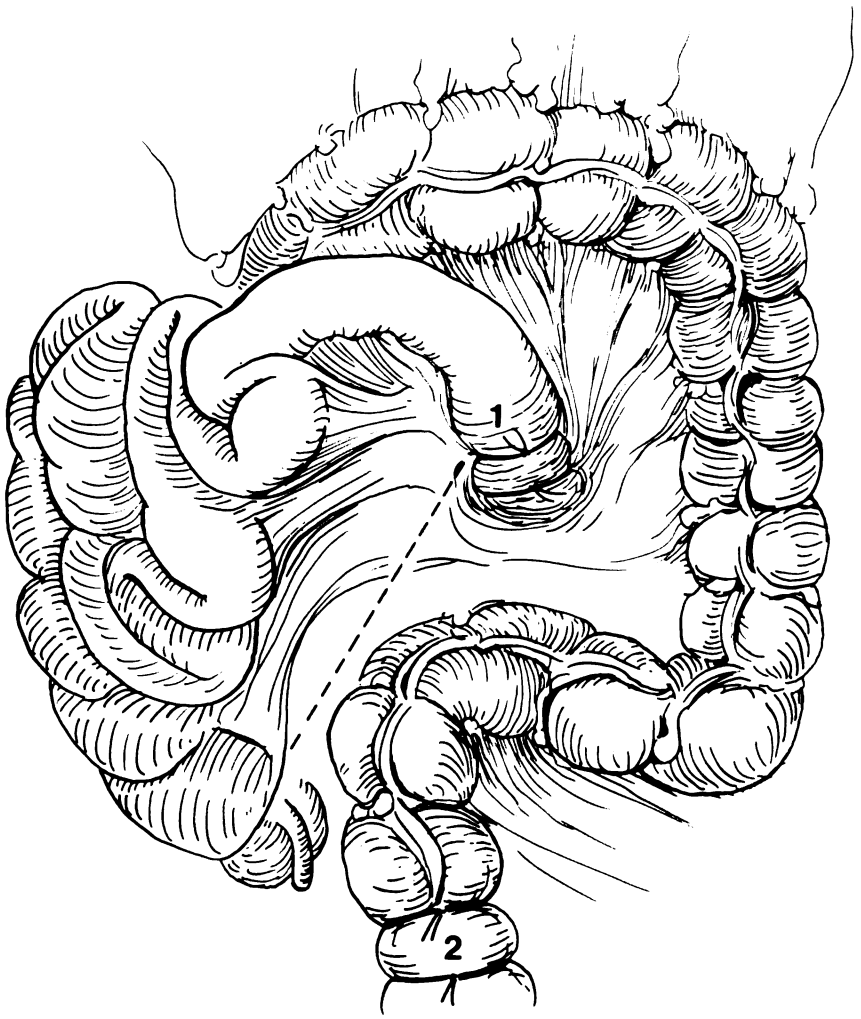

Fig. 20
1 Duodenojejunal flexure
2 Distal sigmoid colon

Fig. 21
3 Ascending colon
4 Transverse mesocolon
5 Descending colon

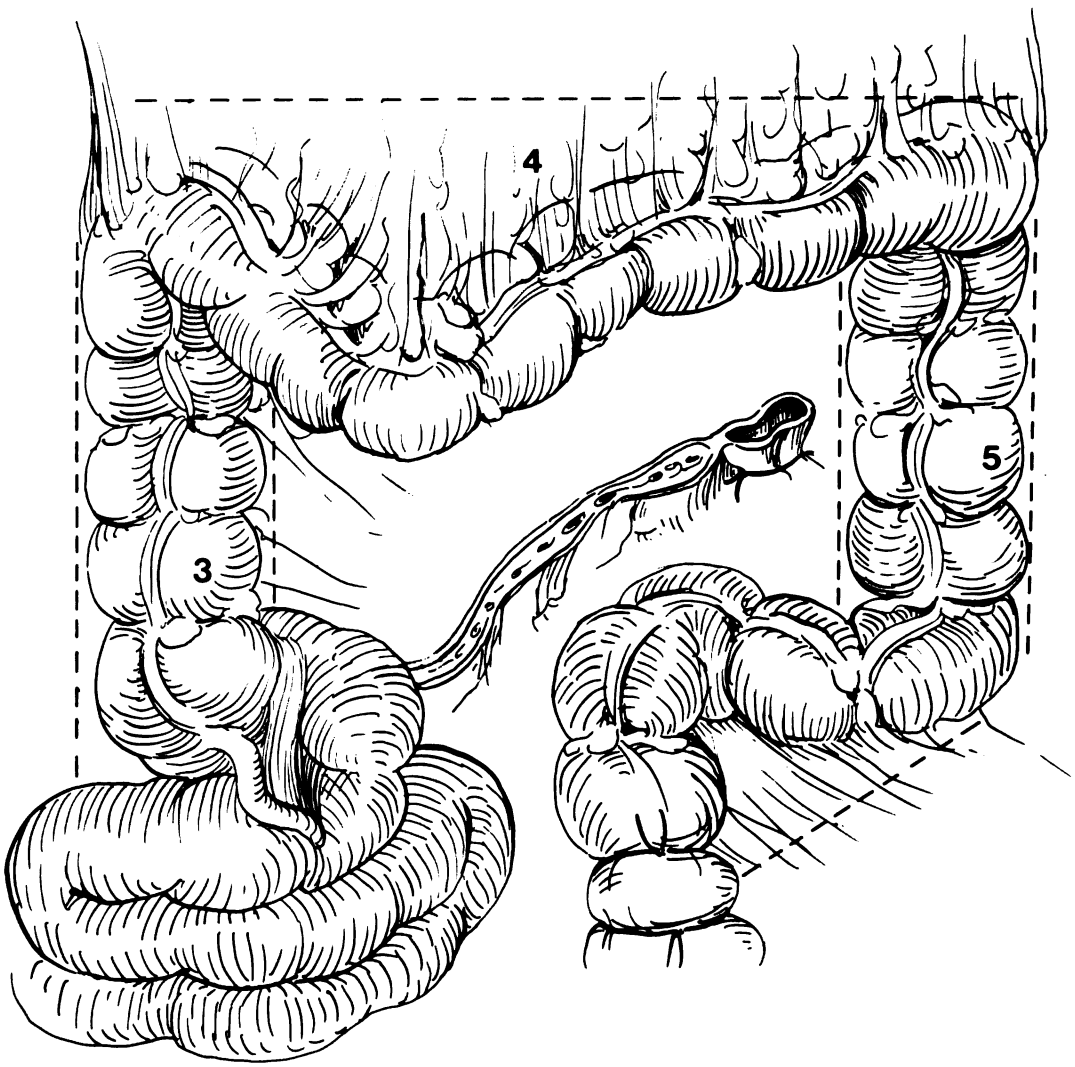
4
5
3

12 PORTA HEPATIS AND DUODENUM

a. Dissect the bile duct, the hepatic artery, and the portal vein in the free edge of the lesser omentum.

b. Dissect the hepatic artery proper, and trace it to the celiac trunk.

c. Dissect the splenic artery, another branch of the celiac trunk. It may be necessary to dissect the splenic artery from the pancreas.

d. Dissect the left gastric artery and vein on the lesser curvature of the stomach; remove as much of the left lobe of the liver as necessary to follow the artery to its origin from the celiac trunk.

e. Identify the vagal trunks on the esophagus and review their continuity with the vagus nerve of the thorax.

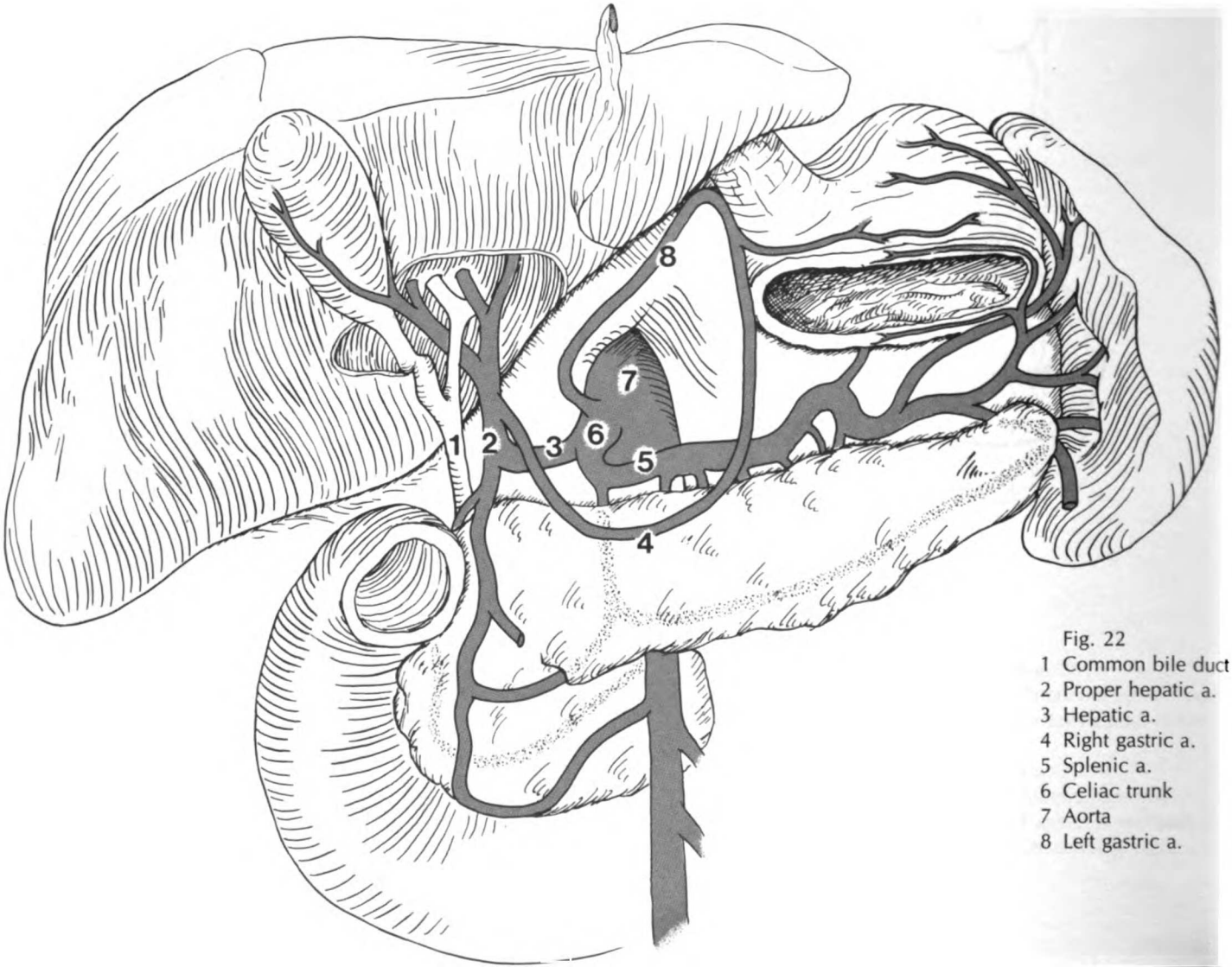

Fig. 22
1 Common bile duct
2 Proper hepatic a.
3 Hepatic a.
4 Right gastric a.
5 Splenic a.
6 Celiac trunk
7 Aorta
8 Left gastric a.

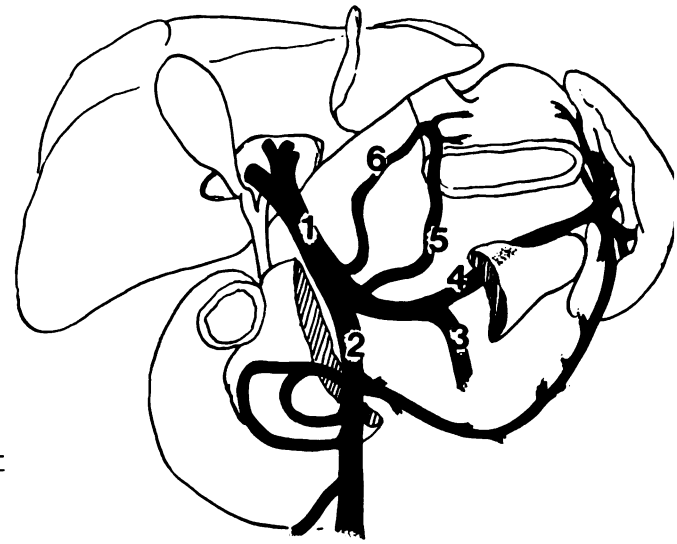

f. Cut the transverse mesocolon and identify the parts of the pancreas. (The arterial supply of the duodenum and pancreas is derived from both the celiac and superior mesenteric arteries.)

g. Identify the portal vein, and locate its tributaries: the superior mesenteric, inferior mesenteric, and splenic veins. What do these veins drain?

h. Open the second part of the duodenum anteriorly by a vertical cut. Identify the duodenal papilla. This marks the place where the bile duct (from the gall bladder and liver) and the pancreatic duct empty their contents into the duodenum.

i. Extend the incision in the descending part of the duodenum throughout the length of the duodenum and study the mucosal surface with particular reference to the presence of circular folds, plicae circulares.

j. Open the stomach anteriorly by a vertical incision and compare its lining with that of the duodenum. Note the rugae or mucosal folds run vertically.

(GA: 2-78, 2-44, 2-47, 2-88, 2-70, 2-93)

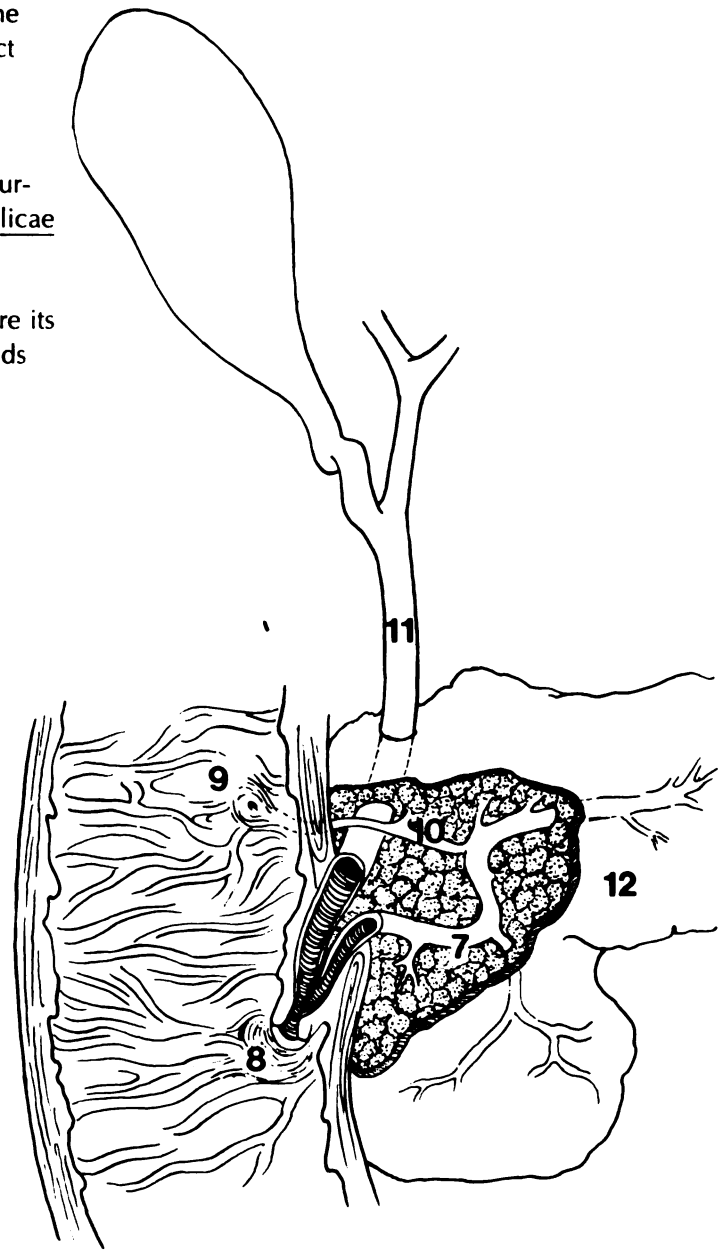

Fig. 23
1 Portal v.
2 Sup. mesenteric v.
3 Inf. mesenteric v.
4 Splenic v.
5 Right gastric v.
6 Left gastric v.

Fig. 24
7 Pancreatic duct
8 Duodenal major papilla
9 Duodenal minor papilla
10 Accessory pancreatic duct
11 Common bile duct
12 Pancreas

13 LIVER

Remove the liver by cutting its peritoneal reflections which attach the liver to the anterior abdominal wall and the diaphragm. This means that you will cut through the falciform, coronary and triangular ligaments of the liver. Consult your atlas to guide you in making these cuts. You will also have to cut the inferior vena cava twice, once at the point where it passes between the diaphragm and liver and again below the liver. Cut the portal vein, hepatic artery, and bile duct in the free edge of the lesser omentum. Study the liver. Remove whatever amount of the liver is necessary to see the hepatic veins entering the inferior vena cava.

(GA: 2-66, 2-61)

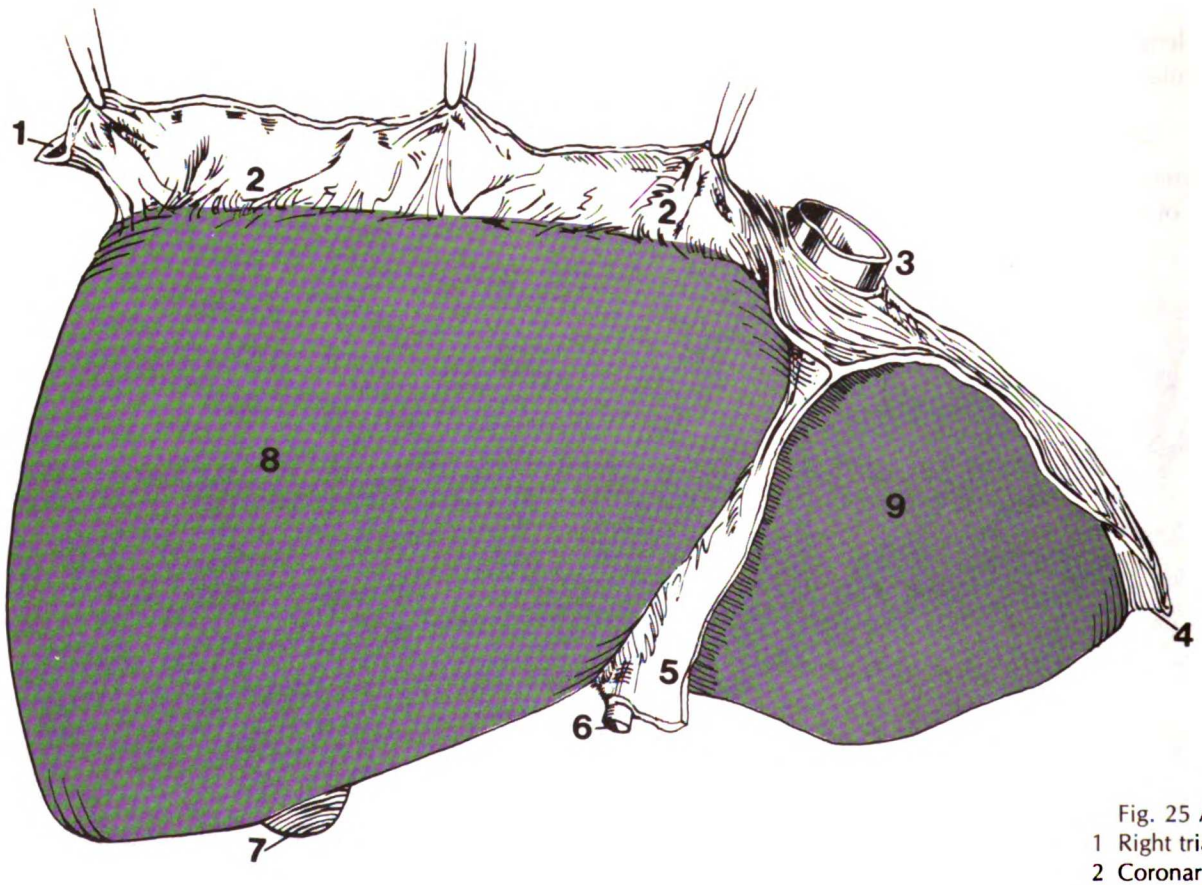

Fig. 25 Anterior view
1 Right triangular ligament
2 Coronary ligament
3 Inferior vena cava
4 Left triangular ligament
5 Falciform ligament
6 Ligamentum teres
7 Gall bladder
8 Right lobe
9 Left lobe

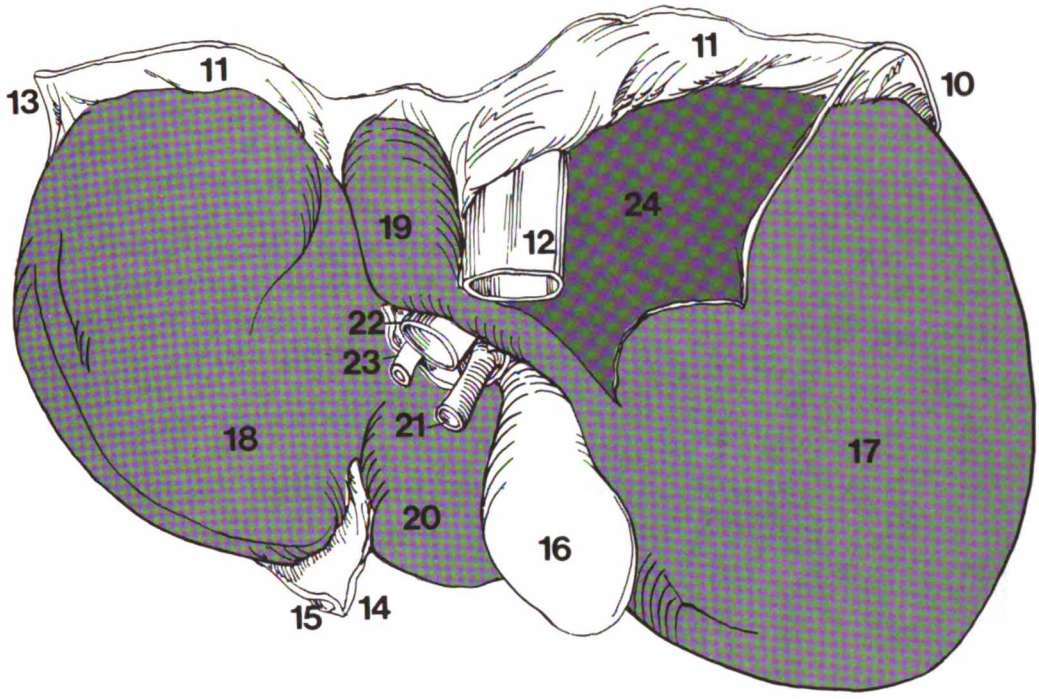

Fig. 26

10 Right triangular ligament
11 Coronary ligament
12 Inferior vena cava
13 Left triangular ligament
14 Falciform ligament
15 Ligamentum teres
16 Gall bladder
17 Right lobe
18 Left lobe
19 Caudate lobe
10 Quadrate lobe
21 Common bile duct
22 Hepatic portal v.
23 Hepatic a.
24 Bare area

14 KIDNEYS AND SUPRARENAL GLANDS

a. Identify the gonadal (testicular or ovarian) arteries and trace them back to their origins from the aorta. Locate the corresponding veins and determine which veins they drain into.

b. Dissect the suprarenal (adrenal) glands by removing the upward extension of the renal fascia that envelopes the adrenal gland and section the gland. If well preserved, you should be able to distinguish between the cortex and medulla.

c. Dissect the renal arteries and veins.

d. Note the relationships of the superior mesenteric artery to the left renal vein.

e. Trace the ureter to the pelvic brim.

f. Open one kidney by longitudinal section and study the renal pyramids, columns, pelvis, and major and minor calyces.

g. Study the aorta, esophagus, inferior vena cava, with particular reference to the arrangement of their openings into the diaphragm.

(GA: 2-99, 2-73, 2-101, 2-102, 2-111, 2-120)

Fig. 27

1 Hiatus of IVC
2 Hiatus of esophagus
3 Hiatus of aorta
4 Adrenal v.
5 Adrenal cortex
6 Adrenal medulla
7 Renal papillae
8 Minor calyx
9 Major calyx
10 Ureter
11 Right renal v.
12 Right renal a.
13 Left renal a.
14 Adrenal gland
15 Kidney
16 Left testicular v.
17 Left testicular a.
18 Right testicular a.
19 Right testicular v.
20 Ductus deferens
21 Inguinal canal
22 Bladder

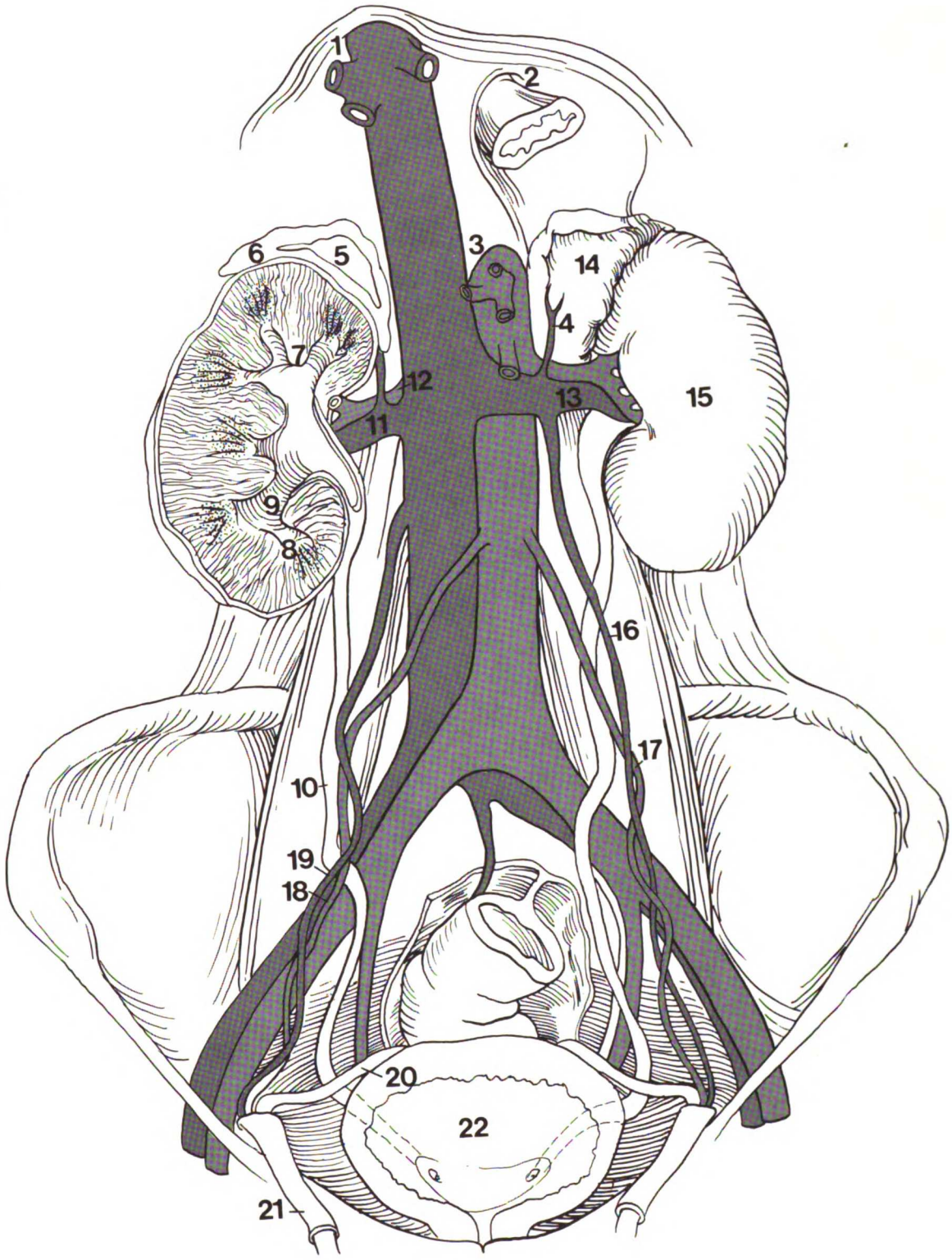

ABDOMEN REVIEW

1 Be able to list the eight layers of the anterior abdominal wall.

2 Define: inguinal ligament, superficial and deep inguinal rings, rectus sheath, tendinous inscriptions, inguinal canal, and hernia.

3 Describe the differences between a direct and indirect inguinal hernia.

4 Be able to list the coverings of the spermatic cord and state from which abdominal layer they are derived.

5 Name four structures contained within the spermatic cord.

6 Be able to draw the rectus sheath above and below the arcuate line.

7 Note the divisions of the gastro-intestinal tract:
–Stomach and its subdivisions
–Small intestine: duodenum, jejunum, and ileum
–Cecum and appendix
–Large intestine (colon): ascending, transverse, descending, and sigmoid

8 Note the mechanical support of the digestive system and associated structures, and in particular the series of membranes known as:
–Greater and lesser omentum
–Mesentery

9 Describe the blood supply, venous drainage, and innervation of the GI tract.

10 Outline the arterial supply and venous drainage of the following organs:
–Liver
–Large intestine
–Right and left testis (ovary)
–Pancreas
–Stomach
–Rectum

11 What lies in the free edge of the lesser omentum?

12 Describe the sites where portal-caval anastomoses occur. What vessels are involved? Why are those anatomoses important?

13 How are the pancreas, superior mesenteric artery, duodenum, and left renal vein related to each other?

14 Review suprarenal glands: structure, relationships (especially to kidney and celiac plexus), blood supply, and innervation.

15 Define the celiac plexus and ganglia, location and functional relationship to the autonomic innervation of the abdomen.



HEAD AND NECK

15 TRIANGLES OF THE NECK

a. Reflect the skin flaps and note the extent of the platysma muscle in the superficial fascia of the neck. The platysma is considered a muscle of facial expresssion and, therefore, innervated by the seventh cranial nerve.

b. Locate the sternocleidomastoid muscle and identify its posterior border. Identify the spinal accessory nerve in the posterior triangle of the neck. Note that the accessory nerve innervation to both the sternocleidomastoid and trapezius muscles.

c. Note that all the sensory nerves to the neck and to the lateral region of the ear and scalp emerge midpoint from the posterior border of the sternocleidomastoid muscle.

d. Anterior triangle of the neck. Reflect the sternocleidomastoid muscle upward. Identify the location of the external jugular vein. (It previously may have been cut.) Identify the common carotid artery and locate its bifurcation into internal and external branches. Identify the internal jugular vein. Attempt to locate the thoracic duct as it courses posterior to the carotid artery to empty into the junction of the internal jugular and subclavian veins.

e. Study the vagus nerve. Locate the sympathetic trunk coursing behind the carotid artery and internal jugular vein. Identify, if possible, the superior and inferior cervical ganglia of the sympathetic trunk.

f. Identify the phrenic nerve, the scalenus anterior muscle, the subclavian vein and artery.

g. Identify the following branches of the subclavian artery:
-internal thoracic artery
-vertebral artery (remember that the vertebral arteries aid the internal carotid arteries in supplying the brain)
-thyrocervical trunk (it gives rise to the transverse cervical and suprascapular arteries and the inferior thyroid artery)

Fig. 28
1 Sup. thyroid v.
2 External jugular v.
3 Clavicle
4 Right subclavian v.
5 Internal jugular v.
6 Mid. thyroid v.
7 Right common carotid a.
8 Thyroid gland
9 Thoracic duct
10 Left recurrent laryngeal n.
11 Left vagus n.
12 Sup. vena cava

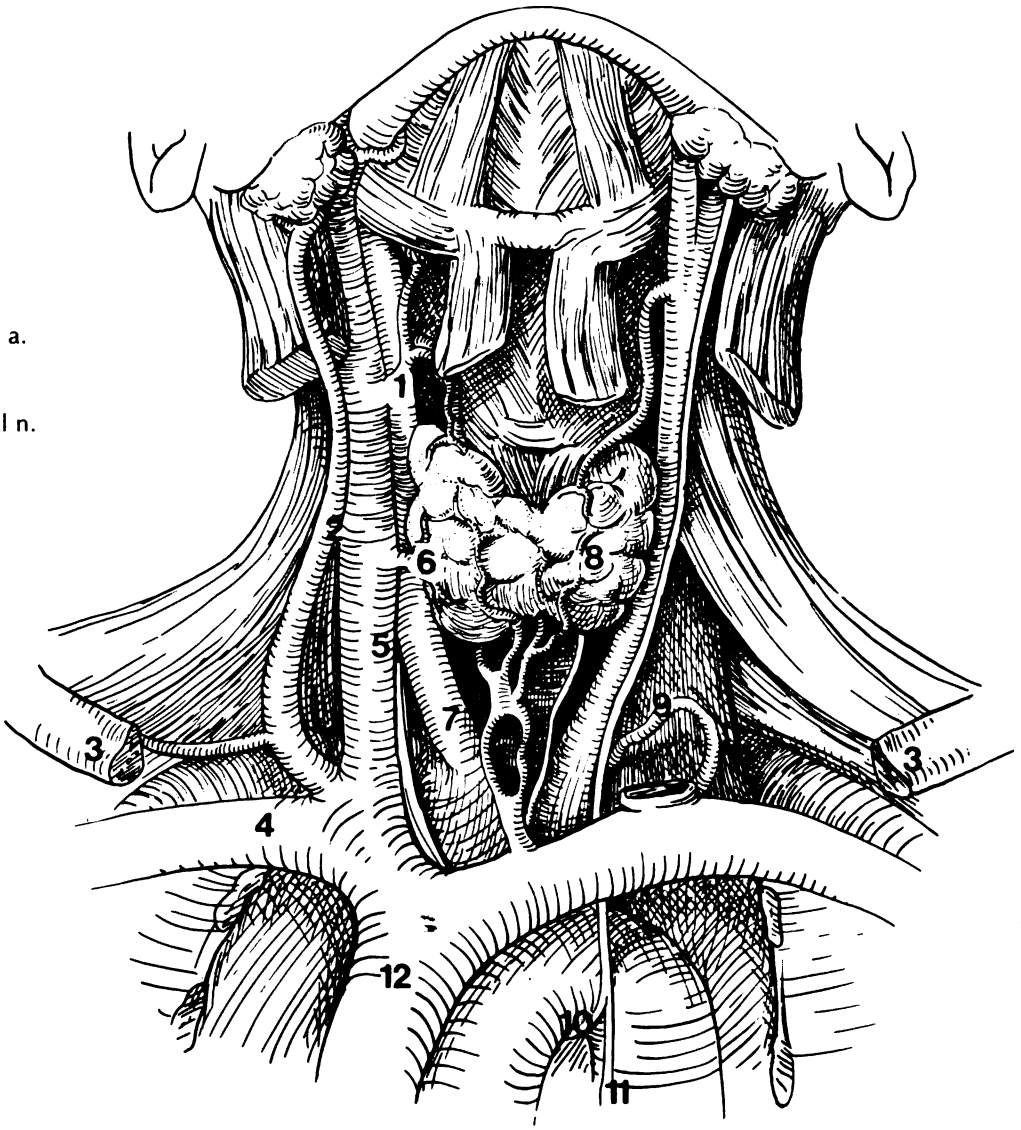

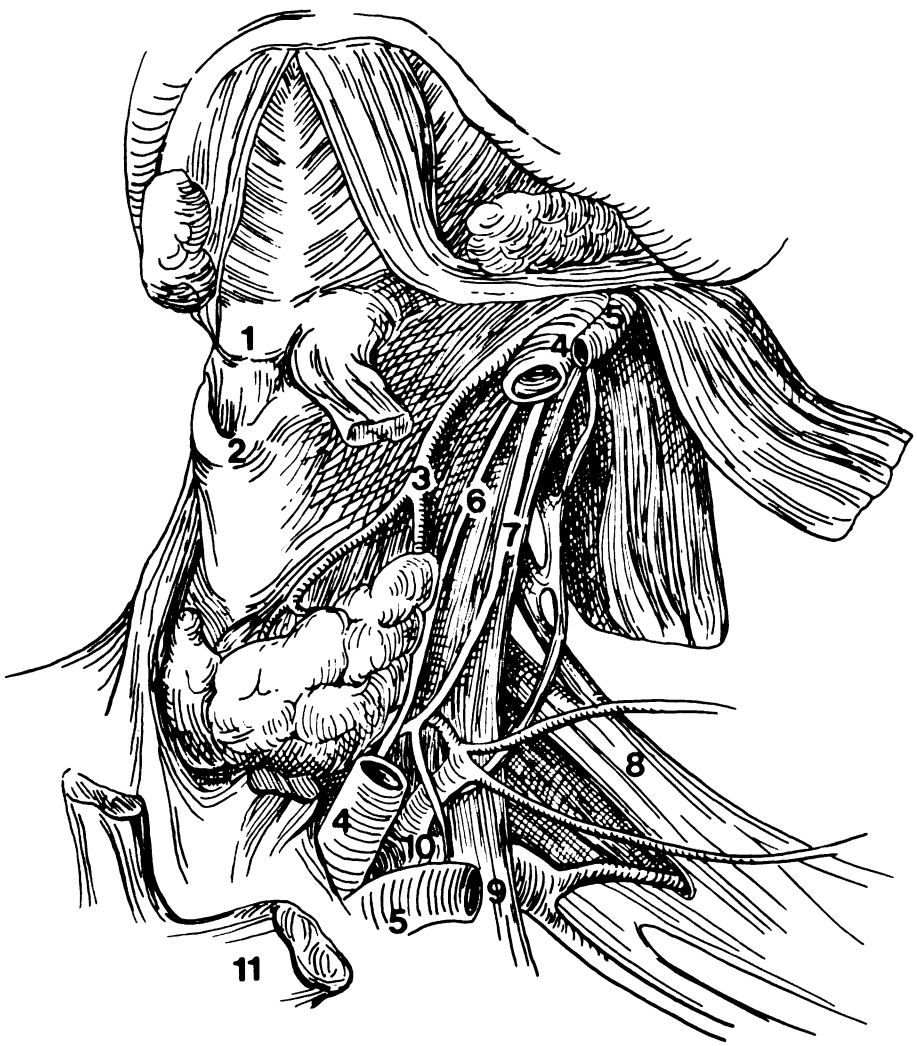

Fig. 29
1 Hyoid bone
2 Thyroid cartilage
3 Sup. thyroid a.
4 Common carotid a.
5 Internal jugular v.
6 Vagus n.
7 Sympathetic trunk
8 Brachial plexus
9 Scalenus anterior m.
10 Subclavian a.
11 Sternocleidomastoid m.
12 Inferior thyroid a.
13 Transverse cervical a.
14 Suprascapular a.
15 Thyrocervical trunk
16 Vertebral a.
17 Internal thoracic a.

Fig.30
1 Submandibular gland
2 External jugular v.
3 Sternocleidomastoid m.
4 Trapezius m.
5 Spinal accessory n.
6 Scalenus medius m.

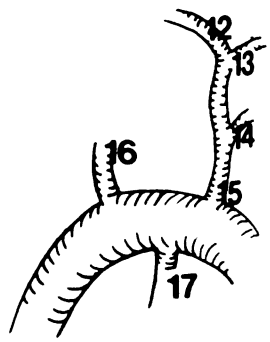

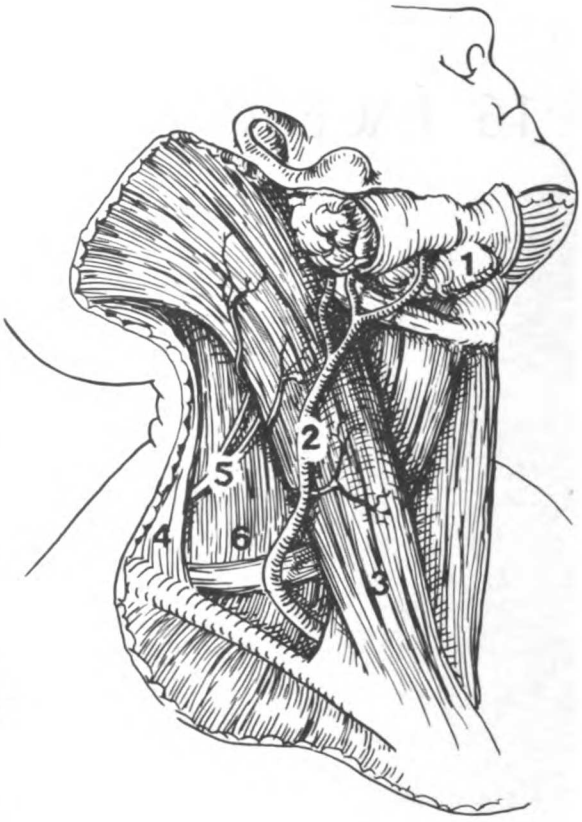

h. Begin to dissect on the brachial plexus (the brachial plexus is the rearrangement of the cervical nerves 5, 6, 7, and 8 and the first thoracic nerve). Notice that the brachial plexus lies posterior to the scalenes anterior muscle and superior to the subclavian artery.

i. In midline of the neck, identify the thyroid cartilage, cricoid cartilage,and hyoid bone.

j. Reflect the strap muscles to expose the thyroid gland.
Study its blood supply and note the relationship of the recurrent laryngeal nerve to the posterior aspect of the gland. Note also the nerve is in close relationship to the inferior thyroid artery.

k. Identify the submandibular gland. Notice on a friend that its duct opens next to the frenulum of the tongue.

(GA: 1-46, 1-47, 1-62, 1-87)

16 FACE AND PAROTID REGION

a. On the prosected material identify the parotid gland and the parotid duct on the masseter muscle. Look at the inside of a friend's cheek for the papilla by the second upper molar tooth. It represents the opening of the parotid duct.

b. The masseter muscle is one of the muscles of mastication.(The temporalis and the two pterygoid muscles are the other muscles of mastication.) On the dissected specimen and on the bony skull note how their attachments determine their function.

c. Note the facial nerve (VII) and how it branches inside the parotid gland. The facial nerve innervates all muscles of facial expression, including the buccinator muscles and the platysma.

d. Identify some of the muscles of facial expression: the orbicularis oris, orbicularis oculi, platysma, and buccinator.

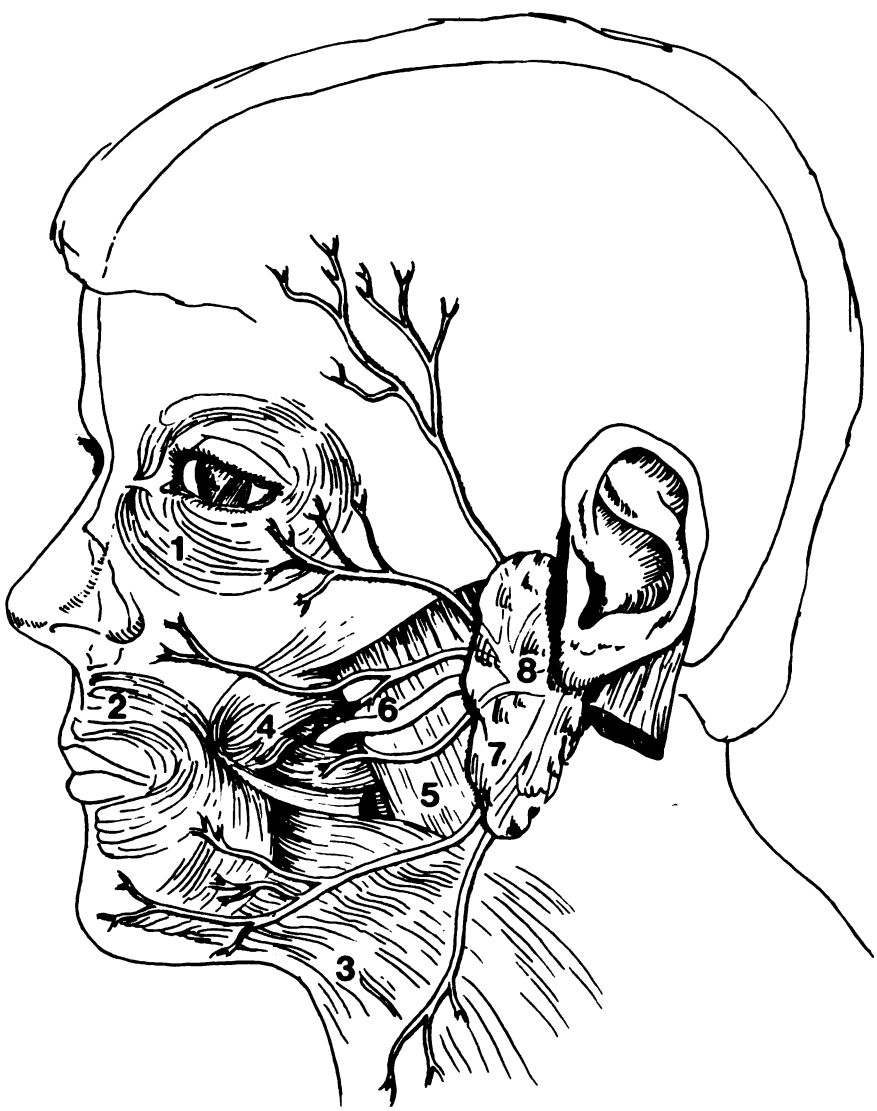

Fig. 31
1 Orbicularis oculi m.
2 Orbicularis oris m.
3 Platysma m.
4 Buccinator m.
5 Masseter m.
6 Parotid duct
7 Parotid gland
8 Facial n. and branches

e. Identify the facial artery as it crosses the mandible. It is palpable in this location.

f. Identify the external carotid artery in the neck and some of its branches: the facial and superficial temporal arteries. Remember that the external carotid sends branches to the thyroid gland, tongue, face, maxillary region, and temporal region.

g. Note the terminal branches of the trigeminal nerve: the supraorbital, infraorbital, and the mental nerves.

h. On prosected material notice the anatomical relationship of the superior, inferior, medial, and lateral rectus to the eyeball. Their actions should be obvious from their attachment to the eyeball. The VIth cranial nerve innervates the lateral rectus but the remaining recti are innervated by the IIIrd cranial nerve.

(GA: 7-16, 7-15, 7-17, 7-18, 7-12, 7-58)

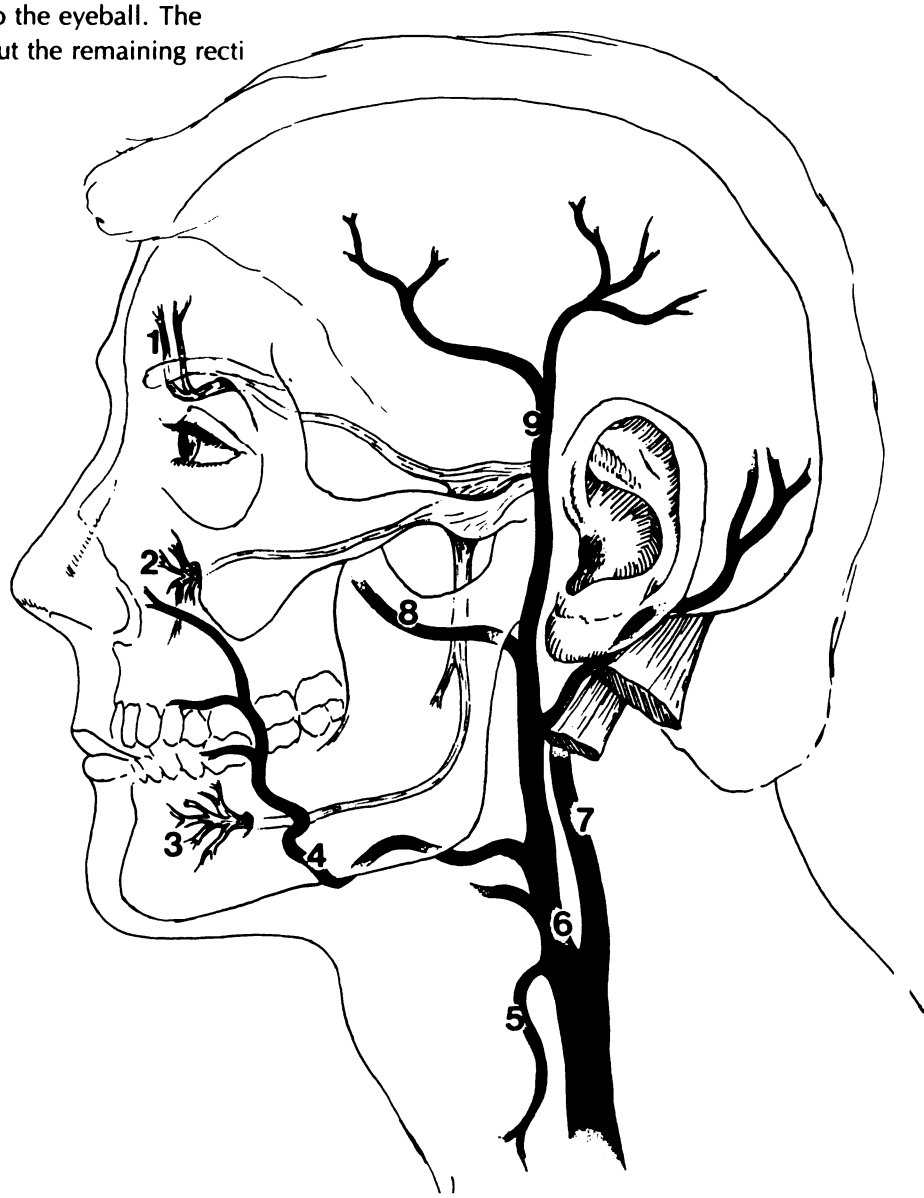

Fig. 32
1 Supraorbital n.
2 Infraorbital n.
3 Mental n.
4 Facial a.
5 Sup. thyroid a.
6 External carotid a.
7 Internal carotid a.
8 Maxillary a.
9 Superficial temporal a.

17 MEDIAN SECTION OF HEAD AND NECK

17. MEDIAN SECTION OF HEAD AND NECK

a. Identify the root of the tongue. Note the large papillae on the tongue (circumvallate papillae) which separate the tongue into an anterior two-thirds from a posterior one-third portion.

b. Study the epiglottis and the larynx and identify the vocal cords, the laryngeal aditus, and the false vocal folds.

c. Observe the nasal septum on a skeleton.

d. Identify the superior, middle, and inferior conchae and meatuses on the lateral side of the nose and locate the openings of the lacrimal duct, the maxillary sinus, the ethmoid sinusus, and the sphenoid sinus beneath these bones.

e. Identify the uvula and the opening of the Eustachian tube into the posterior aspect of the nasopharynx. Note the tonsils at the base of the tongue between the tonsillar pillars.

(GA: 7-84, 9-74, 9-78, 7-1, 7-114, 7-115, 7-108, 9-56, 9-57)

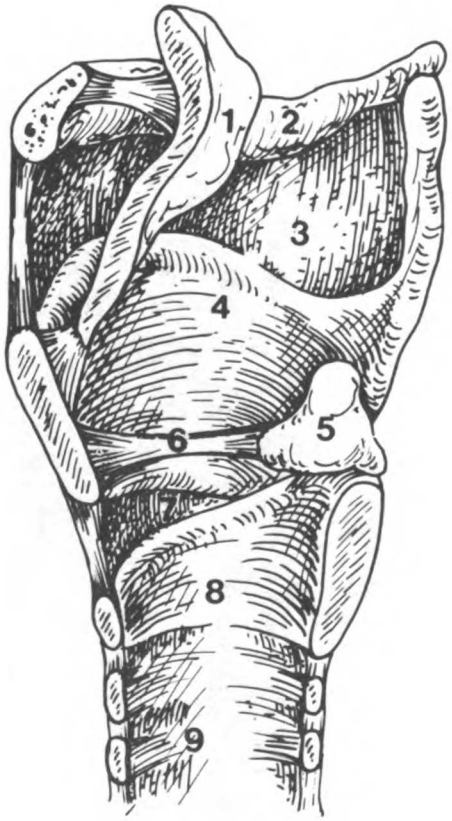



Fig. 33
1 Epiglottis
2 Hyoid bone
3 Thyrohyoid membrane
4 Thyroid cartilage
5 Arytenoid cartilage
6 Vocalis m.
7 Cricothyroid membrane
8 Cricoid cartilage
9 Trachea

Fig. 34
10 Frontal sinus
11 Maxillary sinus
12 Superior concha
13 Middle concha
14 Inferior concha

Fig. 35
15 Frontal sinus
16 Sphenoid sinus
17 Superior concha
18 Middle concha
19 Inferior concha
20 Orifice of lacrimal duct
21 Orifice of eustachian tube
22 Pharyngeal tonsil
23 Palatine tonsil
24 Uvula
25 Circumvallate papillae
26 Genioglossus m.
27 False vocal fold
28 True vocal fold

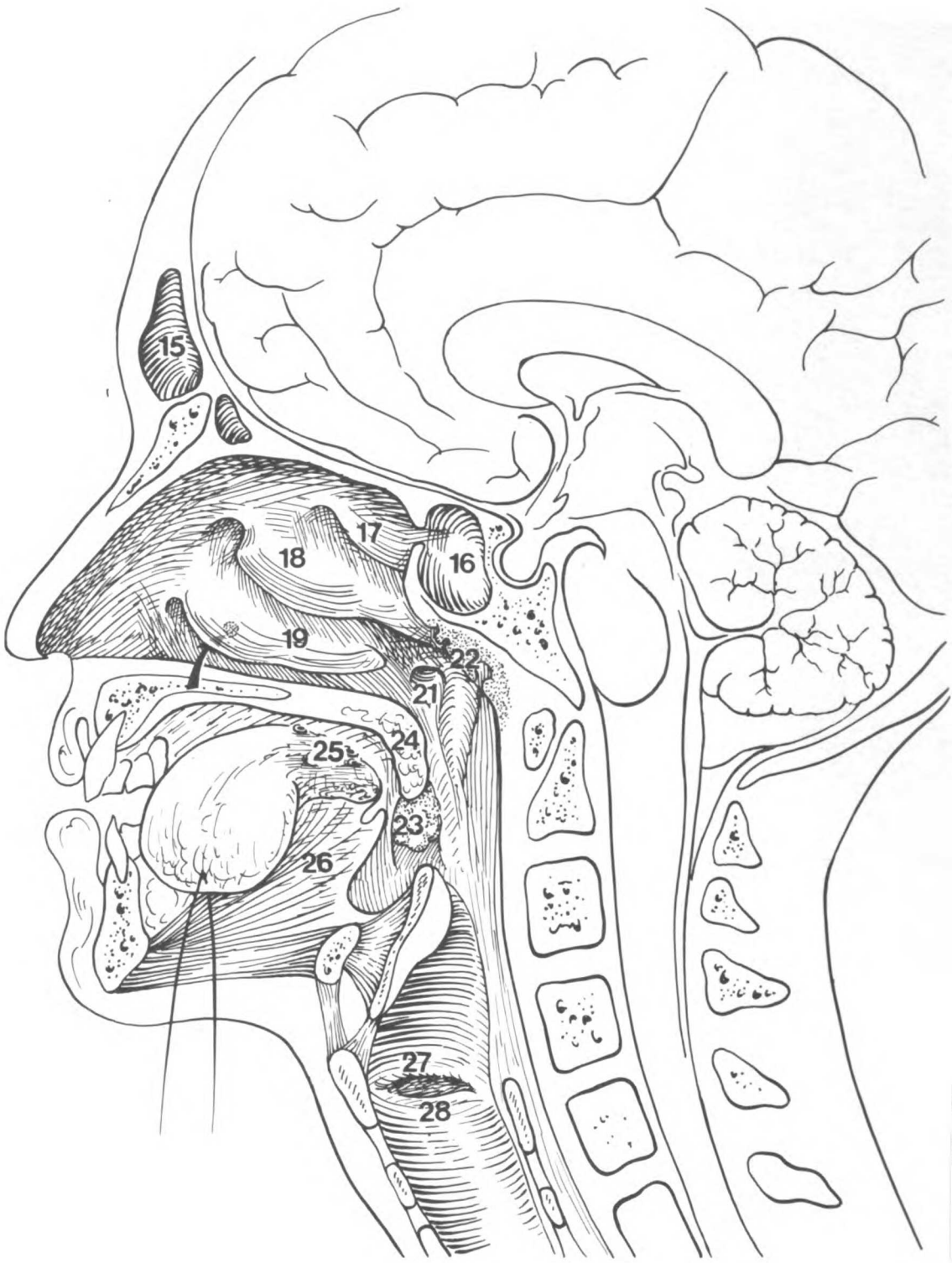

HEAD AND NECK REVIEW

1 Be able to define the borders of the anterior and posterior triangles of the neck.

2 Know the course in the neck of the contents of the carotid sheath (carotid artery, internal jugular vein, and vagus nerve) and the course of the neighboring cervical sympathetic chain.

3 List in order, as given off, the branches of the external carotid artery, as seen in the laboratory.

4 Know the relationships in the neck of the thyroid gland, the parathyroid, the esophagus, the trachea.

5 Describe the arterial and venous drainage of the thyroid gland.

6 Where specifically do the nasal sinuses drain into the nasal cavity?

7 Define: adenoid, Waldeyer's lymphatic ring, deglutition, nasal sinus, conchae, laryngeal aditus.

8 Know the sensory fields of the head innervated by different parts of trigeminal nerve (V) and by the second and third cervical nerves.

9 Know the extracranial relationships and distribution of the facial nerve (VII).

10 Of the arterial supply to the face, know in particular the location of the facial artery especially as it crosses the mandible; also note the importance of the superficial temporal artery. Know the pressure points for first-aid control of hemorrhage in regions served by these arteries.

11 Know the location and drainage of the three pairs of salivary glands.

12 Recognize the general arrangement of muscles of facial expression and know the following: orbicularis oculi, orbicularis oris, buccinator, and platysma.

13 Know the nerve supply of muscles of mastication. Be able to state the origin, insertion, and action of the masseter and temporalis muscles.

14 Give the complete motor and sensory innervation of the tongue.

15 Lesions of what structure(s) may be responsible for each of the following:
–Loss of taste sensation over the posterior third of the tongue
–Inability to close eyelids
–Unilateral paralysis of the tongue
–Anesthesia of the cornea
–Lack of facial expression
–Inability to chew
–Loss of touch sensation over the anterior two thirds of the tongue.
–Weakness in shrugging the shoulders
–Hoarse voice

16 What would be the effect on movement of the eye if the VIth cranial nerve were cut? The IIIrd cranial nerve?

17 State the motor innervation of the following: vocal muscles, masseter muscle, buccinator muscle, sternocleidomastoid muscle, the tongue.

18 State the skeletal motor function served by the following: the spinal accessory nerve, the facial nerve, the trigeminal nerve, the recurrent laryngeal nerve, the phrenic nerve.

19 Be able to describe the relationship of the following structures at the root of the neck: the scalenes anterior muscle, the phrenic nerve, the brachial plexus, the subclavian artery, the subclavian vein.

20 Name one abductor of the larynx and state its innervation.

21 Understand the anatomy of the pharynx and larynx.

UPPER EXTREMITY

18 AXILLA AND UPPER ARM

a. Reflect the pectoralis major and note the pectoralis minor muscle attached to the coracoid process of the scapula.

b. Cut the pectoralis minor from its rib origin and reflect it upwards. Identify the latissimus dorsi muscle forming the posterior wall of the axilla (with the teres major muscle).

c. On the coracoid process identify the coracobrachialis muscle and the short head of the biceps, lying lateral to the neurovascular bundle. (This is composed of the axillary vessels and the nerves of the brachial plexus.) Identify the nerves which form "the big M": the musculocutaneous nerve, the median nerve and the ulnar nerve. The spinal cord segments C 5 - T 1 contribute fibers to the brachial plexus.

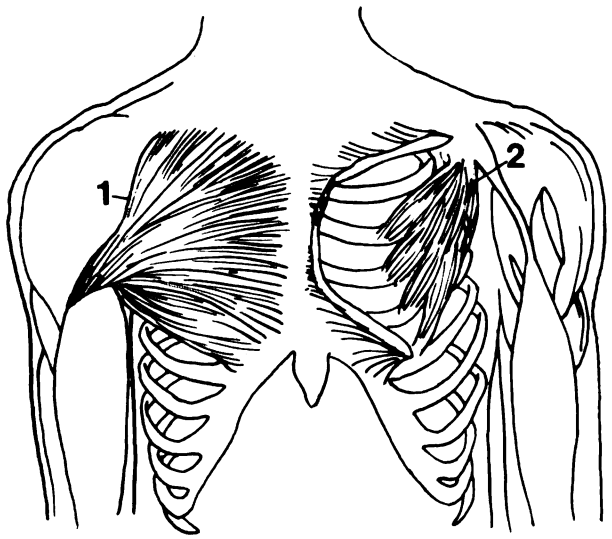

Fig. 36
1 Pectoralis major m.
2 Pectoralis minor m.

Figure 37
3 Pectoralis major m.
4 Pectoralis minor m.
5 Latissimus dorsi m.
6 Teres major m.
7 Serratus anterior m.
8 Coracobrachialis m.
9 Biceps brachii m.
10 Musculocutaneous n.
11 Median n.
12 Ulnar n.
13 Axillary a.

Fig. 38
14 Radial n.
15 Quadrangular space
16 Axillary n.
17 Triangular space
18 Nerve to teres major
19 Nerve to latissimus dorsi
20 Lateral cord
21 Axillary a.
22 Medial cord

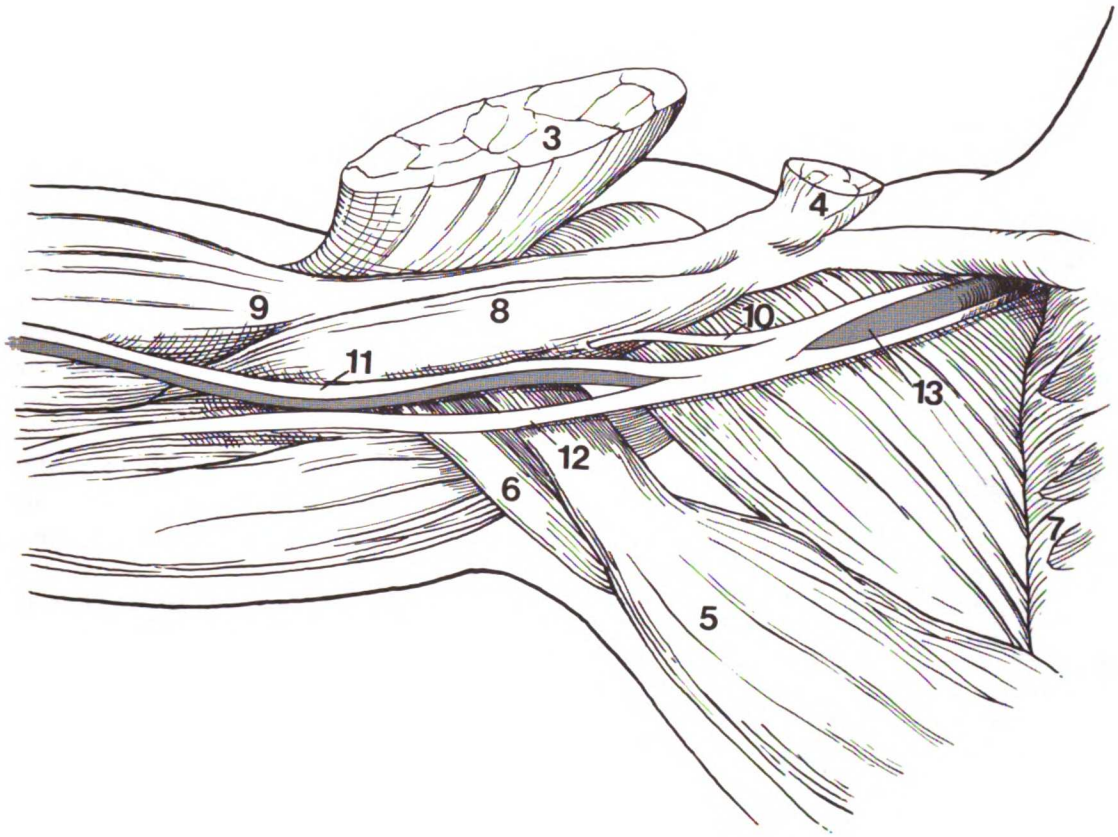
3
4
9
8
10
11
13
12
6
5

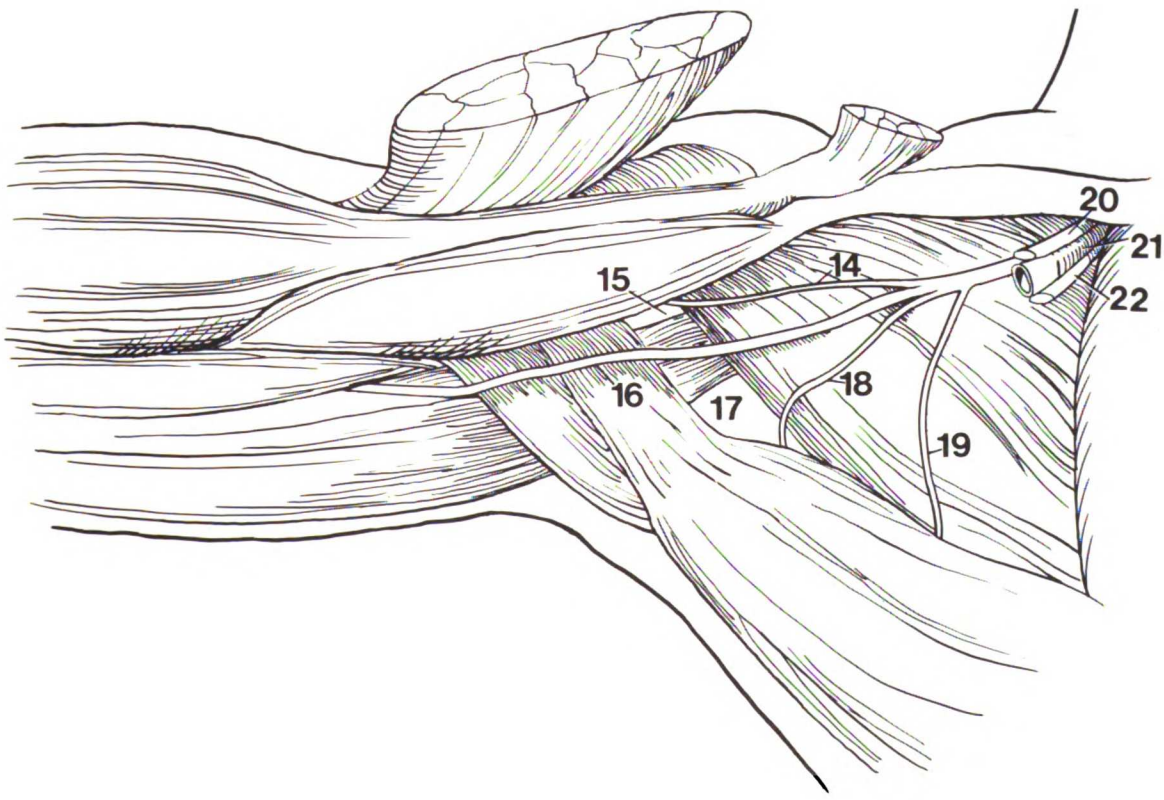
20
21
14
15
22
16
17
18
19

d. After you have dissected the axillary artery free and studied the adjacent nerves, pull the artery aside so that you can find two large nerves that lie behind it: the axillary and radial nerves. They travel inferiorly to innervate the posterior muscles of the shoulder, arm, and forearm. Notice that the profunda brachii artery accompanies the radial nerve as they both travel around the humerus to reach the posterior arm. Reflect the deltoid muscle and find the axillary nerve on its deep surface.

e. On the front of the arm identify the long and short head of the biceps and the brachialis muscles. Identify the musculocutaneous nerve as it passes lateral to the tendon of the biceps muscle.

f. Identify the brachial artery and the median nerve as they pass through the arm.

g. Follow the ulnar nerve as it passes behind the medial epicondyle of the humerus. (What is the funny bone?)

h. Study the triceps muscle (why so named?) and expose the radial nerve as it courses in the spiral groove of the humerus through the triceps muscle.

(GA: 6-14, 6-20, 6-22, 6-23, 6-24, 6-40, 6-55, 6-64)

Fig. 39

1 Long head of triceps m.
2 Head of humerus
3 Axillary n.
4 Post. humeral circumflex a.
5 Lateral head of triceps m.
6 Radial n.
7 Deltoid m. (cut edge)
8 Medial head of triceps m.
9 Brachial a.
10 Profunda brachii a.
11 Triceps m.
12 Ulnar n.

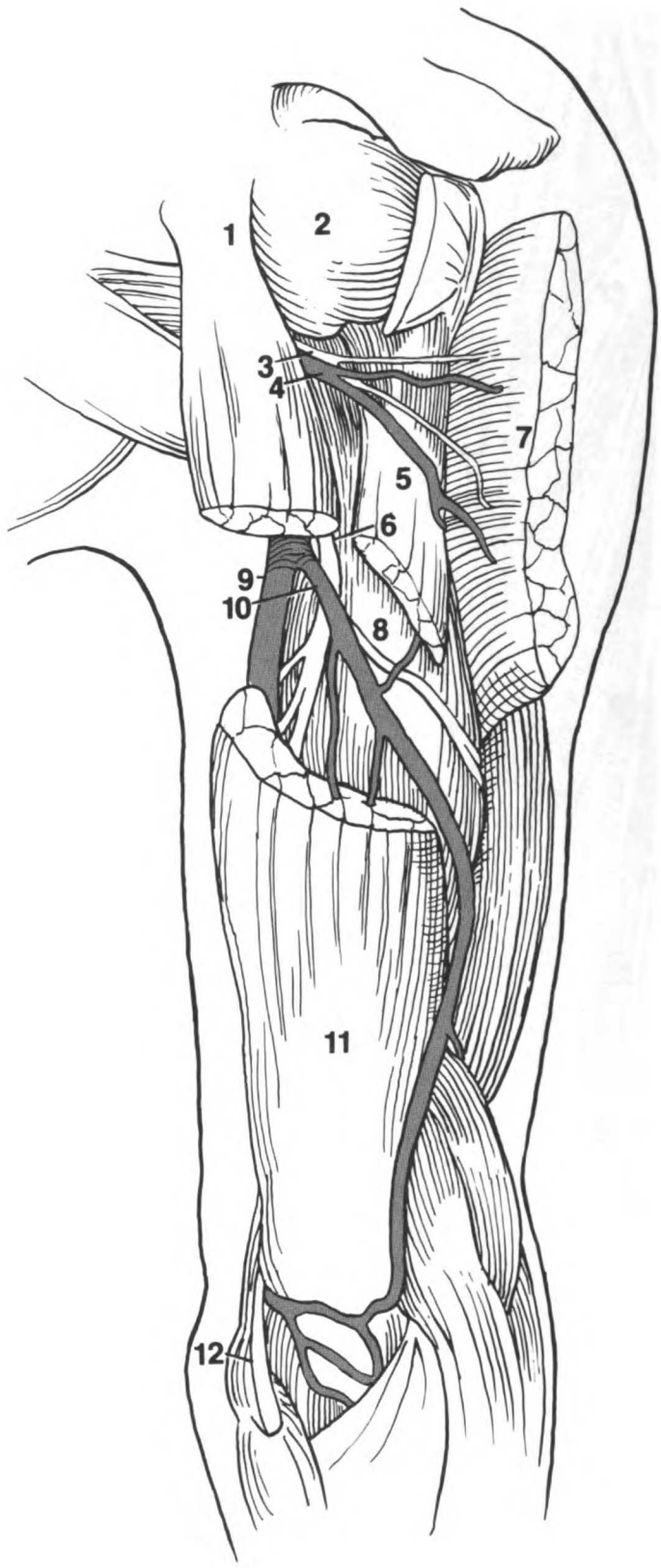

19 CUBITAL FOSSA AND FOREARM

a. Reflect the skin of the arm, forearm, and antecubital fossa. Note the superficial veins in the fossa: note on fellow students their distribution is somewhat variable. Using your atlas, identify the median cubital vein.

b. Identify the bicipital aponeurosis and note that it covers the brachial vessels and the median nerve: the veins of the cubital fossa lie superficial to it.

c. Identify the tendon of the biceps insertion onto the tuberosity of the radius, and the brachialis insertion onto the coronoid process of the ulna.

d. On the skeleton, note the medial and lateral epicondyles of the humerus. In general, the flexors of the forearm arise from the medial epicondyle and are innervated by the median nerve; the extensors of the forearm arise from the lateral epicondyle and are innervated by the radial nerve. Verify this fact on the cadaver. Also notice how your anterior forearm tenses when you make a fist.

e. The radial nerve innervates the extensors as well as the supinators of the forearm. Find it medial to the origin of the brachioradialis muscle and anterior to the lateral condyle of the humerus.

f. In the antecubital fossa the brachial artery divides into two branches: the radial and ulnar arteries. Note the ulnar nerve and artery are moderately superficial laterally and lie below the flexor carpi ulnaris (which it innervates).

g. Identify the pronator teres muscle. The innervation of the pronators of the forearm are via the median nerve.

(GA: 6-4, 6-53, 6-1, 6-67, 6-68, 6-69)

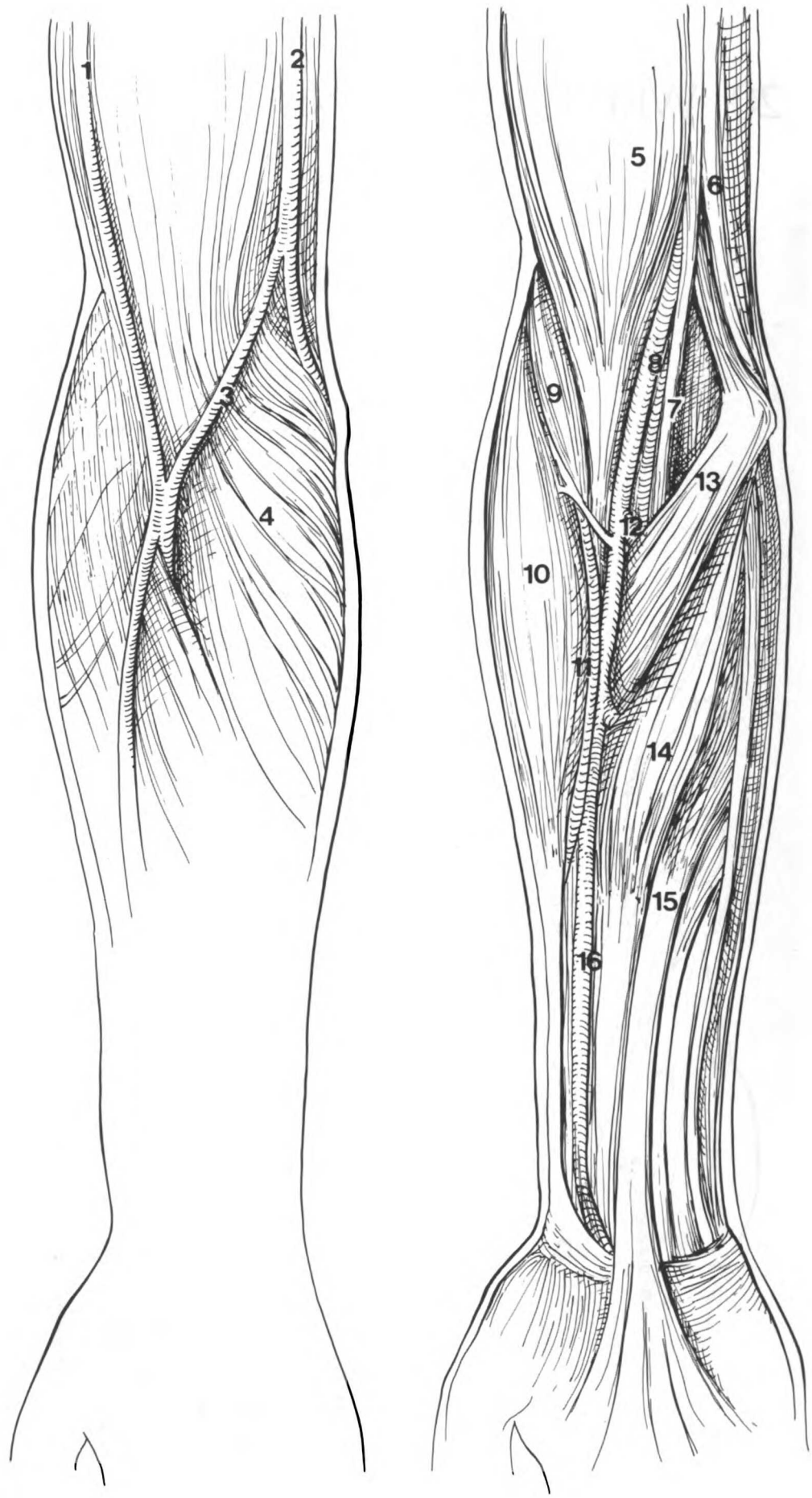

Fig. 40
1 Cephalic v.
2 Basilic v.
3 Median cubital v.
4 Bicipital aponeurosis
5 Biceps brachii m.
6 Ulnar n.
7 Median n.
8 Brachial a.
9 Brachialis m.
10 Brachioradialis m.
11 Radial n.
12 Ulnar a.
13 Pronator teres m.
14 Flexor carpi radialis m.
15 Palmaris longus m.
16 Radial a.

20 WRIST AND HAND

a. Flex your own wrist and note certain tendons become prominent. In the midportion of the wrist, identify the palmaris longus tendon, the flexor carpi radialis tendon, (the median nerve lies between them). Note also the radial artery is palpable on the lateral aspect of the wrist; the tendon to the flexor carpi ulnaris (with its underlying ulnar nerve) is visible in the medial side of the wrist. Verify these structures on the cadaver. Find the ulnar and radial pulses on yourself.

b. Note the flexor retinaculum extends across the wrist and acts as a bandage to prevent the flexor tendons (as they pass into the hand) from bowstringing.

c. Observe the flexor tendons passing through the palm of the hand to attach to the phalanges of the fingers, thereby acting as flexors of the fingers as well as flexors of the wrist.

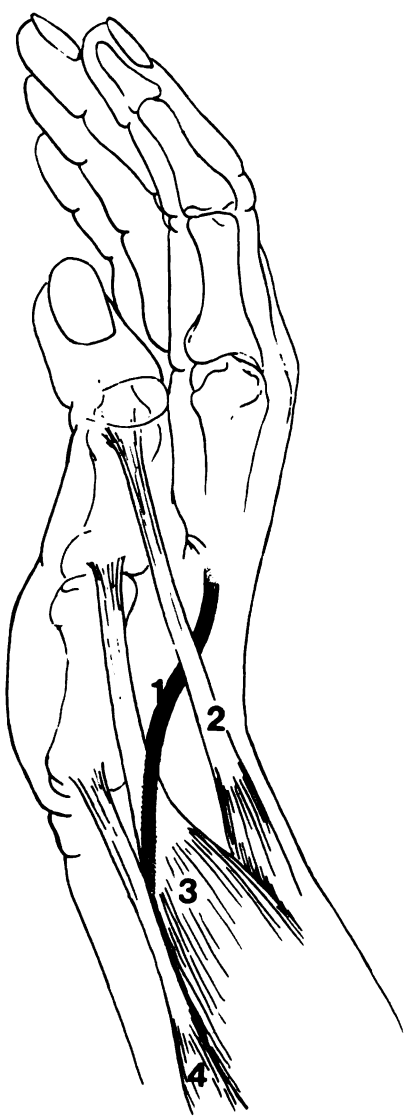

Fig. 41
1 Radial a.
2 Extensor pollicis longus m.
3 Extensor pollicis brevis m.
4 Abductor pollicis longus m.

Fig. 42
1 Flexor carpi ulnaris m.
2 Ulnar a. and n.
3 Flexor digitorum superficialis m.
4 Palmaris longus m.
5 Flexor carpi radialis m.
6 Radial a.
7 Abductor pollicis longus m.



d. Note the small (intrinsic) muscles of the finger (the lumbricals and interossei): these are innervated by the ulnar nerve and are responsible for the fine movements of the fingers.

e. Note the thumb muscles (thenar eminence). These are innervated by the median nerve. This branch is superficial and is in danger of being severed in grasping sharp objects such as knives and broken glass.

f. Note the long extensor tendons of the thumb become visible when the thumb is abducted and extended. The space observed between these long tendons is called the radial (anatomical) snuff box. Find the pulse of the radial artery on the floor of the snuff box.

g. What is the superficial (sensory) distribution of the three major nerves in the hand: the radial, the median, and the ulnar? Review again the spinal cord dermatomes of the hand.

(GA: 6-74, 6-75, 6-79, 6-85, 6-87, 6-100)

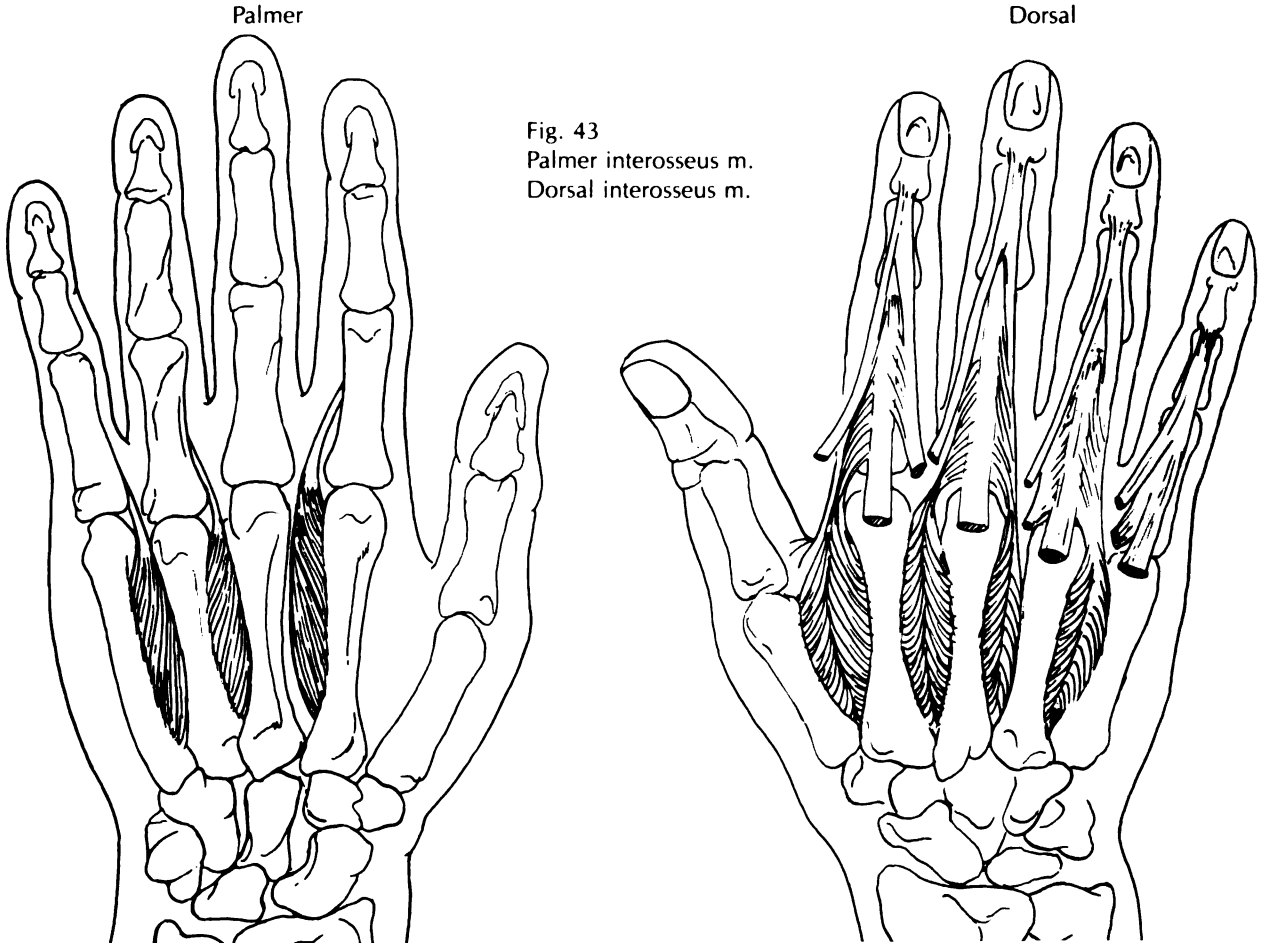

Fig. 43
Palmer interosseus m.
Dorsal interosseus m.

Fig. 44

1 Flexor retinaculum
2 Lumbricals
3 Tendons of flexor digitorum profundus m.
4 Tendons of flexor digitorum superficialis m.
5 Flexor pollicis brevis m.
6 Opponens pollicis m.
7 Abductor pollicis longus m.
8 Recurrent median n.

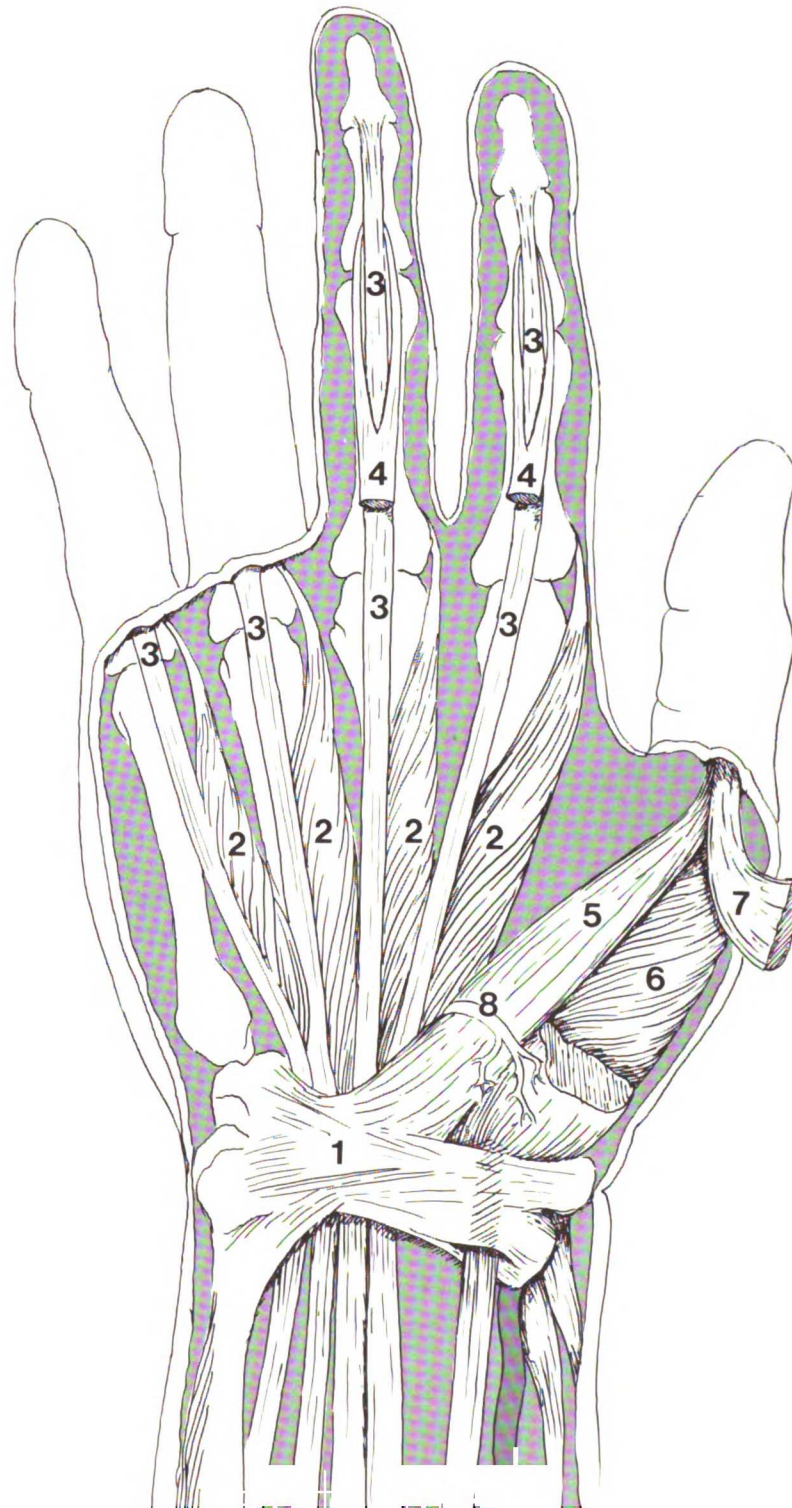

UPPER EXTREMITY REVIEW

1 Know the muscles of the upper extremity, conceived as functional groups in each region rather than as individual muscles; know their principle attachments and the joints upon which they act.

2 Know the main arterial trunks of the upper extremity in shoulder, arm, and forearm.

3 Know the terminal branches of the brachial plexus which serve the principal muscle groups and know their sensory fields.

4 If the median nerve were severed at the level of the middle of the humerus what muscles would be paralyzed? What would the cutaneous sensory loss be?

5 What would be the consequences of division of either the radial or median nerve at the following levels?
–Middle of arm
–Wrist

6 As prime mover(s), what muscle(s) produce(s) the following movements:
–Flexion of forearm on arm
–Medial rotation of humerus
–Supination and pronation of forearm
–Flexion of wrist

7 What nerve is particularly endangered by infra-glenoid dislocation of the humerus?

8 What is the location of the important motor branch of the median nerve to the thenar muscles?

9 Give the origin, location, and sensory and motor distribution of the axillary nerve.

10 In regard to the brachial plexus, give a one word or one line answer:
–With what artery is the brachial plexus in intimate relationship?
–From what cord of the plexus does the radial nerve arise?
–What roots of the brachial plexus are most likely to be compressed by an extra cervical rib (an extra rib associated with the 7th cervical vertebrae)?

11 Know the anastomosis of arteries around the shoulder.

PELVIS AND PERINEUM

21 PELVIC STRUCTURES

a. On a skeleton locate the following regions and landmarks: pelvic inlet, pelvic outlet, true pelvis, false pelvis, iliac crest, iliac spines, ischial tuberosity, ischial spine, pubic tubercle, rami of the pubic bone, greater and lesser sciatic notches, obturator foramen. Determine how the sacrospinous and sacrotuberous ligaments form the greater and lesser sciatic foramen by closing the open side of the greater and lesser sciatic notches.

b. Study the peritoneal relationships of the cadaver. Locate the uterovesical and rectouterine pouches in the female and the rectovesical pouch in the male. Note how the peritoneum is draped over the uterus and oviducts to form the broad ligament.

c. Trace the ureters from the kidneys to the points that they enter the bladder wall.

d. Examine the interior of the bladder by opening it with a midsagittal cut through the muscular wall. Identify the mucous membrane lining the interior. Pass a probe into one of the ureteric orifices and note the obliquity of the intramural part of the ureter. Identify the internal urethral meatus. The trigone of the bladder is the triangular region between the ureteric orifices and the internal urethral meatus. In a hemisected pelvis, estimate the locations of the internal and external urethral sphincters.

Fig. 45

1 Iliac crest
2 Iliac spine
3 Iliac fossa
4 Acetabular fossa
5 Pubic tubercle
6 Ischial spine
7 Sacro-spinous ligament
8 Sacrum
9 Ischial tuberosity
10 Sacro-tuberous ligament
11 Greater sciatic foramen
12 Lesser sciatic foramen
13 Obturator foramen
14 Pelvic brim

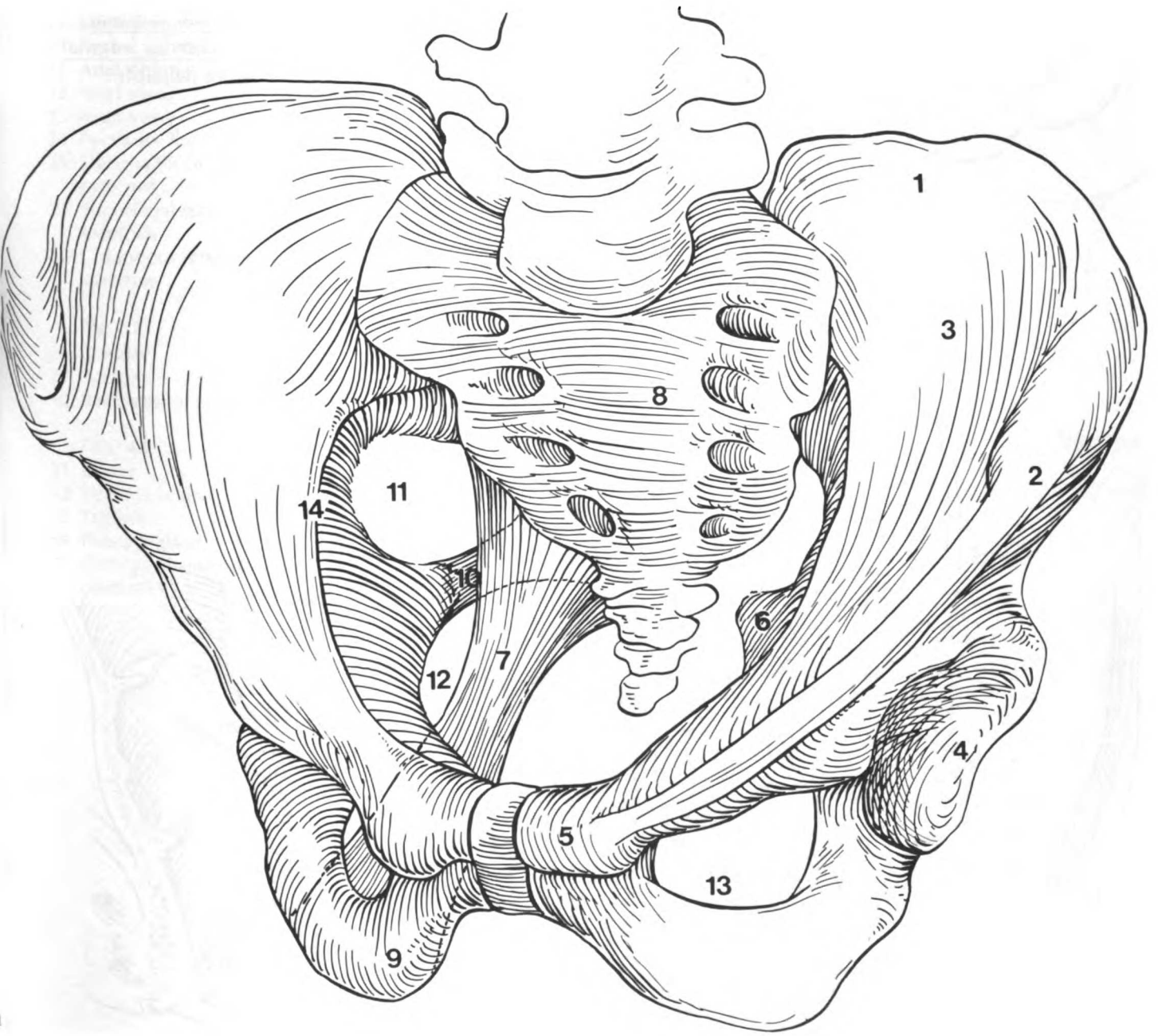
1
3
2
8
11
14
10
6
7
12
4
5
13
9

e. Using a hemisected male and female pelvis, study the rectum and anus. Find portions of the rectal valves of Houston. Identify the anal columns, sinuses, and valves. Note the approximate location of the pectinate line and the anal sphincters. A digital rectal exam in the male allows checking the condition of the prostate gland, seminal vesicles, and rectovesical pouch. In the female, the posterior vaginal wall, cervix, rectouterine pouch, and uterine body are palpable.

(GA: 3-2, 3-4, 3-5, 3-10, 3-11, 3-46, 3-48, 3-44)

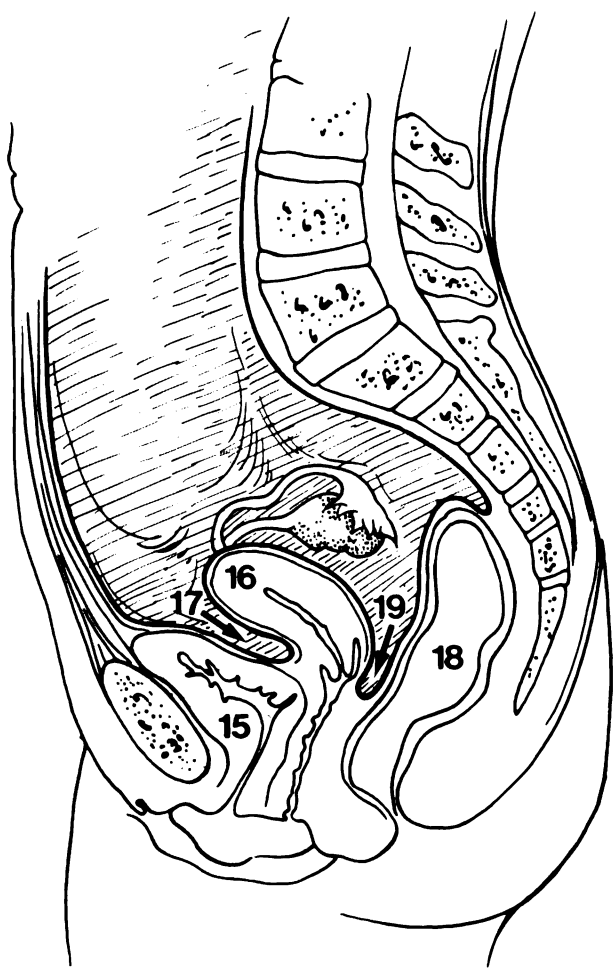



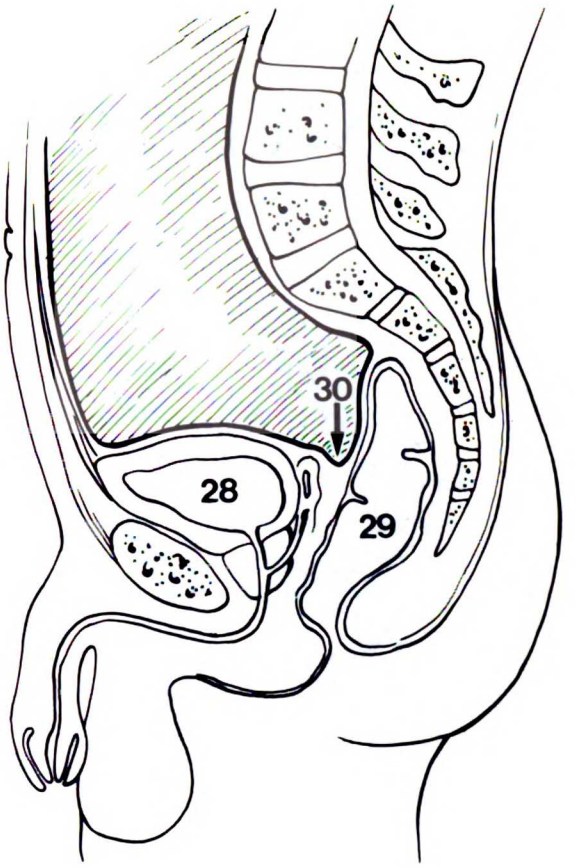

Fig. 46
15 Bladder
16 Uterus
17 Uterovesical pouch
18 Rectum
19 Rectouterine pouch
20 Rectal valves of Houston
21 Anal column
22 Anal sinus
23 Anal valve
24 Pectinate line
25 Deep sphincter ani externus
26 Superficial sphincter ani externus
27 Cutaneous sphincter ani externus

Fig. 47
28 Bladder
29 Rectum
30 Rectovesical pouch

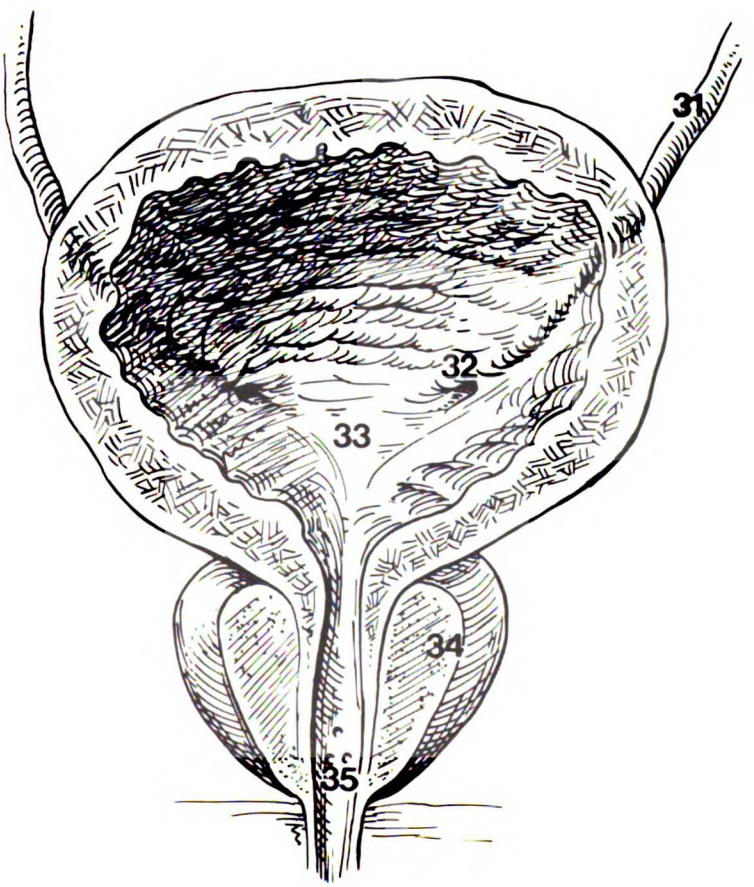

FIG. 48
31 Ureter
32 Ureteric orifices
33 Trigone
34 Prostate gland
35 Orifices of ejaculatory ducts

22 MALE GENITO-URINARY SYSTEM

a. Using the male hemisected pelvis and cadaver, trace the ductus deferens from the testis through the inguinal canal to the ampulla of the ductus. Note that it crosses the terminal part of the ureter. Find the seminal vesicles and the ejaculatory ducts. Locate the prostatic, membranous, and penile parts of the urethra.

b. Open the tunica vaginalis testis. Find the epididymis. With a scalpel cut open the testis and note the thick tunica albuginae and the fine seminiferous tubules.

(GA: 2-16, 2-17, 2-18, 3-25, 3-46)

Fig. 49

1 Tunica albuginea
2 Seminiferous tubules
3 Dartos tunic
4 Cavity of tunica vaginalis

Fig. 50

5 Ureter
6 Seminal vesicles
7 Bladder
8 Prostatic urethra
9 Membranous urethra
10 Penile urethra
11 Ductus deferens
12 Testes
13 Epididymis

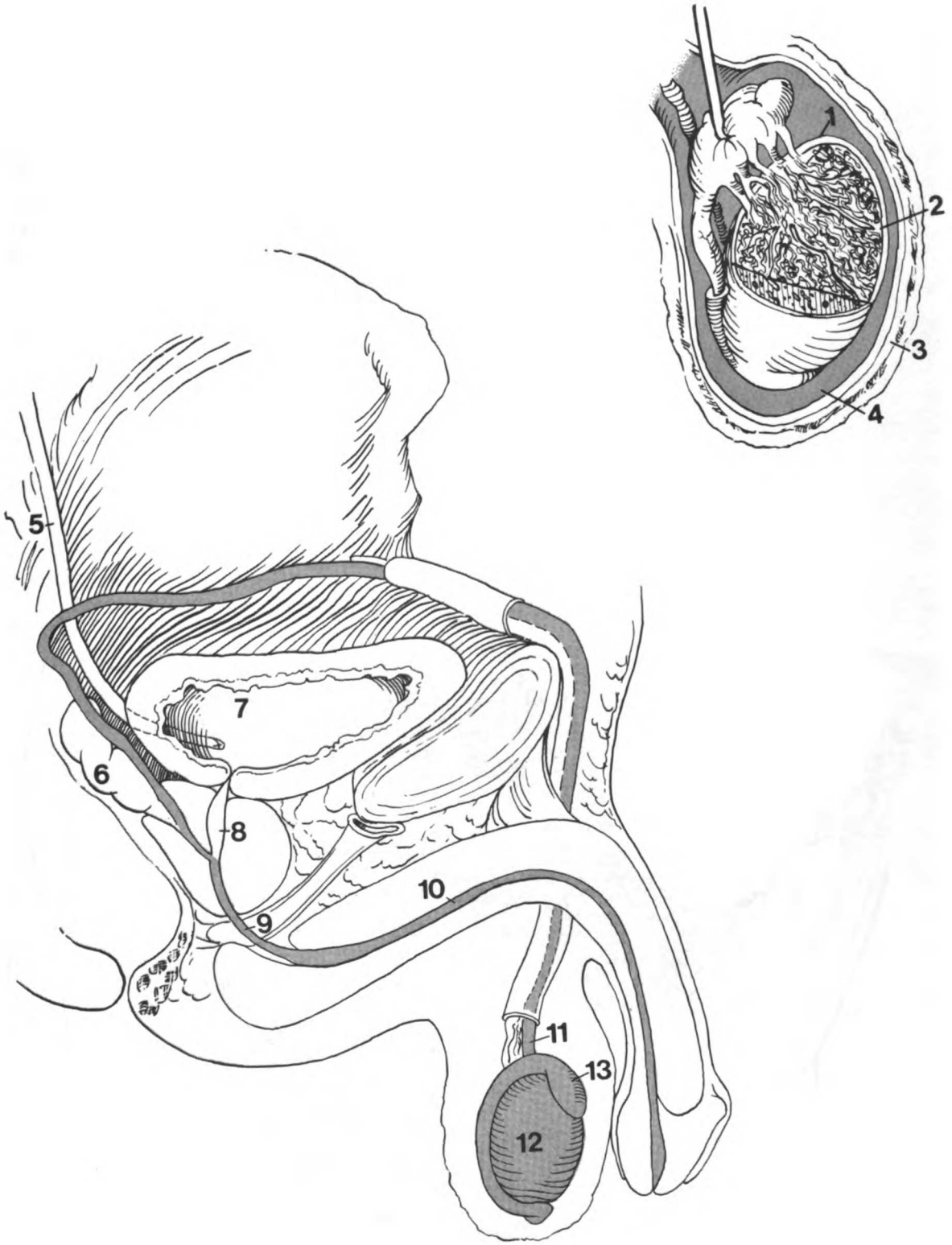
1
2
3
4
5
6
7
8
9
10
11
12
13

23 FEMALE GENITO-URINARY SYSTEM

a. Using the demonstration specimens and the female cadavers, identify the uterus, oviducts (uterine tubes), and the ovaries. Locate the vagina and find the uterine cervix. Note the relationship of the posterior fornix of the vagina to the rectouterine pouch. In a vaginal exam, the rectouterine pouch, rectum, ureters, cervix, cervical os, bladder and urethra can be palpated. Study the relationships of these structures to the vagina.

b. Identify the round ligament of the uterus and follow it through the inguinal canal.

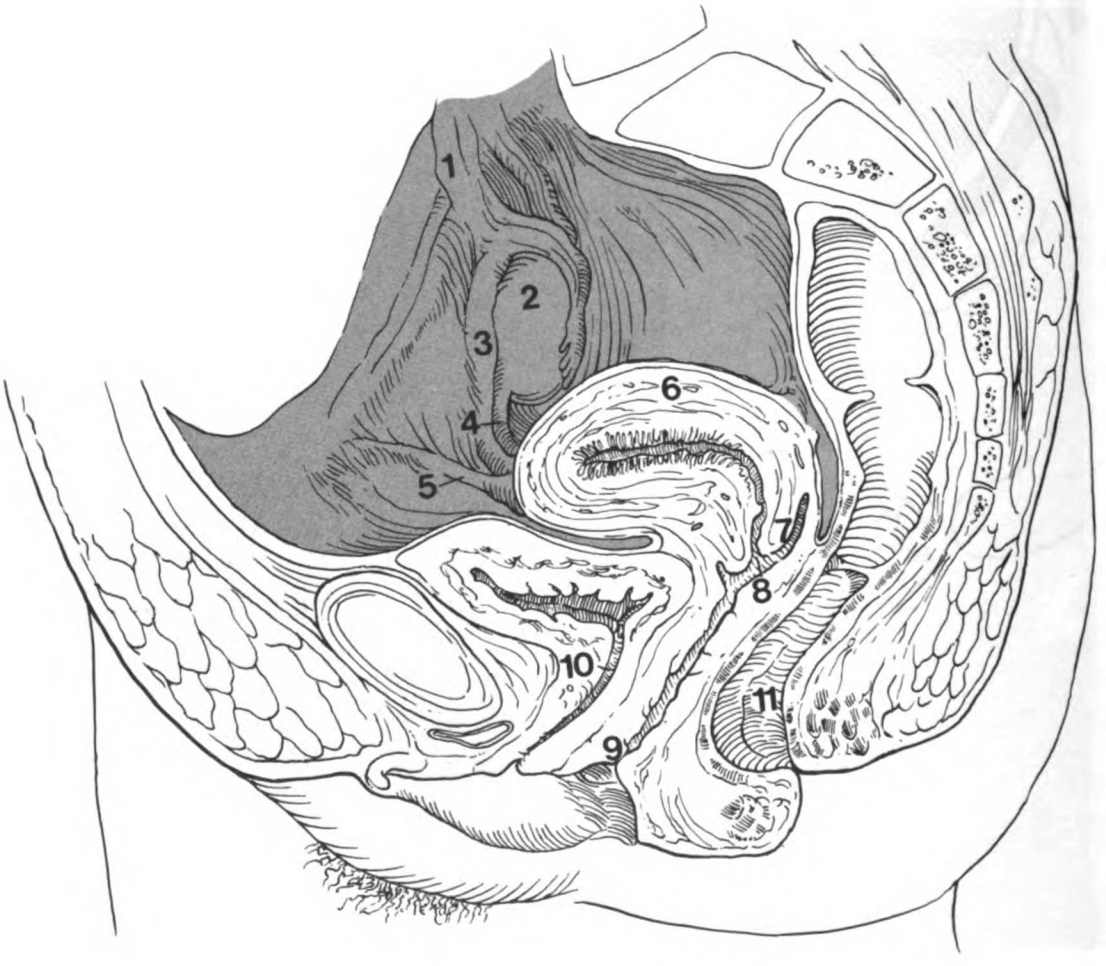

c. Trace the ovarian vessels in the suspensory ligament of the ovary. Find the round (proper) ligament of the ovary attaching the ovary to the uterus.

d. Identify the uterine artery arising from the internal iliac artery and note its relationship to the ureter passing to the bladder. The uterine artery runs within the transverse cervical ligament, a condensation of pelvic fascia.

(GA: 3-58, 3-60, 3-61, 3-62)

Fig. 51 Sagittal view
1 Suspensory ligaments
2 Ovary
3 Uterine tube
4 Round ligament of ovary
5 Round ligament of uterus
6 Uterus
7 Posterior fornix
8 Cervical os
9 Vagina
10 Urethra
11 Rectum

Fig. 52 Posterior view
12 Ovary
13 Uterine tube
14 Round ligament of ovary
15 Uterus
16 Uterine cervix
17 Ureter
18 Uterine a.
19 Suspensory vessels

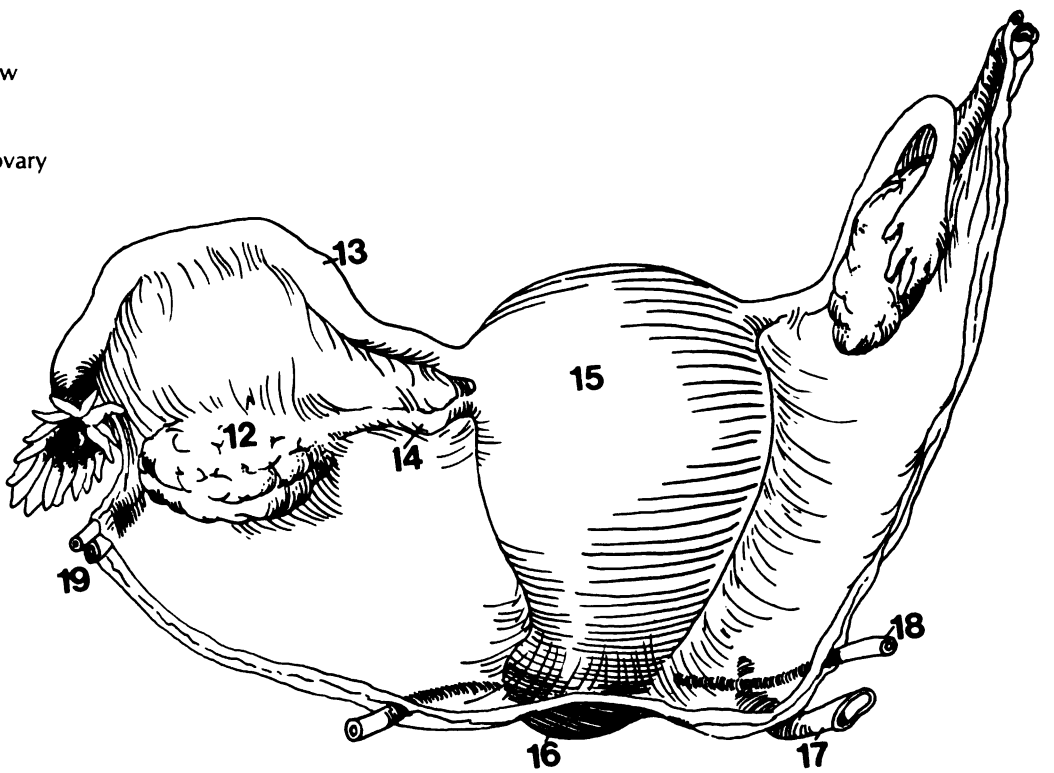

PELVIS-PERINEUM REVIEW

1 What features distinguish the male from the female bony pelvis?

2 Name the fibromuscular structures that form the floor of the pelvis and support the pelvic viscera.

3 How do you explain the occurrence of abdominal pregnancy?

4 What structures are palpable on digital examination of the rectum in the male; in the female?

5 What structures are palpable on digital examination of the vagina?

6 List the ligamentous supports of the uterus; the ovary.

7 Trace the path of sperm in passing from the testis to the outside of the body.

8 What arteries supply the following: bladder, uterus, prostate, seminal vesicles, and vagina?

9 What structures support the bladder?

10 What is a reflex (automatic) bladder: an autonomous bladder?

11 Name some common causes of hemorrhoids.

12 Define obstetrical perineum and anatomical perineum.

LOWER EXTREMITY

24 FRONT OF THIGH

a. Identify the long saphenous vein running in the superficial fascia of the lower limb beginning on the medial side of the ankle and ascending to enter the femoral vein.

b. Identify the femoral artery lateral to the vein and the femoral nerve lateral, again, to the artery.

c. From the abdominal side of this region pass your finger along the medial side of the external iliac vein into the thigh. It now lies along the femoral vein (which is a continuation of the external iliac vein). Your finger is now in the femoral canal. Note that medially you can palpate the lacunar ligament, a curved portion of the inguinal ligament attached to the pubis. The femoral canal is the site of femoral hernias. (Compression of the herniated part by the lacunar ligament may complicate repair of the hernia.)

d. Identify the muscles of the front of the thigh: the rectus femoris and the three vasti. They are innervated by the femoral nerve and act to flex the hip and extend the knee. What is their insertion?

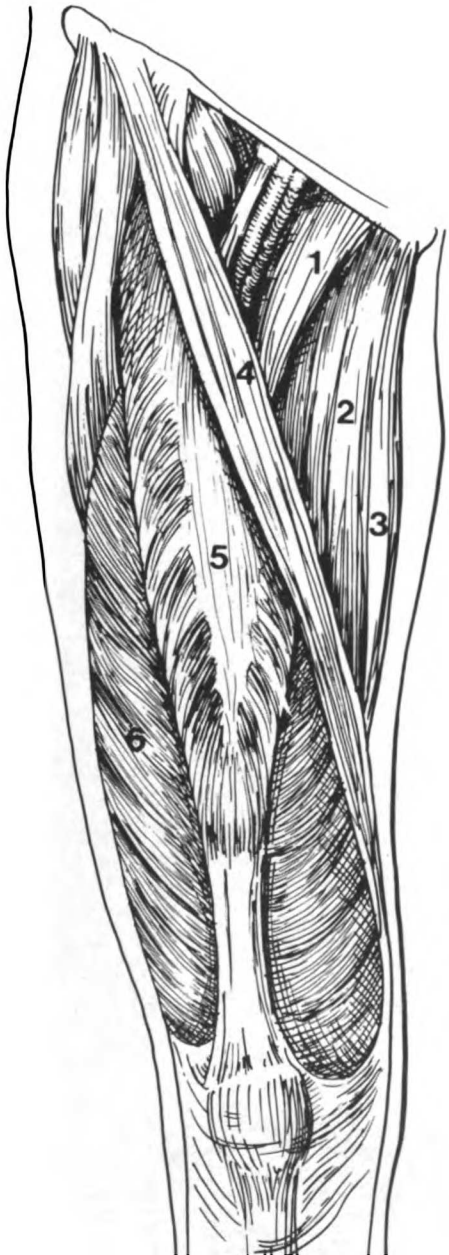

Fig. 53
1 Pectineus m.
2 Adductor longus m.
3 Gracilis m.
4 Sartorius m.
5 Rectus femoris m.
6 Vastus lateralis m.

e. The medial thigh muscles are the adductors. They adduct and flex the thigh and are innervated by the obturator nerve. Identify this muscle group and follow the obturator nerve from the obturator foramen in the pelvis into the thigh.

f. The spinal cord segments involved in the femoral and obturator nerves are L 2, 3, and 4.

g. What spinal cord segments comprise the lumbosacral plexus? What are the terminal branches that supply both motor and sensory innervation to the lower extremity?

(GA: 4-9, 4-20, 4-15, 4-17, 4-28, 4-29, 4-25)



Fig. 54
1 Femoral ring
2 Femoral canal
3 Femoral sheath

Fig. 55
4 Sartorius m.
5 Rectus femoris m.
6 Pectineus m.
7 Adductor longus m.
8 Adductor brevis m.
9 Adductor magnus m.
10 Gracilis m.
11 Vastus medialis m.
12 Vastus intermedius m.
13 Vastus lateralis m.

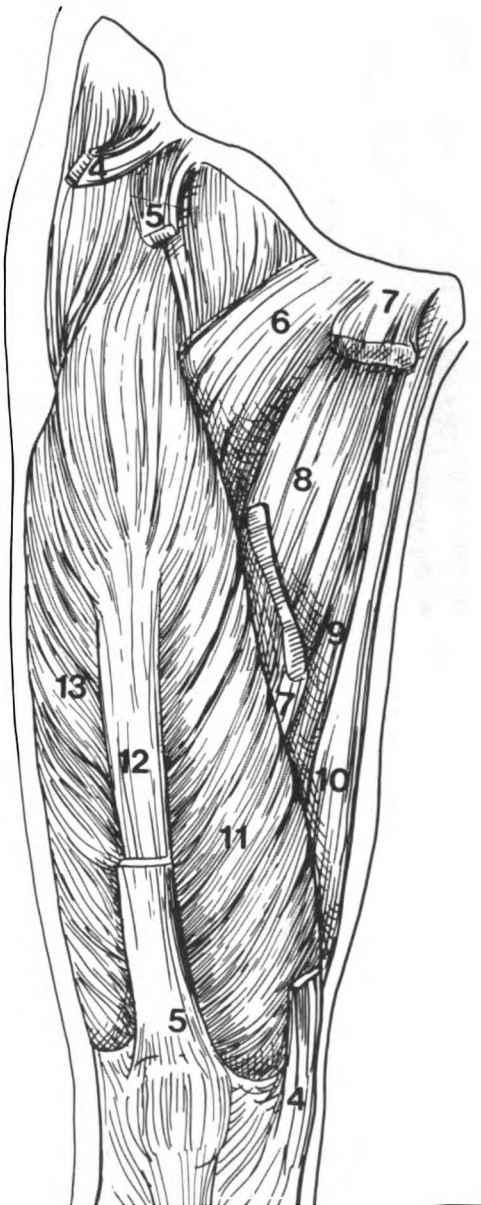

25 GLUTEAL REGION, BACK OF THIGH AND CALF

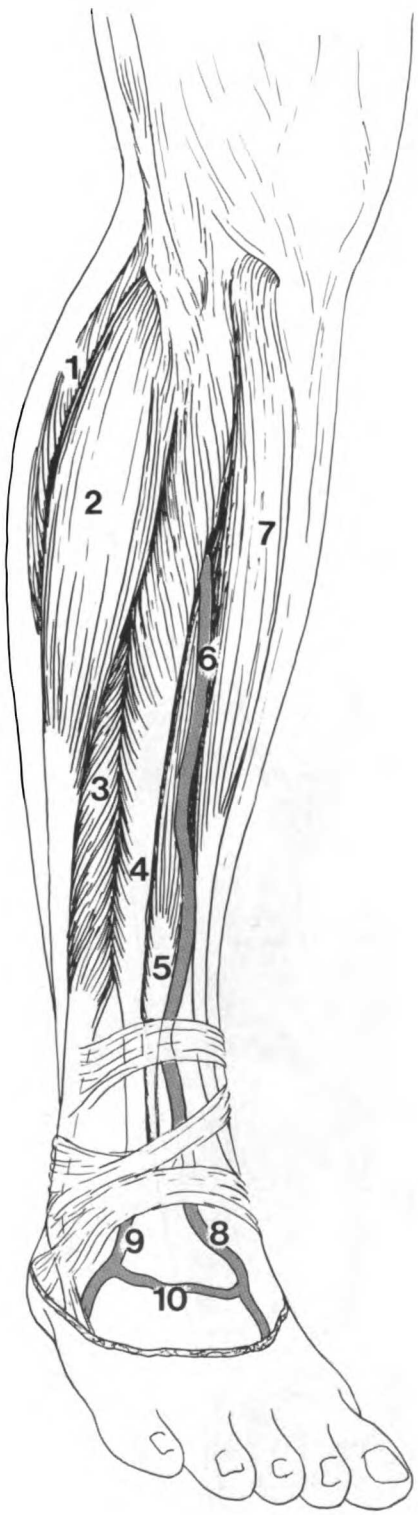

a. Reflect the skin and superficial fascia over the buttocks. Note the large muscle, the gluteus maximus. Reflect it and follow the sciatic nerve into the thigh. Note its inferio-medial location between the ischial tuberosity and the greater trochanter (of the femur). Recall that intramuscular injections are given in the buttocks. They should always be given into the upper and outer quadrant of the buttocks. Failure to follow this rule can result in injections into the sciatic nerve and subsequent destruction of it.

b. Note the hamstring muscles on the back of the thigh: the biceps femoris laterally and the semitendinosus and semimembranosus medially. These are innervated by the medial portion of the sciatic nerve. The hamstring muscles extend the thigh (to push off from the floor as in walking) and flex the lower leg (to bend the knee).

c. Note the sciatic nerve behind the knee in the diamond-shaped popliteal fossa. Observe also that the popliteal artery (a continuation of the femoral artery from the front of the thigh) enters the fossa at its upper end.

d. Find the division of the sciatic nerve into its two main branches, the tibial (continuing down the back of the calf); and the common peroneal (passing beneath the head of the fibula to the lateral side of the calf).

e. The muscles on the anterolateral surface of the calf in general evert and dorsiflex the foot, and are innervated by branches of the peroneal nerve.

f. The popliteal artery divides in the lower part of the popliteal fossa and its branches follow the branches of the sciatic nerve: posterior tibial and anterior tibial (accompanying the deeper branch of the peroneal nerve which is also called the anterior tibial nerve). Locate these two vessels in the region of the ankle. They are important in determining pulses in the lower limb.

(GA: 4-31, 4-52, 4-53, 4-71, 4-75, 4-87)

Fig. 56
1 Soleus m.
2 Peroneus longus m.
3 Peroneus brevis m.
4 Extensor digitorum longus m.
5 Extensor hallicus longus m.
6 Tibialis anterior a.
7 Tibialis anterior m.
8 Dorsalis pedis a.
9 Lateral tarsal a.
10 Arcuate a.

Fig. 57
1 Common peroneal n.
2 Tibial n.
3 Popliteal v.
4 Popliteal a.

Fig. 58
5 Gluteus maximus m.
6 Biceps femoris m.
7 Semitendinosus m.
8 Semimembranosus m.
9 Gracilis m.
10 Gastrocnemius m.
11 Sciatic n.
12 Common peroneal n.
13 Tibial n.
14 Post. tibial a.
15 Ant. tibial a.
16 Peroneal a.

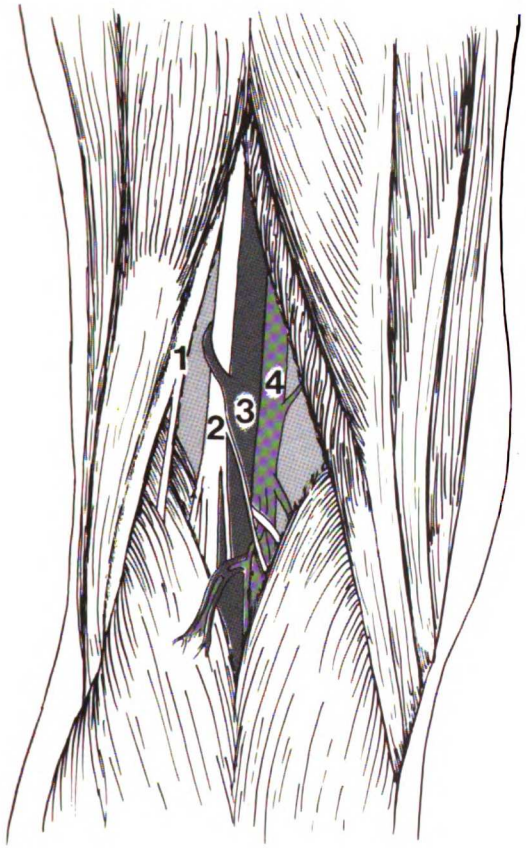

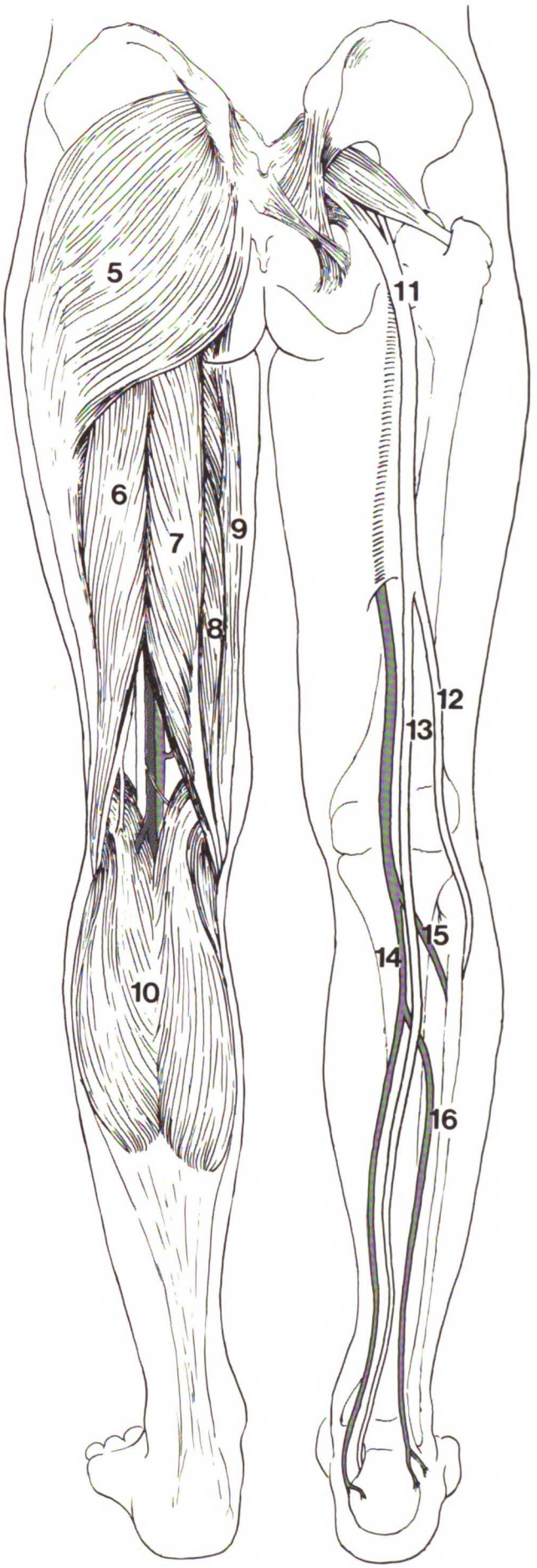

LOWER EXTREMITY REVIEW

1 Make a systematic outline to show the grouping of the muscles of the lower extremity according to functional groups and nerve supply.

2 Name the boundaries of the femoral ring. Trace the femoral artery through the thigh.

3 What are the sensory and motor effects of cutting the common peroneal nerve? The tibial nerve?

4 Trace the location of the superficial veins in the lower extremity. Trace the location of the arteries in the lower extremity. Name four locations where arterial pulses can be found in the lower extremity.

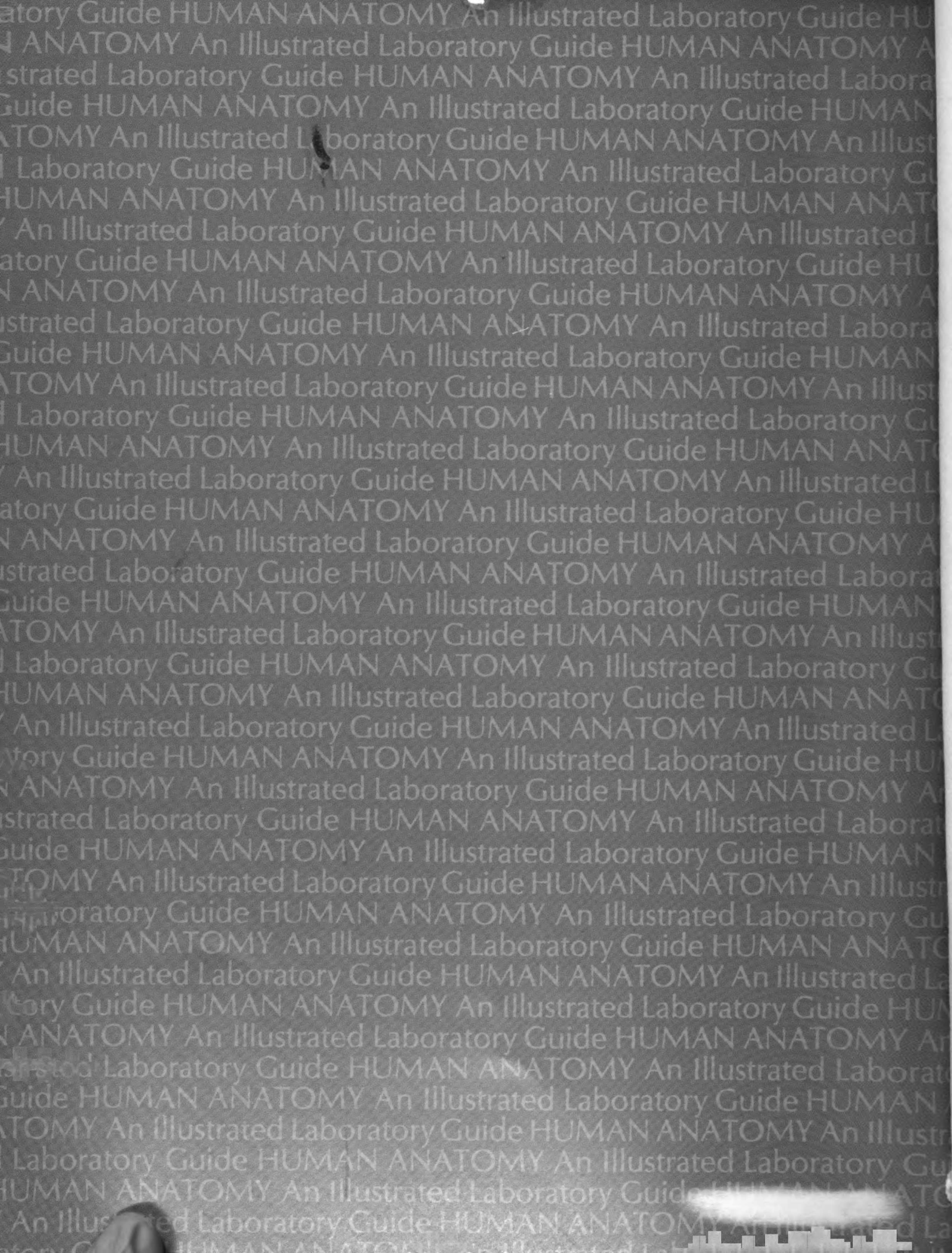
HUMAN ANATOMY An Illustrated Laboratory Guide

UC San Francisco LIBRARY
UNIVERSITY OF CALIFORNIA

UC San Francisco LIBRARY