Title
Transcranial Doppler: Does Addition of Blood to Agitated Saline Affect Sensitivity for Detecting Cardiac Right-to-Left Shunt?

Journal
Echocardiography, 33(8)

ISSN
0742-2822

Authors
Mojadidi, Mohammad Khalid
Zhang, Lili
Chugh, Yashasvi
et al.

Publication Date
2016-08-01

DOI
10.1111/echo.13231

Peer reviewed

DOI:10.1111/echo.13231
Echocardiography

ORIGINALINVESTIGATION

Transcranial Doppler: Does Addition of Blood to Agitated Saline Affect Sensitivity for Detecting Cardiac Right-to-Left Shunt?

Mohammad Khalid Mojadidi, M.D.,* Lili Zhang, M.D.,†Yashasvi Chugh, M.D.,†Parham Eshtehardi, M.D., F.A.H.A.,‡Ninel Hovnanians, M.D.,†Rubine Gevorgyan, M.D.,§Sanaullah Mojaddedi, B.S.,* Nariman Nezami, M.D.,–Muhammad Omer Zaman, M.D.,** Asim Rafique, M.D.,§Pedro A. Villablanca, M.D., M.Sc.,†and Jonathan M. Tobis, M.D.,F.A.C.C.§

*Division of Cardiology, University of Florida, Gainesville, Florida;†Division of Cardiology, Montefiore Medical Center and Jacobi Medical Center, Albert Einstein College of Medicine, New York, New York;‡Division of Cardiology, Emory Clinical Cardiovascular Research Institute (ECCRI), Emory University School of Medicine, Atlanta, Georgia;§Program in Interventional Cardiology, Division of Cardiology, David Geffen School of Medicine, University of California at Los Angeles, Los Angeles, California;¶Department of Radiology and Biomedical Imaging, Yale University School of Medicine, New Haven, Connecticut; and **Department of Medicine, Crozer-Chester Medical Center, Chester, Pennsylvania

Background: Transcranial Doppler (TCD) with agitated saline has been shown to be an alternative for the detection of right-to-left shunts (RLS) with similar diagnostic accuracies as transesophageal echocardiography (TEE). It is hypothesized that the addition of blood to agitated saline increases the sensitivity of TCD for the detection of RLS. The aim of this meta-analysis was to determine whether agitated saline with blood increases the sensitivity of TCD for the detection of RLS compared to agitated saline alone and other contrast agents. Method: A systematic review of Medline, Cochrane, and Embase was per- formed to look for all prospective studies assessing intracardiac RLS using TCD compared with TEE as the reference; both tests were performed with a contrast agent and a maneuver to provoke RLS in all studies. Results: A total of 27 studies (29 comparisons) with 1,968 patients met the inclusion criteria. Of 29 comparisons, 10 (35%) used echovist contrast during TCD, 4 (14%) used a gelatin-based solution, 12 (41%) used agitated saline, and 3 (10%) utilized 2 different contrast agents. The addition of blood to agitated saline improved the sensitivity of TCD to 100% compared to agitated saline alone (96 %sen- sitivity, P=0.161), echovist (94% sensitivity, P=0.044), and gelatin-based solutions (93% sensitivity, P=0.041). Conclusion: The addition of blood to agitated saline improves the sensitivity of TCD for the detection of RLS to 100% when compared to other conventional contrast agents; these findings sup- port the addition of blood to agitated saline during TCD bubble studies. (Echocardiography 2016;00:1–9)

Keywords: right-to-left shunt, patent foramen ovale, transcranial Doppler, transesophageal echocardiogram

Patent foramen ovale (PFO) is a congenital heart defect that is a result of incomplete fusion of the septum primum and septum secundum.[1] Through transient right-to-left shunting (RLS), a PFO may serve as a conduit for paradoxical embolic strokes or transient ischemic attacks.[2] Although the CLOSURE,[3] RESPECT,[4] and PC[5] trials failed to meet their primary endpoints by intention-to-treat analysis,

Funding Sources: None Address for correspondence and reprint requests: Mohammad Khalid Mojadidi, M.D., Division of Cardiology, University of Florida, Gainesville, FL, 1600 SW Archer Road, North Tower, Rm 430, Gainesville, FL 32610-0277. Fax: +352.392.3606; E-mail: mkmojadidi@gmail.com

recent meta-analyses of these trials and observational studies suggest that PFO occluding devices may reduce the recurrence of stroke and transient ischemic attack comparedtomedical treatment in patients with cryptogenic stroke.[6,7]While contrast transesophageal echocardiogram (TEE) is considered by manyasthe gold standard for diagnosing PFO,[8]con- trast transcranial Doppler (TCD) is an alternative for the detection of RLS with similar diagnostic accuracies asTEE.[9]

It is hypothesized that TCD using agitated saline with blood produces a higher sensitivity for the detection of RLS compared to agitated saline alone.[10]Utility of agitated salinewith

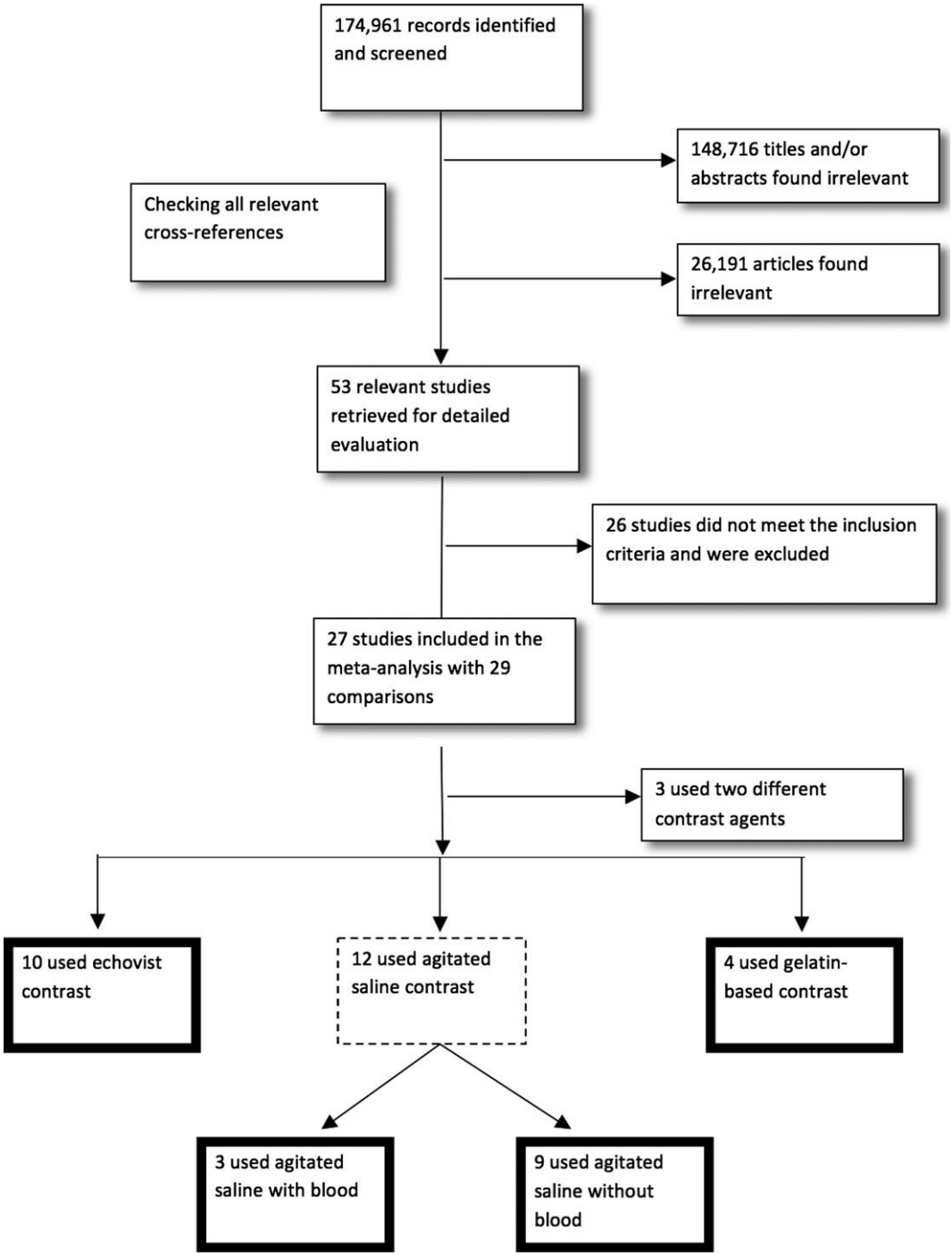

Figure 1.Selection of studies.

blood has also been observed to increasethesensitivity of TTE harmonic imagingcomparedto agitated saline alone for the detectionofRLS.[11]The Consensus Conference of Venice has outlined certain key guidelines for perform- ing a TCD bubble study including use ofan18-gauge needle in the cubital vein, preferen- tial utilization of agitated saline as thecontrast

agent, and application of the Valsalvamaneu-ver as the provocation maneuver for greater than ten seconds.[12]While these guidelines are based on data derived from older observational studies, institutional variations in methodology continue to exist. The Consensus Conference of Venice and newer practice guidelinesforTCD[13]havenotde lineatedadifference

between use of agitated saline with or without blood.

In a recent meta-analysis, a review of 27stud-ies was conducted to determine the accuracyofTCD for the detection of RLS. Thisanalysisdemonstrated that there was no significant differ- ence in sensitivity or specificity when different contrast agents (agitated saline, echovistandgelatin-based solutions) were utilized.[9]Theaimof the current review was to expand on ourpriormeta-analysis of TCD to determine whetheragi-tated saline with blood produces a higher sensi- tivity compared to agitated saline aloneandother contrastagents.

Methods:

A comprehensive systemic search of Medline, Cochrane, and Embase was conducted by the authors to look for all the prospective studies assessing for intracardiac RLS using TCD bubble study with subsequent confirmation by TEE bub- ble study as the reference standard. The search was completed in August 2013. Identified studies were analyzed by 3 independent reviewers for preset inclusion criteria which encompassed (1) original prospective studies, (2) subjects'age greater than 18 years, (3) studies with at least 20 subjects, (4) utilization of a contrast agentandprovocation maneuver to calculate TCD andTEEaccuracies, and (5) availability of completedatato calculate diagnostic accuracies (Fig. 1).Forstudies that compared different TCD protocols (such as comparing accuracy of different typesofcontrast) and also provided the variables tocal-culate the different accuracies (i.e. true positive, false positive, false negative, and true negative), then each methodology was considered asepa-rate comparison in thefinal analysis. A sensitivity analysis was then performed to demonstrate the effect of varying methodologies on accuracyofTCD. The methods of the study are describedinmore detailelsewhere.[9]

Statistical Analysis:

Meta-analysis of diagnostic accuracy variables was performed using Meta-DiSc software(ver-sion 1.4).[14]Cochran Q statistic and inconsistency index (I^2) were calculated to assess between-study heterogeneity and between-study inconsis- tency with statistical significance defined by $P<0.10$. Due to anticipated inter-study hetero-geneity, a random effects analysismodel(DerSimonian–Laird estimator)[15]was utilized becauseitprovidesmoreconservativeestimates

TABLE I

Sensitivity Analysis of TCD Stratifying for Agitated Saline with and without Blood

Parameter	No. of Studies	No. ofPatients	Sensitivity(95% CI)	Specificity (95%CI)	*LR+(95%CI)	*LR−(95%CI)
1: Saline-blood versus salineonly						
Saline-blood	3	139	1(0.90,1.00)	0.83(0.74,0.89)	6.55(1.70,25.29)	0.05 (0.01,0.24)
Saline only	9	731	0.96 (0.93, 0.98)	0.84 (0.80, 0.88)	5.798 (3.00, 11.19)	0.049 (0.02, 0.12)
P-value			0.16	0.82	0.91	0.99
2: Saline-blood versus echovist						
Saline-blood	3	139	1 (0.90, 1.00)	0.83 (0.74, 0.89)	6.55 (1.70, 25.29)	0.05 (0.01, 0.24)
echovist	10	616	0.94 (0.90, 0.96)	0.87 (0.83, 0.90)	9.98 (4.00, 24.92)	0.114 (0.07, 0.18)
P-value			0.04	0.34	0.67	0.32
3: Saline-blood versus gelatin						
Saline-blood	3	139	1 (0.90, 1.00)	0.83 (0.74, 0.89)	6.55 (1.70, 25.29)	0.05 (0.01, 0.24)
gelatin	4	266	0.93 (0.87, 0.96)	0.93 (0.87, 0.97)	10.190 (4.57, 22.72)	0.103 (0.054, 0.20)

P-value			0.04	0.03	0.63	0.44
4: Saline only versus echovist						
Saline only	9	731	0.96 (0.93, 0.98)	0.84 (0.80, 0.88)	5.80 (3.01, 11.19)	0.05 (0.02, 0.12)
echovist	10	616	0.94 (0.90, 0.96)	0.87 (0.83, 0.90)	9.98 (4.00, 24.92)	0.11 (0.07, 0.18)
P-value			0.32	0.27	0.47	0.08
5: Saline only versus gelatin						
Saline only	9	731	0.96 (0.93, 0.98)	0.84 (0.80, 0.88)	5.80 (3.01, 11.19)	0.05 (0.02, 0.12)
gelatin	4	266	0.93 (0.87, 0.96)	0.93 (0.87, 0.97)	10.19 (4.57, 22.72)	0.10 (0.05, 0.20)
P-value			0.25	0.01	0.39	0.23

*LR = positive likelihood ratio; LR = negative likelihood ratio; CI = confidence interval.

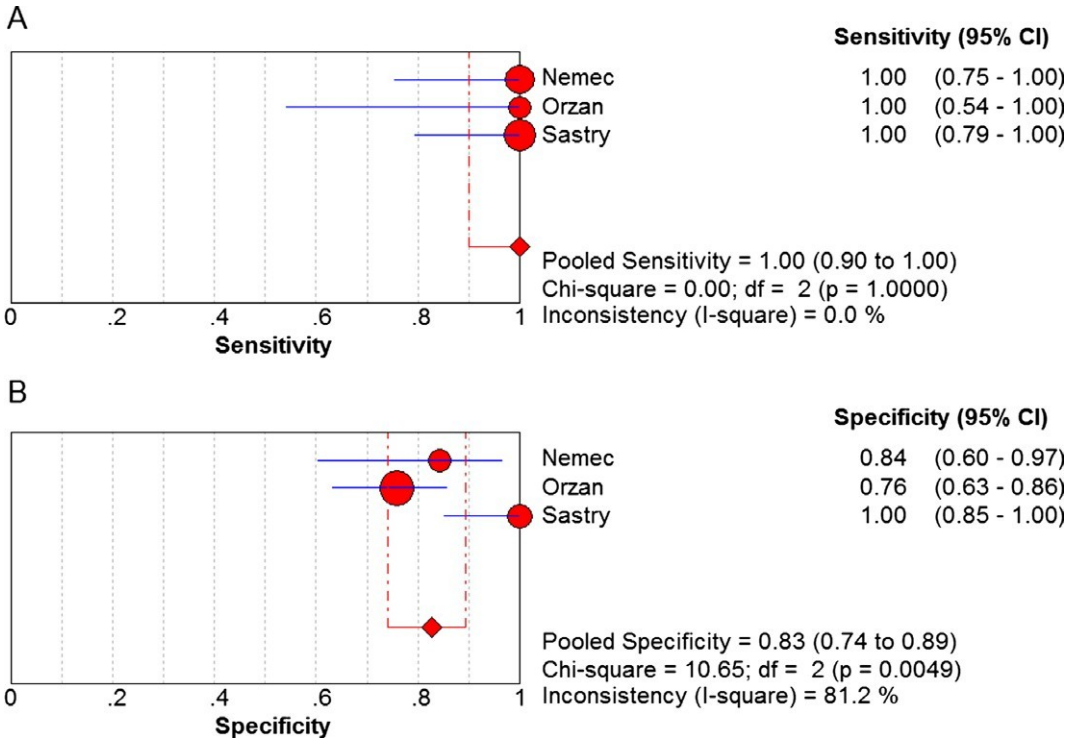

Figure 2. A,B. Sensitivity and specificity forest plots for studies that utilized agitated saline with blood.

of the pooled data. Subgroups were constructed only when≥3 studies could be included. Hetero- geneity of diagnostic accuracy betweensub-groups was assessed by Cochran's Q testandinconsistency index (I^2) with a random effect model.[15]The"Metan"package in Stata, version 12 (StataCorp LP, College Station, TX, USA)wasused in the subgroup analysis. Values of95%confidence intervals (CI) were used for all pooled data, all P-values are two tailed, and an adjusted P-value of<0.05 was considered statisticallysig- nificant unless otherwisespecified.

Results:

Of174,961articlesidentified,27studiesmettheinclusion criteria.[16–42]Two studies compared 2 different TCD protocols; thefinal meta-analysis thereforeconsistedof29comparisons.Ofthe29comparisons, 10 (35%) used echovist contrast during TCD,[20,21,24–26,29–33]4 (14%) used a gela- tin-based solution,[18,20,27,40]12 (41%) usedagi- tated saline,[16,18,23,32,34,37,38,40–42]and 3(10%) utilized 2 different contrast agents.[22,27,28]A fur- ther review of the 12 studies that used agitated saline revealed that 3 of 12 utilized agitatedsal-ine with blood[16,38,41]and 9 of 12 utilized agi- tated saline without blood. Figure 1 describes the study selection method with breakdownofthe included studies by contrastused.

A total of 731 patients (mean age 50;53%male) received agitated saline alone, 139 patients (mean age 46; 50% male) received agitatedsal-ine with blood, 616 patients (mean age 46;59%male) received echovist, and 266 patients(meanage 50.5; 55% male) received gelatin-basedsolu-tions. Before stratifying for agitated saline con- trast with and without blood, there wasnosignificant difference in diagnostic accuracies when agitated saline, echovist, and gelatin-based solutions werecompared.[9]

Table I describes the results of the sensitivity analysis after stratifying for agitated salinewithand without blood. Although the additionofblood to agitated saline increased the sensitivity of TCD for the detection of RLS compared toagi-tated saline alone (from 96% to 100%), thiswasnot statistically significant (P=0.16). Therewasno significant difference in specificity, positive likelihood ratio (LR+), and negative likelihood ratio (LR) comparing agitated saline withandwithout blood (P=NS). Agitated salinewithblood increased the sensitivity of TCDwhencompared to echovist (from 94% to100%,P=0.04) without compromising specificity,LR+,and LR (P=NS). Compared to gelatin-based solutions, agitated saline with blood had asuper-ior sensitivity (100% vs. 93%, P=0.041) butaninferior specificity (83% vs. 93%), P=0.03);

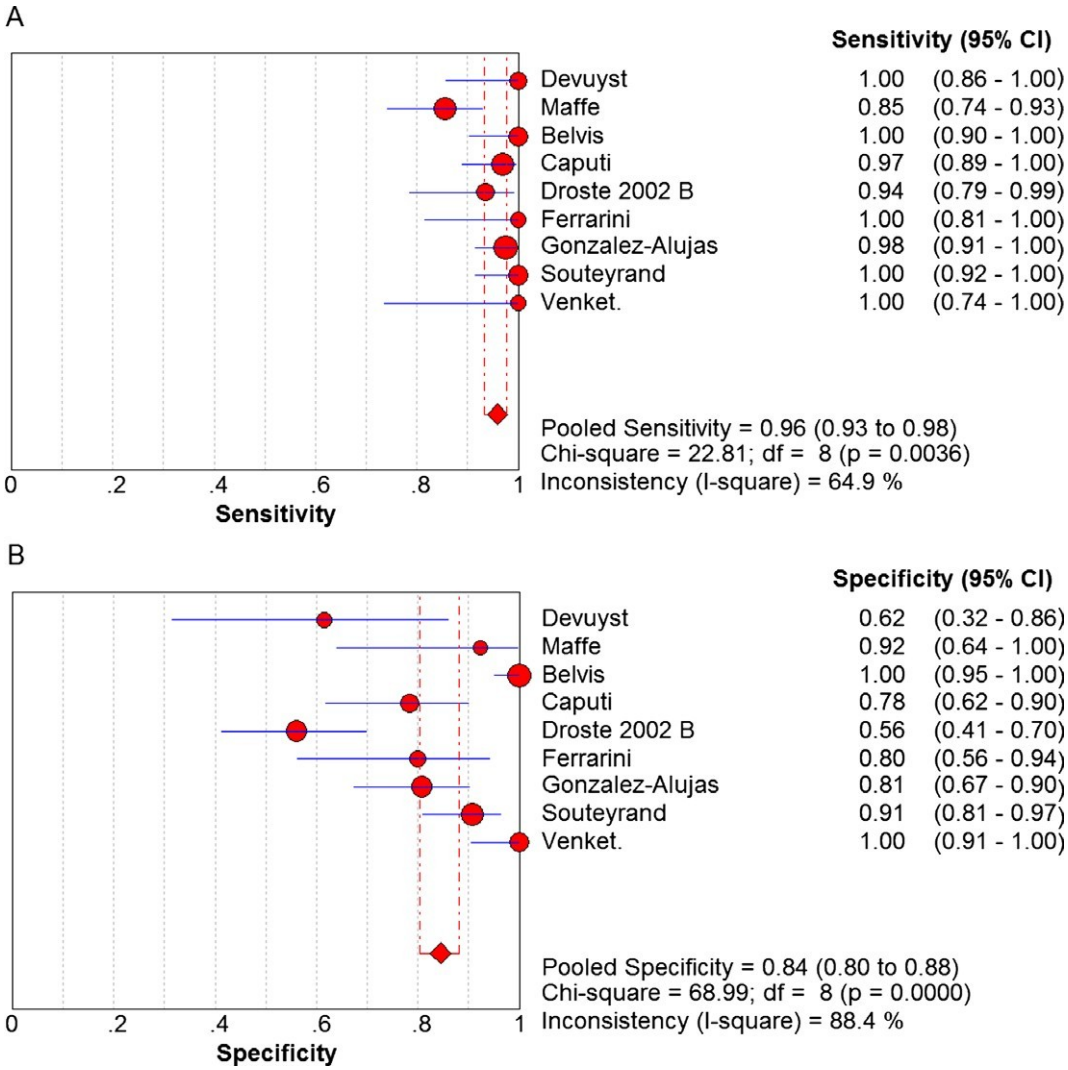

Figure 3. A,B.Sensitivity and specificity forest plots for studies that utilized saline only.

there was no difference in LR+and LRwhencomparing the two contrast agents (P=NS).There was no difference in sensitivity,specificity,LR+, and LR when comparing agitated saline alone to echovist (P=NS). Compared to gelatin- based solutions, agitated saline alone hadaninferior specificity (84% versus 93%, P=0.006) for the detection of RLS; there was, however,nodifference in sensitivity, LR+, and LR (P=NS).Figures 2–5 illustrate the sensitivity and speci-ficity forest plots for the different contrastagentsutilized.

Discussion:

Our study demonstrates that the addition of blood to agitated saline contrast improves the sensitivity of TCD to 100% compared to agitated saline alone (96% sensitivity, P=0.16), echovist

(94% sensitivity, P=0.044), and gelatin-based solutions (93% sensitivity, P=0.041).Thisincreased sensitivity was not countered by acom-promise in specificity, LR+, or LR when agitated saline with blood was compared to agitatedsal-ine alone and echovist; however, there wasadecreased specificity when compared to gelatin. To our knowledge, this is thefirst meta-analysis that compares the diagnostic accuracy ofTCDfor the detection of RLS using agitated salinewithblood compared to agitated saline aloneandother contrastagents.

Lange et al. demonstrated that a TCD bubble study utilizing agitated saline withbloodgenerates more positive tests with highershuntgrades and longer embolic tract durationsthanagitatedsalinealonewhenmiddlecerebralarter-ies were considered independently.[43]However,

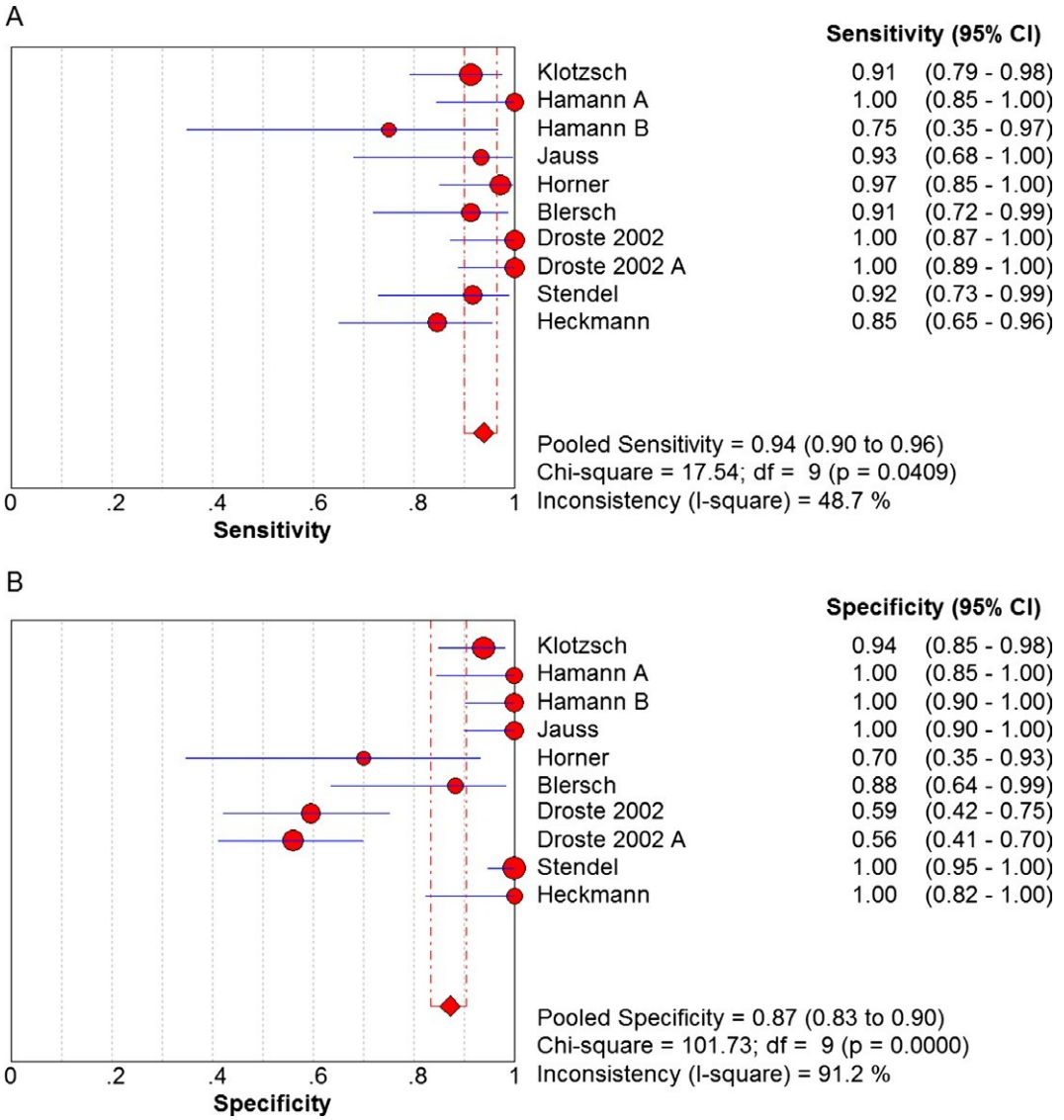

Figure 4. A,B.Sensitivity and specificity forest plots for studies that utilized echovist.

the study was limited as it did not compare thediagnostic accuracies of the two contrast mix-tures to a reference standard such as TEE bubblestudy or right heart catheterization. Prior studieshave demonstrated that combining the patient'sblood with the contrast agent increases the num-ber of microbubbles within a given volume,which maintain a constant size when visualizedusing a hemocytometer.[10]The increased numberof microbubbles detected at the level of the mid-dle cerebral arteries with TCD may explain theincreased sensitivity when utilizing agitated salinewith blood. In this meta-analysis, we observed anincreased sensitivity of TCD to 100% using salinewith blood which is supportive of this hypothesis.Compared to other contrast agents, agitatedsaline has the advantage of its low cost and easy

availability. The addition of patients'ownblood(ranging from a drop to 4 ml)[16,38,41]to the agi- tated saline mixture is safe and inexpensive, allowing the detection of a larger numberofmicrobubbles during the bubble study.Giventhat the increased sensitivity of agitated saline with blood has been demonstrated in boththisstudy utilizing TCD and in other studiesusingTTE,[11]saline with blood may be the superior con- trast in all bubblestudies.

TTE is the most commonly used modalityfordetecting intracardiac RLS due to its cost-effec- tiveness and easy availability. Due totheposterior location of the atria, TTE images oftheseptum often have a low resolution.Forenhanced imaging, the subcostal (subxyphoid) four-chamber view is often utilized.However,

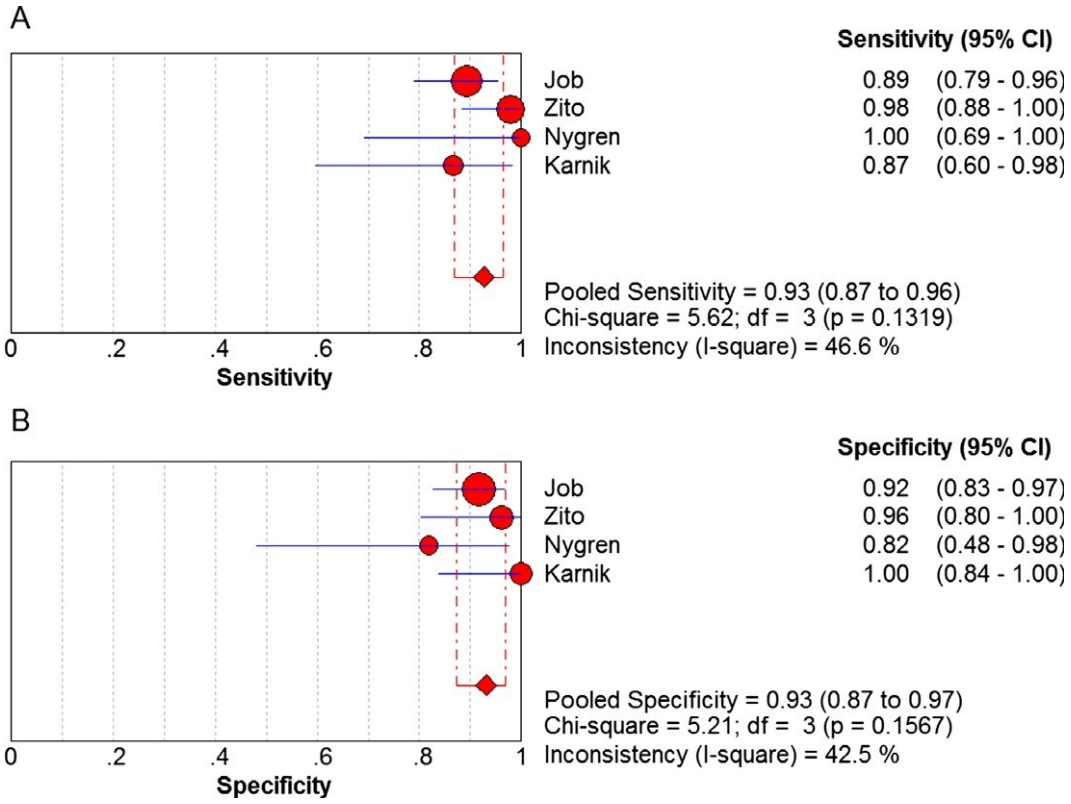

Figure 5. A,B.Sensitivity and specificity forest plots for studies that utilized gelatin-based solutions.

during a Valsalva maneuver, the inflatinglungsand shifting diaphragm often lead to a brieflossof image, usually when the agitated salinehasalready been introduced and bubbles arecrossing the septum. Although cost-effectiveandcommonly used for diagnosing intracardiacRLS,TTE has a low sensitivity.[44,45]In addition, the differentiation between intracardiac and intrapul- monary RLS can be difficult using the standard TTE technique. A recent meta-analysisofprospective studies comparing fundamentalTTEto TEE as the reference demonstrated a sensitivity of 46% and specificity of 99%.[46]The use of sec- ond harmonic imaging with TTE hasnowbecome standard in most centers. Harmonic imaging allows better visualization of a PFOanddifferentiation of the source of RLS (interatrial) septum vs. pulmonary veins). In onerecentstudy, TTE with second harmonicimagingincreased the sensitivity of TEE to 90.5%.[11]However, even with enhanced TTE imaging,TCDbubble study has a superior sensitivity of 97%forthe detection of intracardiac RLS[9]as TCD is not limited by potential poor echo windowsandpossible loss of imaging during the Valsalva maneuver.

TCDislimitedbyitsinabilitytovisualizethe atrial septal anatomy and inability todifferentiate

between cardiac and pulmonary RLS.[11,44]Due to its low cost, good safety profile, and highsen-sitivity, we recommend TCD bubble studyusingagitated saline with blood as an initial screening test for suspected RLS followed by TEEbubblestudy as a confirmatorytest.

Limitations:

Limitations of this meta-analysis includetheheterogeneity of the included studies andthelack of studies utilizing power M-modeTCD.Power M-mode TCD has been reported tohavea higher sensitivity than older single-gatedTCDsfor the diagnosis of RLS when catheterization was used as the reference.[47]In addition, the higher sensitivity of agitated saline withbloodcompared to agitated saline alone wasnotfound to be statistically significant; thismayhave been due to a lack of statisticalpowerconsidering there were fewer studies utilizing agitated saline with blood (only 3 studiescom-pared to 9 studies using saline alone)withfewer patients (139 patients compared to731patients using saline alone). Finally, as the sensi- tivity of the other methods is already high,itwould be difficult to show a statistical differ-ence, even though saline with blood had100%sensitivity.

Conclusion:

Utility of agitated saline with blood improvesthesensitivity of TCD to 100% when comparedtoother contrast agents. Considering that theaddi-tion of a patient's blood to the agitated saline mixture is easy to perform, does not increase cost, and adds minimal to no extra time totheprocedure, ourfindings support the addition of blood to agitated saline during TCDbubblestudies.

Disclosures:

Dr. Tobis is a consultant for St. Jude Medical, Inc. and W.L. Gore, Inc. All other authors have noth- ing to disclose.

References

1. DattiloPB,KimMS,CarrollJD:Patentforamenovale. *Cardiol Clin*2013;31:401–415.
2. Jones HR, Caplan LR, Come PC, et al: Cerebral emboliofparadoxical origin.*Ann Neurol1983;13:314*–319.
3. Furlan AJ, Reisman M, Massaro J, et al: Closure or medical therapy for cryptogenic stroke with patent foramenovale.*N Engl J Med2012;366:991*–999.
4. Carroll JD, Saver JL, Thaler DE, et al: Closure ofpatentforamen ovale versus medical therapy after cryptogenic stroke.*N Engl J Med2013;368:1092*–1100.
5. Meier B, Kalesan B, Mattle HP, et al: Percutaneous closure of patent foramen ovale in cryptogenic embolism.*NEnglJ Med2013;368:1083*–1091.
6. Agarwal S, Bajaj NS, Kumbhani DJ, et al: Meta-analysisoftranscatheter closure versus medical therapy forpatentforamen ovale in prevention of recurrent neurological events after presumed paradoxical embolism.*JACCCardiovasc Interv2012;5:777*–789.
7. Rengifo-Moreno P, Palacios IF, Junpaparp P, et al:Patentforamen ovale transcatheter closure vs. medical therapy on recurrent vascular events: a systematic reviewandmeta-analysis of randomized controlled trials.*Eur HeartJ*2013;34:3342–3352.
8. Pearson AC, Labovitz AJ, Tatineni S, et al: Superiorityof transesophageal echocardiography in detecting car-diac sources of embolism in patients with cerebralischemia of uncertain etiology.*J Am CollCardiol*1991;17:66–72.
9. Mojadidi MK, Roberts SC, Winoker JS, et al: Accuracyof transcranial Doppler for the diagnosis of intracar-diac right-to-left shunt: A bivariate meta-analysisofprospective studies.*JACC CardiovascImaging*2014;7:236–250.
10. Shariat A, Yaghoubi E, Nemati R, et al: Comparison of agi- tated saline mixed with blood to agitated saline alone in detecting right-to-left shunt during contrast- transcranial Doppler sonography examination.*Acta Neurol Taiwan*2011;20:182–187.
11. Mojadidi MK, Winoker JS, Roberts SC, et al:Two-dimen-sionalechocardiographyusingsecondharmonicimaging for the diagnosis of intracardiac right-to-lefy shunt:ameta-analysis of prospective studies.*Int J CardiovascImaging2014;30:911*–923.
12. Jauss M, Zanette E: Detection of right-to-left shuntwithultrasound contrast agent and transcranial Doppler sonography.*Cerebrovasc Dis2000;10:490*–496.
13. Alexandrov AV, Sloan MA, Tegeler CH, et al: Practice standards for transcranial Doppler (TCD) ultrasound.Part II. Clinical indications and expected outcomes.*J Neu-roimaging*2012;22:215–224.

14. Zamora J, Abraira V, Muriel A, et al: Meta-DiSc: Asoft-ware for meta-analysis of test accuracy data.*BMCMedRes Methodol2006;6:31.*
15. BöhningD,MalzahnU,DietzE,etal:Somegeneral points in estimating heterogeneity variancewiththe DerSimonian-Laird estimator.*Biostatistics*2002;3:445–457.
16. Nemec JJ, Marwick TH, Lorig RJ, et al: Comparisonoftranscranial Doppler ultrasound and transesophageal contrast echocardiography in the detection of interatrial right-to-left shunts.*Am J Cardiol1991;68:1498*–1502.
17. KarnikR,StöllbergerC,ValentinA,etal:Detectio nof patent foramen ovale by transcranial contrast Doppler ultrasound.*Am J Cardiol*1992;69:560–562.
18. Venketasubramanian N, Sacco RL, Di Tullio M, et al:Vas-cular distribution of paradoxical emboli bytranscranialDoppler.*Neurology 1993;43:1533*–1535.
19. Job FP, Ringelstein EB, Grafen Y, et al: Comparison oftranscranial contrast Doppler sonography and trans-esophagealcontrastechocardiogra phyforthedetection of patent foramen ovale in young stroke patients.*AmJCardiol*1994;74:381–384.
20. JaussM,KapsM,KeberleM,etal:Aco mparisonoftrans- esophageal echocardiography and transcranial Doppler sonography with contrast medium for detectionofpatent foramen ovale.*Stroke1994;25:1265*–1267.
21. KlötzschC,JanssenG,BerlitP:Transesophage alechocar-diographyandcontrast-TCDinthedetectionofapatent foramenovale:Experienceswith111pat ients.*Neurology*1994;44:1603–1606.
22. AlbertA,MüllerHR,HetzelA:Optimizedtrans cranial Doppler technique for the diagnosis of cardiac right-to-left shunts.*J Neuroimaging*1997;7:159–163.
23. Devuyst G, Despland PA, Bogousslavsky J, et al: Comple-mentarity of contrast trans-cranial Doppler andcontrasttrans-esophageal echocardiography for the detectionofpatent foramen ovale in stroke patients.*EurNeurol*1997;38:21–25.
24. Horner S, Ni XS, Weihs W, et al: Simultaneous bilateral contrast trans- cranial Doppler monitoring in patientswith intracardiac and intrapulmonary shunts.*J NeurolSci*1997;150:49–57.
25. HamannGF,Schätzer-KlotzD,FröhligG,etal:Femoral injection of echo contrast medium may increase the sen-sitivity of testing for a patent foramen ovale.*Neurology*1998;50:1423–1428.
26. Nygren AT, Jogestrand T: Detection of patent foramen ovalebytranscranialDopplerandcarotidduplexultra so-nography: A comparison with trans-oesophageal echocar-diography.*Clin Physiol1998;18:327*–330.
27. DrosteDW,ReisenerM,Kem'enyV,etal:Contrasttran-scranial Doppler ultrasound in the detection of right- to- left shunts. Reproducibility, comparison of 2 agents, and distribution of microemboli.*Stroke*1999;30:1014–1018.
28. Droste DW, Kriete JU, Stypmann J, et al: Contrasttran-scranial Doppler ultrasound in the detection of right-to- left shunts: Comparison of different procedures anddif-ferent contrast agents.*Stroke1999;30:1827*–1832.
29. Heckmann JG, Niedermeier W, Brandt-Pohlmann M, et al: Detection of patent foramen ovale. Transesophageal echocardiography and transcranial Doppler sonography with ultrasound contrast media are supplementary, not competing, diagnostic methods.*Med Klin (Munich)*1999;94:367–370.
30. StendelR,GrammHJ,Schröder K,etal:Transcranial Doppler ultrasonography as a screening techniquefordetection of a patent fo- ramen ovale before surgeryinthe sitting position.*Anesthesiology2000;93:971*–975.
31. BlerschWK,DraganskiBM,HolmerSR,etal:Transcra nial duplex sonography in the detection of patent foramen ovale.*Radiology2002;225:693*–699.

32. Droste DW, Jekentaite R, Stypmann J, et al: Contrast tran- scranial Doppler ultrasound in the detection of right-to- left shunts: Comparison of Echovist- 200 and Echovist-300, timing of the Valsalva maneuver, and general recommendations for the performance of the test.*Cere-brovasc Dis2002;13:235*–241.
33. Droste DW, Lakemeier S, Wichter T, et al: Optimizing the technique of contrast transcranial Doppler ultra- sound in thedetectionofright-to-leftshunts.*Stroke2002;33:2211*–2216.
34. Ferrarini G, Malferrari G, Zucco R, et al: Highprevalenceof patent foramen ovale in migraine with aura.*JHead-ache Pain2005;6:71*–76.
35. Belv'ısR,LetaRG,Mart'ı-F'abregasJ,etal:Almostperfect concordancebetweensimultaneoustranscranialDopplerandtransesophagealechocardiographyinthequantifica-tion of right-to-left shunts.*J Neuroimaging*2006;16: 133–138.
36. SouteyrandG,MotreffP,LussonJR,etal:Comparisonoftransthoracicechocardiographyusingsecondhar-monicimaging,transcranial Doppler and transesophageal echocardiography for the detection of patent foramenovaleinstrokepatients.*EurJEchocardiogr2006;7:147*–154.
37. CaputiL,CarrieroMR,FalconeC,etal:Transcranial Dop- plerandtrans-esophagealechocardiography:Com-pari-sonofbothtechniquesandprospectiveclinicalrelevance of trans- cranial Doppler in patent foramen ovale detec-tion.*J Stroke Cerebrovasc Dis2009;18:343*–348.
38. Sastry S, MacNab A, Daly K, et al: Transcranial Doppler detection of venous-to-arterial circulation shunts: Criteria for patent foramen ovale.*J Clin Ultrasound*2009;37:276–280.
39. Zito C, Dattilo G, Oreto G, et al: Patent foramen ovale: Comparisonamongdiagnosticstrategiesincrypto-genicstroke and migraine.*Echocardiography2009;26:495*–503.
40. Maff'eS,DellavesaP,ZenoneF,etal:Transthoracicsec-ond harmonic two- and three-dimensionalechocardiog-raphy for detection of patent foramen ovale.*EurJEchocardiogr2010;11:57*–63.
41. Orzan F, Liboni W, Bonzano A, et al: Follow-up of resid- ualshuntafterpat-entforamenovaleclosure.*ActaNeu-rol Scand*2010;122:257–261.
42. Gonz'alez-AlujasT,EvangelistaA,SantamarinaE,etal: Diagnosis and quantification of patent foramen ovale. Which is the reference technique? Simultaneous study with transcranial Doppler, transthoracic and trans- esophageal echocardiography.*Rev Esp Cardiol*2011;64:133–139.
43. LangeMC,Z'etolaVF,Piovesan'EJ,etal:Salineversussal-ine with blood as a contrast agent for right-to-left shunt diagnosis by transcranial Doppler: Is there a significant difference?*J Neuroimaging*2012;22:17–20.
44. Mojadidi MK, Gevorgyan R, Tobis J: A ComparisonofMethods to Detect and Quantitate PFO: TCD, TTE,ICEand TEE. In: Amin Z, Tobis J, Sievert H, Carroll J (eds.):*Patent Foramen Ovale*. Springer: London, 2015, pp. 55–65.
45. Mojadidi MK, TobisJM: Patent foramen ovaleandatrial septal defect: Utility of alternativeimagingmodalities for the diagnosis ofpatent foramenovaleand atrial septal defect.*Echocardiography*2015;32: 1451–1452.
46. Mojadidi MK, Winoker JS, Roberts SC, et al: Accuracy of conventional transthoracic echocardiography forthediagnosisofintracardiacright-to-leftshunt:Ameta-ana- lysis of prospective studies.*Echocardiography*2014;31:1036–1048.
47. Spencer MP, Moehring MA, Jesurum J, et al: Power m-mode transcranial Doppler for diagnosis ofpatentforamen ovale and assessing transcatheter closure.*JNeu-roimaging2004;14:342*–349.