

# UCSF

## UC San Francisco Previously Published Works

### Title

Feasibility and Acceptability of Smartphone-Based Cervical Cancer Screening Among HIV-Positive Women in Western Kenya

### Permalink

<https://escholarship.org/uc/item/5k7721f1>

### Journal

JCO Global Oncology, 7(7)

### ISSN

2687-8941

### Authors

Mungo, Chemtai  
Osongo, Cirilus Ogollah  
Ambaka, Jeniffer  
et al.

### Publication Date

2021-12-01

### DOI

10.1200/go.21.00013

Peer reviewed

# Feasibility and Acceptability of Smartphone-Based Cervical Cancer Screening Among HIV-Positive Women in Western Kenya

Chemtai Mungo, MD, MPH<sup>1</sup>; Cirilus Ogollah Osongo, BA<sup>2</sup>; Jeniffer Ambaka, DipCM<sup>2</sup>; Magdalene A. Randa, MBChB<sup>2</sup>; Benard Samba, BSc<sup>2</sup>; Catherine A. Ochieng, BSc<sup>2</sup>; Emily Barker, MD<sup>3</sup>; Anagha Guliam<sup>4</sup>; Jackton Omoto, MBChB, MMed<sup>5</sup>; and Craig R. Cohen, MD, MPH<sup>6</sup>

**PURPOSE** Adjunct cervical cancer screening methods are under evaluation to improve the diagnostic accuracy of human papillomavirus (HPV)-based screening in low- and middle-income countries. We evaluated the feasibility and acceptability of smartphone-based cervicography among HPV-positive women living with HIV (WLWH) in Western Kenya.

**METHODS** HPV-positive WLWH of 25-49 years of age enrolled in a clinical trial (ClinicalTrials.gov identifier: NCT04191967) had digital images of the cervix taken using a smartphone by a nonphysician provider following visual inspection with acetic acid. All participants had colposcopy-directed biopsy before treatment. Cervical images were evaluated by three off-site colposcopists for quality, diagnostic utility, and assigned a presumed diagnosis. We determined the proportion of images rates as low, medium, or high quality, interobserver agreement using Cohen's Kappa statistic, and the off-site colposcopist's sensitivity and specificity for diagnosis of cervical intraepithelial neoplasia grade 2 or worse (CIN2+) compared with histopathology. Acceptability was evaluated using a questionnaire.

**RESULTS** One hundred sixty-four HPV-positive WLWH underwent cervicography during the study period. Mean age was 37.3 years. Images from the first 94 participants were evaluated by off-site colposcopists, with a majority (70.9%) rated as high quality. Off-site colposcopists had a sensitivity ranging from 21.4% (95% CI, 0.06 to 0.43) to 35.7% (95% CI, 0.26 to 0.46) and a specificity between 85.5% (95% CI, 0.81 to 0.90) to 94.9% (95% CI, 0.92 to 0.98) for diagnosis of CIN2+ based compared with histopathology. The majority of women, 99.4%, were comfortable having an image of their cervix taken as part of screening.

**CONCLUSION** Cervicography by a nonphysician provider as an adjunct to HPV-based screening among WLWH in a low- and middle-income country setting is feasible and acceptable. However, low sensitivity for diagnosis of CIN2+ by off-site expert colposcopists highlights the limitations of cervicography.

JCO Global Oncol 7:686-693. © 2021 by American Society of Clinical Oncology

Creative Commons Attribution Non-Commercial No Derivatives 4.0 License 

## INTRODUCTION

Although cervical cancer is preventable, in 2018, an estimated 570,000 new cases occurred, with 90% in low- and middle-income countries (LMICs).<sup>1</sup> Cervical cancer is an AIDS-defining malignancy, and women living with HIV (WLWH), the majority of whom live in LMICs, are at increased risk because of high incidence and persistence of high-risk human papillomavirus (HPV) infection, the causative agent.<sup>2</sup> Compared to HIV-negative women, WLWH are up to six times more likely to develop cervical cancer,<sup>3</sup> making prevention efforts among this group particularly urgent. In 2013, the WHO recommended cervical cancer screening using visual inspection with acetic acid (VIA) or HPV testing in LMICs, followed by immediate treatment, in a screen-and-treat strategy, to reduce loss to follow-up.<sup>4</sup>

However, screening based on VIA is limited by significant variation in sensitivity across studies (41%-79%<sup>5</sup> v 22%-74%<sup>6</sup>) and meta-analyses (41%-92%<sup>7</sup>) depending on the quality of personnel training and experience.<sup>8</sup> Unlike VIA, HPV testing offers a more reproducible test with superior sensitivity for detecting precancerous lesions.<sup>9</sup> In the 2018 global call for cervical cancer elimination, the WHO recommends HPV testing as a primary screening method,<sup>10</sup> listing it as a Best Buy for noncommunicable disease prevention.<sup>11</sup> HPV screening, although increasingly feasible through self-sampling,<sup>12</sup> is limited by poor specificity, as it cannot separate transient from persistent infections, leading to overtreatment in a screen-and-treat approach.<sup>9,13</sup> This lack of specificity highlights a need for adjunct screening or triage methods that increase

## ASSOCIATED CONTENT

### Protocol

Author affiliations and support information (if applicable) appear at the end of this article.

Accepted on March 9, 2021 and published at [ascopubs.org/journal/go](https://ascopubs.org/journal/go) on May 17, 2021; DOI <https://doi.org/10.1200/GO.21.00013>

## CONTEXT

### Key Objective

Is smartphone-based cervicography by a nonphysician provider feasible and acceptable to HIV-positive women as an adjunct to human papillomavirus-based screening in low-resource settings?

### Knowledge Generated

In this study in Kenya, we find cervicography by a nonphysician provider to be highly acceptable. The majority of women were comfortable with cervicography as part of screening, and 97% reported that seeing an image of their cervix improved their understanding of the screening process. Most of the images (taken after application of acetic acid) were rated as high (70.9%) or medium quality (26.6%) by three off-site colposcopy experts and were of diagnostic utility for cervical intraepithelial neoplasia (CIN). However, off-site experts had low sensitivity for CIN2 grade 2 or worse, ranging from 21.4% to 35.7%, compared with gold-standard histopathology.

### Relevance

Although feasible, use of naked-eye cervicography as a triage test for human papillomavirus-positive women would result in substantial loss of sensitivity for CIN2+.

specificity within the screen-and-treat approach without a substantial decrease in sensitivity or increase in cost or infrastructure requirements.

Cervicography, also known as digital colposcopy, involves digital imaging of the cervix and has been investigated as an adjunct method for cervical cancer screening in LMICs.<sup>14-18</sup> Cervicography can improve the quality of VIA through magnification by offering higher resolution than the naked eye, supporting quality control efforts through periodic reviews of images,<sup>19</sup> as well as enabling long-distance consultation by expert colposcopists.<sup>16,19</sup> Unlike traditional colposcopes, which are expensive and require stable electricity, new smartphone-based mobile colposcopes have been developed for use in LMICs.<sup>14,20,21</sup> Smartphone-based imaging offers several advantages, including lower cost hence accessibility, user-friendly interfaces, high-definition cameras, and minimal maintenance requirements.<sup>22</sup> Pilot studies in LMICs suggest that cervicography may improve the sensitivity of VIA to diagnose high-grade precancerous lesions.<sup>19,23</sup> Additionally, recent evidence has demonstrated the feasibility of developing highly accurate automated algorithms for identifying high-grade precancer from cervical film camera images,<sup>24</sup> with the potential for implementation within cervical images taken using smartphones at the point of care.<sup>25</sup>

However, few studies have evaluated the feasibility and acceptability of cervicography by nonphysician providers as an adjunct to HPV screening among HIV-positive women in LMICs.<sup>15</sup> Evaluating acceptability in this high-risk population is crucial, given the role of HIV-associated stigma in affecting the uptake of medical interventions in sub-Saharan Africa.<sup>26,27</sup> In this study, we evaluate the feasibility of adjunct smartphone-based cervical cancer screening among WLWH in LMICs by evaluating the (1) acceptability of digital cervicography and (2) quality of digital cervical images taken by a nonphysician provider.

We also evaluate the diagnostic accuracy of off-site colposcopists for cervical intraepithelial neoplasia 2+ (CIN2+) from cervical images compared with gold-standard cervical histopathology.

## METHODS

This study took place between September 2019 and February 2020 at a Family AIDS Care & Education Services (FACES)-supported Ministry of Health HIV clinic in Kenya. Women of 25-65 years of age were offered cervical cancer screening using HPV testing of self-collected samples using the *careHPV* (Qiagen, Germantown, MD), which tests for 14 high-risk HPV types.<sup>28</sup> The WHO-recommended 'screen-and-treat' approach is implemented where all HPV-positive women are offered same-day treatment per WHO guidelines.<sup>4,29</sup> As part of a clinical trial (ClinicalTrials.gov identifier: [NCT04191967](https://clinicaltrials.gov/ct2/show/study/NCT04191967)), all HPV-positive women undergo colposcopy-directed biopsy for histopathology diagnosis before treatment. Eligibility criteria of this trial has previously been described,<sup>30</sup> which excluded pregnant women. In this analysis, HPV-positive women of 25-49 years of age participating in this clinical trial were included. Following VIA, a smartphone (Samsung J8, Seoul, South Korea) with a 16-megapixel camera was used to take a minimum of three images of the cervix within the Box application (Redwood City, CA). Images were taken at the same distance, approximately 3-5 cm from the speculum. An image was deemed satisfactory if it met the following criteria: no external genitalia were exposed, the speculum was not visible, the cervix was focused and centered on the image, the entire transformation zone was visible with no shadows, and there was minimal or no light reflection on the cervix.<sup>31</sup> Multiple images could be taken until three satisfactory images were obtained. Images were taken by a clinical officer with approximately 4-6 hours of hands-on cervicography training. Because of increased glare, no flash was used while taking images, and the zoom

function was limited to 1.5 times to reduce blurring. Each satisfactory image was then renamed with a unique participant identification code and saved onto the offline application. Participants were then shown the image of their cervix, highlighting abnormal areas if any, before treatment. The smartphone was used exclusively for the study. Cervical colposcopy was then performed using the Gynocular

colposcope (Gynius AB, Göteborg, Sweden) for magnified visualization of the squamocolumnar junction and identification of lesions, if any, for biopsy. A minimum of three colposcopy-directed cervical biopsies were obtained from any abnormal areas, or random four-quadrant biopsies were obtained if no lesions were visualized before treatment. At the end of the visit, a short survey was administered evaluating acceptability of cervicography. Cervical biopsies were stored in dilute formalin and transported to a registered pathologist at the University of Nairobi for analysis. Histopathology results were classified as negative, CIN1, CIN2, CIN3, or invasive carcinoma.

Cervical images were uploaded daily to a secure, web-based Box account via a wireless Internet connection. Participant data, including final histopathology diagnosis linked to the participant's unique image identification number, were recorded in a secure database. For this analysis, among the 164 women enrolled, images from the first 94 participants were analyzed. Study personnel reviewed the three cervical images of these participants and selected the single best image for expert review—using the aforementioned criteria. A survey with an embedded image from each participant was developed using KoBo Toolbox software (Cambridge, MA) and sent to three independent expert colposcopists—two gynecologic oncologists (one in Kenya and another in the United States) and a general gynecologist in Kenya, all with colposcopy experience ranging from 10 to 25 years each. Reviewers were blinded to pathology diagnosis. The survey was administered in person or online, per provider preference. In the survey, reviewers were asked to rate the quality of the images, whether they could make a diagnosis from it, and if so, what diagnosis they would assign. The images could be scored as being of low quality (the image is not in focus and most quadrants are not visible), medium quality (the image is slightly out of focus and most cervical quadrants are visible), or high quality (the image is in focus and all cervical quadrants are visible).<sup>21</sup> Among images thought to be of diagnostic utility, reviewers assigned a diagnosis of normal (no dysplasia), CIN1, or CIN2 or worse. Images were evaluated at a later date, and the results did not influence treatment decisions.

**TABLE 1.** Participant Characteristics of HPV-Positive WLWH Undergoing Image-Based Screening in Western Kenya

Variable	No. (%)
N = 164	
Age, years, mean ± SD	37.3 ± 6.6
Age group, years	
25-39	103 (62.8)
40-49	61 (37.2)
Marital status	
Single	20 (12.2)
Married	83 (50.6)
Widowed	37 (22.6)
Divorced or separated	24 (14.6)
Highest education level attained <sup>a</sup>	
None	0 (0.0)
Primary	88 (55.7)
Secondary	51 (32.3)
Post-secondary	19 (12.0)
Employment status	
Employed	135 (82.3)
Not employed	29 (17.7)
Parity, mean (SD)	3.0 (2)
Age at first sexual intercourse, mean (SD)	17.7 (2.9)
CD4 count, mean (SD)	448.6 (280.8)
Virally suppressed <sup>b</sup>	
Yes	155 (97.5)
No	4 (2.5)
Currently using contraception <sup>c</sup>	
Yes	104 (63.8)
No	59 (36.2)
Method of contraception <sup>d</sup>	
Implant	36 (37.1)
Injectable	32 (33.0)
Condoms	25 (25.8)
Other	4 (4.1)

Abbreviations: HPV, human papillomavirus; SD, standard deviation; WLWH, women living with HIV.

<sup>a</sup>Six with missing data.

<sup>b</sup>Five with missing data.

<sup>c</sup>One with missing data.

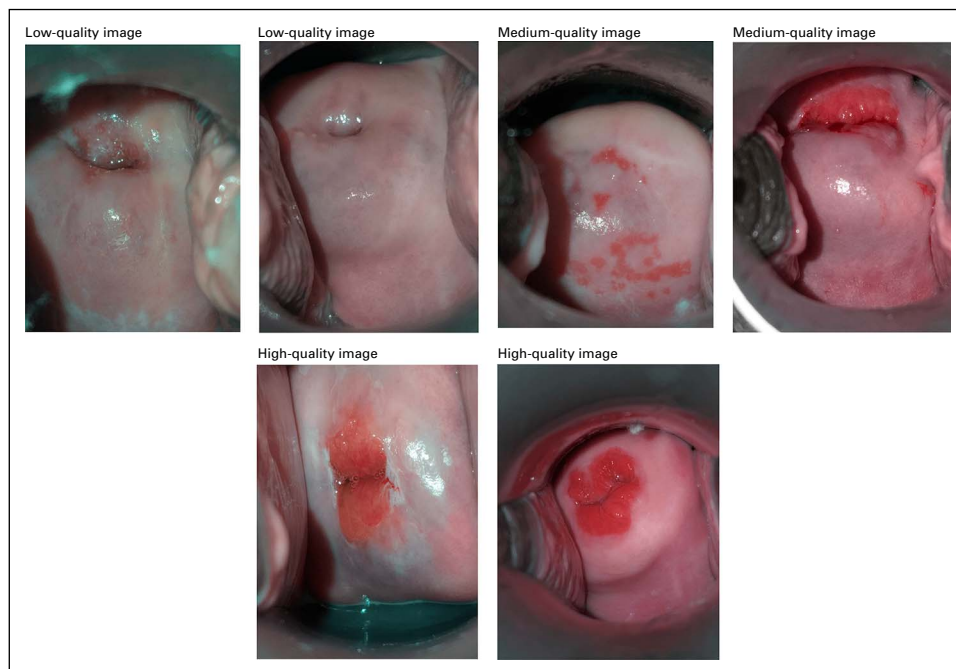
<sup>d</sup>Seven with missing data.

**TABLE 2.** Evaluation of the Quality and Diagnostic Utility of 94 Digital Images From HPV-Positive WLWH by Off-Site Expert Colposcopists

Observer	Low Quality	Medium Quality	High Quality	Diagnostic Utility
	No. (%)	No. (%)	No. (%)	No. (%)
Rater 1	1 (1.1)	45 (47.9)	48 (51.1)	81 (86.2)
Rater 2	1 (1.1)	23 (24.5)	70 (74.5)	94 (100.0)
Rater 3	5 (5.3)	7 (7.6)	82 (87.3)	70 (74.4)
Total	7 (2.5)	75 (26.6)	200 (70.9)	245 (86.9)

Abbreviations: HPV, human papillomavirus; WLWH, women living with HIV.

**FIG 1.** Examples of cervical images from HPV-positive WLWH rated as low, high, or medium quality. HPV, human papillomavirus; WLWH, women living with HIV.



Data were collected using REDCap and analyzed by Stata version 13.1 (StataCorp, College Station, TX). Clinical and demographic characteristics were obtained from participant interviews or abstracted from clinical data. Quantitative variables are expressed as means and standard deviations (SDs), whereas qualitative variables are expressed as proportions, unless otherwise stated. We determined the proportion of images rated as low, medium, and high quality, as well as those thought to be of diagnostic utility by each individual reviewer, as well as overall. We determined the interobserver agreement on image quality using Cohen's kappa ( $\kappa$ ) statistic, and its corresponding *P* values, comparing the observed and expected levels of agreement. Kappa statistics were interpreted as follows:  $\leq 0$  indicating no agreement, 0.01-0.20 none to slight agreement, 0.21-0.40 fair agreement, 0.41-0.60 moderate agreement, 0.61-0.80 substantial agreement, and 0.81-1.00 almost perfect agreement.<sup>32</sup> Among images with assigned diagnoses by the expert reviewers, we determined the sensitivity and specificity (and 95% CIs) of each reviewer's diagnosis of CIN2 or worse compared with the gold-standard histopathology. The institutional review boards of Maseno University and the University of California San Francisco approved this study.

## RESULTS

A total of 164 HPV-positive WLWH between ages of 25-49 years underwent cervicography at FACES between September 2019 and February 2020. The mean age was 37.3 years (SD, 6.6) (Table 1). Slightly more than half of the participants, 83 (50.6%), were married and 88 (55.7%) had at least a primary education. All participants were on antiretroviral therapy, with a mean CD4 count of 448.6 cells/mL (SD, 280.8) and 97.5% were virally suppressed ( $< 1,000$  copies/mL).<sup>33</sup> On average, between five and seven images were needed to be taken to obtain three images of satisfactory quality. Images from the first 94 participants were evaluated by three off-site colposcopists. Of 282 expected evaluations for image quality by all colposcopists, 280 (99.2%) evaluations were successfully submitted. The majority of images 200 (70.9%) were rated as high quality, ranging from 51% (rater 1) to 87.3% (rater 3) (Table 2). Seventy-five (26.6%) images were rated as medium quality and only seven (2.5%) images rated as low quality. The expert reviewers judged 245 (86.9%) of the images to be of sufficient quality to make a diagnosis, ranging from 74.4% (rater 3) to 100.0% (rater 2). The most common reason images were considered nondiagnostic was because of the inability to visualize the squamocolumnar junction. Figure 1 shows examples of images rated as low, high, or medium quality. The rate of agreement on the image quality between colposcopists and the corresponding kappa values ranged from none to slight agreement ( $\kappa = 0.06$ ) to fair agreement ( $\kappa = 0.23$ ) (Table 3). The overall (combined) kappa was 0.29 (data not shown), demonstrating lack of interobserver agreement on the quality of cervical images.

**TABLE 3.** Agreement and Kappa Values Between Colposcopists on the Quality of Cervical Images

Observer	Obtained Agreement %	Expected Agreement %	$\kappa$ Statistic	SE	<i>P</i>
Rater 1	58.51	49.75	0.17	0.09	.024
Rater 2	74.47	66.84	0.23	0.08	.001
Rater 3	51.06	48.17	0.06	0.06	.157

**TABLE 4.** Comparison of the Sensitivity and Specificity of Expert Reviewers for CIN2+ Compared With Gold-Standard Histopathology Among HPV-Positive WLWH

Observer	No. <sup>a</sup>	Sensitivity %	95% CI	No. <sup>a</sup>	Specificity %	95% CI
Rater 1	68	21.4	0.06 to 0.43	68	94.4	0.89 to 0.10
Rater 2	92	35.7	0.26 to 0.46	92	94.9	0.92 to 0.98
Rater 3	69	21.4	0.16 to 0.26	69	85.5	0.81 to 0.90

Abbreviations: CIN, cervical intraepithelial neoplasia; HPV, human papillomavirus; WLWH, women living with HIV.

<sup>a</sup>Number of images assigned a diagnosis by each rater.

We compared the expert colposcopists presumed diagnosis of CIN2+ based on the cervical images to the final histopathology diagnosis. Among the 94 participants, 68 (72.3%) had normal histology, 10 (10.6%) had CIN1, four (4.3%) had CIN2, 11 (11.7%) had CIN3, and one (1.1%) had invasive cervical carcinoma—thus, 16 (17.0%) had CIN2+. Expert colposcopists had a sensitivity of 21.4% (95% CI, 0.06 to 0.43) to 35.7% (95% CI, 0.26 to 0.46) and a specificity ranging from 85.5% (95% CI, 0.81 to 0.90) to 94.9% (95% CI, 0.92 to 0.98) for CIN2+ compared with gold-standard histopathology (Table 4). Figure 2 shows cervical images with histopathology diagnoses of CIN1 (Fig 2A), CIN2 (Fig 2B), CIN3 (Fig 2C), and invasive carcinoma (Fig 2D).

Following screening and treatment, participants were shown images of their cervix and asked questions about the acceptability of this method for screening (Table 5). The majority of women, 163 (99.4%), reported feeling comfortable with having an image of their cervix taken as part of screening, with 97.0% reporting that seeing an image of their cervix helped increased their understanding of the screening and treatment process. When asked, almost all women, 99.4%, said that they would recommend image-based screening to a friend.

## DISCUSSION

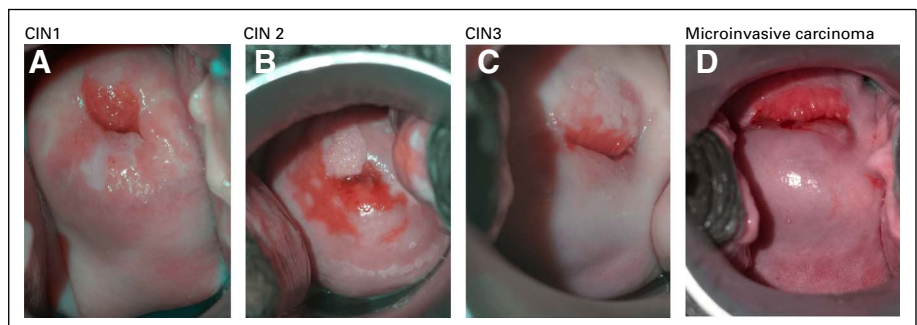
In this study, we sought to investigate the feasibility and acceptability of cervicography as an adjunct to HPV testing in a screen-and-treat program in an LMIC. We find high acceptability of cervicography as an adjunct screening test among HPV-positive WLWH in western Kenya. An overwhelming majority of women were comfortable with having an image of their cervix taken as part of screening and

reported that seeing an image of their cervix increased their understanding of the screening and treatment process and would recommend this screening method to a friend. In this real-world setting of cervical cancer screening done by a nonphysician provider in a primary care setting in an LMIC, we also find that the majority of cervical images taken during routine screening were judged to be of high or medium quality by off-site expert colposcopists and were of diagnostic utility for evaluating for the presence of cervical dysplasia. However, we find low sensitivity for diagnosis of CIN2+ by expert colposcopists from the cervical images when compared with gold-standard histopathology diagnosis, which if used for triage would result in substantial loss in sensitivity obtained from HPV screening.

Prior studies, although limited, have suggested that introduction of cervicography within routine cervical cancer screening programs in LMICs, most of which are led by nonphysicians, can improve diagnostic accuracy and support training and quality improvement efforts. Cervicography programs can also serve as a platform for incorporating technology-based screening like automated algorithms, which in demonstration studies have shown accuracy as high as 91% (95% CI, 89 to 93) for diagnosing CIN2+, higher than HPV tests or human experts.<sup>24</sup> Smartphones, which are increasingly accessible around the world,<sup>34</sup> have the ability to take high-quality images that can be easily shared using wireless connectivity, providing significant advantages over standard digital cameras.<sup>35</sup> To our knowledge, this is the first study to investigate the acceptability of cervicography during routine cervical cancer screening by nonphysician providers among HPV-positive WLWH in an LMIC setting. This is important as WLWH shoulder the highest burden of cervical cancer and are a priority population for implementation of any technology-based solution. Our finding that the majority of cervical images were of high or medium quality is consistent with prior evaluations in LMICs.<sup>35,36</sup>

Despite the reported benefits of cervicography over naked-eye VIA including improving quality through higher resolution<sup>19</sup> and supporting remote consultation,<sup>16,19</sup> significant variation in interobserver agreement persists among off-site expert colposcopists,<sup>37</sup> as shown in our study, where off-site colposcopists' agreement of image

**FIG 2.** Cervical images from HPV-positive WLWH with histopathology diagnoses of (A) CIN1, B (CIN2), C (CIN3), D (invasive carcinoma). CIN, cervical intraepithelial neoplasia; HPV, human papillomavirus; WLWH, women living with HIV.



**TABLE 5.** Acceptability of Digital Cervicography Among HPV-Positive WLWH Undergoing Cervical Cancer Screening in Western Kenya

N = 164	No. (%)
Did you feel comfortable having an image of your cervix taken during screening for cervical cancer?	
Yes	163 (99.4)
No	1 (0.6)
Did seeing an image of your cervix during screening help to increase your understanding more about the screening? <sup>a</sup>	
Yes	159 (97.0)
No	2 (1.2)
Would you recommend cervical cancer screening using an image of the cervix to a friend?	
Yes	163 (99.4)
No	1 (0.6)

Abbreviations: HPV, human papillomavirus; WLWH, women living with HIV.

<sup>a</sup>Data missing for three.

quality was only fair ( $\kappa = 0.29$ ). Interobserver agreement of cervicography findings among HPV-positive women has ranged from fair ( $\kappa = 0.29$ ; 95% CI, 0.20 to 0.38)<sup>15</sup> to moderate ( $\kappa = 0.43$  [CI not reported]) in Madagascar.<sup>35</sup> Although some studies have shown improvement in test sensitivity for precancerous lesions with the addition of cervicography to VIA-based see-and-treat programs,<sup>19</sup> among studies comparing cervicography expert diagnoses to gold-standard histopathology, sensitivity has been as low as 28.6% (95% CI, 3.7 to 73)<sup>15</sup> to 50% (95% CI, 18.8 to 81.2).<sup>35</sup> This is consistent with our study where expert colposcopists' diagnostic sensitivity for CIN2+ from images of HPV-positive WLWH ranged from 21.4% to 35.7%, highlighting a need for better adjunctive tests that can improve the accuracy of the single-visit screen-and-treat approach. Perhaps, like VIA, which has limited accuracy but its use in LMICs lay the groundwork for adoption of more objective HPV molecular assays,<sup>38</sup> the largest impact of cervicography may be in facilitating implementation of automated visual algorithms that bring accurate, affordable diagnosis to the point-of-care.<sup>25</sup>

Our study highlights several feasibility issues for consideration before widespread implementation of cervicography in routine screen-and-treat programs in LMICs. Although we demonstrate the ability to take high-quality images at the point of care, we found important challenges in taking images meeting the laid-out criteria for adequacy, including difficulty with adequate patient positioning because of lack of gynecologic examination beds, which affected the ability to clearly capture all cervical quadrants in an image. Additionally, variable lighting in the screening rooms, including variable availability or functionality of a headlight, meant that several images had shadowing or could not be adequately illuminated. Use of the metal speculum also resulted in glaring within the images in certain cases, which decreases visualization of the

squamocolumnar junction, which is crucial for evaluation of possible dysplasia. In our study, a significant amount of time was spent addressing these elements to obtain adequate cervical images and may be a limitation in busy clinics with few providers. For widespread implementation, this highlights a potential need for embedded algorithms within smartphones that can support front-line healthcare workers in obtaining images adequate for evaluation for precancer,<sup>25</sup> as well as optimizing the screening environment (including lighting) to minimize the time needed to obtain a images. In this study, images were stored in an offline Box application within the smartphone and synced daily to a secure web-based server using a wireless connection. During the process of uploading images to the server, several instances of lost images were encountered because of variable connectivity. A truly feasible automated visual algorithm may need to not rely on an active internet connection to offer functionality in remote settings, while maintaining adequate quality measures.

There are several limitations to our study. In evaluating acceptability of cervicography in this population, a short, nonvalidated survey was administered to the participants following screening. It is possible that, despite use of well-trained research assistants who attempted to normalize all participant responses, some participants may have felt a desire to answer in the affirmative, hence skewing our data toward higher acceptability. Another limitation is the fact that although 164 participants underwent cervicography, we present analysis of images for only the first 94 participants, thereby potentially skewing our results. This was done in part because of restraints on expert reviewer's time, and we believe that given random entry into the study, these first 94 participants are largely representative of the study population. Because of improved experience with image-taking over time, we anticipate that subsequent images would be of the same or higher quality, hence consistent with our findings of image quality and diagnostic utility.

In conclusion, we report significantly high acceptability of image-based cervical cancer screening among HIV-positive WLWH in an LMIC, the first such study in Kenya, to our knowledge. We find that the majority of cervical images taken by a nonphysician clinician during routine cervical cancer screening in this high-risk population were of good quality and had diagnostic utility, as judged by off-site expert colposcopists. However, we find low sensitivity for diagnosis of CIN2+ from cervical images by off-site colposcopists compared with histopathology, which if used for triage would result in substantial loss of sensitivity gained from HPV screening and lost opportunity for treatment of high-grade precancer in a high-risk population. Our findings offer important lessons for ongoing efforts to set the stage for adoption of automated artificial intelligence algorithms that have the potential to bring highly accurate screening to the point of care in LMICs where the burden of cervical cancer is greatest.

## AFFILIATIONS

<sup>1</sup>Division of Prevention Science, Center for AIDS Prevention Studies, University of California San Francisco, San Francisco, CA

<sup>2</sup>FACES Lumumba Clinic, Kisumu, Kenya

<sup>3</sup>Department of Obstetrics and Gynecology, Rush University School of Medicine, Chicago, IL

<sup>4</sup>Barnard College, University of Columbia, New York, NY

<sup>5</sup>Department of Obstetrics and Gynecology, Maseno University School of Medicine, Kisumu, Kenya

<sup>6</sup>Department of Obstetrics, Gynecology and Reproductive Sciences, University of California San Francisco, San Francisco, CA

## CORRESPONDING AUTHOR

Chemtai Mungo, MD, MPH, Division of Prevention Science, University of California San Francisco, 550 16th St 3843, Mail Code 0886, San Francisco, CA 94143; e-mail: Chemtai.mungo@ucsf.edu.

## SUPPORT

Supported by Fogarty International Center of the National Institutes of Health (NIH) under Award Number D43TW009343 and the University of California Global Health Institute (UCGHI), the T32 MH19105 grant from the National Institutes of Mental Health of the US Public Health Service, and a grant from the University of California, San Francisco Global Cancer Program at the Helen Diller Family Comprehensive Cancer Care Center.

## AUTHOR CONTRIBUTIONS

**Conception and design:** Chemtai Mungo, Cirilus Ogollah Osongo, Craig R. Cohen

**Administrative support:** Chemtai Mungo

**Provision of study materials or patients:** Jeniffer Ambaka, Jackton Omoto

**Collection and assembly of data:** Chemtai Mungo, Cirilus Ogollah Osongo, Jeniffer Ambaka, Magdalene A. Randa, Emily Barker, Anagha Guliam, Jackton Omoto

**Data analysis and interpretation:** Chemtai Mungo, Cirilus Ogollah Osongo, Jeniffer Ambaka, Magdalene A. Randa, Benard Samba, Catherine A. Ochieng, Jackton Omoto, Craig R. Cohen

**Manuscript writing:** All authors

**Final approval of manuscript:** All authors

**Accountable for all aspects of the work:** All authors

## AUTHORS' DISCLOSURES OF POTENTIAL CONFLICTS OF INTEREST

The following represents disclosure information provided by authors of this manuscript. All relationships are considered compensated unless otherwise noted. Relationships are self-held unless noted. I = Immediate Family Member, Inst = My Institution. Relationships may not relate to the subject matter of this manuscript. For more information about ASCO's conflict of interest policy, please refer to [www.asco.org/rwc](http://www.asco.org/rwc) or [ascopubs.org/go/authors/author-center](http://ascopubs.org/go/authors/author-center).

Open Payments is a public database containing information reported by companies about payments made to US-licensed physicians ([Open Payments](http://OpenPayments)).

**Craig R. Cohen**

**Honoraria:** Lupin Pharmaceuticals, Miyarisan Pharmaceutical

No other potential conflicts of interest were reported.

## ACKNOWLEDGMENT

The authors thank the FACES Lumumba staff and leadership for support throughout this study.

## REFERENCES

- Bray F, Ferlay J, Soerjomataram I, et al: Global cancer statistics 2018: GLOBOCAN estimates of incidence and mortality worldwide for 36 cancers in 185 countries. *CA Cancer J Clin* 68:394-424, 2018
- Joshi S, Sankaranarayanan R, Muwonge R, et al: Screening of cervical neoplasia in HIV-infected women in India. *AIDS* 27:607-615, 2013
- Dryden-Peterson S, Bvochora-Nsingo M, Suneja G, et al: HIV infection and survival among women with cervical cancer. *J Clin Oncol* 34:3749-3757, 2016
- World Health Organisation: WHO Guidelines for Screening and Treatment of Precancerous Lesions for Cervical Cancer Prevention. [www.who.int/about/licensing/copyright\\_form/en/index.html](http://www.who.int/about/licensing/copyright_form/en/index.html), pp 1-40, 2013
- Sherris J, Wittet S, Kleine A, et al: Evidence-based, alternative cervical cancer screening approaches in low-resource settings. *Int Perspect Sex Reprod Health* 35:147-154, 2009
- Jeronimo J, Bansil P, Lim J, et al: A multicountry evaluation of care HPV testing, visual inspection with acetic acid, and Papanicolaou testing for the detection of cervical cancer. *Int J Gynecol Cancer* 24:576-585, 2014
- Sauvaget C, Fayette JM, Muwonge R, et al: Accuracy of visual inspection with acetic acid for cervical cancer screening. *Int J Gynaecol Obstet* 113:14-24, 2011
- Cholli P, Bradford L, Manga S, et al: Screening for cervical cancer among HIV-positive and HIV-negative women in Cameroon using simultaneous co-testing with careHPV DNA testing and visual inspection enhanced by digital cervicography: Findings of initial screening and one-year follow-up. *Gynecol Oncol* 148:118-125, 2018
- Murenzi G, Dusingize J-C, Rurangwa T, et al: Protocol for the study of cervical cancer screening technologies in HIV-infected women living in Rwanda. *BMJ Open* 8:e020432, 2018
- World Health Organisation: A Global Strategy for Elimination of Cervical Cancer. <https://www.who.int/activities/a-global-strategy-for-elimination-of-cervical-cancer>, 2020
- World Health Organisation: "Best Buys" and Other Recommended Interventions for the Prevention and Control of Non-Communicable Diseases. 2017
- Mungo C, Ibrahim S, Bukusi EA, et al: Scaling up cervical cancer prevention in Western Kenya: Treatment access following a community-based HPV testing approach. *Int J Gynaecol Obstet* 152:60-67, 2021
- Dartell MA, Rasch V, Iftner T, et al: Performance of visual inspection with acetic acid and human papillomavirus testing for detection of high-grade cervical lesions in HIV positive and HIV negative Tanzanian women. *Int J Cancer* 135:896-904, 2014
- Yeates K, Sleeth J, Hopman W, et al: Evaluation of a smartphone-based training strategy among Health care workers screening for cervical cancer in Northern Tanzania: The Kilimanjaro Method. *J Glob Oncol* 2:356-364, 2016
- Ricard-gauthier D, Wisniak A, Catarino R, et al: Use of smartphones as adjuvant tools for cervical cancer screening in low-resource settings. *J Low Genit Tract Dis* 19:295-300, 2015
- Parham GP, Mwanahamuntu MH, Krista S, et al: eC3-A modern telecommunications matrix for cervical cancer prevention in Zambia. *J Low Genit Tract Dis* 14, 2010



17. Cremer M, Jamshidi RM, Muderspach L, et al: Digital camera assessment for detection of cervical intraepithelial neoplasia in rural El Salvador. *Int J Gynaecol Obstet* 91:42-46, 2005
18. Chen ZP, Chen HM, Lee TT. Use of compact digital cervicography: An adjuvant screening tool for precancerous cervical lesions. *Taiwan J Obstet Gynecol* 47:187-191, 2008
19. Firnhaber C, Mao L, Levin S, et al: Evaluation of a cervicography-based program to ensure quality of visual inspection of the cervix in HIV-infected women in Johannesburg, South Africa. *J Low Genit Tract Dis* 19:7-11, 2015
20. Mink J, Peterson C: MobileODT: A case study of a novel approach to an mHealth-based model of sustainable impact. *mHealth* 2:12, 2016
21. Girardet A, Benski A, Tran PL, et al: Cervical cancer screening in low-resource settings: A smartphone image application as an alternative to colposcopy. *Int J Womens Health* 9:455-461, 2017
22. Tran PL, Benski C, Viviano M, et al: Performance of smartphone-based digital images for cervical cancer screening in a low-resource context. *Int J Technol Assess Health Care* 34:337-342, 2018
23. Bomfim-Hyppolito S, Franco ES, Franco RG, et al: Cervicography as an adjunctive test to visual inspection with acetic acid in cervical cancer detection screening. *Int J Gynaecol Obstet* 92:58-63, 2006
24. Hu L, Bell D, Antani S, et al: An observational study of deep learning and automated evaluation of cervical images for cancer screening. *J Natl Cancer Inst* 111:923-932, 2019
25. Xue Z, Novetsky AP, Einstein MH, et al: A demonstration of automated visual evaluation of cervical images taken with a smartphone camera. *Int J Cancer* 147:2416-2423, 2020
26. Rosser JI, Njoroge B, Huchko MJ. Cervical cancer stigma in rural Kenya: What does HIV have to do with it? *J Cancer Educ* 31:413-418, 2016
27. Mbonu NC, Van den Borne B, De Vries NK: A model for understanding the relationship between stigma and healthcare-seeking behaviour among people living with HIV/AIDS in sub-Saharan Africa. *Afr J AIDS Res* 8:201-212, 2009
28. Ying H, Jing F, Fanghui Z, et al: High-risk HPV nucleic acid detection kit-the careHPV test -a new detection method for screening. *Sci Rep* 4:4704, 2014
29. World Health Organisation: WHO Guidelines for the Use of Thermal Ablation for Cervical Pre-cancer Lesions. 2019
30. Mungo C, Osongo CO, Ambaka J, et al: Safety and acceptability of thermal ablation for treatment of human papillomavirus among women living with HIV in Western Kenya. *JCO Glob Oncol* 6:1024-1033, 2020
31. Macheke DG: SEVIA Image Quality Description. 2019
32. McHugh ML: Interrater reliability: The kappa statistic. *Biochem Med (Zagreb)* 22:276-282, 2012
33. Haas AD, Radin E, Hakim AJ, et al: Prevalence of nonsuppressed viral load and associated factors among HIV-positive adults receiving antiretroviral therapy in Eswatini, Lesotho, Malawi, Zambia and Zimbabwe (2015 to 2017): Results from population-based nationally representative surveys. *J Int AIDS Soc* 23:e25631, 2020
34. Wesolowski A, Eagle N, Noor AM, et al: Heterogeneous mobile phone ownership and usage patterns in Kenya. *PLoS One* 7:e35319, 2012
35. Catarino R, Vassilakos P, Scaringella S, et al: Smartphone use for cervical cancer screening in low-resource countries: A pilot study conducted in Madagascar. *PLoS One* 10:e0134309, 2015
36. Quinley KE, Gormley RH, Ratcliffe SJ, et al: Use of mobile telemedicine for cervical cancer screening. *J Telemed Telecare* 17:203-209, 2011
37. Manga S, Parham G, Benjamin N, et al: Cervical cancer screening in Cameroon: Interobserver agreement on the interpretation of digital cervicography results. *J Low Genit Tract Dis* 19:288-294, 2015
38. Silkensen SL, Schiffman M, Sahasrabudde V, et al: Is it time to move beyond visual inspection with acetic acid for cervical cancer screening? *Glob Health Sci Pract* 6:242-246, 2018

