

UCSF

UC San Francisco Previously Published Works

Title

Computed tomography perfusion abnormalities after carotid endarterectomy help in the diagnosis of reversible cerebral vasoconstriction syndrome.

Permalink

<https://escholarship.org/uc/item/5kj9q851>

Journal

Journal of vascular surgery cases and innovative techniques, 7(1)

ISSN

2468-4287

Authors

Isikbay, Masis
Narsinh, Kazim H
Arroyo, Sergio
[et al.](#)

Publication Date

2021-03-01

DOI

10.1016/j.jvscit.2020.10.010

Peer reviewed

Computed tomography perfusion abnormalities after carotid endarterectomy help in the diagnosis of reversible cerebral vasoconstriction syndrome

Masis Isikbay, MD,^a Kazim H. Narsinh, MD,^a Sergio Arroyo, MD, PhD,^b Wade S. Smith, MD, PhD,^b Daniel L. Cooke, MD,^a Randall T. Higashida, MD,^a and Matthew R. Amans, MD,^a San Francisco, Calif

ABSTRACT

Acute neurologic deficits in the postoperative period after carotid endarterectomy (CEA) can prompt extensive diagnostic evaluation. Reversible cerebral vasoconstriction syndrome (RCVS) is an underrecognized cause of acute neurologic deficit after CEA. We present the case of RCVS in an 84-year-old male patient who had experienced left limb weakness after CEA, prompting multiple code stroke activations. The present case is novel because the obtained computed tomography perfusion imaging studies demonstrated abnormalities that have not been previously described in patients with RCVS. These findings, combined with the cerebral angiography findings, led to the rapid diagnosis and delivery of intra-arterial vasodilator therapy. He experienced subsequent resolution of his symptoms and radiologic abnormalities. (*J Vasc Surg Cases and Innovative Techniques* 2021;7:171-5.)

Keywords: Carotid endarterectomy; CT perfusion; Neurological deficits; Reversible cerebral vasoconstriction syndrome; Surgical complications

Reversible cerebral vasoconstriction syndrome (RCVS) is a rare, yet serious, complication that can occur after recent carotid endarterectomy (CEA).¹ Although the exact cause of RCVS remains unknown, the condition itself is characterized by multifocal narrowing of the cerebral arteries in a pattern that mimics the vasospasm and/or vasoconstriction caused by other etiologies (eg, subarachnoid hemorrhage). Although RCVS can be treated effectively with a combination of intra-arterial and systemic calcium channel blockers,² a missed diagnosis or significant delay in the diagnosis can result in cerebral ischemia, cerebral infarction, and permanent neurologic deficits. We present a case that, to the best of our knowledge, is the first report of RCVS after CEA with computed tomography (CT) perfusion imaging studies that demonstrated a perfusion deficit. The patient provided written informed consent for the report of his case and is available on request.

CASE REPORT

An 84-year-old man had presented to his vascular surgeon for performance of an elective right CEA for high-grade stenosis of the right internal carotid artery. His medical history was significant for coronary artery disease treated by angioplasty and stenting to the left anterior descending artery, right coronary artery, and left circumflex artery. He also had a history of non-small-cell lung cancer treated by right lower lobe lobectomy. His other surgical history included remote appendectomy, right knee replacement, laparoscopic cholecystectomy, and left-sided CEA 13 years previously. His medications included aspirin and clopidogrel. His social history was notable for an ~8 pack-year history of smoking, although he had quit >30 years before the current presentation. After carotid ultrasonography (performed as part of a syncope evaluation) had demonstrated ≥70% stenosis of the proximal right internal carotid artery and <50% stenosis of the left internal carotid artery, he was referred to vascular surgery for right CEA.

The patient's procedure was performed 6 weeks after the carotid artery Doppler ultrasound study. His operative course was uneventful. A collagen-impregnated Dacron graft (8 mm × 75 mm; Hemacarotid Patch Ultrathin; Getinge, Gothenburg, Sweden) was used to perform patch angioplasty.³ No perioperative hypotension was observed, and no shunt was used during the procedure owing to the patient's recorded "excellent pulsatile backbleeding." A "negligible" amount of estimated blood loss was documented. Postoperatively, the patient was stable, with no episodes of hypotension and no neurologic deficits. The remainder of the patient's immediate postoperative course was unremarkable.

At 10 days after his right CEA, when the patient had sat down in the evening to have dinner, he noted sudden left arm and leg weakness and numbness. Acutely, he was unable to lift either extremity against gravity for several hours, with a subsequent

From the Department of Radiology and Biomedical Imaging,^a and Department of Neurology,^b University of California, San Francisco, School of Medicine.

Author conflict of interest: none.

Correspondence: Matthew R. Amans, MD, Department of Radiology and Biomedical Imaging, University of California, San Francisco, School of Medicine, 505 Parnassus Ave, Rm M391, Box 0628, San Francisco, CA 94143 (e-mail: Matthew.Amans@ucsf.edu).

The editors and reviewers of this article have no relevant financial relationships to disclose per the Journal policy that requires reviewers to decline review of any manuscript for which they may have a conflict of interest.

2468-4287

© 2020 The Author(s). Published by Elsevier Inc. on behalf of Society for Vascular Surgery. This is an open access article under the CC BY-NC-ND license (<http://creativecommons.org/licenses/by-nc-nd/4.0/>).

<https://doi.org/10.1016/j.jvscit.2020.10.010>

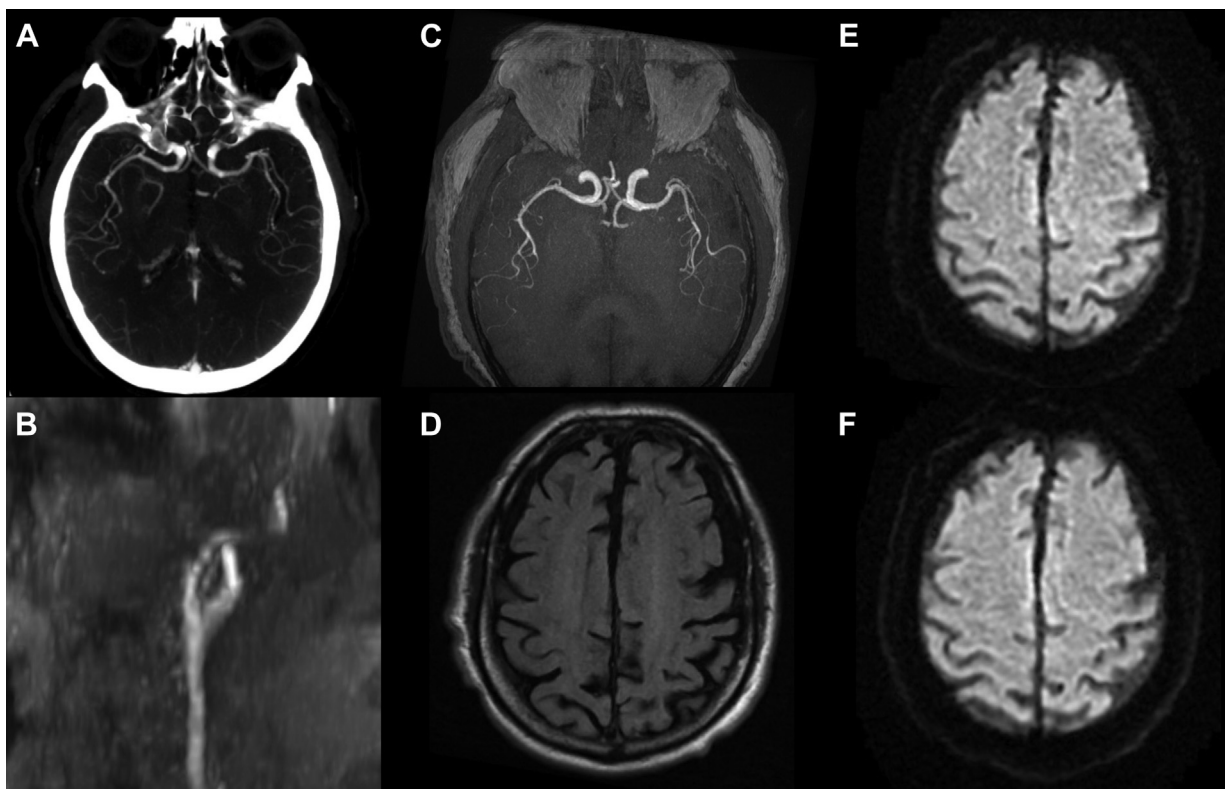


Fig 1. Before the patient's right carotid endarterectomy (CEA), computed tomography angiography of the head showed no evidence of intracranial arterial pathology with a symmetric appearance of the middle cerebral artery branch vessels in the Sylvian fissures bilaterally on axial thick slice reformats (**A**). On initial presentation to the emergency room on postoperative day 12 after carotid endarterectomy, magnetic resonance angiography of the patient's neck revealed a patent right carotid bifurcation as shown on time-of-flight coronal reformats (**B**). Magnetic resonance angiography of the brain was also performed, and axial thick slice reformats did not show a noticeable asymmetry in the middle cerebral artery branch vessels in the Sylvian fissures (**C**). Magnetic resonance imaging (MRI) of the brain conducted as a part of the study does not show any abnormal T2-weighted/fluid-attenuated inversion recovery (FLAIR) signal (**D**) or areas of acute infarct on diffusion imaging (**E**). When the patient presented again on postoperative day 14, magnetic resonance imaging of the brain was repeated and again showed no evidence of infarct (**F**).

rapid resolution of his symptoms. During the next 2 days, he had experienced several additional neurologic episodes, each resulting in left arm and/or leg weakness and each self-resolving during a span of several hours. On postoperative day 12, the patient had experienced left arm weakness, headache, and vision changes, including the perception of abnormal clouds and colorful smoke. He described his headache as an episodic sharp pain centered only behind his right eye.

On the same day (12 days postoperatively), he presented to the local emergency department for the first time, at which point, his preprocedure CT angiogram of the head was reviewed (**Fig 1, A**), and magnetic resonance angiography and magnetic resonance imaging (MRI) of the neck and head were performed (**Fig 1, B-E**). The imaging findings were notable for patent vessels within the head and neck and no areas of acute infarct or abnormal T2-weighted fluid-attenuated inversion recovery (FLAIR) signal. Furthermore, the patient's vessel anatomy was unremarkable, with an intact circle of Willis and no variant intracranial anatomy present. He was subsequently discharged.

On postoperative day 14, he experienced another episode of left arm weakness that made it difficult to hold a mug, again associated with a similar headache and colorful visual percepts. He presented once more to his local emergency department. However, his symptoms had resolved before evaluation. A repeat MRI scan of the brain was obtained, with negative findings for acute infarct (**Fig 1, F**). Given the ongoing, recurrent nature of these events without a clear diagnosis, he was ultimately referred to a tertiary care center for further diagnostic evaluation.

On admission, a carotid ultrasound scan was repeated, which demonstrated a patent right internal carotid artery with <50% stenosis. A few hours after the ultrasound scan, the patient experienced another episode of left-sided weakness, which prompted an emergent neurologic evaluation and code stroke activation. His blood pressure was 116/40 mm Hg, the glucose level was 183 mg/dL, and his National Institutes of Health Stroke Scale score was 4, with points assigned for left arm/left leg weakness, sensory loss, and left facial droop. Although transcranial

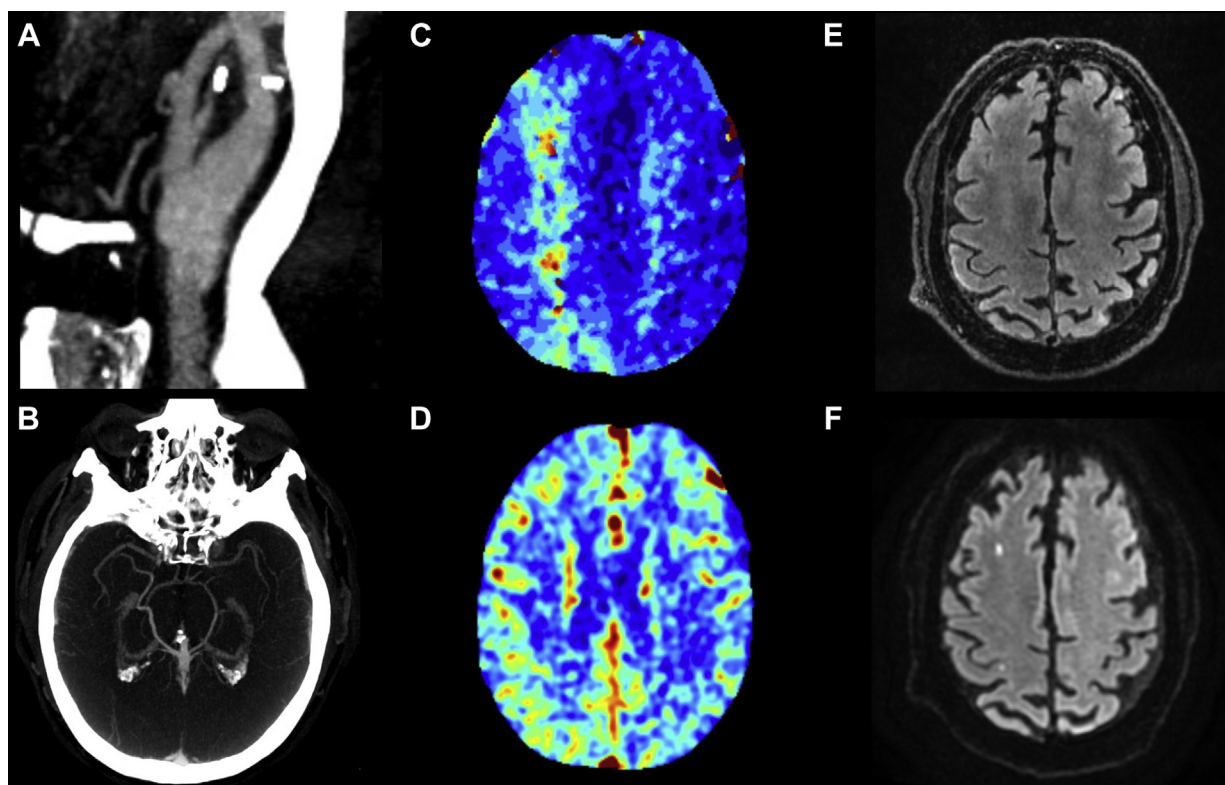


Fig 2. Computed tomography (CT) angiography performed after the patient was transferred to a tertiary care center for further evaluation revealed a patent carotid bifurcation with no evidence of local postprocedural complications (**A**). Computed tomography angiography of the head was notable for the absence of middle cerebral artery branch vessels in the right Sylvian fissure (**B**). CT perfusion imaging revealed elevated mean transit times in a watershed territory of the right middle cerebral artery (**C**) with preserved symmetrical cerebral blood volume (**D**). Follow-up magnetic resonance imaging showed no abnormal T2-weighted/fluid-attenuated inversion recovery (FLAIR) signal in the absence of cerebral edema (**E**). Diffusion imaging revealed areas of focal small infarcts in watershed territories (**F**).

Doppler ultrasonography had been ordered to evaluate for possible vasospasm, it was never performed because the patient had first undergone a stroke protocol CT scan. A non-contrast-enhanced head CT scan revealed left caudate hypodensity, likely reflecting an age-indeterminate infarct, but was negative for acute abnormalities. CT angiography of the head and neck showed a patent right common and internal carotid artery with expected postoperative changes, consistent with the findings from the ultrasound study performed earlier that day (Fig 2, A). A subtle paucity of middle cerebral artery branch vessels in the right Sylvian fissure (Fig 2, B) was also noted. CT perfusion imaging demonstrated elevated mean transit times in the right cerebral hemisphere in a watershed pattern, with preserved and symmetric cerebral blood volume (Fig 2, C and D). Given this pattern of perfusion abnormality, a brain MRI study was obtained. T2-weighted FLAIR imaging did not demonstrate any evidence of edema (Fig 2, E). Consistent with the CT perfusion data, multiple foci of restricted diffusion were seen in the right frontal and parietal lobes in a watershed pattern (Fig 2, F), suggestive of low-flow and/or thromboembolic ischemia.

From the patient's workup findings, the primary team (neurology) and consulting services (vascular surgery,

neurointerventional radiology) decided to proceed with catheter-directed cerebral angiography to evaluate the perfusion deficits identified. The possibility of delivering intra-arterial calcium channel blockers was discussed with the patient and team, as were the potential risks (systemic hypotension and intracranial hypertension). After the patient had provided written informed consent for this procedure, angiography was performed, which again confirmed patency of the right common and internal carotid artery (Fig 3, A). The study demonstrated subtle multifocal luminal narrowing in the right anterior intracranial circulation. Specifically, the angiogram demonstrated narrowing in the right ophthalmic artery and in the branches of the M2 and M3 middle cerebral artery (Fig 3, B).

Intra-arterial verapamil was administered (15 mg into the right internal carotid artery and 5 mg into the right external carotid artery), and the luminal caliber of the previously affected vessels improved significantly (Fig 3, C). A follow-up CT perfusion study of the head was performed, which revealed restoration of symmetric cerebral perfusion (Fig 3, D and E). The patient was monitored in the intensive care unit for 2 days after the procedure with close blood pressure monitoring using an intra-arterial line. Nimodipine (60 mg every 4 hours) was administered for

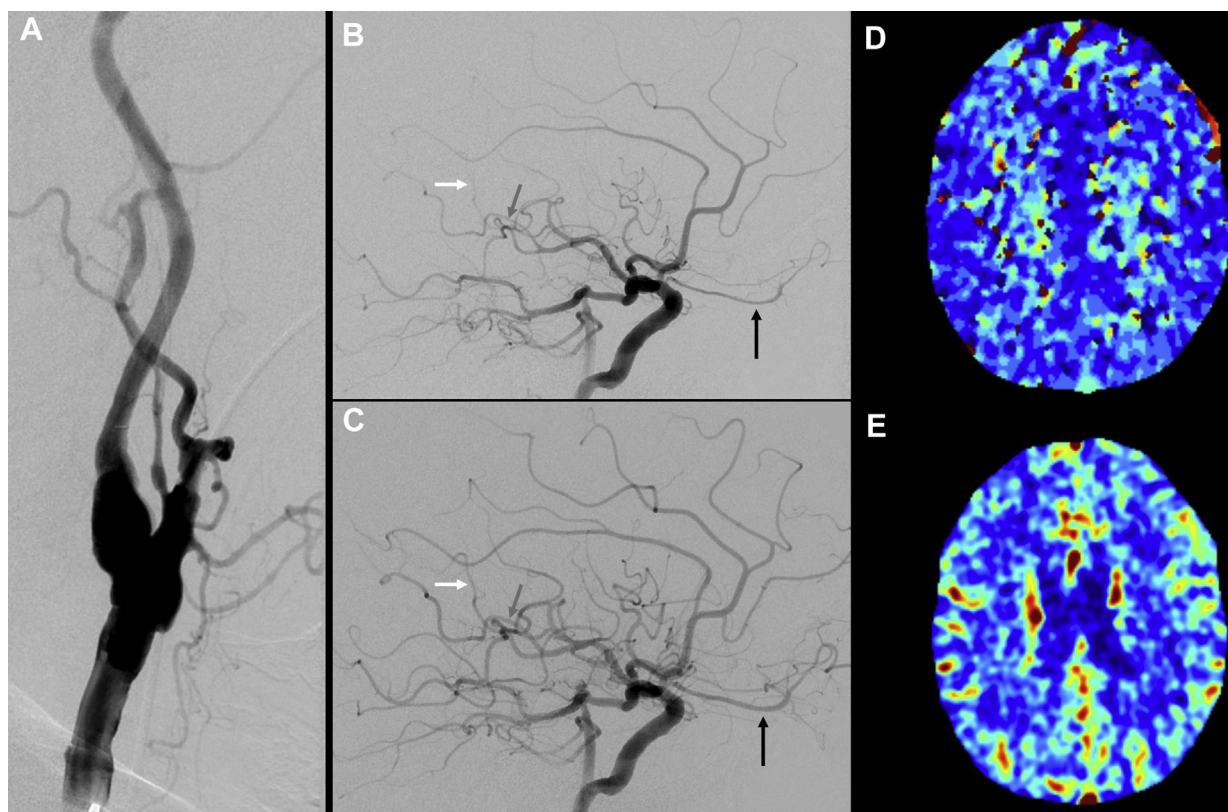


Fig 3. Cerebral angiography was performed because of a suspected diagnosis of reversible cerebral vasoconstriction syndrome (RCVS). At the start of the procedure, a patent right carotid artery bifurcation was visualized (**A**). A cerebral angiogram revealed narrowing of multiple M2/M3 middle cerebral artery branch vessels (**B**; *dark gray* and *white arrows*), with narrowing of the ophthalmic artery (*black arrow*) and its branch vessels, which resolved with verapamil administration (**C**). Postprocedure computed tomography (CT) perfusion imaging showed symmetric mean transit times (**D**) and cerebral blood volume (**E**).

the first 4 days after the procedure, at which point the patient was discharged with verapamil at 40 mg three times daily. The patient's remaining hospital course was uneventful. After the procedure, the patient no longer experienced any episodes of transient weakness or other neurologic abnormalities.

DISCUSSION

In the present report, we have discussed a patient who had recently undergone CEA and had presented with acute neurologic deficits. The differential diagnosis for acute neurologic deficit after CEA includes intracranial hemorrhage,⁴ cerebral hyperperfusion syndrome,⁵ thromboembolic stroke,⁶ reversible cerebral vasoconstriction syndrome,^{1,7} myocardial infarction,⁸ cervical hematoma,⁹ postoperative neck infection,¹⁰ and iatrogenic nerve injury.¹¹ Given this broad differential diagnosis, the evaluation of these patients will benefit initially from a thorough history, physical examination, laboratory analysis, and diagnostic imaging studies.

Brain perfusion imaging (eg, CT perfusion imaging, which is a component of a CT stroke protocol study) might be required as a part of the diagnostic evaluation and can complement vessel imaging and MRI. The

results from our present patient have highlighted the value of CT perfusion imaging to demonstrate asymmetric increases in the mean transit time resulting from small cerebral vessel vasoconstriction (despite the patency of the large vessels at the circle of Willis). The perfusion abnormalities seen in the present case served to be the most striking and obvious findings on diagnostic imaging. These findings in the setting of no cerebral edema (shown by an absence of T2/FLAIR signal on MRI) can help to exclude the possibility of cerebral hyperperfusion or autoregulatory failure as the diagnosis.⁵ Cerebral angiography can identify these subtle small vessel abnormalities, as in the present case, which will enable the diagnosis of RCVS and also allow for its treatment with intra-arterial vasodilator therapy.

CONCLUSIONS

Acute neurologic deficits after recent CEA should prompt a thorough diagnostic evaluation with consideration of a broad range of etiologies. Diagnostic imaging studies, specifically perfusion studies, can have an important role in this evaluation. CT perfusion imaging can help identify areas of reversible ischemia, which can be

caused by RCVS, shown for the first time in the present case. The prompt identification of perfusion abnormalities is critical to the delivery of timely intervention and avoiding clinically significant cerebral infarction. Without the performance of catheter-directed angiography and the observed response to calcium channel blockers, cases of RCVS can easily be missed, with the assumption that a cardioembolic etiology is responsible for the patient's symptoms.

REFERENCES

1. Causey MW, Amans MR, Han S, Higashida RT, Conte M. Reversible cerebral vasoconstriction syndrome is a rare cause of stroke after carotid endarterectomy. *J Vasc Surg* 2016;64:1847-50.
2. Nowak DA, Rodiek SO, Henneken S, Zinner J, Schreiner R, Fuchs H-H, et al. Reversible segmental cerebral vasoconstriction (Call-Fleming syndrome): are calcium channel inhibitors a potential treatment option? *Cephalalgia* 2003;23:218-22.
3. Hemacarotid Patch Ultrathin n.d. Available at: <https://www.getinge.com/int/product-catalog/hemacarotid-patch-ultra-thin/>. Accessed September 26, 2020.
4. Wu TY, Anderson NE, Barber PA. Neurological complications of carotid revascularisation. *J Neurol Neurosurg Psychiatry* 2012;83:543-50.
5. Huijbers AE, Westerink J, de Vries EE, Hoskam A, den Ruijter HM, Moll FL, et al. Editor's choice – cerebral hyperperfusion syndrome after carotid artery stenting: a systematic review and meta-analysis. *Eur J Vasc Endovasc Surg* 2018;56:322-33.
6. Radak D, Popovic AD, Radicević S, Nesković AN, Bojić M. Immediate reoperation for perioperative stroke after 2250 carotid endarterectomies: differences between intraoperative and early postoperative stroke. *J Vasc Surg* 1999;30:245-51.
7. Asuzu DT, Kumar J, Capek S, Park MS. Fulminant reversible cerebral vasoconstriction syndrome after carotid endarterectomy for asymptomatic stenosis. *World Neurosurg* 2020;134:423-6.
8. Boulanger M, Camelière L, Felgueiras R, Berger L, Rerkasem K, Rothwell PM, et al. Periprocedural myocardial infarction after carotid endarterectomy and stenting. *Stroke* 2015;46:2843-8.
9. Doig D, Turner EL, Dobson J, Featherstone RL, de Borst GJ, Brown MM, et al. Incidence, impact, and predictors of cranial nerve palsy and haematoma following carotid endarterectomy in the international carotid stenting study. *Eur J Vasc Endovasc Surg* 2014;48:498-504.
10. Singh A, Wyatt M, Clarke M, Wales L. Late sterile abscess formation in carotid endarterectomy following use of Bio-Glue: a word of caution. *EJVES Short Rep* 2017;37:12-3.
11. Cunningham EJ, Bond R, Mayberg MR, Warlow CP, Rothwell PM. Risk of persistent cranial nerve injury after carotid endarterectomy. *J Neurosurg* 2004;101:445-8.

Submitted Sep 2, 2020; accepted Oct 14, 2020.