

UCLA

UCLA Previously Published Works

Title

An Update on the Adjunctive Neurovascular Support of Wide-Neck Aneurysm Embolization and Reconstruction Trial: 1-Year Safety and Angiographic Results.

Permalink

<https://escholarship.org/uc/item/5m40389d>

Journal

AJNR. American journal of neuroradiology, 39(5)

ISSN

0195-6108

Authors

Spiotta, AM
Chaudry, MI
Turner, RD
et al.

Publication Date




2018-05-01

DOI

10.3174/ajnr.a5599

Peer reviewed

An Update on the Adjunctive Neurovascular Support of Wide-Neck Aneurysm Embolization and Reconstruction Trial: 1-Year Safety and Angiographic Results

 A.M. Spiotta,  M.I. Chaudry,  R.D. Turner IV,  A.S. Turk,  C.P. Derdeyn,  J. Mocco, and  S. Tateshima



ABSTRACT

BACKGROUND AND PURPOSE: The safety and efficacy of the PulseRider for the treatment of wide-neck, bifurcation aneurysms at the basilar and carotid terminus locations were studied in a prospective trial, the Adjunctive Neurovascular Support of Wide-Neck Aneurysm Embolization and Reconstruction (ANSWER) trial, reporting on initial 6-month angiographic and clinical results. This report provides insight into the longer term durability and safety with 12-month data.

MATERIALS AND METHODS: Aneurysms treated with the PulseRider among enrolled sites were prospectively studied. Updated 12-month data on clinical and imaging end points are included.

RESULTS: Thirty-four patients were enrolled (29 women, 5 men) with a mean age of 60.9 years. The mean aneurysm height ranged from 2.4 to 15.9 mm with a mean neck size of 5.2 mm (range, 2.3–11.6 mm). At 1 year, there were no device migrations or symptomatic in-stent stenoses. Raymond-Roy I occlusion was achieved in 53% of cases at the time of treatment and progressed to 61% and 67% at 6 and 12 months, respectively. Adequate occlusion (Raymond-Roy I/II) progressed from 88% at 6 months to 90% at 12 months. No recanalizations were observed. There was 1 delayed ischemic event. Good outcome (mRS 0–2) was achieved in 90% of patients.

CONCLUSIONS: The updated 1-year results from the ANSWER trial demonstrate aneurysm stability and an acceptable safety profile for aneurysms treated at the basilar apex and carotid terminus. Prospective data from a larger set of aneurysms treated at other locations are required to assess how treatment with PulseRider compares with alternatives for treating wide-neck bifurcation aneurysms.

ABBREVIATION: ANSWER = Adjunctive Neurovascular Support of Wide-Neck Aneurysm Embolization and Reconstruction

The endovascular approach to intracranial aneurysms has been revolutionized with the advent of balloon remodeling and stent-assisted coiling, allowing treatment of geometrically complex aneurysms,^{1–6} but optimization of treatment approaches is still necessary. In particular, wide-neck aneurysms arising at bifurcations still present a challenge with suboptimal rates of adequate occlusion and lower-than-desired safety profiles.⁷ A recently approved device is the PulseRider (Cerenovus, a division of Johnson & Johnson, New Brunswick, New Jersey), de-

signed as an adjunct for the coil embolization of aneurysms arising at bifurcations^{8–12} and to provide an alternative to complex Y-stent reconstruction.^{12–28}

The Adjunctive Neurovascular Support of Wide-Neck Aneurysm Embolization and Reconstruction (ANSWER) trial demonstrated the safety and efficacy²⁹ of the PulseRider at 6 months for the treatment of wide-neck, bifurcation aneurysms arising at the carotid terminus and basilar apex. This report provides an update with 1-year data on clinical and imaging end points.

MATERIALS AND METHODS


Patients were enrolled from 10 US sites, all of which had institutional review board approvals (Medical University of South Carolina; SUNY Buffalo; University of Virginia; Long Beach Memorial Medical Center; University of Kansas Medical Center; Rush University Medical Center; University of Texas Southwestern; Mount Sinai, New York, New York; University of Massachusetts; Baptist Medical Center, Jacksonville, Florida). Aneurysms arising at either the carotid terminus or basilar apex that were relatively wide-neck were considered candi-

Received November 13, 2017; accepted after revision January 10, 2018.

From the Department of Neurosurgery (A.M.S., M.I.C., R.D.T., A.S.T.), Medical University of South Carolina, Charleston, South Carolina; Department of Radiology (C.P.D.), University of Iowa, Iowa City, Iowa; Department of Neurosurgery (J.M.), Mount Sinai Hospital, New York, New York; and Department of Radiology (S.T.), University of California, Los Angeles, Los Angeles, California.

This work was supported by Pulsar Vascular.

Please address correspondence to Alejandro Spiotta, MD, Department of Neurosurgery, Medical University of South Carolina, 96 Jonathan Lucas St, CSB 210, Charleston, SC 29425; e-mail: spiotta@musc.edu

 Indicates open access to non-subscribers at www.ajnr.org

<http://dx.doi.org/10.3174/ajnr.A5599>

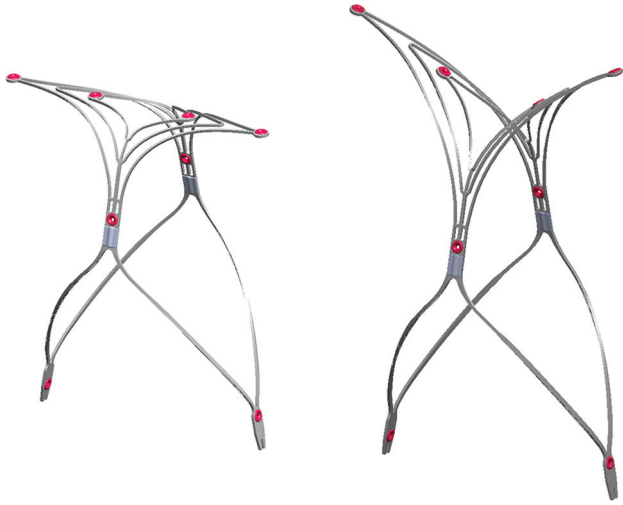


FIG 1. The PulseRider device is a self-expanding, nitinol implant that is fully retrievable and can be repositioned with radiopaque markers to aid in visibility during deployment and manipulation. The device is available in both Y- and T-configurations, as displayed, and has several different diameters and lengths available. The radiopaque markers are highlighted in red. Photograph provided courtesy of Cerenovus.

dates for inclusion in the trial (clinical trial registration number NCT02312856).

Beyond the primary 6-month FDA end points, extended safety end points for this update included death or stroke in a downstream territory postprocedure at 365 days. Technical success end points included device migration, in-stent stenosis, ability to retain coils within the aneurysm, and rate of aneurysm occlusion using the Raymond-Roy classification. Angiographic evaluation of these technical end points was adjudicated at each time point by a core lab blinded to the site performing the treatment. While all patients underwent angiography at 6 months, imaging follow-up at 1 year included MR angiography ($n = 8$), CT angiography ($n = 1$), and digital subtraction angiography ($n = 21$) (3 lost to follow up). All 12-month imaging was evaluated by a core lab.

PulseRider Device and Coil Embolization Technique

The PulseRider device is a self-expanding, nitinol implant (Fig 1) delivered on a stainless-steel delivery wire within any commercially available 021-diameter microcatheter. The device is fully retrievable and can be repositioned and torqued to fit the relevant anatomy. The device itself has significantly less metal than a conventional stent with most of the surface area coverage focused at the neck of the aneurysm. It has an open leaflet structure, which allows unrestricted microcatheter access to the aneurysm once deployed. The device is available in both T- and Y-configurations, intended to fit the geometry of the daughter vessels arising at the bifurcation. The device is available in different diameters and lengths and is outfitted with 8 radiopaque markers to aid in positioning. It can be positioned with both “wings” within the daughter branches (Fig 2), both within the aneurysm neck itself, or 1 in a daughter branch and 1 in the aneurysm neck. The device is then traversed with the coiling microcatheter for coil embolization.

Details of the procedural technique have been previously reviewed.^{8,9,11}

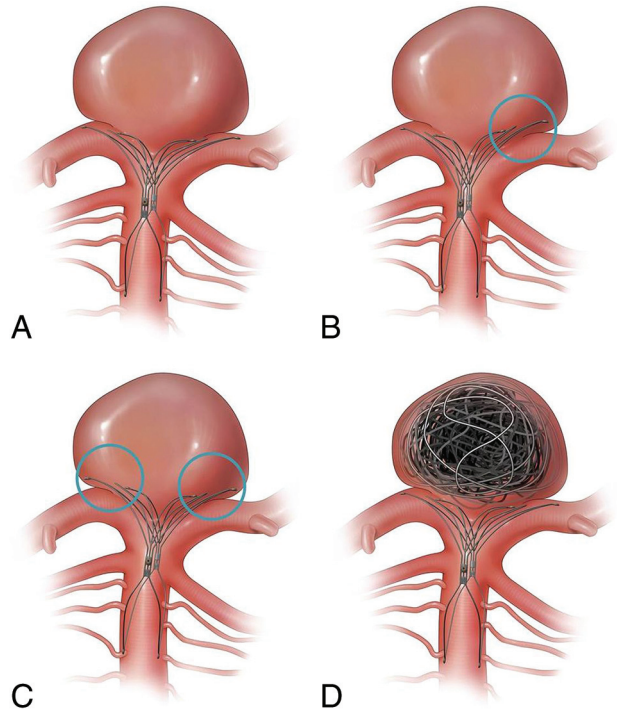


FIG 2. The PulseRider device is versatile and can be positioned with both wings within the daughter branches (A), 1 in a daughter branch and 1 in the aneurysm neck (B), or both within the aneurysm neck itself (C). The device is then traversed with the coiling microcatheter for coil embolization (D). Reprinted from Spiotta AM, Derdeyn CP, Tateshima S, et al. Results of the ANSWER trial using the PulseRider for the treatment of broad-necked, bifurcation aneurysms. *Neurosurgery* 2017;81(1):56–65, by permission of the Congress of Neurological Surgeons.

RESULTS

Patient Demographics and Aneurysm Characteristics

Thirty-four patients were enrolled (29 women and 5 men), with a mean age of 60.9 years (range, 26–86 years). Nine patients had a prior coil embolization procedure to the target aneurysm (8 basilar apex and 1 carotid terminus), and 5 had prior remote subarachnoid hemorrhage.

Aneurysm height ranged from 2.4 to 15.9 mm, and dome size ranged from 2.8 to 16.2 mm. The mean neck size was 5.2 mm (range, 2.3–11.6 mm). Twenty-seven aneurysms were located at the basilar apex and 7 at the carotid terminus. Parent vessel diameter ranged from 2.7 to 3.6 mm (basilar apex) and 2.9 to 4.2 mm (carotid terminus).

Angiographic Outcomes

Of the 34 patients enrolled, 1 patient died of unrelated causes shortly after the 6-month follow-up, and 3 patients were lost to follow-up. Thus, 30 patients in total were imaged at 1 year.

At 1 year, there were no device migrations or vessel stenoses. Raymond-Roy I was achieved in 53% of cases at the time of treatment and progressed to 61% and 67% at 6 and 12 months, respectively. Adequate occlusion (Raymond-Roy I/II) progressed from 88% at 6 months to 90% at 12 months (Table). No recanalizations were observed. No coil herniations or device migrations were observed. At 6 months, there was 1 instance (3.3%) of in-stent stenosis in a daughter vessel, measuring <50%, which was asymp-

Angiographic aneurysm occlusions at treatment (day 0), day 180, and day 365

Raymond-Roy Score	Aneurysm Occlusion (No.) (%)		
	Day 0 (n = 34)	Day 180 ^a (n = 33)	Day 365 ^b (n = 30)
I	18 (53%)	20 (61%)	20 (67%)
II	9 (26%)	9 (27%)	7 (23%)
III	7 (21%)	4 (12%)	3 (10%)
I/II	27 (79%)	29 (88%)	27 (90%)

^a Adequate occlusion was defined as Raymond-Roy I or II occlusion. One subject with a carotid terminus aneurysm had a CTA at 180 days, and occlusion data were not available on the image. The same subject died due to metastatic cancer before the 365-day visit and is not included in the 365-day data.

^b Three subjects were lost to follow-up at the 365-day visit.

tomatic and not flow-limiting. At 1 year, the stenosis had resolved and remained asymptomatic.

Safety End Points

There were no deaths attributed to the device or procedure. There was 1 death involving a patient who was found to have metastatic cancer that was not known before enrollment in the trial, and the death was unrelated to the procedure or the implant. At 12 months, mRS 0–2 was achieved in 90% (27/30) of patients.

One patient (1/30, 3.3%) had a delayed procedure-related ischemic event. Dual-antiplatelet therapy was discontinued after 6 months (per protocol), and at 9 months, the patient reported subjective mild and intermittent visual disturbances. During work-up, a small right thalamic infarct was identified on MR imaging. A thromboembolus from either the coil mass or the limb of the stent positioned in the right posterior cerebral artery was the suspected etiology.

DISCUSSION

The data from the ANSWER trial established the PulseRider as a safe device in the treatment of bifurcation aneurysms.²⁹ This report provides an update on the 12-month results of this trial, previously described at 6 months. Of note, beyond the 6-month follow-up period, the protocol was to discontinue dual-antiplatelet therapy and continue with aspirin, 325 mg daily. Angiographically, there were no device migrations or symptomatic in-stent stenoses identified. The single occurrence of asymptomatic in-stent stenosis of 1 branch vessel was entirely resolved at 1 year. Good outcome (mRS 0–2) was achieved in 90% of patients at a year. There was 1 delayed ischemic complication following discontinuation of dual-antiplatelet therapy.

Aneurysm occlusion rates in patients treated with the PulseRider and evaluated by core lab adjudication were 53% at time of initial treatment and progressed to 67% and 90% for complete and adequate occlusion, respectively. These occlusion rates at 1 year compare favorably with the pooled data from 3 prospective trials using the Woven EndoBridge device (WEB; Sequent Medical, Aliso Viejo, California),³⁰ which demonstrated complete aneurysm occlusion in 52.9%, Raymond-Roy II in 26.1%, and Raymond-Roy III in 20.9%. These angiographic outcomes demonstrate the immediate utility of the PulseRider as an adjunct to coil embolization of these wide-neck aneurysms arising at the basilar apex and carotid terminus, as well as the stability (no recanalizations were observed) and modest degree of flow diversion afforded as reflected in the progressive occlusion at both 6- and 12-month follow-up.

Beyond streamlining the procedure, the results achieved in the ANSWER trial at 12 months compare favorably with the largest, multicenter case series of Y-stent placement ($n = 45$),¹⁵ which reported an 11% intraprocedural complication rate and immediate Raymond-Roy I occlusion rates of 40% that improved to 60% on the latest follow-up imaging, though only 30 of the 45 patients had follow-up imaging available. Among patients in the ANSWER trial, immediate Raymond-Roy I was achieved in 53% of cases at the time of treatment and progressed to 61% and 67% at 6 and 12 months, respectively. However, while the Raymond-Roy I occlusion rates are similar between PulseRider and Y-stent treated cases, Y-stent placement was associated with an 8.9% posttreatment ischemic event rate,¹⁷ compared with 3.3% in this trial.

CONCLUSIONS

The 1-year follow-up data on subjects in the ANSWER trial show that the PulseRider offers a safe and effective adjunctive method of treatment for bifurcation aneurysms of the carotid terminus and basilar apex.

ACKNOWLEDGMENTS

We thank Alyssa Pierce for editorial assistance with manuscript preparation.

Disclosures: Alejandro M. Spiotta—RELATED: Support for Travel to Meetings for the Study or Other Purposes: Pulsar Vascular; UNRELATED: Consultancy: Penumbra, MicroVention, Stryker, Minnetronix, Cerenovus; Stock/Stock Options: Penumbra. M. Imran Chaudry—UNRELATED: Consultancy: Balt, Blockade Medical, EndoStream Medical, Medina, Medtronic, MicroVention, Penumbra, Pulsar Vascular, Synchron, Three Rivers Medical; Stock/Stock Options: Medina, Medtronic, Three Rivers Medical. Raymond D. Turner—RELATED: Grant: Pulsar Vascular*; UNRELATED: Consultancy: Codman, Penumbra, MicroVention, Stryker, Medtronic, Q'apel Medical, Rebound Medical. Aquilla S. Turk—UNRELATED: Consultancy: BALT International, Blockade Medical, Cardinal Consulting, Cerebrotech Medical Systems, Codman, Covidien, EndoStream Medical, Lazarus Effect, Medina, MicroVention, Penumbra, Pulsar Vascular, Siemens, The Stroke Project, Three Rivers Medical, Vastrax; Grants/Grants Pending: MicroVention, Penumbra, Stryker, Cerebrotech Medical Systems, Pulsar Vascular, Covidien, Three Rivers Medical, Codman, The Stroke Project*; Payment for Lectures Including Service on Speakers Bureaus: MicroVention, Penumbra, Stryker, Pulsar Vascular, Covidien, Three Rivers Medical, Codman, The Stroke Project; Stock/Stock Options: Blockade Medical, Lazarus Effect, Medina, The Stroke Project, Three Rivers Medical, Vastrax; Support for Travel to Meetings for the Study or Other Purposes: MicroVention, Penumbra, Stryker, Pulsar Vascular, Covidien, Three Rivers Medical, Codman, The Stroke Project. Colin P. Derdeyn—UNRELATED: Grant: Washington University, Comments: I directed the core lab for analysis for the ANSWER trial. This lab was supported by Pulsar Vascular.* J Mocco—UNRELATED: Consultancy: Rebound Medical, EndoStream Medical, Synchron, Cerebrotech Medical Systems; Other: Apama Medical, The Stroke Project, EndoStream Medical, Synchron, Cerebrotech Medical Systems, NeurVana, NeuroTechnology Investors, Comments: investor/ownership. Satoshi Tateshima—UNRELATED: Board Membership: Pulsar Vascular, Comments: Scientific Advisory Board for Pulsar Vascular from 2008 to 2016; Consulting Fee or Honorarium: Pulsar Vascular/Cerenovus; Grant: Cerenovus, Comments: educational grant for neurointervention clinical fellowship*; Stock/Stock Options: Pulsar Vascular, Comments: stock option 2008–2016. *Money paid to the institution.

REFERENCES

1. Aletich VA, Debrun GM, Misra M, et al. **The remodeling technique of balloon-assisted Guglielmi detachable coil placement in wide-necked aneurysms: experience at the University of Illinois at Chicago.** *J Neurosurg* 2000;93:388–96 Medline
2. Lefkowitz MA, Gobin YP, Akiba Y, et al. **Balloon-assisted Guglielmi detachable coiling of wide-necked aneurysms, Part II: clinical results.** *Neurosurgery* 1999;45:531–37; discussion 537–38 Medline
3. Malek AM, Halbach VV, Phatouros CC, et al. **Balloon-assist tech-**

- nique for endovascular coil embolization of geometrically difficult intracranial aneurysms. *Neurosurgery* 2000;46:1397–406; discussion 1406–07 Medline
4. Moret J, Cognard C, Weill A, et al. **Reconstruction technique in the treatment of wide-neck intracranial aneurysms: long-term angiographic and clinical results—apropos of 56 cases** [in French]. *J Neuro-radiol* 1997;24:30–44 Medline
 5. Raymond J, Guilbert F, Roy D. **Neck-bridge device for endovascular treatment of wide-neck bifurcation aneurysms: initial experience.** *Radiology* 2001;221:318–26 Medline
 6. Fiorella D, Albuquerque FC, Han P, et al. **Preliminary experience using the Neuroform stent for the treatment of cerebral aneurysms.** *Neurosurgery* 2004;54:6–16; discussion 16–17 Medline
 7. Fiorella D, Arthur AS, Chiacchierini R, et al. **How safe and effective are existing treatments for wide-necked bifurcation aneurysms? Literature-based objective performance criteria for safety and effectiveness.** *J Neurointerv Surg* 2017;9:1197–201 CrossRef Medline
 8. Turk A, Turner RD, Tateshima S, et al. **Novel aneurysm neck reconstruction device: initial experience in an experimental preclinical bifurcation aneurysm model.** *J Neurointerv Surg* 2013;5:346–50 CrossRef Medline
 9. Spiotta AM, Chaudry MI, Turk AS, et al. **Initial experience with the PulseRider for the treatment of bifurcation aneurysms: report of first three cases in the USA.** *J Neurointerv Surg* 2016;8:186–89 CrossRef Medline
 10. Gory B, Spiotta AM, Mangiafico S, et al. **PulseRider stent-assisted coiling of wide-neck bifurcation aneurysms: periprocedural results in an international series.** *AJNR Am J Neuroradiol* 2016;37:130–35 CrossRef Medline
 11. Spiotta AM, Derdeyn CP, Tateshima S, et al. **Results of the ANSWER trial using the PulseRider for the treatment of broad-necked, bifurcation aneurysms.** *Neurosurgery* 2017;8:56–65 CrossRef Medline
 12. Chow MM, Woo HH, Masaryk TJ, et al. **A novel endovascular treatment of a wide-necked basilar apex aneurysm by using a Y-configuration, double-stent technique.** *AJNR Am J Neuroradiol* 2004;25:509–12 Medline
 13. Akgul E, Aksungur E, Balli T, et al. **Y-stent-assisted coil embolization of wide-neck intracranial aneurysms: a single center experience.** *Interv Neuroradiol* 2011;17:36–48 CrossRef Medline
 14. Chalouhi N, Jabbour P, Gonzalez LF, et al. **Safety and efficacy of endovascular treatment of basilar tip aneurysms by coiling with and without stent assistance: a review of 235 cases.** *Neurosurgery* 2012;71:785–94 CrossRef Medline
 15. Cho YD, Park SW, Lee JY, et al. **Nonoverlapping Y-configuration stenting technique with dual closed-cell stents in wide-neck basilar tip aneurysms.** *Neurosurgery* 2012;70(2 Suppl Operative):244–49 CrossRef Medline
 16. Darkhabani ZM, Lazzaro MA, Zaidat OO. **Pericallosal artery aneurysm treatment using Y-configuration stent-assisted coil embolization: a report of four cases.** *J Neurointerv Surg* 2012;4:459–62 CrossRef Medline
 17. Fargen KM, Mocco J, Neal D, et al. **A multicenter study of stent-assisted coiling of cerebral aneurysms with a Y configuration.** *Neurosurgery* 2013;73:466–72 CrossRef Medline
 18. Martínez-Galdámez M, Saura P, Saura J, et al. **Y-stent-assisted coil embolization of anterior circulation aneurysms using two Solitaire AB devices: a single center experience.** *Interv Neuroradiol* 2012;18:158–63 CrossRef Medline
 19. Muda AS, Ralib AR, Yaacob Y, et al. **Y-stent-assisted coil embolization of wide-necked aneurysms using a new fully retrievable and detachable intracranial stent: report of two cases.** *Malays J Med Sci* 2011;18:91–97 Medline
 20. Perez-Arjona E, Fessler RD. **Basilar artery to bilateral posterior cerebral artery ‘Y stenting’ for endovascular reconstruction of wide-necked basilar apex aneurysms: report of three cases.** *Neurol Res* 2004;26:276–81 CrossRef Medline
 21. Rohde S, Bendszus M, Hartmann M, et al. **Treatment of a wide-necked aneurysm of the anterior cerebral artery using two Enterprise stents in “Y”-configuration stenting technique and coil embolization: a technical note.** *Neuroradiology* 2010;52:231–35 CrossRef Medline
 22. Sani S, Lopes DK. **Treatment of a middle cerebral artery bifurcation aneurysm using a double Neuroform stent “Y” configuration and coil embolization: technical case report.** *Neurosurgery* 2005;57(1 Suppl):E209 Medline
 23. Spiotta AM, Gupta R, Fiorella D, et al. **Mid-term results of endovascular treatment of wide-necked aneurysms using double stents in Y configuration.** *Neurosurgery* 2011;69:421–29 CrossRef Medline
 24. Thorell WE, Chow MM, Woo HH, et al. **Y-configured dual intracranial stent-assisted coil embolization for the treatment of wide-necked basilar tip aneurysms.** *Neurosurgery* 2005;56:1035–40; discussion 1035–40 Medline
 25. Zhao KJ, Yang PF, Huang QH, et al. **Y-configuration stent placement (crossing and kissing) for endovascular treatment of wide-neck cerebral aneurysms located at 4 different bifurcation sites.** *AJNR Am J Neuroradiol* 2012;33:1310–16 CrossRef Medline
 26. Cekirge HS, Yavuz K, Geyik S, et al. **A novel “Y” stent flow diversion technique for the endovascular treatment of bifurcation aneurysms without endosaccular coiling.** *AJNR Am J Neuroradiol* 2011;32:1262–68 CrossRef Medline
 27. Fiorella D, Arthur A, Boulos A, et al. **Final results of the US humanitarian device exemption study of the low-profile visualized intraluminal support (LVIS) device.** *J Neurointerv Surg* 2016;8:894–97 CrossRef Medline
 28. Hetts SW, Turk A, English JD, et al; Matrix and Platinum Science Trial Investigators. **Stent-assisted coiling versus coiling alone in unruptured intracranial aneurysms in the matrix and platinum science trial: safety, efficacy, and mid-term outcomes.** *AJNR Am J Neuroradiol* 2014;35:698–705 CrossRef Medline
 29. Spiotta AM, Derdeyn CP, Tateshima S, et al. **Results of the ANSWER trial using the PulseRider for the treatment of broad-necked, bifurcation aneurysms.** *Neurosurgery* 2017;81:56–65 CrossRef Medline
 30. Pierot L, Moret J, Barreau X, et al. **Safety and efficacy of aneurysm treatment with WEB in the cumulative population of three prospective, multicenter series.** *J Neurointerv Surg* 2017 Sep 30. [Epub ahead of print] CrossRef Medline