

Nonspecific Findings on MR Imaging

The Importance of Correlative Studies and Clinical Information

LEANNE L. SEEGER, M.D., DAVID H. DUNGAN, M.D., JEFFREY J. ECKARDT, M.D.,
LAWRENCE W. BASSETT, M.D., AND RICHARD H. GOLD, M.D.

Although magnetic resonance (MR) imaging is highly sensitive for the detection of abnormalities of the musculoskeletal system, changes in marrow and soft-tissue signal intensity are often nonspecific, and benign conditions may be mistaken for malignancy. In an effort to identify the cause of this type of misdiagnosis in MR examinations, the MR scans were reviewed of 30 patients whose images manifested bone and/or soft-tissue changes that were initially believed to be consistent with malignancy but were later found to represent benign conditions. Of the 30 patients, MR abnormalities were attributable to trauma in 11, benign tumors and tumorlike conditions in ten, infection in seven, and prior radiotherapy in two. In 24 cases, correlative imaging studies (14 patients), appropriate clinical history (six patients), and/or physical and laboratory examinations (four patients) would have avoided these misdiagnoses.

Magnetic resonance (MR) imaging is a highly sensitive method for the detection of musculoskeletal malignancy, including metastatic disease.^{5,6} Benign conditions such as trauma, benign tumors, and infection may, however, alter bone marrow and soft-tissue signal intensity in such a manner that the appearance is indistinguishable from malignancy.

From the Department of Radiological Sciences and the Department of Surgery, Division of Orthopaedic Surgery, UCLA School of Medicine, Los Angeles, California.

Reprint requests to L.L. Seeger, M.D., Department of Radiological Sciences, UCLA School of Medicine, Center for the Health Sciences, 10833 LeConte Ave., Los Angeles, CA 90024-1721.

Received: January 8, 1990.

To identify the causes of misdiagnoses and to determine ways to avoid them, a review was done of the MR images, MR requisitions or letters of referral, correlative imaging studies, and clinical histories of 30 patients in whom the initial primary MR diagnosis was malignant tumor and whose lesions were later found to be benign.

MATERIALS AND METHODS

All patients were referred to this institution with the presumed diagnosis of malignancy. Patient age ranged from five to 88 years, with a mean age of 47 years. Fifteen of the patients were women and 15 were men. Fourteen patients had a history of known or suspected extraosseous malignancy.

Referral letters and clinical histories provided on MR requisitions were reviewed. Notes were made of the availability or unavailability of correlative imaging studies at the time of MR imaging interpretation (roentgenograms, radionuclide bone scans, and/or computed tomography [CT] scans).

Because most MR scans were obtained and interpreted outside this institution, a variety of different imaging systems was represented. The acquisition technique, including imaging plane, field of view, slice thickness, and interval, and the use of surface coils varied according to the body part under investigation and the institution where the MR images were obtained. Readers included radiologists in general practice and specialists in either MR imaging or musculoskeletal radiology. The referring physician population was also varied, including general and family practitioners, internists, orthopedic surgeons, and rheumatologists.

Eleven patients ultimately were treated with biopsy or surgical excision of their lesion, and the remainder had either a minimum of one year of

clinical follow-up or correlative diagnostic imaging studies.

RESULTS

The correct diagnosis could be made in 24 of the 30 patients with correlative plain roentgenograms (seven patients), CT scan (seven patients), an adequate clinical history (six patients), and physical examination and/or laboratory data (four patients). Reevaluation of the MR images in one patient revealed the benign nature of a bony abnormality. Five patients required biopsy for diagnosis.

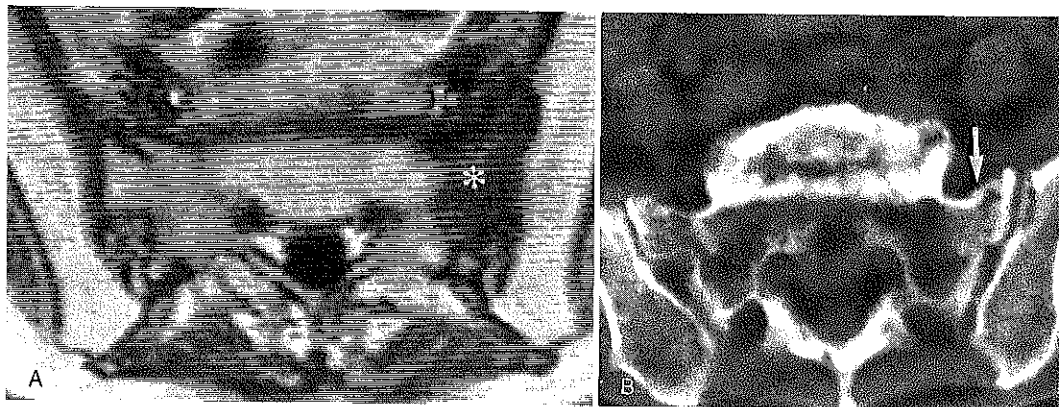
The ultimate correct diagnoses were divided into four major categories: trauma, benign tumors and tumorlike conditions, infection, and the effects of prior radiotherapy.

MR examinations of 11 patients manifested abnormalities that were later shown to represent trauma. This population included five patients with insufficiency fracture (Fig. 1), five with acute trauma (three bony and two soft-tissue) (Figs. 2 and 3), and one with a remote fracture. The correct diagnosis could have been achieved with an appropriate clinical history in four patients and plain roentgenographic correlation in one. Subsequent

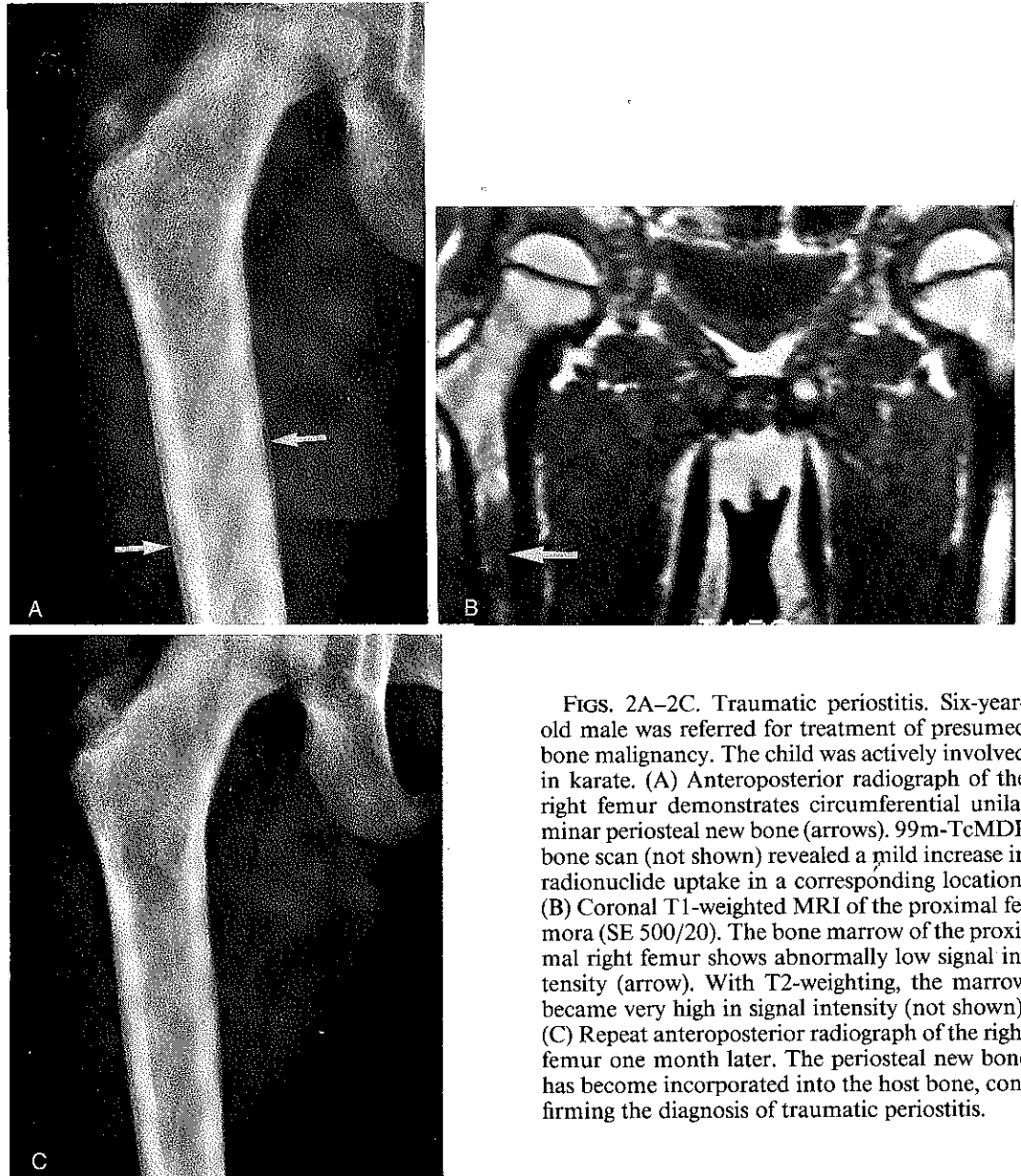
CT scans led to the correct diagnosis in an additional three patients. Review of the MR imaging examination of one patient revealed typical osteoporotic compression fractures without evidence of malignancy. Two patients required biopsy for diagnosis; both patients had a known extrasosseous malignancy.

Ten patients had MR image abnormalities that were shown to represent benign tumors or tumorlike conditions. These included enchondroma in four cases, bone island in three (Fig. 4), Paget's disease in two, and osteoblastoma in one. For all of these patients, the diagnosis of a benign condition could have been made had the MR imaging findings been correlated with additional imaging studies (plain roentgenograms in six patients and CT scans in four); however, these additional studies were not available at the time of MR image interpretation.

Seven patients with suspected malignancy were later proven to have infection as the cause of their MR image abnormalities. Four of the lesions were osteomyelitis and three were soft-tissue abscesses without bone involvement. All of these patients were treated with biopsy and/or drainage and debridement. The diagnosis of infection could have appropriately been made preoperatively in



FIGS. 1A AND 1B. Insufficiency fracture. Seventy-two-year-old female with a history of colon carcinoma and the recent onset of sacral pain. (A) T1-weighted axial oblique MRI (SE 450/28) reveals a focus of abnormal low signal intensity in the left sacral ala (*). Signal intensity became equal to that of the adjacent marrow with T2-weighting (not shown). This could represent a metastasis. (B) Thin-section CT scan reveals a non-displaced fracture in a corresponding location (arrow). There is no evidence for metastasis.

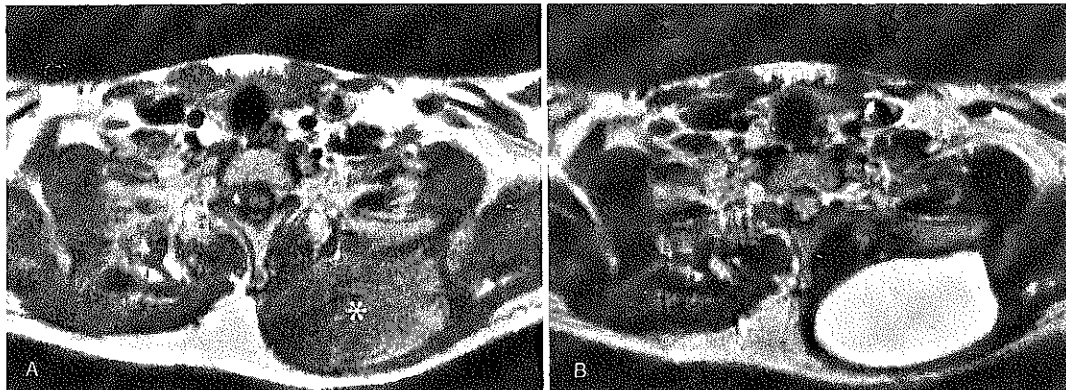

FIGS. 2A-2C. Traumatic periostitis. Six-year-old male was referred for treatment of presumed bone malignancy. The child was actively involved in karate. (A) Anteroposterior radiograph of the right femur demonstrates circumferential unilaminar periosteal new bone (arrows). $^{99m}\text{TcMDP}$ bone scan (not shown) revealed a mild increase in radionuclide uptake in a corresponding location. (B) Coronal T1-weighted MRI of the proximal femora (SE 500/20). The bone marrow of the proximal right femur shows abnormally low signal intensity (arrow). With T2-weighting, the marrow became very high in signal intensity (not shown). (C) Repeat anteroposterior radiograph of the right femur one month later. The periosteal new bone has become incorporated into the host bone, confirming the diagnosis of traumatic periostitis.

four of the seven patients if knowledge of the physical findings (erythema and edema) and laboratory data (markedly elevated sedimentation rate and leukocyte count) had been available at the time the MR imaging examinations were interpreted. Three patients required surgical biopsy for diagnosis (Fig. 5).

In each case, the biopsy provided specific information regarding the type of infecting organism and thus assisted in patient management.

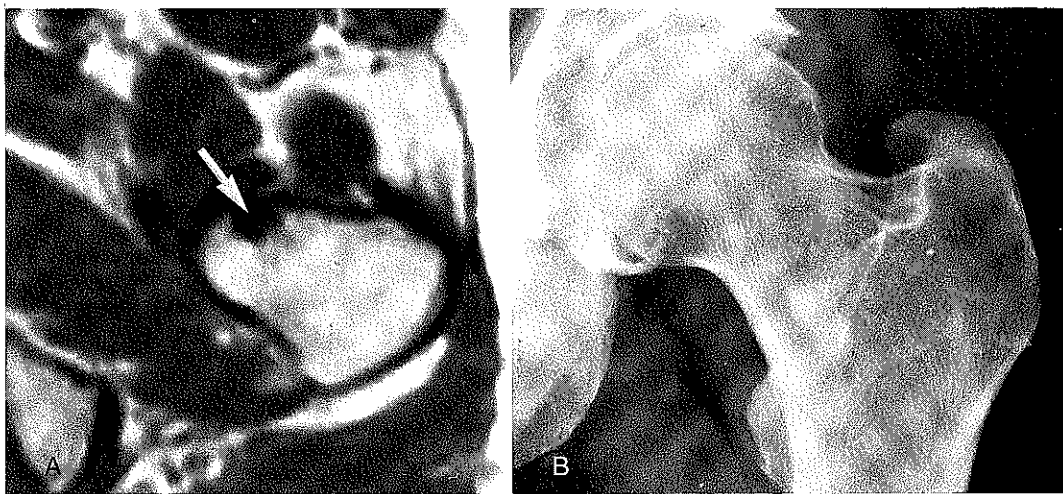
Two patients manifested marrow abnormalities in MR images secondary to prior radiotherapy. The history of previous radiation



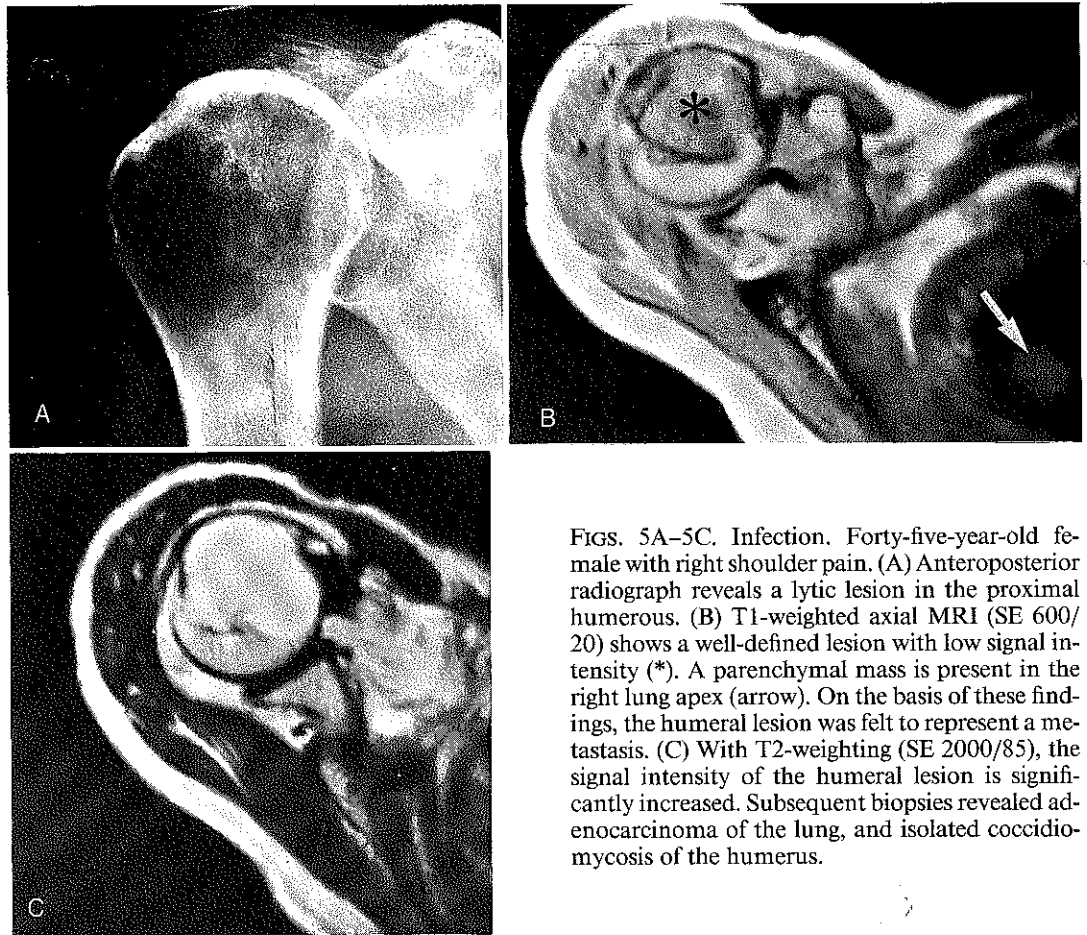
FIGS. 3A AND 3B. Subscapular bursitis. Thirty-four year-old male golf enthusiast presented with a firm, large mass on the upper back. (A) Axial T1-weighted MRI (SE 366/30) reveals a well circumscribed inhomogeneous mass in the soft-tissues of the left side of the upper back (*). (B) With T2-weighting (SE 2380/85), the mass has very high signal intensity. The diagnosis of sarcoma could not be excluded. Open biopsy showed a massively enlarged subscapular bursa filled with serous fluid, without any evidence of malignancy.

therapy was not provided on the MR imaging requisition for either patient but would have led to the correct diagnosis. In both instances, the high signal intensity marrow due to fatty

replacement was misinterpreted to represent normal fatty marrow, and adjacent hematopoietic marrow was thought to signify metastases.



FIGS. 4A AND 4B. Bone island. Sixty-six-year-old female with hip pain and a history of breast carcinoma. (A) Axial T1-weighted MR image through the hip (SE 500/30). A focus of abnormal low signal intensity is present in the marrow of the anterior femoral neck (arrow). With T2-weighting, the lesion retained low signal intensity (not shown). This could represent a blastic metastasis. (B) Radiograph reveals a homogeneously sclerotic lesion with peripheral spicules which blend into the surrounding trabecular bone. The diagnosis of quiescent bone island is confirmed by the inactivity of the lesion on radionuclide bone scan.



FIGS. 5A–5C. Infection. Forty-five-year-old female with right shoulder pain. (A) Anteroposterior radiograph reveals a lytic lesion in the proximal humerus. (B) T1-weighted axial MRI (SE 600/20) shows a well-defined lesion with low signal intensity (*). A parenchymal mass is present in the right lung apex (arrow). On the basis of these findings, the humeral lesion was felt to represent a metastasis. (C) With T2-weighting (SE 2000/85), the signal intensity of the humeral lesion is significantly increased. Subsequent biopsies revealed adenocarcinoma of the lung, and isolated coccidiomycosis of the humerus.

DISCUSSION

MR imaging has a high sensitivity for the detection of abnormalities in bone marrow and soft tissues. Trauma, tumor, and infection may, however, manifest low signal intensity in T1-weighted images and high signal intensity in T2-weighted images and may thus have a similar appearance on MR images. The time, effort, and expense required to investigate alternative diagnoses are relatively minor when compared to the morbidity, emotional stress, and expense of unnecessary biopsy, radiotherapy, and chemotherapy undertaken for benign conditions.

The most common reasons for misdiagnosis at the time of MR image interpretation were insufficient clinical information, including an appropriate history, physical examination, and laboratory data (ten patients), and lack of correlative roentgenograms (seven patients). In seven patients, thin-section CT scans through the region of interest provided sufficient additional information to allow the correct diagnosis to be made.

In cases of known acute trauma, marrow abnormalities on MR images are easily explained. However, when the traumatic episode is minor or has been forgotten, the resul-

tant MR image changes may be mistaken for malignancy. This is also true in the older patient in whom insufficiency or compression fractures may be present. Unfortunately, this is also the segment of the population in whom extraosseous malignancy is more common. Edema and/or blood may be present in the marrow surrounding a recent fracture or in the soft tissues secondary to contusion and hematoma. The signal characteristics of the marrow thus may be altered in both T1- and T2-weighted images.^{1,7,10} Roentgenography remains the most important initial imaging modality for the evaluation of osseous trauma. For cases in which MR imaging is nonspecifically abnormal and roentgenograms fail to reveal evidence of trauma, thin-section CT may demonstrate a subtle fracture. Recognition of common sites for insufficiency fracture (*e.g.*, the sacrum or pubic rami) may lead to additional imaging studies that can assist in differentiating a fracture from a tumor, especially in patients with known extraosseous malignancy.

Although MR imaging is useful in differentiating normal from abnormal tissue, excessive overlap between the signal characteristics of benign and malignant tumors prohibit MRI from reliably differentiating between them.³ Despite this drawback, a comparison of true T1- and T2-weighted images may assist in arriving at a diagnosis. Once again, a detailed clinical history, considerations of patient age and tumor location, and most importantly, roentgenograms are helpful.

MR imaging is useful in the diagnosis of osteomyelitis, and clearly delineates adjacent soft-tissue and joint involvement.^{2,8,9} Because acute osteomyelitis leads to increased water content in the marrow and soft tissues, it appears as a low signal intensity in T1-weighted images and as a high intensity in T2-weighted images. Intraosseous abscesses display similar signal characteristics but have well-defined margins. Correlative roentgenograms, physical findings, and laboratory data are important aids to diagnosis.

As in radionuclide bone scans, radiotherapy ports can be identified in MR images by their characteristic geometric shape and sharply defined borders. The appearance of irradiated bone varies with dose and time since treatment, but, in general, the marrow shows increased signal intensity in T1-weighted images because of fatty replacement.⁴ This abnormally high signal intensity may thus appear to represent normal marrow and the relatively lower signal of adjacent normal marrow may appear to be infiltrated with tumor. Knowledge of the site of the treated tumor and the radiation portals will lead to the correct diagnosis.

Under ideal circumstances, MR images should be acquired with full and complete patient history, and image interpretation should be performed with access to all previous imaging studies for a given patient. In the reality of clinical practice, however, this ideal situation is seldom achieved. Especially in instances in which initial roentgenograms or radionuclide bone scans are obtained at an institution other than that where the MR image is acquired, correlative studies that may lend significant insight into appropriate scan interpretation are often not available. The result is that MR image examinations may be read in a vacuum, often to the detriment of patient care. The nonspecificity of MR imaging therefore places an additional onus both on the referring physician to provide adequate clinical information and on the radiologist to seek answers to key questions regarding pain pattern, recent trauma, and physical findings. The routine use of a patient questionnaire regarding type and duration of symptoms, previous trauma, and prior surgical procedures and treatments can, in some instances, provide additional necessary information.

It is not possible to determine the true frequency of the problem of mistaken malignancy on MR image examinations. These 30 patients represent only those individuals seen by orthopedic oncology and musculoskeletal

radiology at this institution during a 1.5-year period. These cases, therefore, represent only a small segment of the total patient population of all clinical services.

REFERENCES

1. Lee, J. K., and Yao, L.: Stress fractures: MR imaging. *Radiology* 169:217; 1988.
2. Modic, M. T., Feiglin, D. H., Piraino, D. W., Boumphrey, F., Weinstein, M. A., Duchesneau, P. M., and Rehm, S.: Vertebral osteomyelitis: Assessment using MR. *Radiology* 157:157; 1985.
3. Pettersson, H., Slone, R. M., Spanier, S., Gillespy, T., III, Fitzsimmons, J. R., and Scott, K. N.: Musculoskeletal tumors: T1 and T2 relaxation times. *Radiology* 167:783; 1988.
4. Remedios, P. A., Colletti, P. M., Raval, J. K., Benson, R. C., Chak, L. Y., Boswell, W. D., and Halls, J. M.: Magnetic resonance imaging of bone after radiation. *Magn. Reson. Imaging* 6:301; 1988.
5. Richardson, M. L., Kilcoyne, R. F., Gillespy, T., III, Helms, C. A., and Genant, H. K.: Magnetic resonance imaging of musculoskeletal neoplasms. *Radiol. Clin. North Am.* 24:259; 1986.
6. Seeger, L. L., Bassett, L. W., Bertino, F., and Hanafee, W.: Magnetic resonance imaging for demonstrating undetected bone metastases. 16th International Congress of Radiology General Program, Honolulu, Hawaii, July 8-12, 1985.
7. Stafford, S. A., Rosenthal, D. I., Gebhardt, M. C., Brady, T. J., and Scott, J. A.: MRI in stress fracture. *AJR* 147:553; 1986.
8. Tang, J. S. H., Gold, R. H., Bassett, L. W., and Seeger, L. L.: Musculoskeletal infection of the extremities: Evaluation with MR imaging. *Radiology* 166:205; 1988.
9. Unger, E., Moldofsky, P., Gatenby, R., Hartz, W., and Broder, G.: Diagnosis of osteomyelitis by MR imaging. *AJR* 150:605; 1988.
10. Yao, L., and Lee, J. K.: Occult intraosseous fracture: Detection with MR imaging. *Radiology* 167:749; 1988.